THE

# DUBLIN DISSECTOR,

OR SYSTEM OF

# PRACTICAL ANATOMY.

1401

BY

ROBERT HARRISON, M.D., M.R.I.A.,

FELLOW OF THE ROYAL COLLEGES OF SURGEONS OF IRELAND AND OF ENGLAND;
PROFESSOR OF ANATOMY AND SURGERY IN THE UNIVERSITY OF DUBLIN;
AND ONE OF THE SURGEONS OF THE JERVIS-STREET INFIRMARY, ETC., ETC.

COLL · SANCTAE · INDIVIDUAE · TRINITATIS · REG · ELIZAB · JUXTA · DUBLIN

Fifth Edition,

WITH NUMEROUS ILLUSTRATIONS.

VOL. I.

DUBLIN:

…AFTON-STREET.

…ALL, AND CO.

RC-E02291
Sarasvati Mahal Library. Thanjavur

DUBLIN:
PRINTED AT THE UNIVERSITY PRESS,
BY M H. GILL.

# PREFACE.

In presenting a new Edition of the Dublin Dissector, or System of Practical Anatomy, I have to express my satisfaction at the favourable reception the former editions of this work have met with for many years.

Since its first appearance, in the year 1827, several editions have appeared, each containing some additions and improvements. The last having been for some time out of print, my Publishers have urgently requested me to prepare this edition, the completion of which has been unavoidably delayed by numerous other avocations.

Since the first appearance of this work numerous Manuals of Anatomy have been published in these as well as in other countries, some of which have been arranged very much after the same plan, others in a more systematic form.

In the present edition I have adhered very closely to that arrangement, which, being founded on practical experience, I originally adopted from a conviction of its being well suited to the improvement of the anatomical student: subsequent experience has confirmed this impression. The science, however, has of late years been

so extended that the chief difficulty I have experienced has been to condense into a reasonable and convenient compass all the important parts of such a very extensive and varied subject. I have not abridged any portions of the former editions, but have added to, and altered most; I have also corrected many errors and inaccuracies which escaped my observation in the original. I have introduced much new matter, particularly on General or Structural Anatomy, also on the Nervous System and on the Organs of Sense. The whole work has been revised with much care, and may indeed be said to have been re-written; and I trust it will be found to contain a tolerably correct and complete, though condensed, view of the most important details of human descriptive anatomy.

I have also, in the present edition, illustrated the descriptions by numerous Engravings, according to the plan now so generally adopted by writers on anatomy, as well as on other descriptive or demonstrative sciences. For the selection, arrangement, and descriptions of the wood-cuts I am indebted to Dr. John Hill, late Demonstrator of Anatomy in the Park-street School of Medicine, who has devoted much time and trouble to this task. Many of the cuts are from original drawings by Mr. Du Noyer, and a considerable number are reduced copies, by that artist, of engravings in the standard works of the present day.

In the preparation of this work, the great object I have always held in view has been to direct the student in the manner best adapted to facilitate his inquiries; in the descriptive details, therefore, I have prefaced

each with directions as to the best mode of displaying the anatomy of each region, and have then directed attention to those parts most useful in a practical, or most interesting in a physiological, point of view.

The many additions to the present work have increased it to such a size that I have deemed it advisable to divide the whole into two volumes or parts,—an arrangement which cannot, I think, be found in any way inconvenient, as each part contains distinct and independent subjects, and a copious Index of the entire is annexed to each volume.

I may take this opportunity of presenting my acknowledgments to numerous writers to whom I have referred, and from whom I have quoted in the following pages. I have also to offer my sincere thanks to my friends, Dr. Hill, for his exertions in respect to the wood-cuts, and Drs. Hatchell and King for their trouble in revising and correcting the Press.

ROBERT HARRISON.

1, *Hume-street*, *Dublin.*

# CONTENTS.

## VOLUME I.

## PART I.

### OF THE MUSCLES, VISCERA, ETC.


| CHAPTER. | | PAGE. |
|---|---|---|
| I. | ANATOMY OF THE EXTERNAL PARTS OF THE HEAD AND FACE, | 1 |
| | External Parts of the Head, | ib. |
| | General Remarks on Muscles of the Head, | 2 |
| | Division of, | ib. |
| | Superficial Muscles of the Head, | ib. |
| | Occipito-frontalis—Epicranial Aponeurosis, | ib. |
| | Vessels and Nerves of Scalp, | 3 |
| | Structure, Pathology, &c., of Scalp, | 4 |
| | External Muscles of Ear, | ib. |
| | External Parts of the Face, | 5 |
| | Division of Muscles of, | 6 |
| | Orbicularis Palpebrarum, | ib. |
| | Physiology, &c., of ditto, | 7 |
| | Tensor tarsi, or Horner's Muscle, | 8 |
| | Muscles of the Nose, Lips, &c., | ib. |
| | Buccinator Muscle, | 11 |
| | Physiology, &c, of Facial Muscles, | 12 |
| | Division of Glands in general, | ib. |
| | Peculiarities of Salivary Glands, | 13 |
| | Parotid Gland—Steno's Duct, | 14 |
| | Socia Parotidis, | ib. |
| | Vessels and Nerves of Parotidean Region, | 15 |
| | Pathology of Parotid Gland, | 16 |
| | Masseter Muscle, | ib. |
| | Temporalis Muscle—Temporal Aponeurosis, | 17 |
| | Pterygoid Muscles, | 19 |
| | Motions of lower Jaw, | 20 |
| | Vessels and Nerves of the Face, | 21 |

| CHAPTER. | | PAGE. |
|---|---|---|
| II. | ANATOMY OF THE NECK, | 24 |
| | The Muscles of the Neck, | ib. |
| | General Remarks, | 25 |
| | Platysma-myoides—Musculus Risorius Santorini, | 26 |
| | Cervical Fasciæ, | 27 |
| | Prevertebral Fascia, | 28 |
| | Sterno-cleido-mastoid Muscle, | ib. |
| | Division of Neck into triangular Regions, | 29 |
| | Sterno-hyoid, Sterno-thyroid, and Omo-hyoid Muscles, | 31 |
| | Thyroid Body—Levator Glandulæ, | 32 |
| | Physiology and Pathology of Thyroid Body, | 33 |
| | Digastric Muscle, | ib. |
| | Digastric Region, | 34 |
| | Submaxillary Gland, | ib. |
| | Whartonian Duct, | 35 |
| | Pathology of Submaxillary Gland, | ib. |
| | Mylo-hyoid and Genio-hyoid Muscles, | ib. |
| | Sublingual Space, | 36 |
| | Sublingual Gland, | ib. |
| | Hyo-glossus and Genio-hyo-glossus Muscles, | 37 |
| | Lingualis Muscle, | 38 |
| | Styloid Muscles, | ib. |
| | Vessels and Nerves of the Neck, | 39 |
| | Mouth, | 42 |
| | Tongue, | 43 |
| | Pathology of Tongue, | 44 |
| | Pharynx, | 45 |
| | Constrictors of Pharynx, | 46 |
| | Openings in Pharynx, | 49 |
| | Palate, Arches of; Uvula, | 50 |
| | Levator Palati and Tensor Palati Muscles, | 51 |
| | Motor Uvulæ, Palato-glossus, &c., | 52 |
| | Tonsil or Amygdala, | ib. |
| | Deglutition, three Stages of, | 53 |
| | Pathology of soft Palate, Tonsils, &c., | 55 |
| | Œsophagus, | 56 |
| | Pathology of Pharynx and Œsophagus, | ib. |
| | Larynx, | 57 |
| | Os Hyoides, | ib. |
| | Cartilages of Larynx, | 58 |
| | Ligaments of Larynx, | 61 |
| | Muscles of Larynx, | 63 |
| | Openings of Larynx, | 67 |
| | Vessels and Nerves of Larynx, | 68 |
| | Pathology of Larynx and Trachea, | 70 |
| | Deep Muscles of the Neck, | 71 |
| | Longus Colli, Recti Capitis antici, &c., | 72 |

| CHAPTER. | | PAGE. |
|---|---|---|
| III. | ANATOMY OF THE THORAX, | 74 |
| | Muscles on anterior and lateral parts of Thorax, | ib. |
| | Mammary Gland, | ib. |
| | Pathology of ditto, | 77 |
| | Pectoralis Major, | ib. |
| | Pectoralis Minor, &c., | 79 |
| | Serratus Magnus, | 80 |
| | Intercostal Muscles, | 82 |
| | Levatores Costarum, Triangularis Sterni, | ib. |
| | Axilla, | 83 |
| | Vessels and Nerves of Axilla, | 84 |
| | Cavity of the Thorax, | 85 |
| | Mode of opening Thorax, | 86 |
| | Anterior Mediastinum, | ib. |
| | Pleuræ, | 87 |
| | Ligamentum latum Pulmonis, | 89 |
| | Middle Mediastinum, | 90 |
| | Posterior Mediastinum, Vena Azygos, Thoracic Duct, &c. &c., | ib. |
| | Lungs, | 92 |
| | Roots of the Lungs, | 93 |
| | Structure of the Lungs, | 94 |
| | Pathology of Pleuræ and Lungs, | 97 |
| | Parts passing through upper Orifice of Thorax, | 98 |
| | Trachea, | 99 |
| | Bronchial Glands, | ib. |
| | Bronchial Tubes, | 102 |
| | Pericardium, | ib. |
| | Openings in fibrous Layer of Pericardium, | 106 |
| | Pathology of Pericardium, | 107 |
| | Heart, | ib. |
| | Pulmonary Artery, | 115 |
| | Ductus Arteriosus, | 116 |
| | Aorta, | 120 |
| | Endocarde, | 121 |
| | Vessels and Nerves of Heart, | ib. |
| | Muscular Tissue of Heart, | 124 |
| | Sounds of Heart, | 131 |
| | Pathology of Heart, | 132 |
| IV. | MUSCLES ON THE POSTERIOR PART OF THE TRUNK, | 134 |
| | Muscles of the Back—Ligamentum Nuchæ, | 134 |
| | Cervical Aponeurosis—Lumbar Fascia, | 135 |
| | Trapezius, | 137 |
| | Latissimus Dorsi, | 138 |
| | Rhomboid, minor and major, | 139 |
| | Levator Anguli Scapulæ—Serrati Postici, | 140 |

CHAPTER. PAGE.

IV. MUSCLES ON THE POSTERIOR PART OF THE TRUNK—*continued.*

Splenius Colli—Splenius Capitis, . . . . . . . . . 141
Sacro-lumbalis, Longissimus Dorsi, Spinalis Dorsi, Cervicalis Descendens, &c. &c., . . . . . . . . . . . 143
Recti Postici and obliqui Capitis, . . . . . . . . . 145

V. ANATOMY OF THE UPPER EXTREMITY, . . . . . . . 148

Muscles of the Shoulder and Arm, . . . . . . . . . ib.
Supra and infraspinous Fasciæ, . . . . . . . . . . ib.
Subscapular Fascia—Brachial Aponeurosis, . . . . 149
Superficial Veins of the Arm, . . . . . . . . . . . ib.
Deltoid Muscle, . . . . . . . . . . . . . . . . 150
Supraspinatus, . . . . . . . . . . . . . . . . 151
Infraspinatus—Teres Minor, . . . . . . . . . . . 152
Subscapular Muscle, . . . . . . . . . . . . . . 153
Remarks on Capsular Muscles of the Shoulder Joint, . 154
Teres Major Muscle, . . . . . . . . . . . . . . ib.
Coraco-brachialis and Biceps Muscles, . . . . . . 154
Semilunar Fascia, . . . . . . . . . . . . . . . 156
Brachialis Anticus, or Externus, . . . . . . . . . 157
Triceps Extensor Cubiti, . . . . . . . . . . . . ib.
Vessels and Nerves of the Arm, . . . . . . . . . . 159
Forearm and Hand, . . . . . . . . . . . . . . . 160
Subcutaneous Bursæ, . . . . . . . . . . . . . . ib.
Superficial Veins—Basilic, Cephalic, Median, . . . 161
Cutaneous Nerves, . . . . . . . . . . . . . . . ib.
Fascia of Forearm—Annular Ligaments, . . . . . . 162
Palmar Fascia, . . . . . . . . . . . . . . . . 163
Palmaris Brevis Muscle, . . . . . . . . . . . . . 164
Arrangement of the Muscles of Forearm, . . . . . ib.
Pronators and Flexors, . . . . . . . . . . . . . 165
Supinators and Extensors, . . . . . . . . . . . . 170
Muscles of the Hand, . . . . . . . . . . . . . . 175
Vessels and Nerves of the Forearm and Hand, . . . 181

VI. ANATOMY OF THE ABDOMEN AND PELVIS, . . . . . 184

Muscles on anterior and lateral Parts of Abdomen, . ib.
Superficial Fascia of Abdomen, . . . . . . . . . ib.
Scarpa's Fascia, Camper's Fascia, . . . . . . . . 185
General Observations on the Abdominal Muscles, . . 186
Obliquus Externus, . . . . . . . . . . . . . . . 188
Linea Alba, . . . . . . . . . . . . . . . . . . 189
Umbilicus, Lineæ semilunares, . . . . . . . . . . 190
Lineæ Transversæ, external inguinal or abdominal Ring, . . . . . . . . . . . . . . . . . . . 191
Intercolumnar Fascia—Spermatic or Cremaster Fascia, 192

CHAPTER. PAGE.

VI. ANATOMY OF THE ABDOMEN AND PELVIS—*continued.*

Poupart's or Fallopius' Ligament, or Crural Arch, . . 192
Gimbernaut's Ligament, . . . . . . . . . . . . 193
Triangular Ligament or Colles's Fascia, . . . . . . 194
Obliquus internus, . . . . . . . . . . . . . . . ib.
Conjoined Tendons, . . . . . . . . . . . . . . . 195
Cremaster Muscle, . . . . . . . . . . . . . . . ib.
Transversalis, . . . . . . . . . . . . . . . . . 196
Posterior Tendon of Transversalis, Fascia Lumborum, 198
Rectus, . . . . . . . . . . . . . . . . . . . . 200
Lineæ transversæ, . . . . . . . . . . . . . . . 201
Pyramidalis Muscle, . . . . . . . . . . . . . . 202
Fascia transversalis, . . . . . . . . . . . . . 203
Internal inguinal or abdominal Ring, . . . . . . . 205
Infundibuliform Fascia, . . . . . . . . . . . . . ib.
Tunica Vaginalis of the Cord, . . . . . . . . . . 206
Spermatic or inguinal Canal, . . . . . . . . . . ib.
Hernia, . . . . . . . . . . . . . . . . . . . . 207
Oblique inguinal Hernia, . . . . . . . . . . . . ib.
Coverings of oblique inguinal Hernia, . . . . . . ib.
Direct or ventro-inguinal Hernia, . . . . . . . . 209
Coverings of direct Hernia, . . . . . . . . . . . 210
Internal direct Hernia; external direct, . . . . . ib.
Crural Septum; Inguinal Pouches, . . . . . . . . 212
Epigastric Artery; Circumflex Ilii Artery, . . . . . 213
Femoral or Crural Hernia, . . . . . . . . . . . . 214
Inguinal Region, . . . . . . . . . . . . . . . . 215
Inguinal Glands, Saphena Vein, . . . . . . . . . 216
Fascia Lata, . . . . . . . . . . . . . . . . . . ib.
Cribriform Fascia; Hey's Ligament, . . . . . . . 217
Internal Surface of Crural Arch, . . . . . . . . . 219
Fascia propria, . . . . . . . . . . . . . . . . . ib.
Fascia iliaca, . . . . . . . . . . . . . . . . . 220
Parts which occupy the Crural Arch, . . . . . . . 222
Femoral or Crural Ring, . . . . . . . . . . . . . 223
Crural Sheath, . . . . . . . . . . . . . . . . . ib.
Coverings of Femoral Hernia, . . . . . . . . . . 224
Measurement of Parts engaged in Hernia, . . . . . 225
Viscera of the Abdomen, . . . . . . . . . . . . . 226
Regions of the Abdomen, . . . . . . . . . . . . . ib.
External Surface of the Peritonæum, . . . . . . . 228
Internal Surface, . . . . . . . . . . . . . . . . ib.
Anatomy of the Peritonæum, . . . . . . . . . . . 229
Omenta, Mesocolons, &c. &c, . . . . . . . . . . 234
Division of Viscera of Abdomen, . . . . . . . . . 238
Digestive Apparatus, . . . . . . . . . . . . . . ib.
Stomach, . . . . . . . . . . . . . . . . . . . . 240

CHAPTER. PAGE.

VI. ANATOMY OF THE ABDOMEN AND PELVIS—*continued.*

Coats or Tunics of Stomach, . . . . . . . . . . 241
Chymification, . . . . . . . . . . . . . . . . 245
Duodenum, . . . . . . . . . . . . . . . . . 246
Jejunum and Ileum Intestines, . . . . . . . . . . 247
Large Intestine, division of, &c., . . . . . . . . . 248
Cæcum or Caput Coli; Appendix Vermiformis, . . . 249
Ileo-colic Valves, . . . . . . . . . . . . . . 250
Colon, . . . . . . . . . . . . . . . . . . 251
Rectum, . . . . . . . . . . . . . . . . . 252
Structure of the Intestinal Canal, . . . . . . . . 253
Villi; Follicles of Lieberkühn, . . . . . . . . . . 256
Glandulæ Brunneri; Glandulæ Peyeri, . . . . . . ib.
Division of Mucous Membrane, . . . . . . . . . 259
Gastro-pulmonary Mucous Membrane, . . . . . . 260
Structure of Mucous Membrane, . . . . . . . . . ib.
Pathology of Peritonæum and Alimentary Canal, . . 262
Liver, . . . . . . . . . . . . . . . . . . 263
Structure of the Liver, . . . . . . . . . . . . 268
Vena Porta, . . . . . . . . . . . . . . . . 269
Gall Bladder, . . . . . . . . . . . . . . . . 272
Pathology of Liver and Gall Bladder, . . . . . . . 274
Spleen, . . . . . . . . . . . . . . . . . . 277
Pathology of Spleen, . . . . . . . . . . . . . 278
Pancreas, . . . . . . . . . . . . . . . . . 279
Pathology of Pancreas, . . . . . . . . . . . . ib.
Vessels and Nerves of the Abdomen, . . . . . . . 280
Kidney, . . . . . . . . . . . . . . . . . . 283
Structure of Kidney, . . . . . . . . . . . . . 284
Ureter, . . . . . . . . . . . . . . . . . . 288
Renal Capsule, or Suprarenal or Atrabiliary Body, . ib.
Pathology of Kidney, . . . . . . . . . . . . . 289
Deep Muscles of the Abdomen, . . . . . . . . . 290
The Diaphragm, . . . . . . . . . . . . . . . ib.
Ligamenta Arcuata, . . . . . . . . . . . . . 293
Openings in the Diaphragm, . . . . . . . . . . 295
Actions of the Diaphragm in Respiration, &c., . . . 298
Quadratus Lumborum; Psoas Parvus, . . . . . . . 300
Psoas Magnus, . . . . . . . . . . . . . . . 301
Iliacus Internus, . . . . . . . . . . . . . . 303
Perinæum in the Male, . . . . . . . . . . . . ib.
Anus; Sphincter Ani Externus, . . . . . . . . . 305
Sphincter Internus; Perinæal Fasciæ, . . . . . . . 306
Erector, or Compressor Penis, . . . . . . . . . . 308
Accelerator Urinæ, or Ejaculator Seminis, . . . . . 309
Compressores Venæ Dorsalis Penis, Transversalis Perinæi, . . . . . . . . . . . . . . . . . 310
Triangular Ligament of the Urethra, . . . . . . . 311

CHAPTER. PAGE.

VI. ANATOMY OF THE ABDOMEN AND PELVIS—*continued.*

Cowper's, or the Antiprostatic Glands, . . . . . . 312
Levator Ani Muscle, . . . . . . . . . . . . . . . 313
Compressores Urethræ, or Wilson's Muscles, . . . . 314
Guthrie's Muscles, . . . . . . . . . . . . . . . 315
Surgical Anatomy of Parts concerned in Lithotomy, . 316
Pubic Ligament; Coccygeus Muscle, . . . . . . . . 317
Triangular space on Fundus of the Bladder, . . . . ib.
Dissection of the Pelvis, . . . . . . . . . . . . 318
Pelvic Portion of Peritonæum, . . . . . . . . . . 319
Pelvic and Obturator Fasciæ, . . . . . . . . . . ib.
Vesical, Recto-vesical, and Rectal Fasciæ, . . . . . 320
Recto-bulbar Space, . . . . . . . . . . . . . . . 321
Urinary Bladder, . . . . . . . . . . . . . . . . ib.
Ligaments of the Bladder, . . . . . . . . . . . . 322
Coats of the Bladder, . . . . . . . . . . . . . . 325
Vessels and Nerves of the Bladder, . . . . . . . . 329
Pathology of the Bladder, . . . . . . . . . . . . 330
Organs of Generation in the Male, . . . . . . . . 331
Scrotum; dartos, . . . . . . . . . . . . . . . . ib.
Superficial Fascia, . . . . . . . . . . . . . . . 332
Tunica Communis, or Erythroides, . . . . . . . . ib.
Tunica Vaginalis, . . . . . . . . . . . . . . . 333
Tunica Albuginea; Tunica Vasculosa, . . . . . . 334
Testicle, . . . . . . . . . . . . . . . . . . . ib.
Epididymis, . . . . . . . . . . . . . . . . . . 335
Vas Deferens, . . . . . . . . . . . . . . . . . 336
Spermatic Cord, . . . . . . . . . . . . . . . . ib.
Vesiculæ Seminales, . . . . . . . . . . . . . . 337
Prostate Gland, . . . . . . . . . . . . . . . . 338
Penis, . . . . . . . . . . . . . . . . . . . . 339
Urethra, . . . . . . . . . . . . . . . . . . . 342
Method of injecting the Penis and Corpus Spongiosum Urethræ, . . . . . . . . . . . . . . . . 343
Pathology of Testicle, . . . . . . . . . . . . . 345
Pathology of Prostate Gland and Vesiculæ Seminales, ib.

VII. ORGANS OF GENERATION IN THE FEMALE, . . . . . 347

External Parts, . . . . . . . . . . . . . . . . ib.
Vagina, . . . . . . . . . . . . . . . . . . . . 351
Uterus, . . . . . . . . . . . . . . . . . . . . 352
Fallopian Tubes and Ovaries, . . . . . . . . . . 356
Pathology of Female Organs of Generation, . . . . 357

VIII. ANATOMY OF THE INFERIOR EXTREMITY, . . . . . 361

Muscles of the Thigh, . . . . . . . . . . . . . ib.
Cutaneous Veins, Nerves, and Lymphatics, . . . . . ib.

CHAPTER. PAGE.

VIII. ANATOMY OF THE INFERIOR EXTREMITY—*continued.*

Fascia Lata, . . . . . . . . . . . . . . . . . . . . 362
Muscles on the Forepart and Sides of the Thigh, . . 364
Tensor Vaginæ Femoris, . . . . . . . . . . . . . ib.
Sartorius, . . . . . . . . . . . . . . . . . . . . 365
Rectus Femoris, Vasti, Triceps Adductor, &c. &c., . . 366
Vessels and Nerves of the Thigh, . . . . . . . . . 371
Anatomy of the posterior Part of the Thigh, . . . . . 373
Muscles of the Hip, . . . . . . . . . . . . . . . 374
Glutæus Maximus, Medius, &c., . . . . . . . . . . ib.
Pyriformis, Gemelli, Obturator internus, externus, &c., 376
Glutæal and Sciatic Vessels, &c., . . . . . . . . . 379
Sciatic Nerve, &c., . . . . . . . . . . . . . . . 380
Muscles on the back Part of the Thigh, . . . . . . . ib.
Hamstring Muscles, . . . . . . . . . . . . . . . ib.
Poplitæal Space, . . . . . . . . . . . . . . . . 382
The Leg, . . . . . . . . . . . . . . . . . . . . 383
Fascia; Subcutaneous Veins and Nerves, . . . . . . 384
Plantar Fascia, . . . . . . . . . . . . . . . . . 385
Muscles on the anterior and external Part of the Leg, ib.
Tibialis Anticus, Extensor Digitorum Longus, &c. &c., 386
Extensor Digitorum Brevis, . . . . . . . . . . . 388
Peroneus Longus and Brevis, . . . . . . . . . . . ib.
Anterior tibial Vessels and Nerves, . . . . . . . . 389
Muscles on the Back of the Leg, . . . . . . . . . 390
Gastrocnemius, Plantaris, Solæus, &c. &c., . . . . . ib.
Muscles of the Foot, . . . . . . . . . . . . . . 396
Posterior tibial Vessels and Nerves, . . . . . . . 402

# TABLE OF ILLUSTRATIONS.

## VOLUME I.


| Fig. | | Page. |
|---|---|---|
| 1. | Muscles of the Head and Face, | 3 |
| 2. | Pterygoid Muscles, | 19 |
| 3. | Muscles of the Neck, superficial layer, | 25 |
| 4. | Muscles of the Neck, | 30 |
| 5. | Styloid Muscles and Muscles of the Tongue, | 37 |
| 6. | Cavity of the Mouth, | 42 |
| 7. | Muscles of the inferior region of the Tongue, | 44 |
| 8. | Muscles of the Pharynx ; posterior view, | 45 |
| 9. | Muscles of the Pharynx ; lateral view, | 47 |
| 10. | The Pharynx, laid open from behind, | 48 |
| 11. | Muscles of the soft Palate, | 55 |
| 12. | Cartilages of the Larynx ; lateral view, | 58 |
| 13. | Cartilages of the Larynx ; posterior view, | 59 |
| 14. | The Larynx ; vertical section, | 60 |
| 15. | The Rima Glottidis, | 62 |
| 16. | Muscles of the Larynx ; lateral view, | 64 |
| 17. | Muscles of the Larynx ; posterior view, | ib. |
| 18. | Muscles of the Neck ; deep layer, | 71 |
| 19. | Muscles of the anterior aspect of the Trunk, | 78 |
| 20. | Muscles of the Thorax and Neck ; lateral view, | 81 |
| 21. | Viscera of the Thorax, | 85 |
| 22. | Transverse section of the Thorax, shewing the relations of the Pleuræ, | 88 |
| 23. | The Heart and Roots of the Lungs ; anterior view, | 94 |
| 24. | The Trachea and Bronchial Tubes laid open, | 95 |
| 25. | Muscles of the posterior aspect of the Trunk, | 136 |
| 26. | Muscles of the Back ; second and third layer, | 139 |
| 27. | Muscles of the Back ; deep layer, | 142 |
| 28. | Muscles of the Shoulder, | 151 |
| 29. | Muscles of the Arm ; anterior view, | 153 |
| 30. | Muscles of the Arm ; posterior view, | 157 |
| 31. | Muscles of the anterior aspect of the Forearm ; superficial layer, | 164 |

FIG. PAGE.
32. Muscles of the anterior aspect of the Forearm ; deep layer, 168
33. Muscles of the posterior aspect of the Forearm ; superficial layer, . . . . . . . . . . . . . . . . . . . . 170
34. Muscles of the posterior aspect of the Forearm ; deep layer, 173
35. Muscles of the Hand, . . . . . . . . . . . . . . . 176
36. Muscles of the anterior aspect of the Abdomen, . . . . 187
37. Transverse Section of the Abdomen, . . . . . . . . . . 197
38. The Inguinal Region in the Male ; shewing the Anatomy of Inguinal Hernia, . . . . . . . . . . . . . . . . 204
39. The Coverings of a scrotal Hernia, . . . . . . . . . 208
40. The Abdominal Rings and Crural Arch in the Female, . . 215
41. Transverse Section of the Abdomen and Pelvis, shewing the posterior Surface of the anterior Wall of the Abdomen, the Relations of the pelvic Viscera, &c., . . . . . . . . 218
42. The anterior Surface of the Abdomen divided into Regions, 227
43. The Reflections of the Peritonæum, . . . . . . . . . 230
44. Transverse Section of the Abdomen, shewing the relations of the Peritonæum, . . . . . . . . . . . . . . . . 232
45. The Alimentary Canal, from the Œsophagus to the Rectum, . . . . . . . . . . . . . . . . . . . . . . . 239
46. The termination of the Ileum, and the commencement of the large Intestine . . . . . . . . . . . . . . . . 250
47. The Liver ; its superior and inferior surfaces, . . . . 273
48. Section of the Kidney, . . . . . . . . . . . . . . . 284
49. Diaphragm ; thoracic surface, . . . . . . . . . . . . 291
50. Diaphragm ; inferior or abdominal surface, . . . . . . 292
51. Muscles of the Perinæum, . . . . . . . . . . . . . . 304
52. Section of the Pelvis of the Male, shewing the Viscera *in situ*, . . . . . . . . . . . . . . . . . . . . . . . 315
53. Transverse Section of the Pelvis, shewing the arrangement of the Fasciæ, . . . . . . . . . . . . . . . . . . 323
54. The Urinary Bladder and Urethra laid open, . . . . . 328
55. Section of the Testicle, . . . . . . . . . . . . . . . 334
56. Section of the Pelvis of the Female, shewing the Viscera *in situ*, . . . . . . . . . . . . . . . . . . . . . . . 350
57. Muscles of the anterior aspect of the Trunk and Extremities, 360
58. Muscles of the Forepart and Sides of the Thigh, . . . . 365
59. Muscles of the posterior aspect of the Thigh and Leg, . . 372
60. Muscles of the Hip, . . . . . . . . . . . . . . . . . 374
61. Muscles of the anterior and external part of the Leg, . . 386
62. Muscles of the Back of the Leg ; deep layer, . . . . . 393
63. Muscles of the Sole of the Foot ; first layer, . . . . . . 396
64. Muscles of the Sole of the Foot ; second layer, . . . . . 398
65. Muscles of the Sole of the Foot ; third and fourth layers, . 399

THE

# DUBLIN DISSECTOR.

## CHAPTER I.

### DISSECTION OF THE EXTERNAL PARTS OF THE HEAD AND FACE.

## SECTION I.

### EXTERNAL PARTS OF THE HEAD.

The integuments (commonly called the scalp) covering the cranium are firm and dense, although when felt they give the sensation of being thin: the cuticle is delicate and scaly, but the cutis is very thick, and furnished with many sebaceous follicles. The subjacent cellular membrane contains granulated fat, and the bulbs of the hairs, which afterwards perforate the skin in an oblique direction. This tissue is condensed and lamellated, having somewhat a ligamentous structure, and adheres so intimately to the subjacent muscular and tendinous expansion, that the inexperienced student may find some difficulty in exposing the surface of the latter. Both this and the skin differ in structure in different situations; in the anterior third or fourth, or the frontal region, which is bald, and around which the hairs terminate in an abrupt line, as also around the ears, the cutis is delicate, and the cellular tissue is loose and contains less adeps; posteriorly they are more dense, vascular, and adherent, and perfect baldness seldom occurs; the hairs are stronger, they do not end abruptly, but continue soft and down-like for some distance along the neck: this part of the scalp is often found in the dead body congested with serous and sanguineous effusion, owing to the gravitation of the fluids after death.

Make an incision through the integuments along the median line, from the tuberosity of the occipital bone, as far forwards as the lower part of the forehead; from each extremity of this, make a transverse incision about three inches long; let the posterior one be parallel to the

superior transverse ridge of the occipital bone, and the anterior one parallel, and about half an inch superior to the eyebrow; cautiously dissect off the integuments from the subjacent muscular and tendinous expansion, which is the occipito-frontalis. This muscle, like most of the superficial muscles of the face, is closely attached to the skin, which circumstance, added to the paleness and smallness of their fibres, renders their dissection somewhat difficult and tedious; there is no deep or dense fascia covering these muscles, as in other regions of the body. Most of the superficial muscles of the head and face, during life, assist some of the organs of sense, and contribute to produce certain changes in the countenance, indicative of character or passion, and expressive of many diseases, tetanus, peritonitis, &c. In point of function, they may be considered as belonging to the class of mixed muscles, that is, they are in part voluntary and in part involuntary: with the exception of the aponeurosis of the occipito-frontalis, the tendon of the orbicularis palpebrarum, and that of the corrugator supercilii, there is no perfect tendinous structure in the other muscles of this class.

The superficial muscles of the head are divided into those of the cranium and face. Those of the cranium are the occipito-frontalis, and the three common muscles of the ear: to these some add the corrugatores superciliorum; these, however, I prefer placing among the muscles of the face.

Occipito-Frontalis is the only muscle which properly belongs to the scalp; it is a thin, broad, digastric, or rather quadriceps muscle, fleshy at each extremity, aponeurotic in the centre. It is often so pale, weak, and thin, as to be difficult of dissection; the occipital portions are less adherent to the skin and more distinct than the frontal; its tendinous expansion is stronger and more apparent before and behind than superiorly or laterally. It *arises* on each side by tendinous and fleshy fibres, from the two external thirds of the superior transverse ridge of the occipital bone, and from the external and posterior part of the mastoid process; the fibres on each side ascend from behind forwards and from without inwards, and soon terminate in one thin and broad tendon, which extends over the upper and lateral parts of the cranium.—This *epicranial aponeurosis* having arrived opposite the coronal suture, ends in two convex fleshy portions, broader and thicker, but paler, than the posterior extremities of the muscle; these anterior portions, which are thicker externally than internally, descend over the frontal bone, and are *inserted*, fleshy on each side, into the integument of the eyebrow, mixing with the fibres of the corrugator supercilii and orbicularis palpebrarum muscles: a small fleshy slip is often continued down along the nasal bones, and is attached to the internal angular process of the os frontis, and inferiorly to the nasal bones or cartilages: this slip is described by some as a distinct muscle, under the name of *pyramidalis nasi*, or fronto-nasalis. *Use.* The occipito-frontalis muscle can raise the eyebrows and integuments of the forehead into transverse wrinkles, draw the eyebrows a little outwards, and make tense the skin of the upper eyelids, and thus

expose the eyeball, as in staring; it can also pull the scalp backwards; but if the eyebrows be depressed and fixed, this muscle can then (particularly in some persons) draw the scalp downwards and forwards. This muscle is very closely connected to the scalp, particu-

*Fig.* 1.*

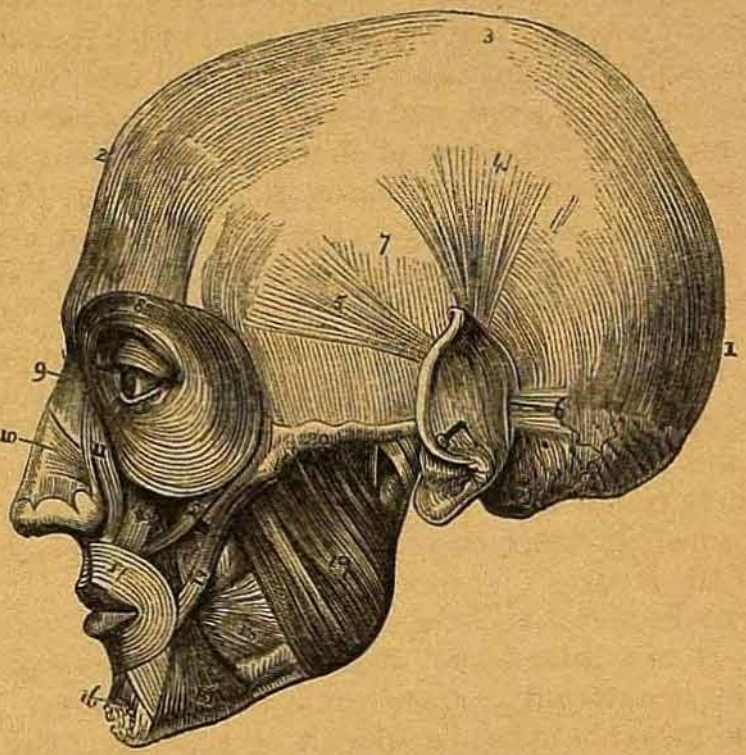

larly in front, but loosely to the cranium, it can thus move easily on the latter, carrying with it the former, which it also serves to support in apposition with the cranium, so as to prevent the skin slipping or yielding when any weight is pressed against the head.

Its origin is connected with the sterno-mastoid, the trapezius, and splenius muscles, and its insertion with those of the eyebrows. Some describe the occipito-frontalis, not as one, but as four distinct muscles, two on each side, under the names of the occipital and frontal muscles of each side, and consider the cranial aponeurosis as their common insertion.

Several vessels and nerves perforate this muscle, and ramify on its surface and in the integument, viz., anteriorly, the supra-orbital branches of the ophthalmic nerve and artery; laterally, the temporal

* The muscles of the head and face. 1. The occipital portion of the occipito-frontalis muscle. 2. Its frontal portion. 3. The epicranial aponeurosis. 4. The superior auris, or attollens aurem. 5. The anterior auris, or attrahens aurem. 6. The posterior auris, or retrahens aurem. 7. The temporal aponeurosis. 8. The orbicularis palpebrarum, which conceals the corrugator supercilii and tensor tarsi. 9. The pyramidalis nasi. 10. The compressor nasi. 11. The levator labii superioris alæque nasi. 12. The zygomaticus minor. 13. The zygomaticus major. 14. The levator labii superioris proprius; a part of the levator anguli oris is seen between the muscles 12 and 13. 16. The depressor labii inferioris. 17. The orbicularis oris. 18. The buccinator. 19. The masseter. 20. The zygomatic arch. 21. The mastoid process.

and posterior auris arteries, with branches of the portio dura and inferior maxillary nerves; and posteriorly, the occipital arteries spread their tortuous branches upwards and forwards, accompanied by the occipital nerves, branches of the second cervical nerve. It covers from behind forwards, the occipital, temporal, parietal, and frontal bones, also the upper portion of each temporal aponeurosis, the corrugator supercilii muscle, and the supra-orbital nerves and vessels. The cranial or epicranial aponeurosis is composed of tendinous fibres which are distinct, glistening, and parallel behind, but anteriorly, superiorly, and laterally become weak, greyish, and interlaced like cellular tissue, and frequently deficient in spots.

The integuments in this region are highly organized, being supplied with numerous nerves and vessels; these are derived from different and distant sources, and are chiefly destined to nourish the hair bulbs in the cellular tissue: in the line of the sutures they have frequent inosculations with the vessels of the diploe, and of the dura mater. This high organization of the scalp is not only of anatomical but of practical importance, as it serves to explain many of the *pathological* phenomena which are of ordinary occurrence in this region; thus, it is frequently the seat of encysted tumours, horny growths, &c.; these often appear to arise in the sebaceous follicles, the ducts of which have become obstructed from irritation or injury; a vitiated secretion then accumulates in the sac, which sometimes becomes circularly enlarged, and at others the contents slowly escaping from the ducts, and hardening, assume horny and various other appearances. The scalp is a common seat of erysipelas, both idiopathic and symptomatic. Injuries of it are of very frequent occurrence, and are more serious than those of the same extent in other situations. Incised wounds bleed more freely; punctured wounds are very frequently followed by high inflammatory symptoms, local and general, in consequence of matter being confined under the tense epicranial aponeurosis, which, in such cases, will require free division. The compact density of the cellular tissue explains the hard rim which surrounds the ecchymosis, the effect of contusion.

In the fœtus the scalp is very thin, and the aponeurosis is loosely attached to the pericranium by reticular membrane; this, and not the subcutaneous cellular tissue, is the seat of those large ecchymoses so commonly seen after parturition, and which in general are quickly removed by the absorbent system: at this age, too, the pericranium is very vascular, and except along the sutures is easily raised from the bones, numerous red dots indicating the ruptured bloodvessels.

The common muscles of the ear are three in number, viz., superior, anterior, and posterior auris:

SUPERIOR AURIS, or ATTOLLENS AUREM, is a small, thin, triangular muscle, situated on the temple and above the ear, *arising* broad and tendinous from the cranial aponeurosis, where it covers the temporal fascia on the side of the cranium, just above the external ear; the fibres descend converging, become fleshy, and are *inserted* into the

upper and anterior part of the cartilage of the ear. *Use*, to raise the cartilage, and deepen the meatus of the ear, also to make tense the epicranial fascia. This muscle is between the skin and temporal fascia, its anterior edge is confounded with the following muscle.

Anterior Auris, or Attrahens Aurem, is connected with the last, is of the same form, but smaller, and often indistinct; it *arises* from the posterior part of the zygomatic process, and from the cranial aponeurosis, passes backwards and downwards, and is *inserted* into the anterior part of the helix. *Use*, to draw the external ear forwards and upwards. This muscle is superficial, and lies on the temporal fascia, vessels, and nerves; its lower edge is lost in the cellular tissue.

Posterior Auris, or Retrahens Aurem, often consists of two or three distinct fasciculi, it is the strongest of these auricular muscles; it has no connexion to the epicranial fascia, but *arises* from the mastoid process above the sterno-mastoid muscle, passes forwards, and is *inserted* into the back part of the concha. *Use*, to enlarge the meatus of the ear and direct it backwards. This muscle is covered only by the skin, it lies upon the temporal bone.

In addition to these muscles, which move the external ear, there are several small muscles attached to different parts of the cartilages, which serve to alter their form, and expand their cavities; these muscles, as also those in the tympanum, shall be described hereafter in the dissection of the organ of hearing.*

## SECTION II.

### DISSECTION OF THE EXTERNAL PARTS OF THE FACE.

The muscles of the *face* require careful dissection; they are delicate, and often very pale; they may be classed into the superficial and deep: the former into those of the eyelids, nose, and mouth, being the dilators and constrictors of these openings; the latter into those of the lower jaw and palate. Make an incision around the base of the orbit, through the skin, which is here very fine, and closely adhering to the fibres of the orbicularis muscle; next make a perpendicular incision, along the middle line of the nose, to the centre of the upper lip, continue this in a semicircular manner round the angle of the mouth to the middle of the lower lip, and thence to the chin, and lastly from the chin to the angle of the jaw; reflect the integuments cautiously from the eyelids and side of the face, as far back as the ear, avoiding the slender muscular fibres which adhere to the skin, and the vessels and nerves which will be exposed in this dissection.

* Previous to, or immediately after dissecting the muscles of the face, the student should examine the brain, the description of which organ will be found at the head of the nervous system.

The integuments of the face are generally soft, delicate, and highly organized with vessels, nerves, and follicles; the vascularity is eminent in the lips and cheeks; hair, soft and downy, covers the greater portion, particularly in man; in the latter also the beard and whiskers, which are of variable extent and strength, require a corresponding organization in the cellular tissue: in the eyelids, the latter is loose and reticular, always free from adeps, but prone to serous infiltration; both skin and cellular tissue are more dense in the median line than laterally, especially on the nose and lip: adipose substance surrounds most of the muscles and abounds in the young, and at all ages, between the masseter and buccinator muscles.

The superficial muscles of the face may be considered as thirty-three in number, that is sixteen pair and one azygos, and are arranged as follows.

Three pair belong to the *palpebræ*, viz.: orbicularis palpebrarum, tensor tarsi, and corrugator supercilii, (the levator palpebræ is deep seated in the orbit, and is arranged among the muscles of that region).

Four pair belong to the *nose*, viz., pyramidalis nasi, levator labii superioris alæque nasi, compressor and depressor naris.

Three pair belong to the *upper lip*, viz., levator labii superioris, levator anguli oris, and depressor labii superioris.

Three pair belong to the *lower lip*, viz., depressor anguli oris, depressor labii inferioris, and levator labii inferioris.

Three pair belong to the *mouth*, viz., zygomaticus major, minor, and buccinator, and one azygos, the orbicularis oris; writers vary this arrangement, but no material difference exists.

Orbicularis Palpebrarum, or Sphincter Oculi, broad and thin, somewhat oval, in some subjects very pale and indistinct, in others strong and well marked, it adheres to the skin, surrounds the base of the orbit, covers the eyelids, and occupies a great portion of the face; it *arises* by several fleshy fibres from the internal angular process of the os frontis, and from the upper edge of a small horizontal tendon (which *tendon*, tendo oculi, or tendo palpebrarum, nearly one quarter of an inch in length, is *inserted* internally into the upper end of the nasal process of the superior maxillary bone, thence passes outwards and backwards to the internal commissure of the eyelids, where it forks into two slips which enclose the caruncula lachrymalis, and are *inserted* each into the tarsal cartilage, and the lachrymal duct); the fleshy fibres then proceed in curves, upwards and outwards along the upper edge of the orbit, the eyelid and tarsal cartilage, as far as the temple and external commissure of the eyelids; thence the fibres curve in a similar manner along the inferior eyelid and edge of the orbit to the internal canthus, where they are *inserted* into the nasal process of the superior maxilla, into the inferior edge of the horizontal tendon, and into the inner third of the lower edge of the orbit. *Use*, to close the eyelids, chiefly by depressing the superior, the levator muscle of which it directly opposes: it also serves to press the tears inwards towards the puncta lachrymalia; the superior orbital fibres

can depress the eyebrow and aid the corrugator supercilii in drawing it, as well as the eyelids, inwards, and oppose the occipito-frontalis and shade the eye; the inferior fibres can raise the cheek, raise and draw the lower eyelid inwards, and compress the lachrymal sac, which they cover. In sleep it is principally relaxed, and the eye is covered chiefly by the descent of the upper palpebra, its elevator muscle being also relaxed: when awake its contraction covers the globe, not only by bringing down the upper, but also by elevating the lower eyelid, hence the "equator oculi," the line formed by the approximated tarsi, is lower during real than in feigned sleep; in the former, also, the cornea is seldom entirely covered, as it always is in the latter.

This muscle is covered by and adheres to the skin; superiorly it overlaps and intermixes with the occipito-frontalis, and covers the corrugator supercilii, the temporal fascia, the frontal vessels and nerves, the tarsal cartilage and ligament, and the levator palpebræ superioris; inferiorly it intermixes with the muscles of the cheek and lips, and sometimes with the platysma myoides, it covers the malar bone, the inferior tarsus and its ligament, the origin of the levator anguli oris, levator labii superioris, and the infra-orbital vessels and nerves. The external or *orbital* fibres of this muscle are strong and red, and run circularly round the base of the orbit; the middle or *palpebral* fibres are pale, thin, and scattered, and are contained in the eyelids; the internal or *ciliary* portion is a thick but pale fasciculus, situated under the ciliæ, at the edge of each eyelid. The palpebral and ciliary portions adhere more closely to the skin, and present an elliptical appearance, as the fibres from the upper and lower eyelid intersect each other at the outer canthus, and adhere to the ligament of the external commissure. The horizontal tendon of this muscle passes across the lachrymal sac a little above its centre, and is a little twisted; a strong aponeurosis derived from its upper and lower edge, covers all the anterior surface of the sac, and adheres to the margins of the bony gutter, in which it is lodged, where it becomes continuous with the periosteum. This tendon can be seen or felt through the integuments during life, particularly when the muscle is in action, or when the eyelids are drawn towards the temple.

Both in structure and function this muscle belongs to the mixed class; the external, circular or orbital fibres are red, strong, and voluntary, and act very powerfully, as when we endeavour to screen the eye from too bright a light, while the inner portions of the muscle are relaxed, or only in slight action, whereas these latter fibres are weak, pale, and scattered, and essentially involuntary, and act in winking, while the orbital fibres are relaxed; during sleep also these fibres, like other sphincters, are in a state of gentle or tonic contractility. It sympathises with the eye in a remarkable and most useful manner; it possesses great irritability, particularly in children; in purulent and strumous ophthalmia it is frequently spasmodically contracted, and totally prevents the eye being seen; this affection is

somewhat analogous to the spasmodic constriction of the sphincter ani muscle.

In the operation of opening the lachrymal sac, the incision should commence immediately below this tendon, so as to avoid injuring it, and be carried obliquely downwards and outwards, to the extent of about half an inch.

Separate the orbicularis from the occipito-frontalis over the internal half of the superciliary arch, the tensor tarsi and the corrugator supercilii muscles will be exposed.

TENSOR TARSI *arises* tendinous from the posterior edge of the os unguis, where it joins the os planum, passes forwards between the conjunctiva and the expansion of the tendo oculi which covers the lachrymal sac, divides into two portions, which are inserted into the lachrymal ducts, along which the fibres extend, nearly as far as the puncta. *Use*, to draw the puncta and eyelids into close contact with the eye, also to press the puncta towards the nose, to compress the lachrymal sac, and to force out the secretion from the follicles of the caruncula lachrymalis. This muscle is also named HORNER's muscle, from its discoverer; it will be better seen if the two tarsi be divided about their middle, and their inner portions turned towards the nose without injuring the tendo oculi.

CORRUGATOR SUPERCILII *arises* fleshy and tendinous from the internal angular process of the os frontis, passes upwards and outwards, and is *inserted* into the middle of the eyebrow, mixing with the orbicularis and occipito-frontalis muscles. *Use*, to depress and approximate the eyebrows, throwing the skin of the forehead into vertical wrinkles, as in the act of frowning; this pair of muscles is voluntary, but they cannot act separately; they directly oppose the occipito-frontalis and shade the eye. They are covered by the orbicularis and occipito-frontalis, and lie on the os frontis and on the frontal nerve and vessels.

PYRAMIDALIS NASI, superficial, long, thin, often wanting, *arises* from the occipito-frontalis, descends close to its fellow between the brows, covering the nasal bones and sutures, becomes broad and aponeurotic, and is *inserted* into the compressor nasi muscle. *Use*, it raises the skin covering the ossa nasi, when the occipito-frontalis is in action, but if the latter be relaxed, it can then draw down the inner end of the eyebrow.

COMPRESSOR NASI is thin and triangular, placed on the side of the nose, between the skin and the cartilage; it *arises* from the inner side of the canine fossa, in the superior maxilla; the fibres pass forwards, expanding over the ala nasi, and are *inserted* by a thin aponeurosis into the dorsum of the nose, joining some fibres from the opposite side. *Use*, to press the ala toward the septum, or to draw it from it, so that it may alternately enlarge or diminish the anterior naris; its action will partly depend on the form of the cartilage; if convex, it may compress, if concave it may expand the ala nasi; in

difficult inspiration it appears in a state of increased action, and is then a dilator more than a compressor, at the same time raising the upper lip, but when inhaling odours it alternately expands and compresses the ala; in tetanus it permanently dilates it. The insertion of this muscle is connected with the occipito-frontalis, and pyramidalis, and its origin with the following, which partly covers it.

LEVATOR LABII SUPERIORIS ALÆQUE NASI is long, thin, and triangular, placed on the side of the nose, between the orbit and the upper lip; it *arises* by two origins; first, from the upper extremity of the nasal process of the superior maxilla; second, broad, from the edge of the orbit, above the infra-orbital hole; the fibres descend and converge a little, and are *inserted* into the ala nasi, and into the upper lip and orbicularis oris muscle: its name denotes its *use*. The superior and orbital origins of this muscle are covered by the orbicularis palpebrarum; the inferior portion is superficial; the angular vein and artery separate its origins: the orbital head covers the infra-orbital nerve and vessels, the levator anguli, and some of the orbicularis oris muscles.*

ZYGOMATICUS MINOR is very small, and sometimes wanting; it *arises* from the upper part of the malar bone, passes downwards and forwards, and is *inserted* into the upper lip near the commissure, uniting with the other muscles which are inserted there. *Use*, to draw the angle of the mouth upwards and outwards, as in smiling; it lies superior, and parallel to the major, between which, and the levator labii, it is inserted.

ZYGOMATICUS MAJOR is long and narrow, and inferior to the last; *arises* tendinous and fleshy from the lower part of the malar bone, near the zygomatic suture: it descends obliquely forwards, and is *inserted* into the angle of the mouth. *Use*, to draw the corner of the mouth upwards and backwards. The zygomatic muscles are partly concealed at their origin by the orbicularis palpebrarum; their insertion intermingles with the levator, depressor anguli, and orbicularis oris muscles; they lie on the malar bone, and cross the masseter and buccinator muscles, also the labial vein and artery, and they run superficial and superior to the duct of the parotid gland; they are imbedded in much soft adipose substance.

LEVATOR ANGULI ORIS (musculus caninus) is situated about the middle of the face, behind and a little external to the orbital portion of the levator labii superioris alæque nasi, or the levator labii of some; *arises* from the canine fossa in the superior maxillary bone, immediately

* The external or orbital head of this muscle is described by most writers as a distinct muscle, and has been enumerated by me as such; it is called *Levator Labii Superioris*: as, however, it will be found on dissection to be inseparably connected with the levator labii alæque nasi, I prefer describing it as part of the outer head of that muscle; in like manner I have united the *depressor labii superioris* or *incisor*, and the *depressor naris*, which are by some described as distinct muscles; much variety will be found in the number and structure of the muscles in the nasal and labial regions; this accounts for the different expression of the corresponding features during life, as also for the different descriptions given of these muscles by different authors.

below the infra-orbital foramen, and above the alveolus of the first molar tooth; it descends obliquely forwards and outwards, and is *inserted* narrow into the commissure of the lips and into the orbicularis oris; its name denotes its *use*. This muscle is covered by the orbicularis palpebrarum, levator labii superioris alæque nasi, zygomatic muscles, and by a quantity of soft adeps, also by the infra-orbital nerve and vessels, which ramify upon its surface and separate it from the orbital portion of the levator labii alæque nasi: it lies on the superior maxilla, the buccinator muscle, and the mucous membrane of the mouth.

Depressor Labii Superioris Alæque Nasi, a small flat muscle, very variable as to size and structure, exposed by everting the upper lip, and raising the mucous membrane on the side of its frænum; it *arises* from the myrtiform fossa in front of the alveoli of the canine and incisor teeth of the superior maxilla, ascends obliquely forwards, and is *inserted* into the integuments of the upper lip and into the fibro-cartilage of the septum and ala nasi. *Use*, to press the lip against the anterior teeth and even to draw it under these, also to depress the septum and ala nasi. It is covered by the levator labii, orbicularis oris, and mucous membrane, and it lies upon the bone.

Depressor Anguli, vel Triangularis Oris, flat and triangular, apex above, situated at the lower part of the face; *arises* broad and fleshy from the external oblique line on the outer side of the lower jaw, which extends from the anterior edge of the masseter muscle to the mental foramen; the fibres ascend converging, and are *inserted* narrow into the commissure of the lips, where the fibres are continuous or mingled with the orbicularis, zygomatic, and levator anguli muscles: its name denotes its *use*. This muscle is covered by the skin, some of its fibres are continuous with those of the platysma myoides; it overlaps the buccinator and the following muscle. The facial artery bounds its external edge and separates it from the masseter.

Depressor Labii Inferioris, vel Quadratus Menti, broad and somewhat square, *arises* from the side and front of the lower maxilla, just above its basis, internal to the last, and continues as far forwards as the middle line; the fleshy fibres, intermixed with fat, ascend a little inwards, decussating with some of the opposite muscle, and are *inserted* into half of the lower lip and into the orbicularis oris; its name denotes its *use*. This muscle is covered by the skin, and externally by the depressor anguli oris; it lies on the bone, the mental nerves and vessels, orbicularis oris muscle, and mucous membrane: by separating this from the last muscle, the mental nerve and vessels are exposed; the fibres are parallel, and many are continuous with those of the platysma; this muscle is difficult to dissect, its inner fibres being pale and intermixed with fat, it is not unlike the structure of the tongue: it conceals the following muscle.

Levator Labii Inferioris, vel Menti, is best exposed by turning down the upper lip, and raising the mucous membrane by the

side of the frænum; *arises* from the alveoli of the incisor teeth of the lower maxilla, by the side of the symphysis; the fibres diverge as they descend obliquely forwards between the mucous membrane and the depressor labii inferioris; *inserted* into the integument of the chin. *Use*, to elevate the chin and lower lip: this muscle is analogous to the depressor of the upper lip. It assists in forming the prominence of the chin.

Orbicularis, vel Sphincter Oris, surrounds the opening of the mouth; consists of two fleshy fasciculi, one for either lip, placed between the skin and mucous membrane, and constituting the chief thickness of the lip; these fasciculi decussate each other at the commissures, and intermix with all the dilating muscles inserted there. *Use*, to approximate the lips and regulate their motions in the acts of speaking and breathing, and to oppose the actions of the several muscles which are inserted into the commissures; it can also close the lips with different degrees of force, as in the process of suction, mastication, and deglutition. This muscle has no bony attachment; its fibres are blended with fat, particularly on their cutaneous surface; internally they are more smooth and distinct; they adhere most closely to the skin, and throw it into numerous minute rugæ when they contract.

Buccinator is broad, thin, and somewhat square; situated between the two alveolar arches, it forms the inner side of the cheek, and the lateral boundary of the mouth, and lies close to the mucous membrane of the latter; *arises* posteriorly from the two last alveoli of the superior maxilla, as far back as the pterygoid process, from the external surface of the posterior alveoli of the lower maxilla, as far back as the coronoid process, and form a strong aponeurosis, named the pterygo or *intermaxillary ligament* (which extends from the extremity of the internal pterygoid plate and tuberosity of the superior maxillary bone, to the root of the coronoid process, and which affords attachment to the superior constrictor of the pharynx posteriorly and to the buccinator anteriorly). From these three origins the fibres pass forwards, at first horizontally, but then converge, and the superior and inferior decussate, and are *inserted* into the commissure of the lips, where they intermix with those of the orbicularis and of the other muscles at the angle of the mouth. *Use*, to press the cheek against the teeth, so as to bruise and push the food between them, and to diminish the cavity of the mouth, as in mastication and deglutition; it is also much engaged in the articulation of certain expressions, as well as in filling wind instruments; it can also retract the commissure of the lips. The buccinator is covered, even in thin subjects, by a considerable quantity of fat, which separates it from the coronoid process of the lower maxilla, and from the insertion of the temporal muscle (this fat extends in the form of large, soft, round masses beneath the masseter muscle); it is also covered by the zygomatic, the depressor anguli oris and platysma muscles, and by the facial vessels; several branches of the facial artery and vein, and of the seventh and

fifth pairs of nerves, ramify on its surface; it lies on the mucous membrane and on a number of small round mucous glands called buccal; it is perforated near its superior posterior third by the duct of the parotid gland, opposite the lower edge of the second or third superior molar tooth, a strong fascia is continued from the outer coat of this vessel over the muscle.

The group of superficial muscles now described present peculiarities, both as to structure and function, when contrasted with those in other regions; the orbicularis oris has no bony attachment; all the other facial muscles have one extremity only inserted into bone or periosteum, and that in a very feeble manner, the other being attached to skin or subcutaneous or submucous tissue, or to some other muscle; they have little or no tendon in their structure; their fibres are weak, soft, and loosely connected to each other, without investing sheath or fascia; their general development is very variable, and bears no ratio in strength and colour to that of the general voluntary muscular system. They present many characters in common with the mixed class; the will has not perfect control over them, and they occasionally assist in respiration without its influence; nervous and mental emotions, health and disease, pleasure and pain, affect them in a well known and remarkable manner; by their habitual action they cause certain folds or lines in the skin, more or less permanent, which give rise to peculiar expressions of the countenance, indicative of corresponding feeling and passion, and thus lay the foundation for the study of physiognomy. A cheerful, joyous state of mind being for the most part denoted by an expansion and elevation of all the features, effected by the combined actions of the occipito-frontalis and of the elevators of the lips, and of their commissure; while in the opposite condition, that of sadness, sorrow, or deep thought, the countenance is rather elongated, and the features depressed by the corrugators of the eyebrows, and by the depressors of the lips and commissure, aided also by the platysma myoides, which latter, though arranged among the cervical muscles, yet plainly intermingles by many fibres with those of the lips and cheeks, and must therefore exert considerable influence in the motions of these parts, as also in the expressions of the countenance consequent thereon.

The deep muscles of the face, which are connected with the lower maxilla, and which are employed in the process of mastication, are the masseter, temporal, internal, and external pterygoid of each side: previous to dissecting these, the student should examine the situation and connexions of the parotid gland, the chief of the salivary glands. There are six *salivary glands*, three on each side, the parotid, submaxillary, and sublingual.

The salivary glands, together with the lachrymal, mammary, and pancreas, are commonly called conglomerate glands, in contradistinction to the absorbent, or lymphatic, or conglobate glands; this term, however, is by no means distinct or definite, for other glands, viz., the liver and kidney, are equally conglomerate, though not so ob-

viously such. The general arrangement of the glandular system we propose, is into two orders, the Absorbent and Secreting; the *absorbent*, or *lymphatic*, or *conglobate*, will be noticed hereafter: the *secreting* order may be divided into two classes, viz., the simple and the complex; the *simple* are the numerous glands which are attached very generally to the mucous membranes; the *compound* secreting or conglomerate glands are the lachrymal, salivary, mammary, pancreas, liver, kidney, prostate, and testis. There is no evidence for considering the pinæal, pituitory, thyroid, thymus, or supra-renal bodies, or the spleen and ovaries, as true glands.

The salivary glands, as well as the lachrymal, the mammary, and the pancreas, all correspond in certain characters, in which, also, they differ from other secreting glands: they are all symmetrical, except the pancreas, which, however, is attached to the digestive organs, the chief apparatus of organic life, one in which no symmetry is observed: they are of a pale gray colour, with a slight reddish tint; the virgin mammary gland is almost white; they have no perfect capsule, except the mammary, and that, though perfect, is very thin and loose; their form and size are not accurately defined, two or more being sometimes connected; they are very irregular in these respects; their texture is loose, that is, they consist of lobes which are composed of irregularly shaped lobules, these latter are separable into granules, each of which is formed by a final dilatation, or cœcal pouch of the minute ramification of an excretory duct, these ducts unite into larger or lobular ducts, and these finally unite into one or more excretory ducts; the lobules are but loosely connected by cellular tissue and vessels, while the granules themselves are very firm and compact. They are all well supplied with nutrient vessels; the arteries ramify minutely before they enter them, which they do at all parts of their surface, and not at any particular fissures, as in the liver and kidney; the transit of the carotid and facial arteries through the parotid and submaxillary glands is not an exception to this statement. The veins in like manner escape at different parts, and enter the neighbouring vessels. Their excretory ducts in some unite into one vessel, which proceeds to its destination, but in others, as in the lachrymal, mammary, and sublingual, they continue separate to the surface. In no case is there any perfect reservoir to delay or retain the secretion, as in the case of the liver and the gall bladder, the kidney and the vesica; the lachrymal sac cannot be considered as such, and the ampullæ in the mammary gland but imperfectly so. They are largely supplied with nerves, which, except the filaments of the sympathetic, accompanying the vessels, are derived from the spinal and cerebral system; the pancreas is an exception to this rule: not only cellular tissue in abundance, but even adipose, enter into their composition; they are in close connexion with the lymphatic or absorbent system, numerous lymphatic vessels pervade them, and lymphatic glands are in their close vicinity, and occasionally even imbedded in their substance. In many of these characters, the salivary glands form a remarkable contrast with the other complex secreting glands, which

will more fully appear when the latter come under our notice. All the secreting glands, simple as well as compound, are subject to many diseases; these will be noticed in the account of the individual glands.

The Parotid Gland is the largest of these conglomerate glands, it derives its name from its proximity to the ear; it is exposed by dissecting off the integuments and some fibres of the platysma, also a dense fascia which covers and adheres to it; this fascia is continued from that of the neck, spreads over the gland, is closely connected to the cartilaginous part of the meatus auditorius, and sends numerous processes into the gland in every direction, which serve to separate its lobules, and to conduct the different vessels through its substance. The parotid gland is not of any regular figure, by some it is considered pyramidal, the apex above, the base directed outwards and downwards; by others (the upper end being more developed), an irregular square; as such we shall consider it, and, of course, as presenting two surfaces, a superficial and a deep, and four margins, a superior, inferior, anterior, and posterior: it occupies, together with some other important parts, that deep excavation on the side of the face between the lower jaw and the auditory meatus, it also extends into the small region of the neck, named the posterior digastric space; it is bounded above by the zygoma, below by a line drawn from the angle of the jaw to the mastoid process, posteriorly by the meatus auditorius, the mastoid process, and sterno-mastoid muscle, and anteriorly by the masseter muscle, the posterior third of which it overlaps. The external surface is pale, flat, or slightly convex, in this respect, however, differing in different persons, as it also does in superficial extent; probably the absence of a regular capsule may in some measure account for this diversity; the anterior and inferior margins are the least defined, are irregular in their extent, in some they considerably exceed the ordinary bounds; the superior border is limited by the attachment of the fascia to the zygoma, and the posterior is resisted by the meatus of the ear, and by the sterno-mastoid muscle.

The connexions of the deep surface may be examined after the course of the excretory duct, and of the several vessels and nerves which pass through the gland, shall have been exposed. The *Parotid* or *Steno's duct arises* from its anterior superior border, and is formed by the union of numerous small vessels, which issue, each, from one of the granulations of the gland; it passes forwards over the masseter muscle, about an inch below the zygoma, parallel to a line drawn from the tube of the ear to midway between the commissure of the lips and the root of the nose; it winds round the anterior edge of the masseter, beneath the zygomatic muscles and through a quantity of soft adeps, pierces the buccinator, and opens through the mucous membrane of the mouth by a very small hole, without any papilla or projection, opposite the second or third superior molar tooth, about half an inch from the junction of the cheek with the gum. Between the duct and the zygoma, a small, smooth, glandular mass is frequently found, it appears like a detached lobe of the parotid, and is named the *socia parotidis;* from the lower and anterior part of this process, a small duct

proceeds, which after a short course unites with the duct of Steno; in some this duct opens distinctly into the mouth. The transverse artery of the face, and several branches of the facial nerve, accompany this vessel, and in general the artery is superior to it, while the nerves wind around it. This duct appears much larger than its calibre really is; it is formed of two coats, the external white, fibrous, and dense, commences beyond the anterior edge of the gland, and ends at the buccinator muscle; and the internal, a fine, delicate, mucous membrane, is continuous with that lining the mouth: the canal is larger at the commencement and outside the buccinator than in the intervening space, or at the orifice in the mouth.

The parts which pass through this gland are the external carotid artery and several of its branches, with their accompanying veins, and branches of the inferior maxillary and cervical nerves, also the plexus of the portio dura, or facial nerve. The first or most superficial of these parts is the *ascendens colli nerve*, or the superficialis colli or auricularis, it enters the gland near its lower border, and is lost chiefly in communicating with the *portio dura;* this last-named nerve escapes from the cranium by the stylo-mastoid foramen, enters the gland at its posterior inferior part, passes forwards and upwards through it, and forms in its substance the remarkable plexus, *parotidæan*, or *pes anserina*, which crosses superficial to the external carotid artery, and then separates into its two great divisions, the superior and inferior; a small portion of the gland intervenes between it and the vessels. The branch of the inferior maxillary nerve which traverses the gland is the *temporo-auricular*, which will be found between the neck of the lower jaw and the meatus auditorius, about half an inch above, but much deeper than the portio dura, with which it communicates, and for a branch of which it is sometimes mistaken.

The *external carotid artery* will be found to enter the lower border of the gland, near its deep surface; as it ascends it is crossed by the portio dura, and becomes much more superficial, its posterior auricular branch borders the lower and back part of the gland, the temporal ascends through it, the internal maxillary is deeply imbedded in it in its course forwards and inwards, the transverse facial artery also traverses it in a direction forwards, it also gives off numerous branches to the granules of the gland and to the ear. The veins corresponding to these arteries also pass through this organ; the temporal and internal maxillary, by their confluence, which is superficial to the external carotid artery, and very rarely to the portio dura also, forms the *external jugular vein*, which descends through the gland and becomes superficial in the neck. Several lymphatic vessels and glands are connected with the parotid, particularly along its inferior border; generally one or two small glands may be found imbedded in its substance, in front of the meatus auditorius, just where its cartilage is deficient.

Now divide the parotid duct, raise off the gland from the masseter muscle, and from the ramus of the jaw, and observe its several deep-seated connexions.

The deep or posterior surface of the gland is very irregular, it covers the posterior third of the masseter, also the ramus of the jaw behind which it sinks, and fills the deep excavation between this bone and the ear, envelopes the styloid process of the temporal bone and the muscles which arise from it, and touches the internal carotid artery, jugular vein, and the large nerves connected with these vessels; it also fills the posterior part of the glenoid cavity in the temporal bone, and adheres to the capsular ligament of the maxilla, inferiorly it is wedged in between the internal pterygoid, digastric, and styloid muscles.

The styloid process is in some cases so involved in this gland as to appear to divide it into a superficial and a deep lobe, the latter will then be deeper than this process and in close connexion with the great cervical nerves and vessels: a portion of the parotid will also be found to accompany the internal maxillary artery between the ramus of the jaw and its internal lateral ligament; this touches the inferior maxillary nerve, and in many instances extends into the fatty space between the two pterygoid muscles, where it swells out to a considerable size, so as to appear like a distinct lobe connected to the body of the gland by a narrow neck.

The parotid gland receives its nutrient vessels from the external carotid artery and its branches; its nerves are derived from the auricular branch of the fifth pair, from the cervical plexus, and from the sympathetic. The portio dura traverses it, but does not probably supply it, although some of its filaments can be traced to the fibrous coat of its ducts.

The parotid gland is composed of numerous small lobules, united together by cellular tissue, by branches of blood-vessels and nerves, and by the small roots of its excretory duct. A very small lobule can, by dissection and maceration, be divided into many smaller grains; it is probable that each minute granule is essentially a small cœcal pouch of a minute excretory duct; several of these latter coalesce to form the excretory duct.

The parotid gland is subject to several MORBID changes, viz., inflammation, or cynanche parotidæa, or parotitis, or mumps; abscess; hypertrophy, or scirrhous induration, which sometimes requires extirpation; scirrhus, ending in cancer; fistula, the effect of abscess or wound of the gland or duct; atrophy, or absorption; this latter condition is usually caused by tumours, lymphatic or encysted, these by degrees come to occupy the position of the gland and cause its absorption. Such tumours simulate the enlarged parotid, though essentially different; they admit of more easy extirpation, as they are usually surrounded by a capsule, and are not traversed by the adjacent nerves and vessels.

Next clean the masseter muscle and the temporal aponeurosis.

MASSETER.—The greater part of this muscle is superficial, it is thick and strong, covers the ramus and angle of the jaw, and consists of *two portions*, one anterior, which is the larger, the other posterior; these decussate each other; the *anterior arises* chiefly tendinous from the

superior maxilla where it joins the malar bone, also from the inferior edge of the latter, the fibres pass downwards and backwards and are *inserted* fleshy into the outer surface of the angle of the lower maxilla. The *posterior* or deep portion of the muscle *arises* chiefly fleshy from the edge of the malar bone and from the zygomatic arch, as far back as the glenoid cavity; the fibres descend, some vertically, others obliquely forwards, and are *inserted*, chiefly tendinous, into the external side of the angle and ramus of the jaw, as high as the coronoid process; thus the two layers of this muscle are contrasted both in the direction of their fasciculi, as well as in the relative position of their tendinous and fleshy fibres. *Use*, if both portions of both muscles act together, they will elevate the lower jaw; if the anterior portions only of opposite sides act together, they can carry the jaw forwards and upwards; and if the posterior alone, they can move it backwards and upwards; if the superficial layer of one side act alone it can rotate the chin to the opposite side, and if the deep layer only act it can rotate it to its own side. Thus the masseter muscles of opposite sides, by the alternate action of their different portions, are powerful agents in mastication; they not only cause the division of the food by the direct elevation and pressure of the lower maxilla against the upper, but they can also triturate it, by the great lateral motion of the jaw which their different laminæ are capable of exercising alternately. The masseter is covered by the skin, some fibres of the platysma and orbicularis palpebrarum, a portion of the parotid gland, and its excretory duct, by the transverse facial vessels and nerves, and by the zygomatic muscle. It lies on the ramus of the jaw, and conceals the insertion of the temporal, and the origin of the buccinator, from which it is separated by a great quantity of fat; the superficial layer covers the deep one, except a small portion of the latter near the articulation of the maxilla; strong, tendinous septa pass from the surface of this muscle through its substance, and adhere to the ramus of the bone beneath.

The masseter, by its superficial layer, may assist in dislocating the lower jaw, if it suddenly contract when the chin is much depressed. This muscle, like the temporal, appears to be much under the influence of the nervous system and extremely irritable, it is very seldom in a state of paralysis, even when the superficial muscles of the face are so; whereas in tetanus it is in a state of almost rigid contraction: in rigors also, or when exposed to much cold, these muscles evince their sympathy with the general system, the will loses all control over them, they act irregularly, and produce the "chattering of the teeth."

Temporalis is concealed by the temporal aponeurosis, the zygoma, and the masseter, it fills the temporal fossa, is thin and broad above, thick and narrow below. The *aponeurosis* is white and glistening, very strong and tense, of a semicircular form, adhering by its superior convex border to the semicircular ridge on the side of the cranium, which extends from the external angular process of the frontal along the parietal, as far back as the mastoid process of the temporal bone, and by its inferior straight margin to the upper edge of the zygoma,

and to the superior posterior edge of the malar bone. This fascia is thin above, the muscle appears through it; inferiorly it is thick and opaque; it consists of two laminæ which are very distinct inferiorly, some fat, vessels and nerves being interposed; the fibres composing the external layer run longitudinally, those of the internal irregularly. The temporal aponeurosis confines the muscle in its place, and gives additional origin to its fibres. Separate the masseter from its superior attachment, divide with the saw the zygoma at either end, and elevate it together with the lower part of the temporal fascia; the temporal muscle will be thus exposed. It consists of two laminæ, the superficial is thin, but the deep layer is very thick; an aponeurosis or tendon is between these. It *arises* from all the side of the cranium beneath the semicircular ridge on the parietal bone, and from all the temporal fossa and fascia; the fibres therefore are attached internally to the parietal, frontal, and temporal bones, also to the sphenoid as low down as the crest at the root of its great wing, which crest separates the temporal from the zygomatic fossa; anteriorly to the malar bone, and externally to the inside of the temporal fascia, and to the zygomatic arch. The fleshy fibres all descend converging; the middle nearly vertical; the anterior with a little obliquity backwards; the posterior, which are very long, pass nearly horizontally forwards, over a smooth surface at the root of the zygoma, and the inferior fibres, which arise from the crest on the sphenoid bone, are very short, and pass transversely outwards.

*Inserted* by a strong tendon into the coronoid process of the inferior maxilla; it nearly surrounds that process, except on its outer side, and is continued along its forepart as far as the last molar tooth. *Use*, to raise the lower jaw when the whole muscle acts; the anterior fibres may also advance the jaw, and the posterior long fibres can draw it backwards, while the inferior transverse fibres, which are nearly parallel to the external pterygoid muscle, may assist in its lateral and rotatory motions; this muscle, particularly its posterior portion, is the greatest security which the jaw possesses against dislocation, as it directly opposes the external pterygoid muscles which tend to advance the jaw, and to place its condyles on the zygomatic eminences. The temporal muscle is covered by the integuments, occipito-frontalis, superficial temporal vessels and nerves, temporal fascia, zygoma, masseter, orbicularis palpebrarum, and auricular muscles; it lies on the side of the cranium, and covers all the bones which compose the temporal fossa, also the deep temporal vessels, and part of the external pterygoid and buccinator muscles, from which it is separated by much fat.

Wounds of the temporal aponeurosis are often attended with serious effects, the severe pain and tension interfere with the action or extension of the muscle, the mouth can scarcely be opened, nor can mastication be performed without great difficulty; these symptoms simulate tetanus, from which, however, they may be distinguished by attention to the countenance and to the state of the muscles of the opposite side:

suppuration beneath this fascia is both troublesome and dangerous; injury to it should be avoided in arteriotomy. In vital powers this muscle is analogous to the masseter, it is largely supplied with nerves from the same source. Remove the temporal, masseter, and buccinator muscles, also the zygomatic arch, saw or break off, low down, the coronoid process, dissect away some fat, and the pterygoid muscles will be exposed, the dissection of which may be still further facilitated by dividing the side of the lower jaw in front of the insertion of the masseter, as the angle and ramus of the jaw can then be moved backwards and forwards.

*Fig. 2.**

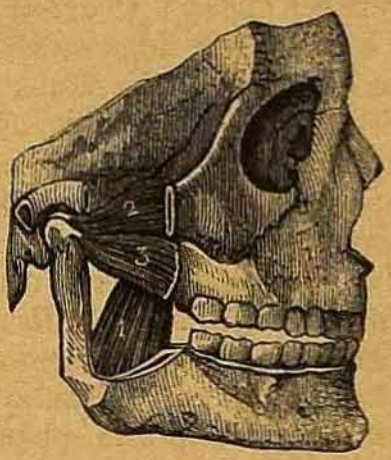

The pterygoid muscles are situated very deep behind the ramus of the lower jaw, they are two in number, internal and external, their names, however, only refer to their origins from the external pterygoid plate of the sphenoid bone, for neither are attached to the internal plate; that which is called external is nearer to the median line of the body, the internal is more superficial, and therefore first met with in dissection.

Pterygoideus Internus is strong, thick, and somewhat quadrangular, placed on the inner side of the ramus of the jaw, parallel and very similar to the superficial layer of the masseter muscle externally; it *arises* tendinous and fleshy from the inner side of the external pterygoid plate, and pterygoid process of the palate bone; it fills the greater part of the pterygoid fossa, descends obliquely outwards and backwards, and is *inserted* tendinous and fleshy into the inner side of the angle of the jaw, and into the rough surface above it. *Use*, if the muscles of opposite sides act together, to draw forwards and to elevate the jaw, thus cooperating with the superficial layers of the masseter muscles; if alternately, they can rotate it, each moving the jaw laterally, so as to turn it to the opposite side. This muscle is larger and longer than the external pterygoid, inferior and external to which it lies. Above, the tensor palati and superior constrictor, and below, the submaxillary gland are in contact with its internal surface: the ramus of the jaw is external to it, and separated from it by the dental nerve, the internal maxillary artery and its primary branches, which are protected from the pressure of the muscle by the internal lateral ligament of the jaw; the gustatory nerve crosses it in front: the lower and posterior extremity of this muscle is very superficial, lying be-

* The internal and external pterygoid muscles. The zygomatic arch and a portion of the ramus of the lower jaw have been removed. 1. The internal pterygoid. 2. The sphenoidal portion of the external pterygoid. 3. Its pterygoid portion. 4. The condyle of the lower jaw.

tween and in contact with the parotid and submaxillary glands: the upper extremity or origin is separated by the tendon of the tensor palati muscle from the internal pterygoid plate, it is concealed by, and lies deeper than that of the external pterygoid muscle.

Pterygoideus Externus is short and triangular, the base at the pterygoid process, the apex at the condyle, placed at the lower part of the temporal fossa; it *arises* broad and fleshy from the outer side of the external pterygoid plate, from the crest on the root of the great wing of the sphenoid (which divides the temporal from the zygomatic fossa), and from the back part of the tuberosity of the superior maxilla; the fibres pass outwards and backwards, horizontal, converging, and twisted, are *inserted* tendinous into the anterior and internal part of the neck of the lower jaw, into the interarticular cartilage and inferior synovial membrane. *Use*, when both muscles act, they draw forward the jaw, and at the same time the interarticular cartilages, which serve as moveable or temporary sockets to prevent the condyles slipping off the zygomatic eminences, when the chin is advanced, or the mouth much opened; if the muscle of one side only act, it will draw forward the condyle of that side, and turn the chin to the opposite, and therefore when both muscles act alternately, they will become the principal agents in triturating or grinding the food. The external pterygoid muscle lies in a transverse direction beneath the base of the cranium, superior to the internal pterygoid, except at its origin; it is internal and inferior to the temporal muscle, and is also concealed by the masseter and the ramus of the jaw; superiorly it is in contact with the sphenoid bone, posteriorly with a number of veins and with the inferior maxillary nerve at its exit from the foramen ovale, while anteriorly and inferiorly it is in contact with much adipose matter, and with the principal branches of the internal maxillary artery and inferior maxillary nerve. As the external and internal pterygoid muscles arise so near each other, and thence pass in different directions to their insertions, the external going transversely, and the internal descending, they leave between them a triangular space, which contains a quantity of fat, a small portion of the parotid gland, the internal maxillary artery and vein, and the dental and gustatory branches of the inferior maxillary nerve: as the internal maxillary artery is about to sink into the spheno-maxillary fossa, it sometimes passes between the origins of the external pterygoid muscle.

The condyles of the jaw enjoy a slight rotation forwards and downwards in the temporal articular cavities, they can also advance a little from the glenoid depressions, and descend so as to rest on the zygomatic tubercles. The lower jaw can be moved in five directions; depressed, elevated, carried forwards, backwards, and rotated to either side. Depression, whereby the cavity of the mouth is opened, follows the simple relaxation of the elevator muscles, as when asleep in the erect posture; but a greater depression, as in yawning, is effected by the platysma, digastric and hyoidæan muscles; in opening the mouth

very wide, the upper jaw is also raised by the sterno-mastoid and digastric muscles. Elevation of the lower jaw is performed by the combined actions of the temporal, the masseter, and the internal pterygoid muscles. The jaw is moved forwards by the internal pterygoid, the anterior fibres of the temporal, the superficial layer of the masseter, and, above all, by the external pterygoid muscles; if these of one side only act at a time, the chin will not only be advanced, but turned to the opposite side. The jaw is carried backwards by the deep layer of the masseter, and particularly by the posterior portion of the temporal muscle. In the rotatory motions, such as occur in mastication, the chin is moved from one side to the other by those muscles which can advance and draw back the condyles acting in alternate succession on opposite sides; during these rotatory motions, the elevators are also in slight action, and thus the food is perfectly comminuted by the pressure of the latter, and by the friction of the former against the uneven surfaces of the molar teeth.

The external pterygoid muscles are the chief agents in producing dislocation of the jaw; when the mouth is widely opened, their spasmodic action may suddenly draw the condyles and interarticular cartilages forwards off the tubercles into the zygomatic fossæ.

## SECTION III.

### VESSELS AND NERVES OF THE FACE.

THE arteries which are to be met with in the dissection of this region, are the facial and the terminating branches of the external carotid; the nerves are branches of the seventh and fifth pair. The *facial artery*, which is a branch of the external carotid, is seen winding round the side of the jaw, anterior to the masseter, and running in a contorted course towards the commissure of the lips, and thence ascending along the side of the nose, to the internal canthus of the eye; in this course it sends off numerous *muscular branches*, the *coronary arteries of the lips*, the *nasal*, and terminates in the *angular*, which communicates with the ophthalmic artery, at the inner side of the orbit. The facial artery and its divisions are accompanied by corresponding veins: the *facial vein* is not coiled like the artery, but is straight, and lies to its outer side; at the lower edge of the jaw it generally, but not always, divides into two branches, one superficial joins the external jugular vein, the other passing deeper in the neck joins the internal jugular. *The external carotid artery*, which is seen ascending from the neck into the parotid gland, gives off numerous branches to its several lobules, and to the ear, and a little below the condyle of the jaw divides into the transversalis faciei, temporalis superficialis, and maxillaris interna. *The transverse artery of the face*

crosses the masseter above, sometimes below the parotid duct, and divides into small muscular branches, some of which communicate with the facial and infra-orbital arteries. *The temporal artery* ascends behind the articulation of the maxilla, on the temporal aponeurosis, and soon divides into an anterior and posterior branch; the former is directed towards the forehead, supplies the integuments and muscles there, and communicates with the frontal branches of the ophthalmic artery; the posterior division of the temporal runs tortuously upwards and backwards, and divides into numerous branches, which supply the integuments and inosculate with the occipital and posterior auris arteries. *The internal maxillary artery* is the largest branch of the carotid; it bends in behind the neck of the lower jaw, between the bone and the internal lateral ligament, then runs tortuously between the pterygoid muscles upwards, forwards, and inwards, to the lower and back part of the orbit, where it sinks into the spheno-maxillary fossa; in this course it sends off the *middle artery of the dura mater*, the *inferior dental*, several *muscular branches* to the temporal, masseter, pterygoid, and buccinator muscles, and terminates by dividing into the *nasal*, *descending palatine*, and *infra-orbital arteries.* Veins accompany these different arteries, and in the parotid gland we find the temporal and internal maxillary veins forming a plexus from which proceeds a considerable vessel called the external jugular vein, which will be afterwards seen descending superficially in the neck. (For the particular description of the blood-vessels of the face, see the Anatomy of the Vascular System).

The nerves which are met with in the dissection of the face are branches of the seventh and fifth pair; those of the seventh, or the portio dura, have in general a *transverse* direction from behind forwards, are remarkable for their plexiform arrangement, and have numerous communications with the three branches of the fifth, which are distributed chiefly in a *vertical* direction along the anterior part of the face. The *portio dura* escapes from the temporal bone through the stylo-mastoid hole, and immediately gives off two or three small branches, the posterior *auricular*, *digastric*, and *stylohyoid;* it then turns forwards into the parotid gland, superficial to the blood-vessels, here it divides into two large branches, the temporo-facial, and cervico-facial, which subdivide and join again by several filaments forming the plexus, named *pes anserinus*, or *parotidæan plexus*, from which proceed several branches; some ascend obliquely forwards to the temple and forehead, others pass transversely to the muscles of the face, and several descend along the side of the neck, some parallel and others inferior to the side of the lower maxilla.

The fifth pair of nerves consist of three portions, viz., the ophthalmic, superior maxillary, and inferior maxillary; a branch of each of these divisions is met with in the dissection of the face. The *frontal* nerve, which is a branch of the ophthalmic, or first division of the fifth, is seen escaping from the orbit by the superciliary notch or fora-

men; it then ascends on the forehead, distributes its branches to the integuments and muscles, and communicates with the portio dura. The *infra-orbital* nerve, which is a branch of the superior maxillary, or second division of the fifth, is observed passing out of the infra-orbital foramen, behind the levator labii superioris alæque nasi, and dividing into several branches; the most of these pass obliquely downwards, and communicate freely with branches of the seventh pair. Through the mental foramen the *mental nerve* escapes: this is a branch of the inferior maxillary, or third division of the fifth pair; most of its branches ascend to the muscles of the lower lip, and several communicate with the portio dura. The temporo-auricular nerve is also a branch of the inferior maxillary, it lies deep-seated in the parotid gland, close to the meatus auditorius, to which it sends some branches, while others ascend with the temporal artery. (For the more particular description of the nerves of the face, see the Anatomy of the Nervous System).

The mouth, fauces, and palate, are the parts of the face next in order to be examined; but as these are connected and continuous with the pharynx, and as this organ cannot be seen until the muscles of the neck have been removed, the student had better postpone the dissection of the former until he has become acquainted with the anatomy of the latter; we shall therefore proceed next to the dissection of the neck.

# CHAPTER II.

## DISSECTION OF THE NECK.

## SECTION I.

### OF THE MUSCLES.

THE neck implies that contracted portion of the trunk between the head and chest; the cervical vertebræ alone forming its skeleton or support. It contains, besides the pharynx and œsophagus, larynx and trachea, numerous muscles, nerves, and vessels, whose mutual relations are complicated and intricate, but an accurate knowledge of which is of great practical importance. The neck presents a posterior, anterior, and two lateral aspects. The dissection of the posterior must be deferred, and conducted along with that of the back generally, from which it cannot be accurately separated, either superficially or still less in regard to its muscular contents; the lateral and anterior regions may now be examined.

Raise the shoulders of the subject by blocks placed beneath them, so as to make tense the muscles in this region; divide the integuments, which are thin and delicate, near to, and in a line with the clavicle, also along the side of the jaw, from the chin to the mastoid process; connect these incisions by another made in a perpendicular direction, in the middle line from the chin to the sternum; dissect off the integuments from before backwards, in an oblique direction, from the chin towards the clavicle; this should be done cautiously, to avoid injuring the platysma or fascia; in the child and in the female there is generally more subcutaneous fat than in the male subject. The platysma myoides will be now fully exposed, and the sterno-mastoid and hyoid muscles partially so; in the middle line of the neck a chain of projections may be observed which can also be felt during life, viz., a little below, but at some distance behind the chin, is the body of the os hyoides; inferior to this is the angle of the thyroid cartilage; next is the cricoid, below which the commencement of the trachea may be felt, on the forepart of which the soft swelling of the thyroid body can be discerned; and lastly, the continuation of the trachea descending into the chest. The distance between the chin and sternum, and the intervals between these several eminences, are much affected by the position of the neck from flexion to the extreme degree of extension. In the latter state, the space between the inferior

maxilla and the os hyoides, as also between the latter and the thyroid cartilage, is greatly augmented, the trachea also is elongated and drawn upwards from the thorax; in flexion, on the contrary, the os hyoides is within the arch of the lower jaw, the cartilages of the larynx are pressed together, and but a short portion of the trachea is in this region. By altering the position of the neck, the student will soon perceive these facts, and cannot fail to conclude how much the details of any operation in the neck must be influenced by them.

The muscles on the anterior part of the neck are very numerous, they are concerned in several functions and execute different motions; some act as the ordinary muscles of locomotion, others are occasionally engaged in deglutition, and in respiration, also in the exercise of voice and speech. They are symmetrical, or similar on each side of the middle line; they are twenty-one pair in number, and may be arranged for the convenience of dissection into three layers, a superficial, middle, and deep; the superficial consists of two pair, the platysma myoides and sterno-cleido mastoid; the middle may be divided into two orders, the superior and inferior; the inferior are three in number, viz., sterno-hyoid, thyro-hyoid, and omo-hyoid; the superior are nine in number, viz., digastric, mylo-hyoid, genio-hyoid; three styloid muscles, hyo-glossus, genio-hyo-glossus, and lingualis muscles; the deep layer consists of seven pair, viz., longus colli, rectus capitis anticus, major and minor, rectus lateralis, and three scaleni; this arrangement excludes the muscles of the palate, pharynx, and larynx.

*Fig.* 3.*

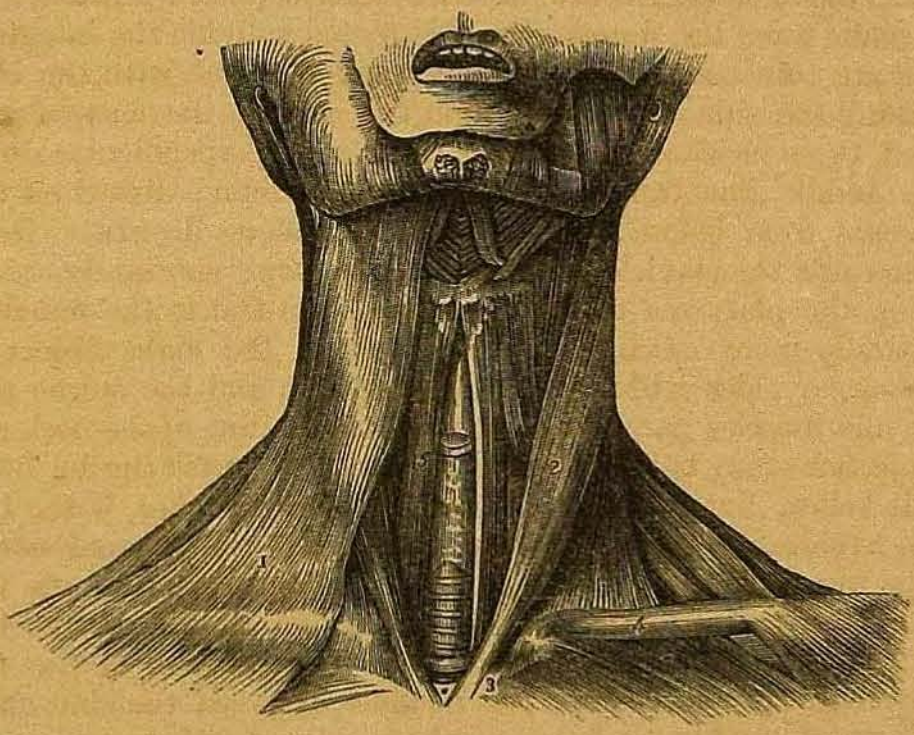

* The superficial muscles of the neck. 1. The platysma myoides. 2. The sterno-cleido mastoideus. 3. Its sternal attachment. 4. Its clavicular attachment. 5. The sterno-hyoideus.

PLATYSMA-MYOIDES, or latissimus colli, is a thin and pale cutaneous muscle, analogous to the panniculus carnosus of quadrupeds; in many subjects weak, and even indistinct; it is situated on the fore-part and side of the neck, extending from the chest and shoulder to the face; its figure is somewhat square, but a little longer than it is broad, and narrower in the centre than at either end; it *arises* by many fine fleshy fibres from the cellular membrane, covering the upper part of the deltoid and pectoral muscles, a few also adhere to the clavicle; the fibres ascend obliquely inwards; at first loosely, afterwards closely connected to each other, and form a broad thin muscle, which covers the side and forepart of the neck; occasionally fine aponeurotic or short tendinous fibres may be noticed, prolonged into the cutis: *inserted*, first, into the skin and cellular tissue on the chin, decussating there with fibres from the opposite side; second, into the fascia along the side of the lower jaw, a few only into the bone; some fibres may be traced high on the face, and seen to join the depressor anguli oris, the zygomatic, and orbicularis palpebrarum muscles; and third, into the fascia, which covers the parotid, and which adheres to the meatus auditorius; some of these latter fibres take a waving transverse direction towards the commissure of the lips, and constitute the musculus *Risorius Santorini;* this transverse band is sometimes very strongly marked. *Use*, to depress the angle of the lips and the lower jaw, but if the mouth be closed it may elevate the integuments of the neck, and fold them into transverse wrinkles; it also serves to compress and support the several muscles, glands, and vessels in this region. The platysma is covered only by the skin; it partly conceals the clavicle and the deltoid and pectoral muscles, the sterno-mastoid, hyoid, and thyroid muscles; also the digastric and stylo-hyoid, the submaxillary gland, the lower part of the parotid, the side of the jaw, and some of the muscles of the face; also, in part, the *external jugular vein.*

This vein commences in the parotid gland, descends obliquely outwards over the sterno-mastoid muscle, where it lies very superficial, and then sinks deep behind the clavicle, and joins the subclavian vein or some of its branches. The upper portion of the external jugular vein is accompanied by a large nerve, which lies to its outer side, *superficialis colli*, a branch of the cervical plexus ascending to the parotid gland and external ear. This vein in its course down the neck receives several cutaneous veins, and almost always communicates with the internal jugular; it presents great varieties in its size and course, is sometimes double, and is sometimes even wanting. Superficial veins may also in general be marked descending along the anterior part of the neck; they arise about the os hyoides and upper part of the thyroid body, and descend beneath some fibres of the platysma along the anterior edge of the mastoid muscle, and end in the internal or external jugular, or in the venæ innominatæ. The fibres of the platysma are closely connected to a layer of condensed cellular tissue, which in some subjects is very strong, and in some situations aponeurotic; this

is the *superficial cervical fascia*. In some, the fibres of the platysma are so intermingled with this structure, that they cannot be perfectly separated, and must be raised together. Some writers designate this as the *deep* cervical fascia, and apply the term *superficial* fascia to the subcutaneous cellular tissue, which connects and supports the fibres of the platysma, a title it does not appear to me to deserve, except in very few instances, and in particular situations. This fascia extends over the anterior and lateral parts of the neck, is continued down over the forepart of the thorax, where it becomes cellular and adipose, ascends to the jaw, to which it is attached, expands over the parotid gland, and adheres to the cartilage of the ear; in this situation its strength is greatly increased: towards the lateral and posterior parts of the neck it becomes weak like cellular membrane; at the edge of the trapezius, one thin lamina passes superficial to this muscle, while the other stronger portion is continued beneath it to the ligamentum nuchæ, giving off in this course processes to enclose the different muscles. From the posterior or deep surface of this fascia, a lamina of membrane is derived, which passes behind the sterno-mastoid muscle; this is the *deep cervical fascia*, whose connexions are important, and may be examined in this stage of the dissection. If the superficial lamina be divided along the median line of the sterno-mastoid muscle, this deep fascia will be seen to be continuous with, or produced from, the superficial, and to pass behind the anterior border to the posterior surface of that muscle, so that the latter, as also the omo-hyoid, and the other muscles in this region, may be considered as enclosed between these fasciæ, each in a sort of sheath; at the lower part of the neck it is strong, and adheres to the inter-clavicular ligament and posterior edge of the sternum and clavicles. Some loose fatty substance is here interposed between it and the superficial layer; as the deep fascia extends upwards, it covers and adheres to the sheath of the cervical vessels, and arriving at the space between the trapezius and mastoid muscles, it becomes, at first, weak and cellular, but inferiorly as it accompanies the great vessels beneath the clavicle it is dense, and serves to enclose the subclavian muscle, and is attached to the costo-clavicular, or coracoid ligament or membrane; superiorly it is lost on the branches of the cervical plexus of nerves; at the superior and lateral parts of the neck it sinks deep, behind the angle of the jaw, to which it adheres, and is connected to the styloid process of the temporal bone, and to the stylo-maxillary ligament, which it may be said to form; absorbent glands, the lower part of the parotid, and much cellular membrane, here lie between these two fasciæ. In this situation collections of matter often form, the result of cynanche parotidæa, or of inflammation of some of the lymphatic glands; such collections are productive of great inconvenience, causing such swelling and tension, as to interfere with the motions of the jaw, and with the act of deglutition. The cervical fasciæ bind down the muscles and support the vessels and glands in this region; at the lower part of the neck they serve to protect the trachea and the upper part of the thorax

from the pressure of the atmosphere during inspiration. In the subsequent dissection of the deep muscles of the neck, this fascia will be found continued by lateral slips from the external sides of the sheaths of the cervical muscles to form another extensive sheath, the *prevertebral fascia ;* this adheres above to the occipital bone, and the adjacent muscles; on either side, to the tips of the transverse processes, covers and binds down the longi colli, recti, and scaleni muscles, connected in front by loose reticular membrane to the pharynx and œsophagus, and inserted below into the first ribs, clavicles, and subclavian muscles; it adheres to, and forms prolongations around the brachial vessels and nerves, and separates the axillæ from the inferior triangular regions of the neck; more internally it overlaps the two pleuræ, and by its various inter-muscular and inter-vascular connexions with the superficial layers which adhere to the sternum and its ligaments, completes the cervico-thoracic septum, which, when viewed from the cavity of the thorax, appears as a vaulted partition perforated by various funnel-shaped passages for the several tubes and vessels, passing in and out of the chest, attached to each by cellular and fibrous prolongations which are lost on their individual parietes. Dissect off the platysma and superficial fascia, and examine the subjacent muscles, the second pair of the first order. In the course of this dissection are seen branches of the cervico-facial division of the seventh pair; many of these arch along the side of the neck towards the os hyoides and the chin, others descend to join the cutaneous branches of the cervical plexus, and they are all distributed to the platysma, fascia, and integuments.

STERNO-CLEIDO MASTOIDEUS, long and flat at the extremities, but somewhat round in the centre; placed at the anterior and lateral part of the neck; *arises* by a strong flat tendon with fleshy fibres posterior to it, from the upper and anterior part of the first bone of the sternum, also by short aponeurotic and fleshy fibres from the upper and anterior edge of the sternal third, sometimes half of the clavicle; a small triangular space separates these two origins, through which small vessels and some cellular membrane pass: this space corresponds to the sterno-clavicular articulation.

The sternal and longer portion of this muscle ascends obliquely backwards and outwards, and overlaps the clavicular, which ascends vertically; about the middle of the neck they are intimately joined; *inserted* by a tendon which is thick and rounded anteriorly, but thin, broad, and aponeurotic posteriorly, into the upper part of the mastoid process, and into the external third of the superior transverse ridge of the occipital bone. *Use*, the sternal portion can rotate the head so as turn the face towards the opposite side: the clavicular can bend the head and neck to its own side, so as to approximate the ear and shoulder; and if the two portions of the muscle on each side act together, they will move the head downwards and forwards, but if the muscles on the back of the neck be in action, so as to fix the vertebræ and head, then these muscles, particularly the sternal portions, may assist in still further extending the neck, and carrying the head back-

wards, so as to turn the face upwards, in consequence of their insertion being posterior to the centre of motion in the occipital condyles; this appears to be the case in tetanus: these muscles can also assist in laborious respiration, by raising and fixing the shoulders. This muscle is covered by the integuments, platysma, superficial fascia, external jugular vein, ascending branches of the cervical plexus of nerves, descending branches of the portio dura, and by a small portion of the parotid gland; it conceals part of the sternum and clavicle, of the sterno-hyoid, sterno-thyroid, omo-hyoid, and digastric muscles, also the lower part of the cervical vessels and several glands. The spinal accessory nerve perforates it obliquely a little above its centre, and near its posterior surface; this nerve is a division of the eighth pair, it distributes small branches to the mastoid and trapezius muscles, and joins freely with the cervical plexus; the spinal accessory does not always perforate, but sometimes passes posterior to the mastoid muscle; it is supposed to associate the nerves and muscles of the neck with the respiratory system.

The student may remark that the two sterno-mastoid muscles bound a large triangular space situated on the forepart of the neck, the apex at the sternum, the base at the jaw: this is divided by the mesial line into two lateral portions, which are named the anterior lateral triangles of the neck.

Between the mastoid and the trapezius muscles also, on each side, a large triangular space is enclosed, the base formed by the clavicle, the apex by the mastoid process; this space is called the posterior lateral triangle of the neck. Both these triangular regions may be observed to be subdivided into two by the omo-hyoid muscle, which crosses the neck obliquely from the shoulder to the os-hyoides. Thus on each side of the middle line four triangular spaces may be noticed, principally formed by the trapezius, sterno-mastoid, and omo-hyoid muscles; these triangles are distinguished by the terms—1. posterior inferior; 2. posterior superior; 3. anterior inferior; and 4. anterior superior. We do not at present allude to the important space bounded by the digastric muscle.

The student should examine each of these regions, and consider the parts situated in each. These spaces can be ascertained during life, and therefore an accurate knowledge of the contents of each may be of practical importance. 1. The *posterior inferior triangle* is that small space partly behind the clavicular portion of the mastoid muscle, and partly between it and the trapezius, above the clavicle and below the posterior belly of the omo-hyoid muscle; in this space we find the trunk and several branches of the subclavian artery, vein, and the brachial plexus of nerves; it is here that the operation of tying the subclavian artery, in case of axillary aneurism, is recommended to be performed. 2. The *posterior superior triangle* is above the posterior belly of the omo-hyoid, and between the mastoid and trapezius muscles; it contains the cervical plexus of nerves, several lymphatic glands, and a great quantity of cellular membrane. 3. The *anterior inferior*

*triangle* is above the sternal third of the clavicle, between the median line and anterior belly of the omo-hyoid, and rather behind the sterno-mastoid muscles; this space contains the carotid artery, jugular vein, and accompanying nerves, also the lateral lobe of the thyroid body, all of which are covered by the sterno-mastoid, hyoid, and thyroid muscles. 4. The *anterior superior triangle* is between the sterno-mastoid and anterior belly of the omo-hyoid muscles; the apex is formed by the decussation of these muscles, and is opposite the cricoid cartilage; the base is, superiorly, marked by the digastric muscle and lingual nerve; this space also contains the great vessels and nerves,

*Fig.* 4.*

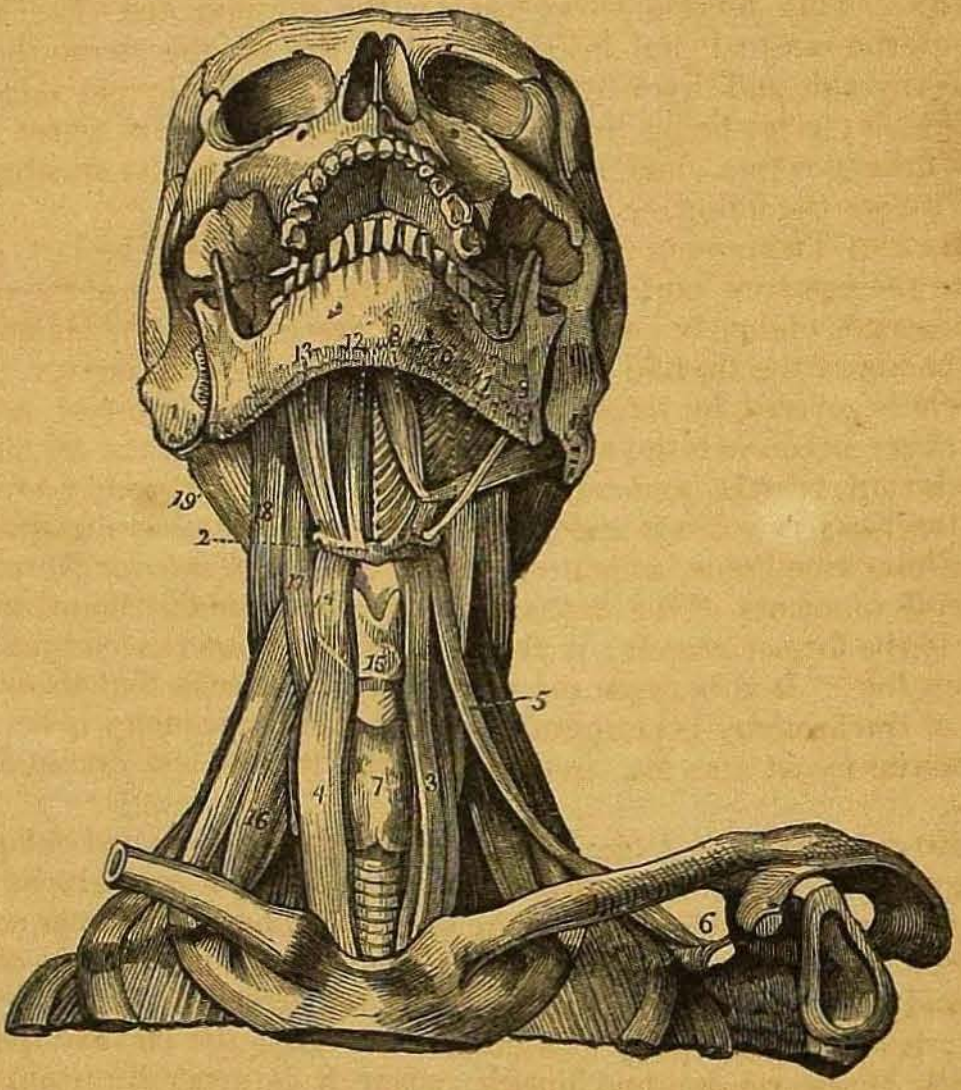


* The muscles of the neck. 1. The mastoid process of the temporal bone. 2. The os hyoides. 3. The sterno-hyoideus muscle. 4. The sterno-thyroideus. 5. The omo-hyoideus. 6. Attachment of the omo-hyoideus to the superior costa of the scapula. 7. The thyroid body. 8. The anterior belly of the digastricus. 9. Its posterior belly. 10. Its median tendon perforating the stylo-hyoid muscle, and connected to the os hyoides by a tendinous pulley. 11. The mylo-hyoideus. 12. The genio-hyoideus. 13. The hyo-glossus. 14. The thyro-hyoideus. 15. The thyroid cartilage. 16. The scalenus anticus muscle. 17. The rectus capitis anticus major. 18. The levator anguli scapulæ. 19. A portion of the splenius.

which here, however, are only superficially covered, so that in this situation the operation of tying the carotid artery can be more easily effected. Divide the sterno-mastoid muscle about its centre, and reflect each portion towards its attachment; at the lower part of the neck, behind and between the sterno-mastoid muscles, are seen the following:

STERNO-HYOIDEUS is long, flat, and thin, *arises* within the thorax from the posterior surface of the first bone of the sternum, cartilage of the first rib, sternal end of the clavicle, and sterno-clavicular capsule; ascends obliquely inwards, approximating its fellow above, and is *inserted* into the lower border of the body of the os hyoides, internal to the omo-hyoid. *Use*, to depress the os hyoides, pharynx, and larynx. This muscle is covered by the sternum and clavicle, by the sterno-mastoid and integuments; it lies on the sterno-thyroid, crico-thyroid, and thyro-hyoid muscles, and on the thyroid gland and its vessels; a tendinous line often intersects it about its centre. Cut this muscle across, and reflect each portion towards its attachments, and we see the following pair of muscles:

STERNO-THYROIDEUS is broader and shorter than the last, *arises* from the posterior surface of the sternum and cartilage of the second rib, ascends obliquely outwards, and is *inserted* into the oblique line on the ala of the thyroid cartilage. *Use*, to depress the larynx. This muscle is covered by the sterno-mastoid and hyoid muscles, and by the skin; it conceals the arteria and vena innominata, the carotid and subclavian vessels, and adjacent nerves, also the thyroid body, and the trachea; between it and the latter there is a considerable quantity of cellular membrane, which contains several veins (*inferior thyroid* v.) Several filaments of the descendens noni nerve are distributed to this and to the former muscle; it also is occasionally intersected by a tendinous line. It is between the sterno-thyroid muscles that the operation of tracheotomy is performed, while that of laryngotomy is between the sterno-hyoid muscles, and between the thyroid and cricoid cartilages.

OMO-HYOIDEUS is long, slender, and digastric, situated obliquely along the inferior, lateral, and forepart of the neck; it *arises* broad and fleshy from the superior costa of the scapula behind its semilunar notch, from the ligament covering that notch, sometimes from the base of the coracoid process, and sometimes also from the acromial end of the clavicle; it ascends obliquely forwards a little above the clavicle, passes beneath the sterno-mastoid muscle, where it is generally tendinous, except in the very young subject; becoming again fleshy, it ascends nearly vertical along the outer side of the sterno-hyoid, and is *inserted* fleshy into the lower border of the os hyoides, at the junction of its body and cornu, external and anterior to the insertion of the sterno-hyoid. *Use* (the muscle of one side cannot act independent of the other), both draw the os hyoides, pharynx, and larynx, downwards and backwards, and in deglutition serve to urge the food into the œsophagus; they also make tense the cervical fascia. The origin of

this muscle is concealed by the trapezius, it is anterior to the insertion of the levator anguli scapulæ, and between the serratus magnus and supra-spinatus muscles; the posterior belly is covered by the integuments and fascia, in some the clavicle overhangs it; it divides the great posterior lateral triangle of the neck into an inferior and superior part, as was before mentioned; this portion of the omo-hyoid can frequently be distinguished in the living neck. The tendon crosses the carotid artery and jugular vein, and is covered by the sterno-mastoid, which can thus move more easily on this structure. The anterior belly and insertion are covered by the integuments and fascia; this portion of the muscle divides the anterior lateral triangle of the neck into an inferior and superior part. The omo-hyoid is enclosed through its whole course between septa of the cervical fascia, it crosses over the scaleni muscles, the brachial plexus, phrenic, pneumo-gastric and sympathetic nerves, the carotid artery, jugular vein, and superior thyroid vessels.

Beneath the three last described muscles, and lying on the trachea and sides of the larynx, is a large, soft, red mass, of a crescentic shape, the concavity directed upwards; this is the *thyroid body;* it is in general larger and of a deeper colour in the child than in the adult or old, and in the female than in the male; its size, however, varies considerably in different individuals, even of the same sex and age. It consists of two large pyramidal portions, called *lateral lobes*, connected together by a narrow slip, *the middle lobe* or *isthmus;* the latter is thin and flat, and closely connected to the second, third, and fourth rings of the trachea; the lateral lobes are plump and convex; large below, pointed above, placed by the side of the trachea and larynx, and extending as high as the alæ of the thyroid cartilage; the left lateral lobe rests on the œsophagus, and both right and left overlap the carotid artery, inferior thyroid vessels, and recurrent nerve; they are covered by the sterno-mastoid, hyoid, thyroid, and omo-hyoid muscles, by the platysma and skin; they lie on the side of the trachea and larynx, on the crico-thyroid and inferior constrictor of the pharynx. The middle lobe is very irregular, it is sometimes deficient, in other cases it is full and broad, and might even cause embarrassment in tracheotomy; in some cases it passes behind the œsophagus, or between this tube and the trachea, a circumstance which might be productive of great inconvenience, and even danger, in the event of enlargement of this body occurring in one in whom this malformation existed. A narrow slip is often seen to ascend from the middle lobe as high as the os hyoides. A small muscular band is occasionally found to arise from its upper border, and to be inserted into the base of the os hyoides, or angle of the thyroid cartilage, named by Sœmerring "*levator glandulæ*." In the infant the lower part of the thyroid is connected to but not continuous in structure with the thymus gland. This organ has no perfect capsule, a fine cellular tissue only surrounds it; it is of a soft and spongy texture, the cells contain a yellow, serous, and sometimes an oily fluid, it appears composed of a number

of granulations united by cellular tissue into lobules, the serous fluid is contained in the connecting cellular membrane, no excretory duct has been discovered, nor does there appear to be any communication between the lobes and the lobules, except through the medium of the blood-vessels, which are of considerable size; four arteries, two from the carotid and two from the subclavian, are distributed to it, the former border its superior margin, the latter bend along its inferior and posterior portions; several veins issue from it, small superiorly, but very large and numerous below. This body has been by many considered as glandular, and named accordingly the thyroid gland, but there does not appear any evidence to support this opinion; it cannot belong to the secreting glands, unless we admit that its veins (which are certainly very large) serve the additional office of excretory ducts, neither does it appear to have any peculiar connexion with the lymphatic or absorbent system. Anatomical writers usually describe it in connexion with the larynx, but without any reason, except from its contiguity to that organ. Although it is an opinion prevalent among many physiologists, that the thyroid body is an organ for sanguification, yet it may be affirmed that its use is by no means fully ascertained.

The thyroid body is very subject to enlargement, which is sometimes partial, sometimes general; this affection is named *bronchocele* or *goitre*, and presents great varieties as to size, form, and consistence of the tumour, in some being firm and regular, in others very uneven, and soft or pulpy to the feel. Next dissect the muscles at the upper part of the neck.

DIGASTRICUS, placed at the lateral and anterior part of the neck, thick and fleshy at each extremity, round and tendinous in the centre, *arises* from a groove in the temporal bone, internal to the mastoid process, descends obliquely forwards and inwards, ends in a round tendon which perforates the stylo-hyoid muscle, and is connected to the cornu of the os hyoides by a dense fascia, sometimes by a tendinous ring like a pulley; the tendon is then reflected upwards and forwards, and soon ends in the anterior fleshy belly, which continuing forwards and inwards, is *inserted* into a rough depression on the inner side of the base of the jaw, close to the symphysis. *Use*, to depress the lower jaw, and, when the mouth is closed, to elevate the os hyoides, tongue, and larynx; the posterior belly can also draw these backwards and upwards, and the anterior upwards and forwards, so that this muscle can exert great influence in deglutition; it can also draw the head backwards if the chin be fixed. The digastric is covered posteriorly by the sterno-mastoid and splenius, and by a portion of the parotid, more anteriorly by a few fibres of the stylo-hyoideus and a small part of the submaxillary gland, by the cervical fascia, platysma, and skin; it passes across the styloid muscles, the external and internal carotid, the labial and lingual arteries, the eighth, ninth, and sympathetic nerves; also the origin of the hyo-glossus and the insertion of the mylo-hyoid.

In the position in which the subject is placed during this dissection,

this muscle forms the inferior or convex border of a semicircular space, the *digastric region*, the superior straight edge of which is marked by the side of the maxilla, and by a line continued from its angle to the mastoid process; the skin, platysma, and cervical fascia close it in superficially, and the side of the jaw overhangs it; its deep, or superior surface is formed by the mylo-hyoid and lingual muscles, and by the side of the pharynx. This region is divided by the stylo-maxillary ligament into two spaces, the posterior or parotidæan, the anterior or submaxillary.

The *parotidæan space* is the smaller, bounded behind by the mastoid process and meatus auditorius, and more deeply by the vaginal and styloid processes; it extends as high as the maxillary articulation; the stylo-maxillary ligament, ramus and angle of the jaw, and internal pterygoid muscle, bound it anteriorly and separate it from the submaxillary space; it is prolonged to some depth within the neck and ramus of the jaw between the pterygoid muscles; this space contains the parotid gland, which is firmly wedged into it around the jaw, and impacted into all its irregular recesses; also several absorbent glands, the external carotid artery and its terminal branches; the commencement of the external jugular vein, the seventh nerve and its plexus, and more deeply the origin of the three styloid muscles, the internal carotid artery, internal jugular vein, and the eighth, ninth, and sympathetic nerves.

The anterior, or *submaxillary space*, is larger, is bounded above by the mylo-hyoid muscle, and by the mucous membrane of the mouth reflected from the jaw to the tongue; the muscle like a shelf divides it into a superficial and a deeper or sublingual portion, which communicate around the outer border of that muscle. This space contains superficially the submaxillary and several lymphatic glands, the facial artery and vein, with their numerous branches, and the mylo-hyoid nerve of the fifth pair, and the submaxillary ganglion; in the deeper or sublingual portion of this space, that is, above the mylo-hyoid muscle, and between it and the mucous membrane or the floor of the mouth, are contained the gustatory and lingual nerves, and more deeply still the glosso-pharyngeal; also the Whartonian duct, the lingual artery and vein, with their tortuous branches, and the sublingual gland; these last mentioned objects cannot be seen in the present stage of the dissection.

The *submaxillary* is the second of the salivary glands, of an oval form and pale colour, surrounded by cellular membrane and several absorbent glands, covered by the skin, platysma, and fascia, bounded posteriorly by the digastric tendon, externally by the internal pterygoid muscle and stylo-maxillary ligament; anteriorly by the side of the maxilla, and internally by the anterior belly of the digastric; it rests on the mylo-hyoid, stylo-hyoid, and hyo-glossus muscles; a small process of the gland accompanies its excretory duct, turns round the posterior edge of the mylo-hyoid, and lies between the upper surface of that muscle and the membrane of the mouth; this process fre-

quently joins the sublingual gland. The facial artery and vein pass through a deep groove in this gland. The duct of this gland is called *Whartonian duct*, it *arises* by numerous fine cœcal radicles from the lobules of the gland, leaves it at its outer end, winds above the mylo-hyoid muscle, and runs forwards and inwards towards the frænum linguæ, by the side of which it *opens* into the mouth; the orifice can be distinctly seen in the mouth in a prominent papilla, which appears when the anterior part of the tongue is raised; this duct is about two inches and a half long, is thin and transparent, its coats are weaker, but its calibre is larger than in Steno's duct, the gustatory nerve accompanies it, at first superior, but afterwards inferior to it; sometimes a second or accessory duct is met with.

The submaxillary gland is subject to the same *morbid* changes as those which have been alluded to in speaking of the parotid gland. Its removal in case of scirrhus is also spoken of by authors, and this operation has been described as having been frequently performed; most probably, however, many of these recorded accounts were rather cases of tumours which have pressed this gland aside, or, causing its absorption, have thus come to occupy its place. The Whartonian duct is not unfrequently obstructed near to, or closed at its termination in the mouth, the saliva, and often calcareous matter, then distend it into the form of a tumour of variable size, which is situated beneath the tongue, and causes more or less inconvenience to the latter; this disease is termed Ranula. Detach this gland from the mylo-hyoid, turn it outwards, leaving the duct and deep process to be further examined afterwards; separate the anterior belly of the digastric from the chin and we see the following muscle:

Mylo-hyoideus, triangular, *arises* from the oblique line (the myloid ridge,) on the inner surface of the side of the maxilla, which line descends obliquely from beneath the last molar tooth towards the chin; the fibres descend obliquely inwards and backwards to the mesial line, and *are inserted* into the base of the os hyoides, and along with its fellow, into a middle tendinous line between that bone and the chin, which latter point they seldom reach. *Use*, to elevate the os hyoides and tongue, so as to press the latter against the palate. This muscle is covered by the submaxillary gland, and by the digastric; it lies on the hyo-glossus, stylo-glossus, and genio-hyoid muscles, and conceals the Whartonian duct, the lingual and gustatory nerves, and sublingual gland. This pair of muscles seem like a digastric muscle, the tendon being in the mesial line, opposite to the raphe in the pharynx; they might almost be considered as continuations of the superior constrictors of that organ, the gustatory nerve at each side intervening and marking the separation. Detach this muscle from the os hyoides and from its fellow; in the middle line we shall then see the following pair:

Genio-hyoideus, short and round, *arises* by a small tendon on the inner side of the chin, above the digastric, descends obliquely back-

wards, and is *inserted* broad and fleshy into the base of the os hyoides. *Use*, to draw the os hyoides upwards and forwards, to push the tongue against the incisor teeth, or protrude it from the mouth; this pair of muscles lie superior to the digastric and mylo-hyoid, and inferior to the genio-hyo-glossus. Reflect the genio and mylo-hyoid muscles towards the lower jaw, and the *sublingual space* within the submaxillary will be exposed; the mucous membrane of the mouth bounds this above, the side of the tongue and pharynx internally, the mylo-hyoid muscle forms its floor. In this space are lodged the sublingual gland adhering to the mucous membrane, the gustatory and lingual, or the sentient and motor nerves of the tongue, with their connecting plexus, on the surface of the hyo-glossus muscle, the chorda tympani thrown off from the gustatory to the submaxillary ganglion, the Whartonian duct rising obliquely forwards to the side of the frænum linguæ, accompanied usually by a lobe of glandular structure, a *socia*, as in the case of Steno's duct, the lingual artery emerging from under the hyo-glossus, and dividing into the sublingual and ranine, the styloid and lingual muscles, and the glosso-pharyngeal nerve winding around the stylo-pharyngeus muscle. Observe how any change of position of the head, neck, or jaw, affects this space as to dimension, aspect, and form; any such, therefore, during life, must materially influence an examination or operation in this region; if the jaw be depressed, or the neck flexed, it will become compressed, or almost obliterated within the side of the jaw; but if the mouth be closed, and the head thrown back and slightly turned to the opposite side, it will present an extended plane surface, through which the submaxillary gland can be felt and even seen. In this gland and the surrounding cellular tissue inflammation occasionally occurs with much swelling and suppuration beneath the cervical fascia; the abscess in some cases opens into the mouth; hæmorrhage is not uncommon, and it may be necessary to open the cavity through the skin. A free semicircular or crucial incision will open it into a superficial cavity, but a small vertical wound will only give the appearance of a narrow pit, or deep axilla, without exposing its contents to view.

The *sublingual* is the third and smallest of the salivary glands, oblong, placed beneath the anterior and lateral part of the tongue, covered superiorly by the mucous membrane, to which it adheres, and resting inferiorly on the mylo-hyoid, is in contact internally with the genio-hyo-glossus, and is connected externally to the deep process of the submaxillary gland, and partly resting in a depression in the lower maxilla. This gland opens by several small ducts, some of which join the Whartonian canal, others perforate the mucous membrane of the mouth, between the tongue and inferior canine and bicuspis teeth, by small openings which may be observed on a sort of crest or fold of the mucous membrane in this situation. The three salivary glands, though generally separated from each other, yet are in some cases so joined together as to resemble one irregular glandular mass, the parotid being united to the submaxillary behind the angle of the

jaw, and the latter being connected to the sublingual around the mylo-hyoid muscle.

*Fig. 5.**

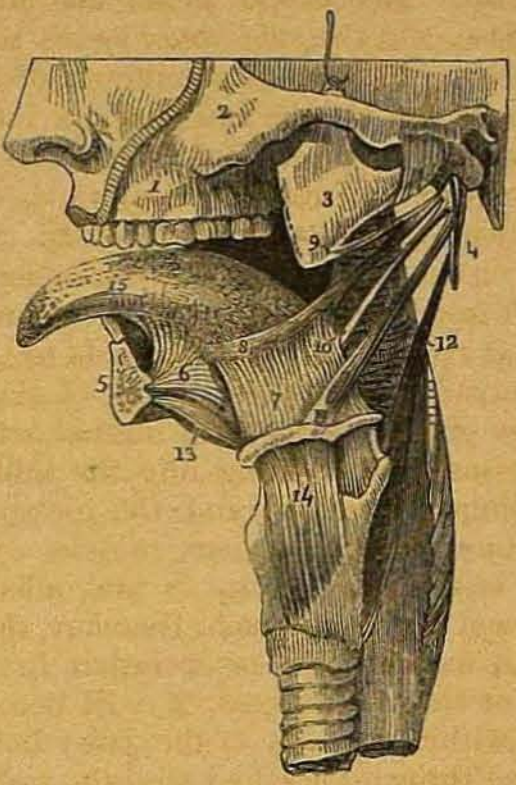


HYO-GLOSSUS is flat and thin, *arises* from the cornu and part of the body of the os hyoides, ascends a little outwards, *inserted* into the side of the tongue. *Use*, to render the dorsum of the tongue convex by depressing its side; it may also elevate the os hyoides and base of the tongue. This muscle is covered by the mylo-hyoid, by the duct and deep lobe of the submaxillary gland, also by the sublingual gland and lingual nerve, and a plexus between this and the gustatory nerve; it lies on the middle constrictor of the pharynx, the lingual artery, and the substance of the tongue.

GENIO-HYO-GLOSSUS is triangular or fan-shaped, *arises* by a small tendon from an eminence inside the chin, beneath the frænum linguæ; thence the fibres radiate, the superior ascend, and turn forwards towards the tip of the tongue; the middle also ascend, some inclining forwards, others backwards; the inferior and posterior pass backwards and downwards to the base of the os hyoides; *inserted* into the mesial line of

* The styloid muscles and muscles of the tongue. 1. The superior maxillary bone. 2. The malar bone. 3. A portion of the ramus of the inferior maxillary bone drawn upwards in order to shew the origin of the styloid muscles. 4. The styloid process of the temporal bone. 5. The inferior maxillary bone divided at the symphysis. 6. The genio-hyo-glossus muscle. 7. The hyo-glossus. 8. The stylo-glossus. 9. The stylo-maxillary ligament. 10. The stylo-hyoid ligament. 11. The stylo-hyoideus muscle. 12. The stylo-pharyngeus muscle. 13. The genio-hyoideus muscle. 14. The thyro-hyoideus muscle. 15. The tongue.

the tongue from the apex to the base, and into the body or lesser cornu of the os hyoides. *Use*, the posterior fibres can draw the os hyoides towards the chin, and thus protrude the tongue from the mouth, and bend its tip down towards the frænum; the middle portion can depress the middle of the tongue and make it concave from side to side; it can also draw it forwards so as to enlarge the opening of the fauces. This muscle is therefore used in mastication and deglutition, also in the articulation of several letters. The several muscles last described cover this muscle externally, internally it is in contact with its fellow.

LINGUALIS is a fasciculus of fibres taking a longitudinal course on the inferior surface of the tongue from the base to the apex, and intermixing with the muscles on either side, so that it appears as being derived from these rather than a distinct muscle; the fibres are attached through their whole length, and are mixed with a soft, fatty substance, with but little cellular tissue; anteriorly they are broader and more distinct; they are situated between the genio-hyo-glossus internally, and the hyo and stylo-glossus externally. *Use*, to shorten the tongue and bend the tip downwards and to one side. External to the muscles now described, we see the three styloid muscles.

STYLO-HYOIDEUS *arises* from the outer side of the styloid process near its base, descends obliquely forwards parallel to the posterior belly of the digastric, whose tendon generally perforates this muscle; *inserted* into the cornu and body of the os hyoides and into the fascia, which connects the digastric tendon to this bone. *Use*, to cooperate with the posterior part of the digastric, in raising and drawing back the os hyoides and tongue. This muscle is nearly superficial, but at first is covered by the parotid; the digastric lies to its external side and the external carotid artery to its internal; this vessel is posterior to the lower part of the muscle, but anterior to its origin; a ligament often accompanies the stylo-hyoid muscle, from the styloid process to the cornu of the os hyoides; it is named the stylo-hyoid ligament, and is sometimes ossified. Raise the digastric and stylo-hyoid, and we see the remaining styloid muscles.

STYLO-GLOSSUS *arises* tendinous and narrow from the inner side of the styloid process near its point, and from the stylo-maxillary ligament; descends obliquely forwards and inwards, and is *inserted* into the side of the tongue; its fibres overlap and unite with those of the hyo-glossus, and can be traced as far as the tip. *Use*, to draw the tongue backwards, and to one side, and to raise the tip behind the upper incisor teeth. It is covered by the sub-maxillary and lingual glands, by the gustatory nerve and mucous membrane.

STYLO-PHARYNGEUS, long and narrow, *arises* from the back part of the root of the styloid process, descends inwards and very little forwards, passes between the superior and middle constrictors of the pharynx, with which it mixes; is *inserted* with these into the side of the pharynx, also into the cornu of the os hyoides and thyroid cartilage. *Use*, to elevate and dilate the pharynx, so as to receive the

food from the tongue. It is covered by the stylo-hyoid, middle constrictor, and external carotid, and it lies on the superior constrictor, internal carotid, sympathetic, and par vagum; the glosso-pharyngeal nerve winds round it.

# SECTION II.

## DISSECTION OF THE VESSELS AND NERVES OF THE NECK.

The arteries which are met with in dissecting the neck, are the carotid and subclavian of each side, and their several branches; the veins are the external and internal jugular and subclavian, with numerous branches; the nerves are the gustatory branches of the fifth, the eighth, and the ninth pair, the sympathetic, and the anterior branches of the eight cervical and first dorsal spinal nerves. The *right carotid artery* arises from the arteria innominata, behind the right sterno-clavicular articulation; the *left carotid* arises from the upper part of the arch of the aorta; in other respects these arteries are nearly similar; both ascend by the side of the trachea and larynx, surrounded by a sheath of cellular membrane, on the forepart of which are seen the branches of the descendens noni nerve; behind the sheath lies the sympathetic, and within it are the jugular vein, lying to the outside of the artery, and the par vagum nerve, between, and rather behind both these vessels; opposite the os hyoides, each carotid divides into two branches, viz., the internal and external; the *internal carotid artery* is the larger branch, lies deeper in the neck, and more external; it ascends tortuously along the forepart of the transverse processes of the vertebræ to the base of the cranium, enters this cavity, through the foramen caroticum in the temporal bone, and is distributed to the brain. The *external carotid artery* ascends towards the parotid gland, being crossed by the digastric and stylo-hyoid muscles, and by the lingual and portio dura nerves; in this course it gives off several branches, viz., the superior thyroid, lingual, labial or facial, auricular, occipital, pharyngeal, transverse facial, internal maxillary, and temporal.

The *subclavian arteries* are situated at the inferior and lateral part of the neck; the *right* arises from the arteria innominata, the *left* from the posterior part of the arch of the aorta; each subclavian artery passes upwards and outwards to the anterior scalenus, behind which it passes; it then turns downwards and outwards behind the clavicle, and over the first rib, into the axilla; the difference in the origin causes an important difference in the situations and connexions of the right and left subclavian in the early part of their course; the right, being shorter and nearly transverse, lies higher in the neck, and more superficial than the left, which arises deep in the thorax, out of which it ascends perpendicularly before it turns outwards to pass between the

scaleni; after this point, these vessels are similar in every respect, and give off the following branches, viz., arteria vertebralis, mammaria interna, axis thyroidea, cervicalis profunda, and inter-costalis superior.

The external jugular vein has been already noticed; the *internal jugular vein* of each side commences at the termination of the lateral sinus in the foramen lacerum posterius, descends along the outer side, first, of the internal, and afterwards of the common carotid artery, and at the inferior part of the neck joins the *subclavian vein*, which returns the blood from the upper extremity, and accompanies the subclavian artery, but separated from it by the anterior scalenus muscle; the junction of each jugular and subclavian, which is posterior to the sternal end of each clavicle, forms the right and left venæ innominatæ; these veins enter the chest, and uniting, commence the superior vena cava, as will be seen in the dissection of the thorax. (For the particular description of the vessels of the neck, *see Vascular System*).

The *gustatory nerve* is the principal branch of the inferior maxillary or third division of the fifth pair; it is seen, on dividing the mylohyoid, taking an arched course below the sublingual gland, parallel to the lingualis, and stylo-glossus muscles, from within the angle of the jaw towards the tip and side of the tongue; it accompanies the Whartonian duct, at first above, afterwards beneath it, and then rises above the sublingual gland, between it and the tongue; it gives branches to the submaxillary and sublingual glands, and terminates in fine filaments, which are lost in the papillæ beneath the mucous membrane covering the sides and tip of the tongue. The chorda tympani joins it near the condyle, and parts from it opposite the angle of the lower maxilla; this delicate nerve then swells into a small ganglion, whose branches pass into the submaxillary gland. The *eighth pair of nerves* leave the cranium by the foramen lacerum posterius, anterior to the jugular vein; it immediately separates into its three portions, the internal or glosso-pharyngeal, the external or spinal accessory, and the middle or par vagum. The *glosso-pharyngeal* is connected to the stylo-pharyngeus muscle, its name denotes its destination; the arch which it forms, as it runs to the base of the tongue, is inferior to and deeper in the neck than the gustatory nerve. The *spinal accessory nerve* separates from the par vagum, and in general winds round behind the internal jugular vein, perforates the sterno-mastoid muscle, as was before mentioned, and distributes its branches to it and to the trapezius; several of these also communicate with the cervical plexus, and descend towards the acromion. The *par vagum* or *pneumogastric* descends along the neck, between, and rather behind the carotid artery and jugular vein, and enclosed in their sheath; it then passes through the thorax, and terminates on the stomach. The cervical portion only of this nerve is to be observed at present; from it arise several branches, viz., communicating branches to join the sympathetic and lingual; pharyngeal branches to the side of the pharynx; superior laryngeal nerve, which takes an arched course behind the great vessels to the

thyroid cartilage, and is distributed to the upper part of the larynx; and small cardiac branches, which join similarly named branches of the sympathetic nerve. At the inferior part of the neck, on each side of the trachea, a large nerve, the *inferior laryngeal* or *recurrent nerve*, is seen; this is also a branch of the par vagum. On the *right* side, this nerve *arises* at the lower part of the neck, turns round the subclavian artery, and passing behind it and the carotid, pursues its course upwards and inwards, behind the thyroid body, to the lower and back part of the larynx; on the *left* side the recurrent nerve *arises* in the thorax, opposite to the lower part of the arch of aorta, under which it passes, and then attaching itself to the forepart of the œsophagus, ascends to the larynx, to the muscles of which it is distributed like that of the opposite side. At the inferior part of the neck, the eighth pair of nerves enter the thorax; that of the right side passes anterior to the subclavian artery, crossing it at a right angle; that of the left side descends anterior but parallel to the left subclavian artery. The *ninth pair*, or *lingual nerve*, leaves the cranium by the anterior condyloid hole in the occipital bone, descends forwards and inwards, nearly parallel to the digastric muscle, and is distributed to the muscles of the tongue; the arch which the course of this nerve describes is parallel, but inferior to that of the gustatory. From the convexity of this arch a long branch arises, the *descendens noni;* this descends along the forepart of the sheath of the carotid artery, communicates with the second and third cervical nerves about the middle of the neck, and is distributed to the omo and sterno-hyoid and thyroid muscles: in some cases this nerve descends within the sheath and behind the vein. The *sympathetic nerve* may be found descending along the vertebræ posterior to the carotid artery: this nerve commences at the base of the cranium, in a long, oval, red swelling, the *superior cervical ganglion*, which extends as low as the third cervical vertebra; from this the nerve, becoming very small, descends almost vertically, and in general opposite the fifth cervical vertebra it forms a second swelling, called the *middle cervical ganglion;* from this the small nervous chord continues its course down the neck, behind the sheath of the vessels, and opposite the seventh cervical vertebra, and the neck of the first rib, it expands into a large irregular swelling, the *inferior cervical ganglion*, from the lower part of which the nerve descends into the thorax. On the side of the neck are seen numerous branches of the cervical spinal nerves: there are *eight pair of cervical nerves;* the first, or suboccipital, is very small; the eighth is very large; the first leaves the spinal canal between the occipital bone and the atlas; and the eighth between the last cervical and first dorsal vertebra: these cervical nerves all divide into a posterior and anterior branch, the former are distributed to the muscles and integuments on the back of the neck; the anterior branches of the first, second, third, and fourth, communicate with each other, and give origin to several branches, which again unite with each other, and constitute *the cervical plexus;* this plexus is between the mastoid and trapezius muscles; it sends off several branches, which

are entangled with much cellular membrane, and several absorbent glands: the anterior branches of the four inferior cervical nerves, with that of the first dorsal, unite and form the *brachial plexus ;* this is situated at the lateral and inferior part of the neck, and accompanies the subclavian artery beneath the clavicle into the axilla, in which region the plexus divides into several branches to supply the upper extremity and the muscles on the parietes of the thorax. In the inferior and lateral parts of the neck, on each side, the *phrenic nerve* is also seen; this arises by several fine filaments, from the third, fourth, and fifth cervical nerves; the phrenic nerve descends obliquely inwards along the anterior scalenus muscle, enters the thorax between the subclavian vein and artery, and is distributed to the diaphragm. (For the particular description of the branches of the sympathetic, as well as of the cerebral nerves, met with in the dissection of the neck, *see the Anatomy of the Nervous System*). Previous to examining the deep muscles of the neck, the student should study the anatomy of the mouth, pharynx, and larynx.

## SECTION III.

### DISSECTION OF THE MOUTH, PHARYNX, AND LARYNX.

THE cavity of the mouth may be exposed by dividing the commissure of the lips, and the cheek of one side, and removing a small portion of one side of the lower jaw; draw forwards and fix the tongue with a tenaculum, and cleanse the parts very well. The *mouth* is bounded anteriorly by the lips, superiorly by the hard and soft palate, laterally by the cheeks, inferiorly by the tongue, and mucous membrane reflected from it to the gums; posteriorly it communicates with the pharynx; this opening is named the *isthmus faucium*, is bounded above by the velum and uvula, below by the tongue, on each side by the arches of the palate.

*Fig.* 6.*

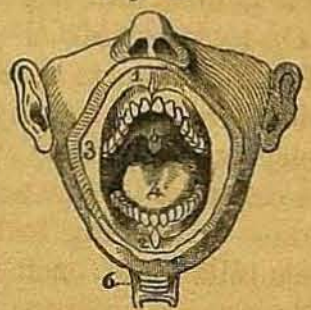


The anterior part of the palate, or *hard palate*, is formed of the palate plates of the maxillary and palate bones, covered by mucous membrane and glands; the posterior part of the palate, or *soft palate*, or *velum pendulum*, consists of a dense aponeurosis, and of several muscles and glands, enclosed in mucous membrane.

The *cheeks* are formed of mucous membrane, covered by the buccinator and a quantity of fat; several small mucous glands lie between

* The cavity of the mouth. 1. The upper lip. 2. The lower lip. 3. The internal surface of the cheeks. 4. The tongue. 5. The velum pendulum palati, and uvula. 6. The œsophagus.

the membrane and this muscle, and towards the upper and back part on each side we perceive the small opening of Steno's duct.

The lips are composed of integuments with more or less of fat, muscles, vessels, nerves, glands, and mucous membrane. The skin is delicate, and vascular, particularly at the red borders, where it is continuous with the mucous membrane of the mouth. The cuticle is continued over the latter to line the whole cavity as a very fine epithelium. The muscles are the orbicularis oris, with which the fibres of many others (already described) intermingle. The arteries of the lips are the coronary vessels, assisted by their inosculations with branches of the internal maxillary artery. The sentient nerves are derived from the infra-orbital and dental branches of the fifth, and the motor from the seventh pair. The labial glands are very numerous, they are rounded and pale, and are situated in the submucous loose cellular tissue, at some distance from the red border. The mucous membrane is continued from each lip to the alveolar processes of the maxillæ, and forms in the centre of each a small fold or frænum; this is larger in the upper than in the lower lip.

The mouth is lined throughout by mucous membrane, which is continuous with the cutis on the lips, and extends posteriorly through the pharynx, whence it ascends to line the nares, the Eustachian tube, and tympanum on each side, and descends to line the œsophagus and larynx; it is also continued into the ducts of the sublingual, submaxillary, and parotid glands; as it is reflected from one surface to another, it forms folds or fræna, as between the lips and alveoli, and beneath the tongue; at the sides of the fauces, also, it forms two semilunar folds on each side, called the pillars or arches of the palate; these folds enclose muscular fibres, which we shall examine afterwards.

On looking into the mouth, either in the living or dead subject, the following objects strike the attention; inferiorly the tongue and inferior teeth; laterally the cheek; posteriorly the back part of the pharynx; superiorly, the superior teeth, the hard and soft palate, from the centre of the latter, the uvula, and from the sides, the pillars or arches descending to the tongue and pharynx; in the recess between these pillars on each side, the tonsil or amygdala is also seen; lastly, if the tongue be drawn forward, the epiglottis comes into view.

The *tongue*, though somewhat triangular, is of a very variable shape; its base, thick and broad, is connected to the epiglottis, and to the palate by folds of mucous membrane, the former are the fræna of the epiglottis, the latter are the arches of the palate, and to the os hyoides and inferior maxilla by muscles, to the latter also by a mucous fold, the frænum linguæ; the apex is thin and unattached; that portion between it and the base is named the body of the tongue; all the upper surface, the sides, and about one-third of its inferior surface, are covered by mucous membrane, which is very rough superiorly, from the number of papillæ that project through it; anteriorly, these papillæ are small, conical, and connected with the terminations of the nerves of taste; posteriorly, they are large, round, fungiform, lenticular,

and very irregular; these are small glands which open on the mucous surface; near the epiglottis these glandular papillæ are often observed to have a peculiar arrangement, like the letter v, the concavity turned forwards; these are of a conical form, the apex attached in a little membraneous cup or calyx; behind the apex of this angle, a deep depression (foramen cœcum) is observable; this contains some mucous follicles; a superficial groove or raphe runs along the dorsum of the tongue, one more distinct exists along the inferior surface, and a cellulo-ligamentous line divides it mesially into two symmetrical portions, this line is more distinct near the base; in some animals it is very dense and even bony; in paralysis one side only of this organ is frequently found affected.† The substance of the tongue is composed of adeps blended with numerous muscular fibres derived from the stylo, hyo, genio-hyo-glossi, and lingualis muscles, and of many other fleshy fibres which do not properly belong to any of these; two large arteries (lingual), and six considerable nerves (the gustatory, the lingual, and the glosso-pharyngeal, on each side), supply this organ. The tongue is not only the organ of taste, but by its great mobility it assists in speech, in suction, and in deglutition. The fifth pair of nerves endow the tongue with sensation and with the sense of taste, the ninth with mobility, and the eighth supply its base with sensation, and connect the motions of this organ with those of the pharynx and stomach. (*See Nervous System*).

*Fig. 7.**

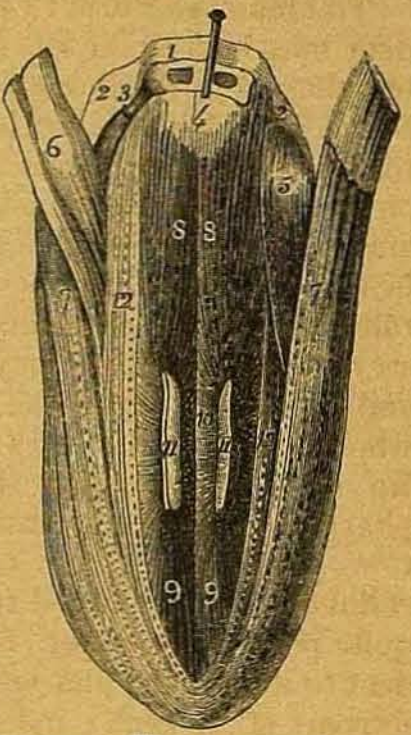


The tongue is subject to many *morbid* changes, viz., inflammation, acute or chronic, causing a great and dangerous, and sometimes fatal enlargement; tumours of different kinds may occur in it, also ulceration, cancerous, syphilitic, apthous, &c.; portions of this organ can be removed with safety, either by ligature or excision.

* The muscles of the inferior region of the tongue. (Gerdy). 1. The body of the os hyoides reversed by the position of the tongue upon a horizontal plane. 2. 2. Its greater cornua turned forwards instead of backwards. 3. Its appendix or lesser cornu. 4. The hyoidean aponeurosis of the genio-hyo-glossus. 5. The right hyo-glossus muscle. 6. The left hyo-glossus detached from the os hyoides and turned aside. 7. 7. Longitudinal portions of the stylo-glossus muscles. 8. 8. Posterior and inferior fibres of the genio-hyo-glossi. 9. 9. Their anterior fibres. 10. Their middle fibres. 11. 11. Section of the inferior angle of each of the genio-hyo-glossi. 12. 12. The lingualis profundus.

† In hemiplegia, when the muscles of one side of the face are paralysed, it has been remarked that, if the tongue be protruded, the apex will be directed towards the affected side; this phenomenon, which is only an apparent exception, depends on the action of the genio-hyo-glossus muscle of the healthy side, which will pull the base of the tongue, on that side, towards the chin, and must therefore turn the point to the opposite side; but if when protruded the point be moved towards the sound side, it cannot again be pointed to the paralysed side.

# SECTION IV.

## DISSECTION OF THE PHARYNX.

To obtain a view of the muscles of the pharynx and palate, the student may now make the following dissection: divide the trachea and œsophagus in the lower part of the neck; detach them from the vertebræ, to which they are loosely connected; draw forward these organs, together with the vessels and nerves on either side; place the saw flat on the bodies of the vertebræ; insinuate its edge between the styloid and mastoid processes on each side, and make a vertical section of the head; we have thus the face and anterior part of the cranium separated from the vertebral column; or, should it be desirable to preserve the cranium, we may separate the occipital bone from the atlas, and then remove from the subject the whole head, together with the organs we wish to examine; distend the pharynx with cotton, curled hair, or tow, and remove some of the loose cellular tissue connected to it. It is quite possible, however, for the student to dissect the pharynx from the forepart of the neck; indeed it is desirable that he should examine this organ in both these aspects.

*Fig.* 8.*

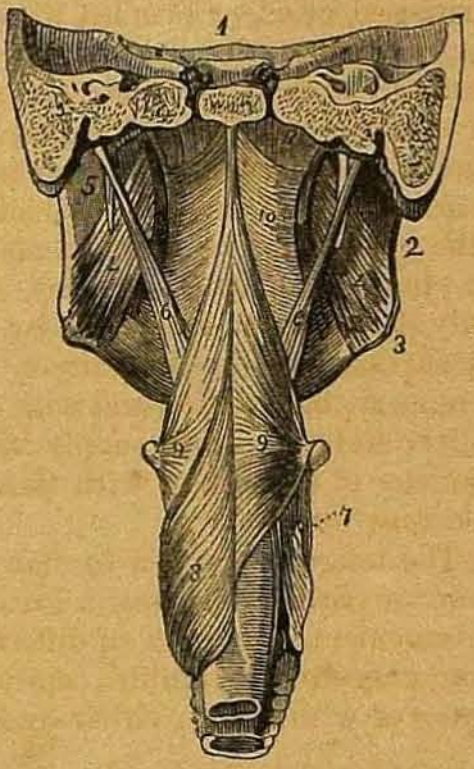


The *pharynx* is a large, muscular, and membranous bag, extending from the base of the cranium to the fourth or fifth cervical vertebra, where it contracts and ends in the œsophagus behind the cricoid cartilage; it is placed behind, and communicates with the nose, mouth, and larynx; is somewhat of an oval form, the largest part being opposite the os hyoides, and the smaller extremity joining the œsophagus. The pharynx is attached superiorly and posteriorly to the cuneiform process, by an aponeurosis, which is very strong in

* A posterior view of the muscles of the pharynx. 1. A vertical section carried transversely through the base of the skull. 2. The posterior border of the ramus. 3. The angle of the inferior maxilla. 4. The internal pterygoid muscle. 5. The styloid process of the temporal bone, giving attachment to, 6. the stylo-pharyngeus muscle. 7. The inferior extremity of the stylo-pharyngeus muscle, attached to the superior cornu and posterior border of the thyroid cartilage. 8. The inferior constrictor of the pharynx. 9. The middle constrictor of the pharynx, partly covered on the left side by the inferior constrictor. 10. The superior constrictor of the pharynx. 11. The external surface of mucous membrane of pharynx, uncovered by muscular fibres.

the middle line, laterally by a thinner aponeurosis to the petrous bone, and anteriorly, by fleshy fibres, to the internal pterygoid plate and hamular process, to the posterior part of the mylo-hyoid ridge of the lower maxilla, and to the sides of the tongue. The pharynx is connected posteriorly to the vertebræ, and to the deep muscles of the neck, by loose reticular membrane; anteriorly, by mucous membrane and muscular fibres, to the cornua of the os hyoides and thyroid cartilage, and to the sides of the cricoid, behind which it abruptly contracts and ends in the œsophagus; on either side of it are the styloid process with its muscles, and the sheath of the carotid artery with its accompanying nerves.

The pharynx is composed of muscular fibres, placed in successive strata, of mucous membrane, and of an intervening aponeurosis, which superiorly forms, as it were, its framework for the attachment and support of the investing muscles, and the lining membrane. The *pharyngeal aponeurosis* is stronger mesially than laterally, is attached above and behind to the cuneiform process, and to the Eustachian tubes, descends mesially as a raphe or linea alba, and for about an inch and a half retains considerable strength, receiving the insertions of the constrictor muscles; laterally it is attached to each petrous bone internal to the carotid foramen and to the superior cervical ganglion by a strong band, which is continuous with the middle portion, and descending expands into different processes, of which some continue between the muscular and mucous walls of the pharynx, as low down as the os hyoides; others pass external to the superior constrictor, and are inserted, some into the pterygoid fossa, between the tensor palati and internal pterygoid muscles; others, encircling the tonsil, reach the posterior part of the inferior alveolar arch and the buccinator muscle.

The mucous membrane is continuous with that lining the mouth, nares, and Eustachian tubes, and is continued inferiorly as a lining to the larynx and trachea in front, and the œsophagus behind; it is soft, vascular, highly organized, very sensible, studded with numerous mucous glands, and covered with a fine epithelium.

The muscular fibres which cover the back and sides of the pharynx, are named constrictor muscles; they are symmetrical, and are three in number on each side, they are named the superior, middle, and inferior; they overlap each other, the inferior being most superficial, the middle next, and the superior the deepest; the constrictor muscles of opposite sides have one common insertion into the *middle tendinous line*, or raphe on the back part of the pharynx, which line is very strong and distinct superiorly, being *inserted* into the cuneiform process, but inferiorly is weak and often indistinct.

Constrictor Pharyngis Inferior is of an irregular form, the anterior and inferior borders being shorter than the superior and posterior; *arises* by two heads, one from the side of the cricoid cartilage (crico-pharyngeus of some), the other from the inferior cornu and posterior part of the ala of the thyroid carilage, external to the crico-thyroid and thyro-hyoid (thyro-pharyngeus of some); the superior

*Fig.* 9.*

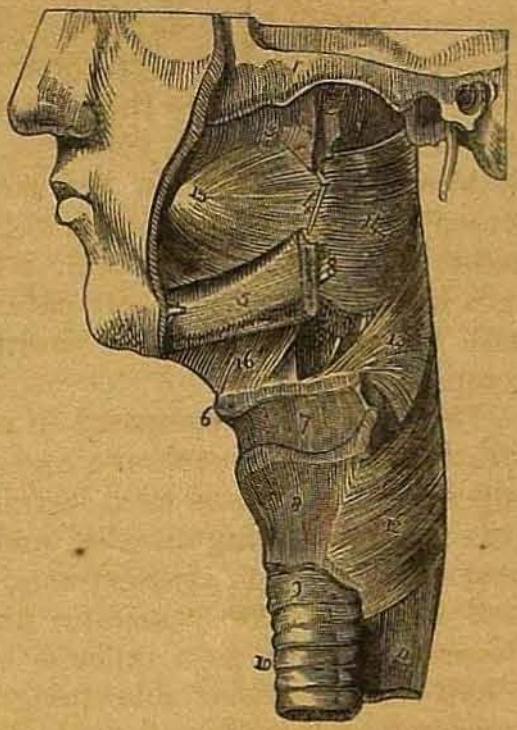

fibres ascend obliquely, and overlap the middle constrictor; the inferior fibres, a few of which often arise from the trachea, run circularly and overlap the œsophagus; *inserted*, along with that of the opposite side, into the middle line or raphe on the back of the pharynx; its origin is covered by the sterno-thyroid muscle, and the thyroid gland; it lies on the mucous membrane, except its superior fibres, which are separated from it by the middle constrictor. The inferior laryngeal or recurrent nerves pass beneath its lower edge, and the superior laryngeal above its upper; the inferior head or origin is between the crico-thyroid and crico-arytenoideus posticus muscles; and the superior between and behind the attachments of the sterno-thyroid and thyro-hyoid.

Constrictor Pharyngis Medius, or Hyo-pharyngeus (improperly called constrictor), is of a triangular form, *arises* from the cornu and appendix of the os hyoides, also from the stylo-hyoid and posterior thyro-hyoid ligaments; its fibres expand on the back of the pharynx, the superior ascend to the occipital bone, the middle run transversely, and the inferior descend beneath the lower constrictor, *inserted* into the mesial tendinous line or raphe, and into the cuneiform process. The lingual artery and hyo-glossus muscle are connected to its origin, which is separated from the inferior constrictor by the superior laryngeal nerve and cornu of the thyroid cartilage, and from the superior constrictor by the stylo-pharyngeus muscle and glosso-pharyngeal nerve; on dividing the edge of this muscle, the Stylo-pharyngeus appears; it *arises* from the root of the styloid process, descends to the side of the pharynx, where it expands between the superior and middle constrictors, and is *inserted* beneath the latter, partly into the submucous tissue, and partly into the cornu of the thyroid cartilage. *Use*, to elevate, dilate, and shorten the pharynx, and draw it slightly backwards, in order to receive the food from the tongue; it will also raise the larynx. Divide the stylo-pharyngeus, and the superior constrictor will be exposed.

* A lateral view of the muscles of the pharynx. 1. The zygomatic arch. 2. The external pterygoid plate. 3. The hamular process of the internal pterygoid plate. 4. The intermaxillary, or pterygo-maxillary ligament. 5. A portion of the inferior maxillary bone. 6. The os hyoides. 7. The thyro-hyoid membrane or ligament. 8. The thyroid cartilage. 9. The cricoid cartilage. 10. The trachea. 11. The œsophagus. 12. The inferior constrictor of the pharynx. 13. The middle constrictor. 14. The superior constrictor. 15. The buccinator muscle. 16. The mylo-hyoid muscle.

CONSTRICTOR PHARYNGIS SUPERIOR, surrounds the superior part of the pharynx; *arises* by a dense aponeurosis from the petrous bone (which is, in fact, the lateral or bucco-pharyngeal portion of the pharyngeal aponeurosis); this soon becomes connected with the next origin, which is fleshy, from the lower part of the internal pterygoid plate and hamular process, also from the pterygo or intermaxillary ligament (see page 11), which connects it to the buccinator muscle, from the posterior third of the mylo-hyoid ridge, and from the side of the base of the tongue, between the stylo and hyo-glossus muscles; all the fibres take a semicircular course backwards and inwards, and are *inserted* into the cuneiform process and into the middle tendinous line on the back of the pharynx. The superior constrictor is covered by the styloid muscles and by the great vessels and nerves, and inferiorly by the middle constrictor, from which the stylo-pharyngeus and glosso-pharyngeal nerve separate it; between the lateral attachments to the petrous bones and the mesial one to the occipital, the mucous membrane and fascia are uncovered by muscular fibres in a small semicircular space, named *sinus of Morgagni;* this is beneath the cuneiform process, on each side of the middle line, and internal to the Eustachian tube; between the temporal and pterygoid attachments, the levator palati muscle is seen, and between the pterygoid and maxillary origins the internal pterygoid muscle and the gustatory nerve are situated. *Use*, the constrictors, particularly the upper and lower, diminish the capacity of the pharynx; the inferior can also elevate the os hyoides and tongue, and shorten the pharynx; by the successive contractions of each, the food is forced into the œsophagus; the complex muscular structure of the pharynx may also assist in the modulation of the voice and in the production of certain sounds.

*Fig.* 10.*

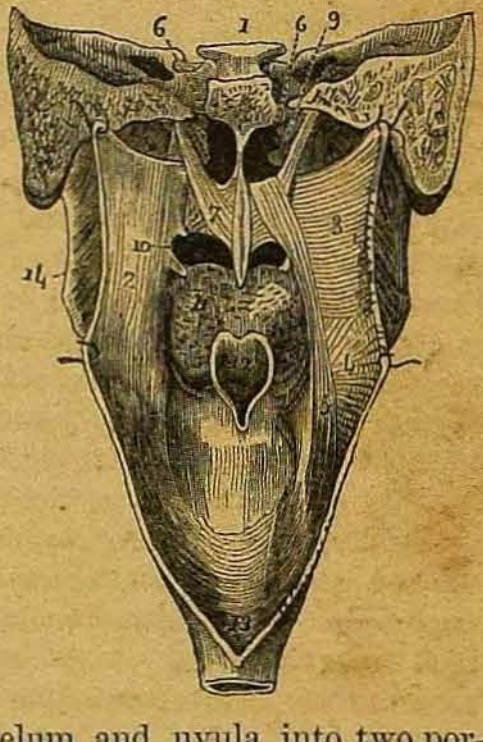


Open the pharynx by a perpendicular incision through the middle tendinous line; on looking into the cavity it will be found divided by the velum and uvula into two por-

* The pharynx, laid open from behind. 1. A vertical section carried transversely through the base of the skull. 2. 2. The walls of the pharynx drawn to each side; on the right side the mucous membrane has been removed, in order to shew the internal surface of 3. The superior constrictor, and 4. The middle constrictor. 5. The palato-pharyngeus muscle. 6. 6. The posterior nares, separated by the vomer. 7. The levator palati. 8. The vertical portion of the circumflexus palati. 9. The extremity of the Eustachian tube of the right side. 10. The isthmus faucium. 11. The base of the tongue. 12. The epiglottis, and beneath it the superior opening of the larynx. The commencement of the œsophagus. 14. A portion of the internal pterygoid muscle.

tions, a superior and inferior: *seven openings* also may be remarked leading from it in different directions, viz., in the upper or nasal portion there are the two posterior nares, and on the side of each of these is the opening of the Eustachian tube; below the velum is the isthmus faucium or posterior opening of the mouth; below and behind the tongue is the opening of the glottis; and lastly, the termination of the pharynx in the œsophagus.

The *openings of the nares* are of an oval shape, their long diameter being vertical; the body of the sphenoid bone bounds them superiorly, the palate bones inferiorly, the internal pterygoid plates externally, and the vomer, with a fibrous prolongation from its periosteum, separates them from each other; all these bones are covered by the mucous membrane; through these, which are permanently open, the air generally passes during respiration.

The *Eustachian tubes* open on each side of the posterior nares, behind the inferior spongy bone; they are circular, and look downwards, forwards, and inwards towards the septum narium, are formed, in two-thirds of their circumference, of thick cartilage, covered by mucous membrane; through these, air is admitted from the nose and pharynx into the tympanum, to support the membrana tympani on its inner side. The Eustachian tube must be again examined in the dissection of the organ of hearing.*

Beneath the velum is the *isthmus faucium*, transversely oval, but capable of great change in figure and size, bounded above by the velum and uvula, below by the tongue, and on either side by the *pillars or arches* of the palate, and by the amygdalæ.

The opening of the *glottis*, or *superior* opening of the larynx, is at the lower and anterior part of the pharynx, behind the epiglottis, and rather beneath the tongue; it is of a triangular form, the base anteriorly formed by the epiglottis; the sides are composed of folds of mucous membrane, termed aryteno-epiglottidean, and the apex, which is posteriorly and a little notched, is formed by the appendices of the arytenoid cartilages; the sides are somewhat thickened and strengthened by two small fibro-cartilages enclosed between the mucous folds (cuneiform cartilages or bodies). The glottis, which will again be considered in speaking of the larynx, is always open, except in the act of deglutition. The *œsophageal opening* is below and behind the glottis; it is always closed, except in deglutition. The student should next examine the velum pendulum palati, or palatum molle.

* The student may practise the introduction of a probe into this tube; slightly curve a blunt probe, pass it along the floor of the nose to the posterior nares, then direct its extremity upwards, outwards, and backwards, that is, towards the ear, and it will enter this tube.

## SECTION V.

### DISSECTION OF THE PALATE AND ITS MUSCLES.

THE *velum pendulum palati*, or *palatum molle*, is a soft, moveable partition, or valve, extending in a gentle curve the surface of the arched roof of the mouth, and the inclined plane of the nares, and separating the mouth and fauces from the nasal or superior region of the pharynx; quadrilateral, its anterior and superior border, which is thick and strong, is firmly attached to the posterior part of the hard palate; its posterior inferior margin is thin and concave, bounding the isthmus faucium; from its centre a conical appendix (uvula) descends, and thus divides this margin into two slightly lunated portions, named by some the *half arches* of the *palate*. Its lateral limits are marked by a prominent ridge leading from the posterior part of the superior alveolar arch to that of the inferior one; this ridge nearly corresponds to the anterior border of the internal pterygoid muscle, and contains a number of small mucous glands; these are often collected into a distinct, round cluster behind the last inferior molar tooth. The velum, when at rest, is placed obliquely; near the hard palate it is horizontal, but towards its free margin it is curved downwards, so that the inferior or oral surface is concave, the superior convex; on the former a dense, pale line continued from the raphe on the hard palate marks it mesially and divides it into two symmetrical portions; this surface looks downwards and forwards towards the tongue; the opposite surface, also marked by a mesial raphe, but more prominent on either side, looks upwards and backwards; during life these aspects are constantly being changed by the action of the muscles, which can depress, elevate, and make tense the velum. The *uvula* is a conical prolongation of the mucous membrane of the velum, a sort of *cul de sac*, containing some muscular fibres superiorly, glands and cellular tissue inferiorly; it hangs perpendicularly over the depression in the tongue, called foramen cœcum, is not in contact, but so very close that nothing of any size can pass between them without affecting the sensibility of the uvula, whereby all the surrounding muscles are excited to action; the point of the uvula is anterior to the epiglottis. This organ is very variable as to shape and size, it is sometimes a little bifid, sometimes nearly absent, and is wanting in almost all other mammalia, except the quadrumana. From either side of the uvula the mucous membrane of the velum is continued downwards in two folds, which contain muscular fibres, and are named the *arches* or *pillars* of the palate. The anterior arch or fold, passing from the base of the uvula, is curved downwards and outwards, and ends on the superior and lateral part of the tongue; this fold is very concave inwards, and contains the palato-glossus or constrictor isthmii faucium muscle. The posterior arch or fold arises near the point of the uvula, and is continued in a curved form from the free edge of the velum downwards, outwards, and backwards, and is lost in the side of the pharynx; it contains the palato-pharyngeus muscle,

and is on a plane internal as well as posterior to the former; both these folds are somewhat triangular, the apex above, the base below, and as they diverge inferiorly they leave a considerable space between them, in which the amygdala or tonsil of each side is lodged. This tonsilitic recess or ventricle is narrow and pointed above, broad and deep below, bounded before and behind by the arches of the palate, below by the base of the tongue and the mucous membrane passing from the pharynx to the epiglottis; it corresponds externally and inferiorly to the angle of the jaw and to the integuments over the posterior part of the sublingual region. The velum is a highly organized structure, it is composed of a duplicature of mucous membrane, enclosing glands, cellular tissue, nerves, and vessels, a strong aponeurosis forming the basis of general support, and several muscles designed to move it in different directions, namely, to elevate, depress, and make it tense. It is of great use in deglutition and in the modulation of the voice; when depressed it comes into close contact with the tongue and closes the mouth posteriorly; when elevated during the contraction of the pharynx it may touch the latter so as to separate or shut off the nasal division, and thus during deglutition or in vomiting prevents the food ascending into it and regurgitating through the nares and Eustachian tubes, its aponeurosis and tensor muscles regulate and restrict these motions and impart the necessary strength and resistance.

The mucous membrane is continued from that of the hard palate, round the thin edge, to the upper surface, and is continuous with that covering the floor and septum of the nose; the laminæ are in much closer apposition in the lunated borders of the free margin than in other situations; a digital prolongation from the centre is produced downwards to constitute the uvula; the lower surface is soft and vascular, resembling that in the adjacent regions, the upper, like that on the floor of the nose, is paler and thinner; the mucous glands are but few above, but on the oral surface they form a thick, submucous layer, which is prolonged for a variable extent into the uvula. The palatine aponeurosis is very strong and laminated; an inferior, weaker layer is continued from the hard palate, the submucous glands are intimately connected to it; above this is a much stronger aponeurosis, formed partly of the expanded tendons of the tensor muscles, and partly of the fibrous tissue from the septum narium and adjacent bones. The muscles of the velum or soft palate are five pair, the levator and tensor palati, the motor uvulæ, palato-glossus, and palato-pharyngeus.

Levator-Palati, thick and round, *arises* narrow from the petrous bone, in front of the foramen caroticum and behind the Eustachian tube, descends obliquely inwards, and is *inserted* broad into the velum near its centre: its name denotes its *use.* It is situated on the side of the posterior nares, covered internally and posteriorly by mucous membrane, and externally by the tensor palati and superior constrictor; its insertion intermixes with its fellow, with the other muscles of the palate, and with the palato-pharyngeus.

Tensor Palati vel circumflexus palati, thin and slender, *arises*

fleshy from a depression at the root of the internal pterygoid plate, from the spinous process of the sphenoid, and from the forepart of the Eustachian tube, descends between the internal pterygoid plate and muscle, ends in a flat tendon, which turns round the hamular process inwards to the velum, it then expands, and is *inserted*, with that from the opposite side, into the horizontal plate of the palate bones, and into the palatine aponeurosis. *Use*, to make tense the velum in a horizontal direction between the hamular processes; it may possibly dilate the Eustachian tube.

Motor Uvulæ, *arises* from the posterior extremity, or spine of the palate bones, or rather from the palatine aponeurosis, or fibrous continuation of the septum narium; descends close to its fellow along the median line of the nasal surface of the velum, and is *inserted* into the cellular tissue of the uvula. *Use*, to raise and shorten the uvula: this pair of muscles are so close that they appear but as one, hence they have sometimes received the name of *azygos uvulæ*.

Palato-Glossus vel constrictor isthmi faucium, or the anterior arch or pillar of the palate, semilunar, narrow in the centre, broad at its extremities, *arises* from the inferior surface of the velum, descends a little forwards and outwards, enclosed in a fold of mucous membrane anterior to the tonsil; *inserted* into the side of the tongue, intermingling with the stylo-glossus. *Use*, to elevate the tongue or to depress the velum; this pair of muscles may also close the fauces.

Palato-Pharyngeus, or posterior arch of the palate, *arises* broad from the inferior surface of the soft palate in common with its fellow; arches downwards and backwards behind the tonsil, and is *inserted* into the side and back of the pharynx, and into the cornu of the thyroid cartilage, its fibres mixing with those of the stylo-pharyngeus; both this and the palato-glossus muscle are narrower in the centre than at their extremities. *Use*, to elevate the pharynx, like the stylo-pharyngei, in the commencement of deglutition, also to depress the velum, but chiefly to approximate the sides of the fauces and bring them, the tongue, and velum into contact.

The *tonsil*, or *amygdala*, though apparently a compact body, is formed of a congeries of mucous glands, of an irregular figure, somewhat oval, the larger extremity above, placed in a triangular recess between the pillars of the palate, above the side of the base of the tongue, and opposite the angle of the jaw; covered internally by the mucous membrane, and externally by a fascia and by the superior constrictor of the pharynx; small holes are remarked on its surface; these lead into interlobular cells from which the mucus can be expressed. The amygdalæ are very vascular and secrete a viscid fluid, which being pressed out in the moment of deglutition by the contraction of the surrounding muscles, *serves* to lubricate the alimentary bolus in its passage. The internal carotid artery is posterior and somewhat external to it, and, when tortuous, very near to it; the external carotid is also to its outer side, and the facial artery, just before it enters the

submaxillary gland, is anterior to it; from these three vessels this gland, when of its healthy size, is separated by the superior constrictor, and by a considerable interval which is filled by cellular tissue, but when enlarged, as in the case of abscess, it comes into such close contact with these, particularly with the internal carotid, that there is some danger of wounding the latter in opening the abscess with the lancet.

The group of muscles now described, though in a great degree voluntary, yet rather belong to the mixed class; the will can excite and control them only to a certain extent, it can even continue their actions for a time, but if there be no substance to be swallowed, their contractions cannot be often repeated and volition is impotent; they act, too, convulsively, and oftentimes without any cognizance; deglutition occurs in sleep: the volition power is most enjoyed anteriorly, as in the tongue, lips, and cheeks; the mixed property prevails in the middle region; the lower we descend the more involuntary is the muscular fibre, and so it is at the opposite or lower end of the alimentary canal, the mixed property and the volition power of the investing and surrounding muscles are gradually developed towards the orifice, while all the intervening muscular coat of the digestive tube is purely involuntary; perhaps the muscular powers of the stomach, in some animals at least, may prove an exception to this general assertion. The sensibility to contact of the mucous membrane in the palatine region is very considerable, and exerts a rapid influence over the surrounding muscles through the reflex motor power of the nervous system, whereby the act of *deglutition* is effected; this act, though momentary, and, as it were, convulsive, may be divided into three stages; in the FIRST, which is in part only a continuation of mastication, the alimentary matter is pressed by the convex surface of the tongue, which is accurately and beautifully moulded to the vault of the palate, backwards into the space bounded by the anterior arches or pillars of the velum, that is, into the isthmus faucium; during this stage the velum is depressed, and lies nearly in contact with the base of the tongue, the pharynx is in a state of rest; this stage is accomplished chiefly by the muscles of the tongue and cheeks; in the first instance the mouth is closed anteriorly and the last agent is the constrictor isthmus faucium; it is a voluntary act. In the SECOND stage, the alimentary matter is carried through the fauces and pharynx into the œsophagus; the velum at first is made tense and slightly raised; the tongue is retracted, the larynx drawn upwards beneath it so that the epiglottis is pressed or shut down over the glottis, and the alimentary mass glides over its centre and sides; at this very instant the pharynx is advanced, its sides approximate, the velum descends a little, though still preserving the partition below the nares, and is held steady; all the muscles now contract towards the base of the tongue, and thus a narrow inclined passage or chink conducts the food down to the œsophagus; finally, the still contracting pharynx recedes; and, last of all, the larynx descends coincident with the entrance of the morsel into the opening of the œsophagus. This stage is effected not only without the influence of

the will, but even at times in opposition to it, although it may and does occasionally exert some power of control so as to retard, hurry, or even interrupt it. In the THIRD stage, the food descends along the œsophagus into the stomach by rapid, undulatory contractions, each portion of the tube first dilating to receive, and then contracting to propel, somewhat analogous to the peristaltic action of the alimentary canal, and like that, too, wholly involuntary, and scarcely even giving rise to any sensation, unless the mass swallowed should be of inordinate magnitude, or of a temperature extremely high or even very low, or unless the act be too rapidly repeated. Not only is the velum essential in deglutition, but it is also most usefully concerned in certain conditions of respiration, thus in suction it is indispensable; in forced inspiration through the mouth, it is raised and made tense, and thus the whole of the air imbibed must descend into the chest, as none can enter the Eustachian tubes, or escape by the nares. In the modulation of the voice, the expression of sounds, words, and letters, it also acts an important part; by being raised or depressed, made tense or loose to the requisite degrees, it produces the desired effect, and hence not only the difficulty of deglutition, but also the peculiar altered tone and indistinctness of voice and utterance when this organ is cleft or otherwise abnormal from original malformation or arrest in its development, or when it has become perforated by ulceration, condensed and shrivelled by disease, or partially destroyed by gangrene. The mucous membrane of the velum and adjacent surfaces enjoys a certain degree of taste for peculiar substances, and is also exquisitely sensible to certain pungent, disagreeable, and noxious odours, and the irritability of all the surrounding muscles is thereby rapidly excited, through the reflex power of the nervous system, to active and repeated contractions, not so much in their ordinary as in a retrograde order, so as to lead to the rejection or expulsion, aided by forcible expiration, of the offending substance, and thus by this endowment the lungs and stomach are wonderfully guarded against the admission of injurious or dangerous agencies. In these various offices of the velum, it is not easy to affirm the use of the uvula; its muscle may stiffen and strengthen it when the palate is raised or tense, or when the latter is depressed, it may in a passive manner contribute to narrow the chink-like passage for the food; however its variable and even occasional arrest of development, and not unfrequent removal in man without any corresponding deficiency, together with its total absence in most of the animal kingdom, preclude the idea of its being of any essential utility in a function so universal as is that of deglutition; it may, no doubt, aid the velum in perfecting those modulations and expressions of voice already alluded to. It is very sensible to contact, and irritable, and all the surrounding parts very quickly sympathize with it; from its depending position and the proximity of its apex to the base of the tongue, not even the thinnest stratum of fluid can glide between the two, without exciting the sensibility of the uvula, and thence the irritation is rapidly conveyed to all the muscles concerned in the second stage of deglutition; it thus

appears to act as a sort of sentinel in this important and critical position, and as deglutition of the salivary secretions constantly occurs at intervals during sleep, which man usually enjoys in the horizontal or reclined position, it may not, perhaps, be amiss to conceive that the superior development of this appendix in him has reference to that condition.

A careful examination of all this curious and complicated palatine and pharyngeal apparatus will explain the mechanical arrangements which have been so ingeniously designed and so perfectly executed for the safe and frequent performance of functions so necessary to life; how

*Fig.* 11.*

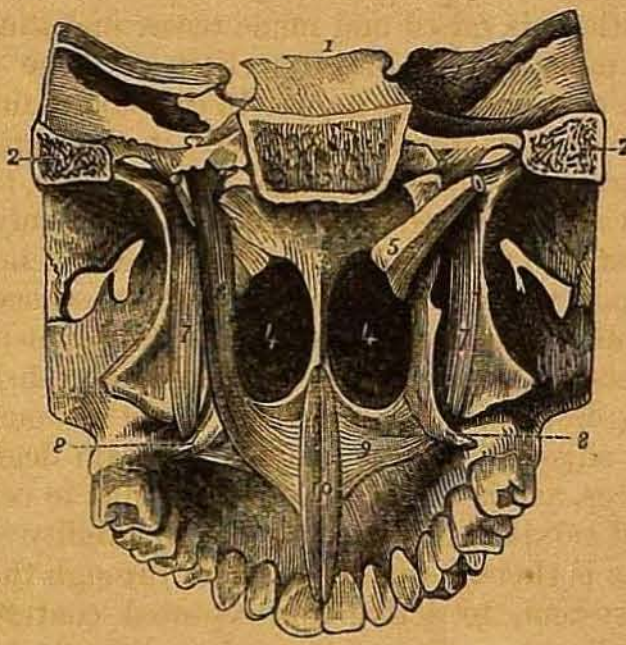


the air can freely pass, during sleeping as well as waking hours, to and from the lungs, as also into each tympanum, without descending into the stomach, and how all alimentary matters, solid as well fluid, are in safety propelled over the glottis into the œsophagus by the rapid, convulsive efforts of numerous concurring muscles, with only a momentary interruption to respiration, as this function, that is, the mechanical acts of inspiration and expiration, must be suspended during the instant in which the second stage of deglutition is being performed.

The soft palate and its arches, the uvula and the tonsils, are liable to many *morbid* affections, viz., acute inflammation and all its consequences; syphilitic ulceration very commonly attacks these parts, particularly that surface towards the mouth; polypi, also, are not un-

* The muscles of the soft palate. 1. A transverse section of the skull, passing through the basilar process of the occipital bone in the centre, and through, 2. The posterior part of the great wing of the sphenoid. 3. The vomer covered by mucous membrane, and forming the posterior part of the septum of the nasal fossæ. 4. The posterior nares. 5. The Eustachian tube. 6. The levator palati muscle. 7. 7. The tensor or circumflexus palati. 8. 8. The hamular process, round which the tensor palati turns. 9. The horizontal portion of the tensor palati, expanding in the structure of the soft palate. 10. The motor uvulæ descending from the posterior spine of the palate bones.

frequently produced from the velum, and in general from its upper or nasal surface. When the uvula is the seat of inflammation, its pendulous extremity becomes so distended by serous infiltration that its figure is totally changed, and it sometimes interferes so much with deglutition and respiration, or excites such irritation, as to require free scarification, or excision of its lower portion. The velum is sometimes found cleft at birth with or without the accompanying similar abnormal state of the hard palate and upper lip.

The tonsil is very subject to acute inflammation (cynanche tonsillaris); in this affection it enlarges so much as to impede deglutition, induce deafness, and even in some cases to threaten suffocation. It is sometimes, also, the seat of chronic enlargement, to such a degree as to require the operation of removal; it is also frequently affected with syphilitic ulceration, also with calcareous deposit: its cribriform surface, when covered with lymph, should not be mistaken for ulceration.

The *œsophagus* appears as the continuation of the pharynx, it differs from it, however, in structure; the mucous membrane is paler, and thrown into longitudinal folds; the muscular fibres are arranged in two laminæ, the external are longitudinal, strong, and red, attached superiorly and anteriorly to the cricoid cartilage, and below are lost on the stomach; the internal circular fibres are pale, and cease abruptly at the cardiac orifice of the stomach. In the neck the œsophagus descends posterior to the trachea, and nearly in the middle line; it inclines a little to the left side below, so as to be uncovered by that tube; in the upper part of the thorax it inclines a little to the right, and below again to the left. This slightly tortuous, intestine-like course might offer some impediment to the passage of a bougie: the left lobe of the thyroid gland, the recurrent nerve, and the inferior thyroid vessels, lie on it in this situation; it is flattened in the neck, and rounded in the back, is wider below than above.

The *morbid* appearances met with in the pharynx and œsophagus are not very many; the mucous membrane of the former is liable to inflammation (cynanche pharyngea), and to ulceration from various causes; the submucous tissue is frequently the source of polypous growths, particularly at the upper part. The lining membrane of the œsophagus is seldom the seat of active inflammation, except as the consequence of some foreign body, or the contact of some acrid substance; it is not unfrequently the seat of stricture, caused in some cases by a contraction and thickening of its coats, in others by true scirrhus, ending in cancerous ulceration; tumours in the vicinity of this tube will also interrupt its functions, for example, bronchocele, enlarged bronchial glands, or aneurism of the descending aorta. The œsophagus is also sometimes affected with paralysis, and in hysterical patients it is very subject to nervous affections, which frequently bear a close resemblance to true stricture of this tube. The course and connexions of the œsophagus in the chest will be seen hereafter.*

* The student should practise the passing of a probe or canula armed with a ligature, along the nares, into the pharynx, and endeavour to enclose the uvula

# SECTION VI.

## DISSECTION OF THE LARYNX.

THE *larynx* surmounts the upper extremity of the respiratory passages with which it communicates below, as it does with the pharynx above; it is composed of a complicated apparatus of several cartilages, muscles, and ligaments, which constitute the organ of voice; is placed at the anterior part of the neck, between the tongue and trachea, in front of the pharynx and œsophagus, covered only by the integuments and the subhyoidean muscles; it is suspended by muscles and ligaments from the os hyoides. Although this bone does not, strictly speaking, appertain to the larynx, but rather to the tongue, yet the former is so connected with it, that this appears a fitting situation to examine it.

The *os hyoides* is connected to the chin by several muscles, and to the styloid process of the temporal bone on each side by the digastric and stylo-hyoid muscles and ligament; it consists of five parts, the middle portion, or *body*, is very rough, and convex anteriorly and superiorly for the attachment of muscles, concave posteriorly and inferiorly, where it covers the epiglottidean submucous tissue; from the body the cornua pass off, one to either side, giving attachment to muscles above and below, and lined by mucous membrane; they serve to expand the pharynx and fauces; where each cornu joins the body a small process, the *appendix*, ascends obliquely backwards, and gives attachment to the stylo-hyoid muscle and ligament. It sometimes happens that this ligament is ossified, so that the os hyoides will then be found attached to the cranium.

In examining the different structures which enter into the formation of the larynx, I shall pursue the following order: 1. the cartilages, with their ligaments and articulations; 2. the muscles; 3. the mucous membrane and glands; 4. the vessels; 5. the nerves; and, finally, offer a few general observations on this organ. Four true, or

in the noose, thus imitating the operation of tying polypi when situated in the pharynx, on the velum, or in the posterior nares; he may also pass a flexible tube into the pharynx, and thence direct it to the stomach or into the larynx. Any practitioner may be suddenly called on to use the stomach pump in case of poison having been swallowed, or to inflate the lungs in asphyxia; in the *first case*, when the tube has passed into the pharynx, from the mouth or nares, the tongue should be pressed back, so as to close the glottis, and the end of the instrument should be kept close to the vertebræ to avoid irritating or pressing on the epiglottis; in the *second case*, the tube should be passed through either naris into the pharynx, the forceps or the finger of the surgeon, introduced into the mouth, can then guide it downwards and forwards to the glottis; at this time, however, the tongue should be drawn forwards; thus the epiglottis will be raised, and the glottis opened opposite the edge of the velum; the tube may then be urged into the larynx, and artificial respiration commenced. In conducting this process it is advisable to press the upper part of the trachea gently against the vertebræ, so as to fix the larynx and the tube, as well as to guard against the admission of air into the œsophagus, and the consequent inflation of the stomach.

perfect, and four false, or imperfect, cartilages, enter into the formation of the skeleton of the larynx: the true cartilages are the thyroid, cricoid, and two arytenoid; the false cartilages are the two corpora cuneiforma, and the appendices or cornicula of the arytenoid cartilages; there is also one fibro-cartilage, the epiglottis.

*Fig.* 12.*

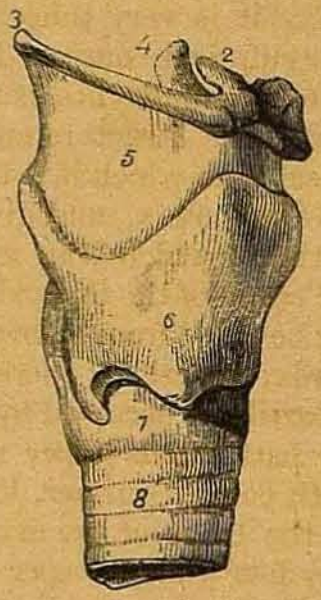


The *thyroid*, or shield-like cartilage, is placed at the anterior and lateral parts of the larynx; it embraces the sides and back part of the cricoid, and protects the greater part of the mechanism of the larynx, but is open behind; it is composed of two broad, irregularly shaped lateral plates or alæ, which join in an anterior angle or prominence in the mesial line; this is more developed in man than in the female or child, and is named the *Pomum Adami*. As each ala passes backwards it increases in depth, and presents two tubercles, one near the superior, the other smaller near the inferior margin; an oblique ridge connects these, and divides the ala into two unequal segments, of which one is anterior and superior, and much larger than the other, which is behind and below this line. This ridge gives attachment to the sterno-thyroid, hyo-thyroid, and inferior constrictor muscles; near the upper tubercle is a notch, or often a foramen, for the transmission of the superior laryngeal nerve. The upper border of each ala is convex, and gives attachment to the thyro-hyoid membrane; it is deeply notched in front above the pomum. The inferior border is shorter, and nearly horizontal, and projected a little below the pomum, giving attachment to the elastic crico-thyroid ligament; posteriorly this border is arched deeply. The alæ are round and thick posteriorly, giving attachment to muscles and the mucous membrane of the pharynx, and resting against the vertebral column: from the upper and lower edge of each are continued the cornua. The superior or ascending cornua are long and round, and are connected to the os hyoides by round ligaments, which are often studded with cartilaginous and osseous grains. The inferior cornua are short, and bent a little inwards and forwards, and are articulated to the oblique surfaces on the cricoid cartilage. Each ala is concave internally, and covers the thyro-arytenoid, and the lateral crico-arytenoid muscles. The posterior surface of the pomum is

* A lateral view of the larynx, the muscles having been removed. 1. The body of the os hyoides. 2. Its appendix or lesser cornu. 3. Its great cornu. 4. The superior extremity of the epiglottis. 5. The hyo-thyroid ligament or membrane. 6. The thyroid cartilage. 7. The cricoid cartilage. 8. The upper part of the trachea.

very concave, and gives attachment in the mesial line to the ligament of the epiglottis, and on each side to the chordæ vocales.

The *cricoid* or annular cartilage forms the lower part or base of the larynx, it is very thick and strong; it is not perfectly circular, but rather elliptical, narrow before, deep and strong behind; the inferior edge or circumference is nearly circular and horizontal, and connected by an elastic structure and mucous membrane, to the first ring of the trachea, than which it is thicker and deeper. The anterior and external surface is convex, and gives attachment to the crico-thyroid muscles, posterior to which is an articulating tubercle on each side for the inferior cornu of the thyroid cartilage. The superior margin is oblique, being bevelled from below and before, upwards, backwards, and a little inwards; anteriorly there is a space between this border and the thyroid cartilage, occupied by the elastic crico-thyroid ligament; the posterior part of this upper margin is horizontal, having on each side a smooth convex surface, looking upwards and outwards for articulation with the bases of the arytenoid cartilages. The posterior surface is nearly four times deeper than the anterior, and is divided by a middle vertical prominent ridge, to which some fibres of the œsophagus are attached; on each side of this is a depression which is occupied by the crico-arytenoid postici muscles. The internal surface of this cartilage is smooth, and lined by the mucous membrane.

The arytenoid, or ewer-shaped cartilages, are situated vertically on the articulating surfaces on the upper and posterior border of the cricoid; they are somewhat pyramidal or triangular; the base of each is below deeply curved into an oval, oblique, articulating surface, with two processes, one external for the attachment of the crico-arytenoid muscle, the other is anterior, for the insertion of the inferior chorda vocalis, which forms the side of the rima glottidis; this latter prominence is pyramidal, it projects considerably over the side of the rima, nearly one-third of its extent. The apex of each arytenoid inclines a little backwards, and is surmounted by the *appendix* or *corniculum*. The posterior surface is concave, and covered by the arytenoid muscle. Anteriorly each is convex, with sharp, rugged ridges for the insertion of the superior chorda vocalis, and the aryteno-epiglottidæan folds of mucous membrane which form the side of the glottis; these ridges are, of course, superior to the basilar projections into which the inferior chordæ

*Fig.* 13.*

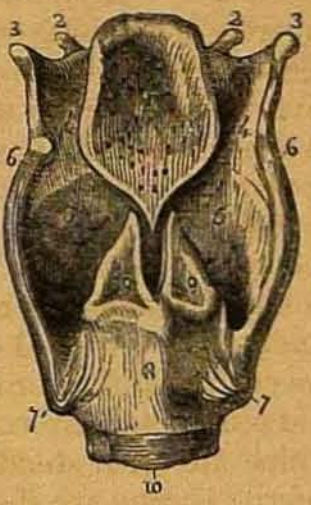

* A posterior view of the larynx, after the removal of its muscles. 1. The posterior surface of the epiglottis. 2. 2. Appendices or lesser cornua of the os hyoides. 3. 3. The great cornua of the os hyoides. 4. 4. The posterior surface of the hyo-thyroid ligament. 5. 5. The posterior surface of the thyroid cartilage. 6. 6. The ascending cornua of the thyroid cartilage. 7. 7. Its inferior cornua. 8. The cricoid cartilage. 9. 9. The arytenoid cartilages. 10. The first ring of the trachea.

vocales are inserted. Their internal or opposed sides are flat and smooth, and covered by mucous membrane, so as to admit of their approximation. These cartilages enjoy free motion in the four directions, forwards, backwards, inwards, and outwards, as well as a certain degree of rotation round the axis of their articulations on the cricoid.

*Fig.* 14.*

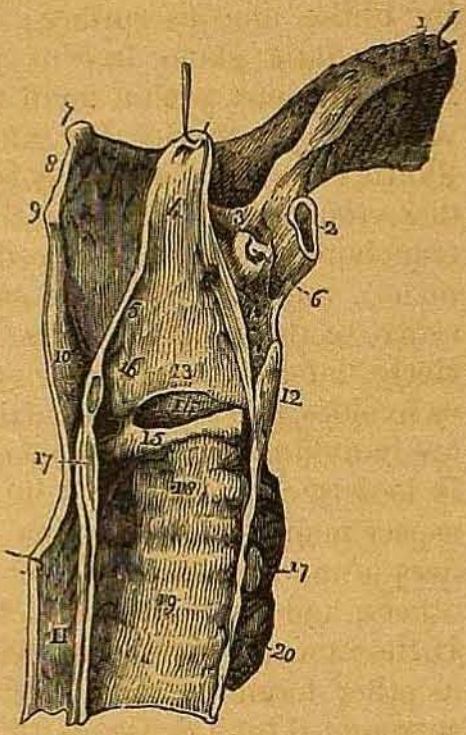

The *appendices* or *cornicula* of the arytenoids are two small, curved, cartilaginous bodies, described by Santorini, inclining backwards and towards each other, loosely joined to the apex of each arytenoid, which they serve to lengthen in the vertical direction, and on which they can freely move.

The *epiglottis* stands behind the base of the tongue, nearly erect, in front of the opening of the glottis, over which it can, however, be bent almost horizontally, so as to cover this opening during deglutition. It is considered as a fibro-cartilage, but it is really a complex structure, and may be regarded as one *sui generis* ; in form it is somewhat triangular or oval, its edges being curved or curled, so as to resemble a cordate leaf; its colour is a pale yellow, with little appearance of vascularity ; anteriorly it is curved forwards above and a little along its edges, so as to be concave from above downwards, and convex transversely, while posteriorly it is convex from above downwards, and concave transversely. The anterior or lingual surface is free superiorly, and can be seen and felt in the living mouth ; inferiorly this surface is adhering to the base of the tongue, os hyoides, and thyroid cartilage ; to the tongue by an elastic tissue, glosso-epiglottic ligament, which is below the mucous frænum ; to the os hyoides by a thin ligament (hyo-epiglottic), extending from the upper and posterior edge of the base of that bone to the forepart of the epiglottis, and beneath this by a mass of cellulo-adipose matter of a yellowish colour, very soft, mobile, and somewhat elastic, and surrounded by loose cellular

* A vertical section of the larynx, exhibiting the interior of the left half. 1. A portion of the base of the tongue. 2. The section of the body of the os hyoides. 3. The frænum epiglottidis. 4. The left half of the epiglottis. 5. The aryteno-epiglottidæan fold of mucous membrane. 6. A section of the epiglottidean gland. 7. The great cornu of the os hyoides. 8. The hyo-thyroid ligament. 9. The ascending cornu of the thyroid cartilage. 10. The mucous membrane of the pharynx. 11. The cavity of the œsophagus. 12. A section of the thyroid cartilage. 13. The superior vocal chord. 14. The sinus or ventricle of the larynx. 15. The inferior vocal chord. 16. A prominence produced by the left arytenoid cartilage. 17. 17. Sections of the cricoid cartilage. 18. The internal surface of the cricoid cartilage, lined by mucous membrane. 19. The internal surface of the trachea. 20. A section of the thyroid gland.

tissue very like a synovial bursa; this mass has been very generally called "epiglottic gland," but on insufficient grounds, for careful examination does not disclose any glandular structure or ducts extending to the mucous surface; in the young subject I have often found a lymphatic gland in this position, and in delicate children I have frequently met with a small tumour here, and suppuration is by means uncommon in this locality, and is occasionally very dangerous. The epiglottis is attached inferiorly by a stalk-like pedicle (not visible without dissection), to the inside of the pomum, immediately above that of the true chordæ vocales; this pedicle is ligamentous (thyro-epiglottic ligament), and much thinner and more delicate than the leaf itself; the centre of the upper border is slightly notched, and perfectly free; anteriorly, laterally, and posteriorly it is connected to the tongue, pharynx, os hyoides, and arytenoid cartilages by folds of mucous membrane, which are individually named from their attachments. The mucous membrane is loosely connected to it in front, but closely behind; on this latter aspect many small foramina are observable, which are probably orifices of mucous ducts; these are much more obvious in some than in others, and are more distinct in some of the ruminantia than in man. If the mucous membrane be dissected off this surface, these, as well as other foramina, are observed perforating this plate; the holes are surrounded by a dense cartilaginous tissue, and through these some bands of elastic, yellow tissue, intermingle. The epiglottis is very flexible, and eminently elastic, thus it is easily depressed in deglutition, and its elevation is rapid, not requiring any muscular action, when once the tongue has advanced, and the larynx descended. It is never found ossified, a change which the other cartilages of the larynx, particularly the thyroid and cricoid, are very prone to undergo. In deglutition the epiglottis is of much use, it covers the larynx, and so prevents any foreign substance entering it; during this act the tongue is drawn backwards, and the larynx raised forwards, thus the glottis is closed, and the contents of the mouth pass over the epiglottis into the pharynx. The *cuneiform* are two small, irregularly-shaped bodies, somewhat triangular, the base above involved in the aryteno-epiglottidæan folds of mucous membrane, near to the apices of the arytenoid cartilages; in some they are very indistinct, and look like a small glandular or adipose mass; in others they are firm and prominent, and, when separated from the investing tissue, have somewhat the form of the letter L; they serve to strengthen and thicken the sides of the glottis.

The larynx is articulated, or rather connected to the os hyoides by three *hyo-thyroid ligaments*, one middle and two lateral; the anterior is a broad, yellow, but loose tissue, arising from the superior margin of the thyroid angle, and inserted into the inner margin, and superior edge of the base of the os hyoides, and not into its lower, it is therefore behind that bone, it is covered by the integuments in the centre, and on each side by the thyro-hyoid muscles, and is separated from the epiglottis by the adipose mass. The lateral thyro-hyoid ligaments are

round cords which connect the superior cornua of the thyroid cartilage with the round tubercles at the extremities of the cornua of the os hyoides, these occasionally contain cartilaginous or osseous grains. The thyroid cartilage is articulated by its inferior cornua, to the oblique surfaces on the cricoid, which look upwards and outwards, these are arthrodial joints and possess synovial membranes, and capsular ligaments, the fibres of which are very distinct and bright, radiate to some extent, particularly behind, nearly reaching the crico-arytenoid articulations. In these joints, there is a slight gliding motion, and a very palpable rotatory one round the transverse axis of both. The middle crico-thyroid is an important ligament, very strong, yellow, and elastic, arising from the lower border of the thyroid, and *inserted* into the upper edge of the cricoid; two or three minute pores exist in it for the passage of small blood-vessels. Strong ligamentous fibres also connect the sides of these two cartilages by their internal borders. The crico-arytenoid articulations are furnished with loose synovial membranes, and secured by strong crico-arytenoid fasciculi of ligamentous fibres; the surface of the cricoid is convex, that of the arytenoid concave; great freedom of motion exist in these articulations. The *thyro-arytenoid* ligaments or chordæ vocales are four in number, two on each side, a superior and inferior. The inferior are true fibrous chords, much stronger than the superior, which are little more than folds of mucous membrane; they *arise* from the angle of the thyroid, extend horizontally backwards on each side of the long axis of the rima glottidis, and are *inserted* into the anterior or long pyramidal process at the base of each arytenoid cartilage; the thyro-arytenoid muscles are closely connected to their outer side, and impart much of their apparent thickness, while their inner, upper, and lower are smooth and free to vibrate in the opening; these are strong and semi-transparent ligaments, and composed of parallel and elastic fibres; they are longer in the male than in the female, and very short in the child. The superior chordæ vocales or thyro-arytenoid ligaments are by some named false ligaments; they are thinner, weaker, and further removed from the axis of the larynx; they *arise* above the former, pass backwards in an arched course, concave downwards, and are *inserted* into the anterior superior part of the arytenoid; they consist of a few delicate fasciculi of elastic fibres, involved in mucous membrane; their superior border is not defined, but the inferior is, as it forms the top of the sinus of ventricle of the larynx. The ligaments of the epiglottis are the thyro-epiglottidæan, or the stalk-like connexion to the thyroid cartilage;

*Fig.* 15.*

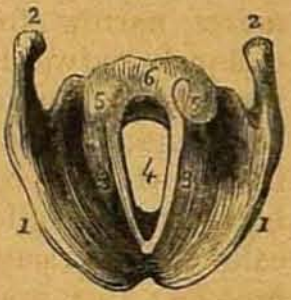


* A view of the larynx from above downwards, to shew the form and relative dimensions of the rima glottidis; the os hyoides and hyo-thyroid ligament have been removed. 1. 1. The upper border of the thyroid cartilage. 2. 2. Its ascending cornua. 3. 3. The chordæ vocales. 4. The rima glottidis. 5. 5. The apices of the arytenoid cartilages. 6. The cricoid cartilage.

the hyo-epiglottidæan, which is a thin membrane passing horizontally from the upper edge of the base of the os hyoides to the forepart of the epiglottis; the epiglottis is also connected to the anterior and lateral parts of the pharynx on each side by a fold of mucous membrane, and to the base of the tongue by three similar folds, of which the centre (frænum epiglottidis) is the strongest, it contains a little dense cellular tissue, a few elastic fibres, and is also slightly *inserted* into the os hyoides, above the hyo-epiglottic ligament. The cricoid cartilage is connected to the trachea by an elastic ligamentous tissue which, though very strong, admits of free motion in all the movements of the neck; this ligament is stronger in front; it is very similar to that connecting the several rings of the trachea to each other.

The muscles of the larynx are symmetrical, they are found on the front, sides, and backpart, those on the forepart are the thyro-hyoid, and crico-thyroid, on each side are the thyro and lateral crico-arytenoid, and posteriorly are the arytenoid and posterior crico-arytenoid; to these some add the thyro-epiglottidei and the aryteno-epiglottidei.

THYRO-HYOIDEUS, broad and flat, *arises* from the upper edge of the oblique ridge on the ala of the thyroid cartilage, ascends a little outwards, and is *inserted* into the lower border of the cornu of the os hyoides. *Use*, to elevate and draw forwards the larynx beneath the tongue and epiglottis, and so cause the glottis to be closed in deglutition. This muscle is partly covered by the integuments and sterno and omo-hyoid; it appears like a continuation of the sterno-thyroid.

CRICO-THYROIDEUS, inferior to the former, short and triangular; *arises* narrow from the forepart of the cricoid cartilage, ascends obliquely outwards and backwards, and is *inserted* broad into the lower border and cornu of the thyroid. *Use*, to approximate these cartilages, and, at the same time, to rotate the cricoid on the thyroid; that is, they depress and draw forward the thyroid and raise and tilt backwards the cricoid cartilage, and thus make tense the chordæ vocales. The crico-thyroid ligament occupies the space between these muscles; they are covered by the sterno-hyoid. Raise the ala of the thyroid cartilage on one side, and the lateral muscles of the larynx will be exposed.

THYRO-ARYTENOIDEUS is flat and thin; *arises* from the internal surface of the thyroid cartilage, near its angle; the fibres pass backwards and outwards, expanding over the side of the rima glottidis, and are *inserted* into the anterior and outer edge of the arytenoid cartilage, and into the outer side of its long anterior process; some fibres pass partly round this border to the posterior surface. *Use*, to draw the cartilage downwards and towards its fellow, thereby diminishing the capacity of the rima glottidis; these muscles can also produce various alterations in the form, position, and degree of tension of the chordæ vocales, which they cover; and they can compress the sinus or sacculus laryngis. The thyro-arytenoid muscles are considered by some as the principal and most important agents in the production of voice, in consequence of their close connexion to the vocal chords, and their ca-

pability of producing endless varieties in their condition, causing the vibration in their edges so to differ in intensity and duration as to produce from the air passing over them (to a certain extent only) corresponding varieties of sound or tone. These muscles are covered by the alæ of the thyroid cartilage and some intervening loose cellular tissue; they lie on the chordæ vocales, and on the intermediate sinus; superiorly their fibres extend to an indefinite height in the mucous folds of the glottis, and inferiorly they are connected to the following muscles.

*Fig.* 16.*

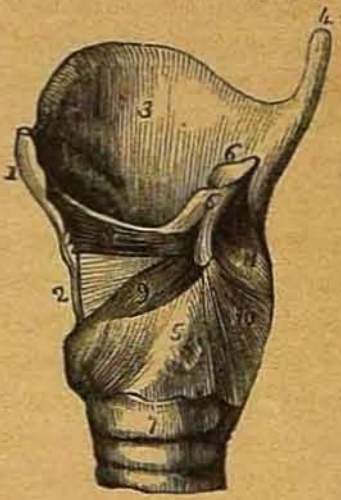


CRICO-ARYTENOID LATERALIS *arises* from the upper edge of the side of the cricoid cartilage, where the latter is covered by the ala of the thyroid cartilage, ascends obliquely backwards and is *inserted* into the base of the arytenoid. *Use*, to draw that cartilage forwards and outwards, and thus to relax the vocal chords and enlarge the rima from side to side, but contract it from before backwards. These two last described muscles might be regarded as one, there being no very marked line of distinction between them. Raise the mucous membrane from the commencement of the œsophagus on the back part of the larynx to expose the muscles situated there.

*Fig.* 17.†

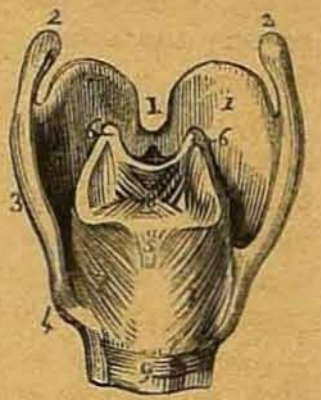


CRICO-ARYTENOID POSTICUS, strong and flat, *arises* from the depression on the posterior surface of the cricoid; the fibres ascend obliquely outwards, *inserted* by a tendon into the outside of the base of the arytenoid cartilage. *Use*, to draw this cartilage backwards and outwards, so as to enlarge the rima in every direction, as in full inspiration. These muscles lie on the back of the cricoid cartilage, and are covered posteriorly by the pale mucous membrane descending into the œsophagus; these are the great dilators of the rima glottidis.

ARYTENOIDEUS fills the interval, and is enclosed in the fold of mucous membrane between the arytenoid cartilages; it consists of oblique and

* A lateral view of the muscles of the larynx; the left ala of the thyroid cartilage having been removed. 1. The cut edge of the thyroid cartilage. 2. The divided edge of the crico-thyroid ligament. 3. The remaining ala of the thyroid cartilage. 4. Its ascending cornu. 5. The lateral surface of the cricoid cartilage. 6. 6. The arytenoid cartilages. 7. The first ring of the trachea. 8. The thyro-arytenoid muscle of the left side, exposed by the removal of the left ala of the thyroid cartilage. 9. The crico-arytenoideus lateralis. 10. The left crico-arytenoideus posticus. 11. The arytenoid muscle.

† A posterior view of the larynx. 1. The posterior surface of the thyroid cartilage. 2. 2. Its ascending cornua. 3. Its posterior border. 4. One of its inferior cornua. 5. The posterior surface of the cricoid cartilage. 6. 6. The arytenoid cartilages. 7. 7. The crico-arytenoidei postici muscles. 8. The arytenoideus muscle. 9. The upper part of the trachea.

transverse fibres, the former are superficial and consist of two or three fasciculi which pass from the apex of one cartilage to the base of the opposite; the transverse fibres are anterior to the former, more numerous, and are attached to the posterior surface of each cartilage. *Use*, to approximate these cartilages, and close the sides of the rima posteriorly; at the same time that they tend to separate their anterior processes, and thus can open the rima in front; these, together with the thyro and crico-arytenoid laterales, are the contractors of the rima glottidis. In the aryteno-epiglottidean folds, fleshy fibres are sometimes discernable, and have been described as distinct muscles, and named, from their situation, aryteno-epiglottidean, and thyro-epiglottidean, or the depressors of the epiglottis.

In the human subject these are seldom sufficiently well marked to merit the appellation of distinct muscles. We shall, however, describe them as they are occasionally to be found.

THYRO-EPIGLOTTICI are situated between the thyroid cartilage and the epiglottis; *arising* from the internal surface of the angle of the thyroid, the fibres pass upwards and forwards to the base of the epiglottis, and are *inserted* into it, behind the thyro-epiglottidean ligament; the action of these fibres will be to depress the epiglottis.

The ARYTENO-EPIGLOTTICI *arise* from the apices of the arytenoid cartilages, and the membrane around them, pass forwards and upwards to the sides of the epiglottis, and the adjacent folds of mucous membrane; the action of these fibres must be nearly similar to that of the former.

Mr. Hilton has described an inferior aryteno-epiglottidean muscle, as arising from the arytenoid cartilage, just above the chordæ vocales, thence expanding forwards and upwards, over the sacculus laryngis, and inserted broad into the side of the epiglottis; its action he concludes to be, to compress and alter the form of this pouch, diminish its cavity, and compress the adjacent submucous glands.

The group of laryngeal muscles now described are exceedingly complex, and their actions, individually and collectively, by no means easily understood. The articulations between the thyroid and cricoid cartilages, and the arytenoid, allow of such varied and composite motions, and the rima glottidis is so differently affected by each, even by the slightest alteration in the chordæ vocales, that it is difficult, if not impossible, to appreciate the influence of each individual muscle; neither can we suppose that any such isolated action occurs during life, but, on the contrary, in every vocal exertion it is more than probable all these muscles are in a state of action, and by that harmonious consent and sympathy which is every where maintained in groups of muscles associated for one common purpose, they mutually adjust their states of action and of relaxation, in such nicely balanced proportions, as to produce the effect required, and that this exquisite degree of arrangement is acquired by an education and practice of the muscles, of which the will is scarcely cognizant; for although these muscles are, to a great extent, voluntary, and belong to the system of

animal life, yet the will has not perfect control over their individual actions, neither can it separate those of one side from the opposite; nay, those fibres which are connected with the epiglottis, and which probably minister to the function of deglutition rather than to that of voice, appear wholly from under the influence of the will, and act in that spasmodic or convulsive motion, by which the food is hurried over the glottis and precipitated into the œsophagus.

The mucous membrane of the larynx is continued from that of the mouth, nose, and pharynx; it is soft, smooth, and of a delicate rose colour, the tint differing in different situations; it encloses both the anterior and posterior surfaces of its back part, descends into it, covers every irregularity of the surface, lines every depression, and is continued through the trachea and bronchial tubes into the vesicular structure of the lungs, thus constituting the anterior division of the great internal or gastro-pulmonary mucous membrane. As this membrane passes from the tongue to the epiglottis, it forms three folds which serve to connect the latter to the former, of these three *glosso-epiglottic* folds the centre or frænum is the principal; is continued all round the free surface of the epiglottis, and covers the entire of its posterior or laryngeal aspect; is reflected from its edges to the arytenoid cartilages, forming the aryteno-epiglottic folds or lateral boundaries of the opening of the glottis or larynx, these enclose some ligamentous fibres; as it descends it covers the chordæ vocales, lines the ventricles and sacculi laryngis, and the adjacent muscles, and finally becomes the lining coat of the trachea. It is perforated by numerous minute holes, the orifices of mucous ducts; the submucous tissue at the upper part is loose, and quickly admits of infiltration and swelling, or œdema, during inflammation, but below, as well as in the trachea, it is less in quantity, and of a more dense quality, therefore, inflammation is not succeeded so rapidly by submucous effusion, as it is by exudation of lymph upon its surface. Several mucous glands are connected with this membrane, the principal are to be found in the immediate vicinity of the ventricle and sacculus laryngis, and in the aryteno-epiglottidean folds of mucous membrane; these latter are not to be confounded with the cuneiform cartilages which also occupy this situation, and were looked upon by some as glandular. The epiglottidean gland or body, situated in front of the epiglottis, behind the os hyoides, and beneath the hyo-epiglottidean ligament, has been already considered. Some describe, but most probably incorrectly, the porous appearance presented by the laryngeal surface of the epiglottis, as derived from the orifices of its ducts.

The *openings* of the larynx are two, the superior or the glottis, and the inferior or the tracheal. Intermediate, and nearly midway within the larynx, is a very remarkable slit-like narrowing of its cavity, named the rima of the glottis or larynx, this is occasionally, but certainly inaccurately, called the lower opening of the larynx, to distinguish it the more certainly from the upper extremity or the glottis; the rima, however, is by no means the lowest part of the organ; it is the narrowest portion of

the air tube, and is the seat of the vocal function. The *superior opening* or the *glottis* is at the lower and anterior part of the pharynx, behind the epiglottis, and rather beneath the tongue; it is of a triangular form, the base anteriorly formed by the epiglottis; the sides are composed of the aryteno-epiglottidean folds of mucous membrane, and the apex, which is posteriorly notched or bifid, is formed by the appendices of the arytenoid cartilages. The sides are somewhat thickened and strengthened by the enclosed cartilages or bodies; the aspect of this opening is upwards and backwards; when dilated it is the widest part of the tube; it is momentarily, but perfectly, closed during deglutition; its size and form, therefore, admit of every variety of change.

The *inferior opening* of the larynx is always free, and nearly a perfect circle, formed by the lower border of the cricoid cartilage, which is connected and continuous with the trachea: its size or figure cannot be altered by position or muscular action.

The *rima glottidis* is an horizontal, slit-like passage, about three quarters of an inch below the glottis, bounded posteriorly by the mucous membrane connecting the bases of the arytenoid cartilages, and which covers a portion of the anterior surface of the arytenoid muscle, laterally by the chordæ vocales, chiefly the lower and by the inner side of the bases of the arytenoid cartilages, and their anterior processes, and anteriorly by the angle of the thyroid. We might regard the rima as double, one placed horizontally above the other; the upper one, between the upper or false chordæ vocales, wide, and not so distinct as the lower or true rima, which is between the true vocal chords, and which is narrow, distinct, and sharp; the form of this true rima in a state of repose appears, on a superficial view, to be triangular, but on closer examination it will be found contracted behind the centre, and in fact may be described as consisting of three distinct parts, an anterior, middle, and posterior. The anterior is the space enclosed between the true chordæ vocales, and extends from the angle of the thyroid to the anterior spurs of the arytenoids, the middle corresponds to the interval between the anterior thin edges of the arytenoid cartilages, and is the narrowest; the posterior is bounded by the internal sides of the bases of the arytenoid cartilages and the semilunar fold of mucous membrane, before alluded to as forming the posterior boundary of the rima; of these three spaces, the anterior is the most extensive, and of a compressed elliptical form; the antero-posterior diameter of this portion is often considerably increased by an excavation in the pomum Adami, or angle of the thyroid cartilage; this excavation is very remarkable in some of the larger ruminants. The middle division of the rima is the smallest, and the posterior is triangular, with an arched base, so that the three spaces, taken together, resemble the steel of a halbert in shape. The form of this opening, however, is variable, and depends on muscular action, as during every act of respiration, voice, or speech, it is subject to change in shape and size; thus in ordinary breathing it dilates during inspiration, and contracts in expiration. If the lateral crico-arytenoid muscles are alone thrown into forcible action, the arytenoid cartilages are

rotated upon their articulations, so as to cause their anterior edges and spurs almost to meet, and thereby nearly divide the rima transversely into two unequal openings. The muscular action which appears most completely to dilate the rima, is the joint action of the crico-arytenoid laterales and postici, the former having the power of drawing the cartilages forwards and outwards, the latter backwards; the two forces will act in the diagonal, which is backwards and outwards, and so convert the rima into a lozenge-shape with unequal sides, the two anterior being longer than the posterior. The muscles which appear most completely to close the rima, are the arytenoid and thyro-arytenoid acting in conjunction; the former approximate the bases of the arytenoid, and the latter, causing the chordæ vocales to meet, at the same time prevent the anterior edges of the arytenoids being turned outwards, a motion which, we have seen, the unassisted action of the arytenoid accomplishes.

Immediately above the true chordæ vocales, the larynx presents, on each side, a lateral dilatation called the *ventricle* or sinus of the larynx; this elliptical space is bounded above by the semilunar folds, before alluded to under the name of the superior or false chordæ vocales; the mucous membrane lining these cavities presents numerous small glands, the mucus from which is constantly expressed by the action of the thyro-arytenoid muscle, which forms the outer boundary of this space. From each ventricle of the larynx the mucous membrane is prolonged upwards in a thimble-like form, constituting a pouch or *cul de sac*, first noticed by Morgagni, also described by Cruveilhier, and more recently by Mr. Hilton,* under the name of *sacculus laryngis;* it communicates with the ventricle by a narrow valve-like opening, extends upwards and forwards between the superior chordæ vocales and the ala of the thyroid cartilage to a variable distance in different individuals; in some these sacs are small, and even indistinct, whereas in others, they ascend as high as the upper border of the thyroid cartilage, and in front of the epiglottis, so that two probes, introduced into these cavities, can be carried so far forwards and inwards as almost to meet in front of the latter: this, however, is by no means a constant conformation. Each sac is lined by a thin membrane, and covered by the aryteno-epiglottic and thyro-epiglottic muscular fibres; many mucous glands open on its surface, the secretion of which serves to lubricate the chordæ vocales.

The arteries which supply the larynx are derived from the superior and inferior thyroid, the former is a branch of the external carotid, the latter of the subclavian, the accompanying veins open into the adjacent venous trunks.

As the surface of the larynx possesses exquisite sensibility, and its muscles execute delicate and complex actions, it requires a proportionably free supply of nerves. The laryngeal nerves are four in number, two on each side, the superior and inferior, or the recurrent nerves; both are derived from the par vagum or pneumo-gastric, the former arises

* Guy's Hosp. Reports, No. V.

near the base of the cranium; the latter, on the right side, arises in the lower part of the neck, and on the left in the thorax, below the arch of the aorta. The superior nerve first sends some filaments to the pharyngeal plexus, and to the lower part of the pharynx; next to the thyro-hyoid muscle, and to the thyroid gland; it enters the larynx either above the thyroid cartilage, or by a foramen in its ala, and then sends its principal branches to the mucous membrane around the epiglottis, also some to the arytenoid muscles, to the thyro-arytenoid, and crico-arytenoid lateralis; a long filament also to the crico-thyroid muscle, and descending filaments to anastomose with the recurrent. The inferior laryngeal nerve first gives off several cardiac branches, some to the trachea, œsophagus, and pharynx, and finally is lost in filaments which supply the crico-arytenoideus posticus, arytenoidei, crico-arytenoideus lateralis, and thyro-arytenoideus, and also anastomose with the superior nerve. The precise functions of each of these nerves it is difficult to ascertain; it is probable they are each compound nerves, that is, both motor and sensitive, but in inverse proportions; the superior partakes of the sensitive endowment much more than the inferior, which is eminently motor, as may be inferred from the distribution of its branches being almost wholly to the muscles, and which opinion has been confirmed by experiments. Sensibility is more exalted at the upper than at the lower part of the larynx, with the obvious design of affording protection to the air passages against the admission of any noxious gas or foreign substance; and here, accordingly, the mucous membrane is largely supplied by the sensitive portion of the superior laryngeal nerve, which, from its connexions with the pharyngeal plexus, and thereby with the glosso-pharyngeal, pneumo-gastric, and sympathetic, will most intimately associate the apparatus for deglutition with this particular part of the larynx, while again the connexion between the superior and inferior laryngeal nerves maintains that sympathy, which, between the several parts of so complex an apparatus, must be necessary to the due exercise of the functions of the whole.

An extensive range of sympathetic connexions, interesting to regard in health, and important to reflect upon in disease, is maintained between the organ of voice, and the great vital functions of digestion, respiration, and circulation, through the medium of the laryngeal, cardiac, pulmonary, œsophageal, and gastric branches of the eighth pair, all of which are still further associated, not only with one another, but also with the great nervous centres, by their common and frequent communications with the great sympathetic or ganglionic system in the neck, in the chest, and in the abdomen. The reflex property of the nervous system is well exemplified in these nerves, as impressions made on the sensitive surface, and reflected to the medulla oblongata, are thence rapidly propagated to the motor nerves. The muscles of the larynx must be considered as belonging to the mixed class; in the production of the voice, with its various modifications, they are wholly under the influence of the will, and their actions are

improved by age, by practice, and by education; but in deglutition, in spasmodic closure, and in the respiratory movements, the dilatation, and contractions of the glottis, corresponding to inspiration and expiration, and the design of which is to oppose the very contrary tendency in the current of air to and from the lungs, in all these, and in many other conditions, these muscles are wholly involuntary. (For a more particular description of these nerves, see *Par Vagum*, in *Nervous System*).

The larynx in the male is better developed than in the female; the angle of the thyroid cartilage, the base of the os hyoides, and the anterior segment of the cricoid, are all much less prominent in the latter. In the infant it is proportionately small, the cartilages are weak, the chordæ vocales by no means strong and shining, the ventricles and laryngeal sacs scarcely visible, whereas the base of the os hyoides is large and prominent. The larynx undergoes but little change during the years of infancy and youth, and does not increase in the same ratio as other parts of the body; but at puberty, coeval with the changes in the reproductive organs, it is rapidly developed, so that in the course of a year it loses the infantine, and acquires the adult character, either male or female. Ossification commences at uncertain ages, seldom before thirty-five or forty years, but occasionally much earlier; it occurs first in the thyroid, next in the cricoid, and latest in the arytenoid cartilages, and is always more perfect in the male than in the female.

The larynx and trachea are subject to many *morbid* changes, of which the mucous membrane is most commonly the seat: inflammation of that lining the larynx is named cynanche laryngea, or laryngitis; of that lining the trachea, cynanche trachealis, or croup; in the latter case an exudation of lymph, or a false membrane, is usually formed in the trachea, in the former case, effusion of serum in the loose submucous tissue, or œdema of the glottis, is a frequent and often fatal effect; ulceration, the effect of inflammation, is not uncommon about the glottis, also diffuse inflammation ending in sloughing of the mucous and submucous tissues; syphilis and phthisis, too, occasionally induce ulceration in this part, and even involve the epiglottis and the arytenoid cartilages. All the cartilages, except the epiglottis, especially in men, are very prone to ossification; this can scarcely be regarded as disease; these bodies are also liable to inflammation, softening, ulceration, and change of form; the epiglottis is occasionally shrivelled and contracted, and even completely separated and discharged externally, or almost wholly absorbed, and yet deglutition may continue unimpaired. The articulations, particularly the crico-arytenoid, are subject to the same morbid changes as other synovial membranes; the muscles, without undergoing any obvious abnormal change in structure, are particularly liable to dangerous spasmodic affections, also to gout, rheumatism, and paralysis. Foreign bodies impacted in the lower part of the pharynx, or when engaged in the larynx, or when fallen into the trachea, may cause such suspension of respiration as to call for the operation of bronchotomy; suspended animation, also, from any cause, or any tumour in the fauces which impedes respiration, may require

the same means; this operation is two-fold, laryngotomy and tracheotomy; in the first the air tube is to be opened through the crico-thyroid ligament, in the second through the fourth, fifth, and sixth rings of the trachea.

# SECTION VII.

## DISSECTION OF THE DEEP MUSCLES OF THE NECK.

THESE muscles, which are seven in number on each side, form the third layer of the cervical muscles; they lie close to the vertebræ, and are exposed by removing the pharynx, larynx, cervical vessels, and nerves.

*Fig.* 18.*

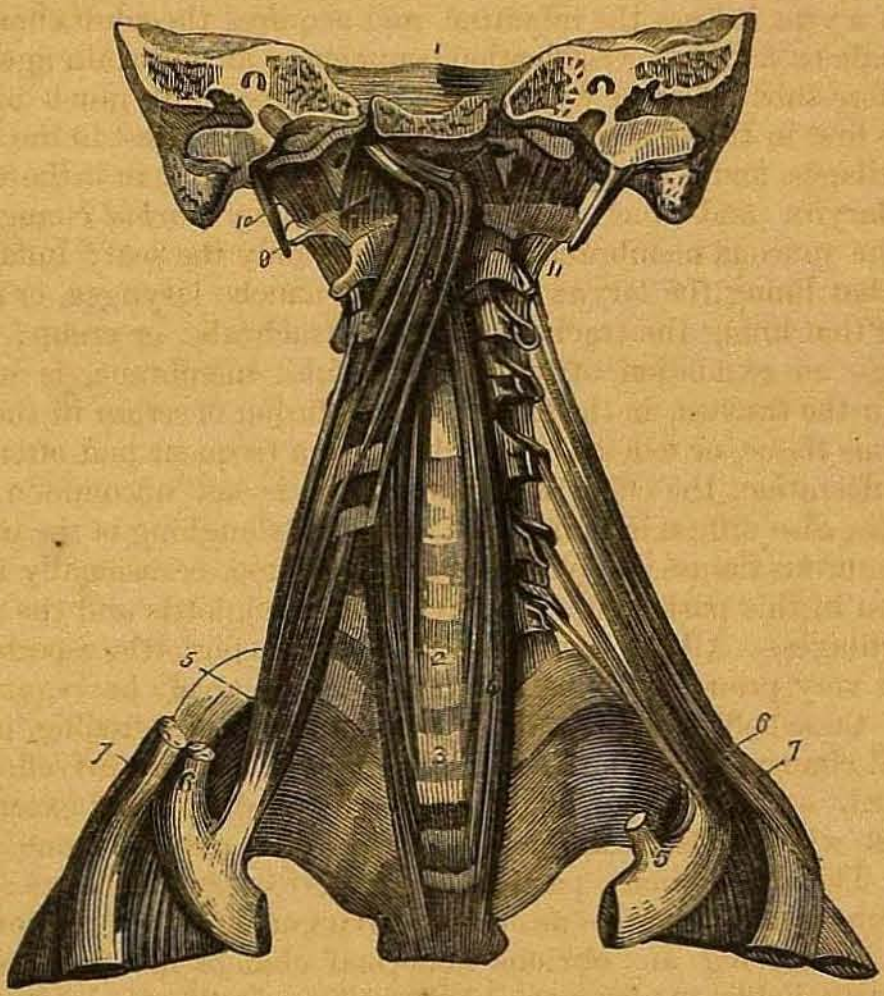


* The deep muscles of the neck. 1. A transverse section of the base of the skull. 2. The body of the seventh cervical vertebra. 3. The body of the first dorsal vertebra. 4. The longus colli muscle. 5. 5. The scalenus anticus muscle. 6. 6. The scalenus medius. 7. 7. The scalenus posticus. 8. The rectus capitis anticus major, drawn aside to shew, 9. The rectus capitis anticus minor. 10. The rectus capitis lateralis. 11. The first cervical inter-transversalis.

Longus Colli extends from the third dorsal vertebra to the atlas; it *arises* from the sides of the bodies of the three superior dorsal, and four inferior cervical vertebræ, from the intervertebral ligaments, also from the head of the first rib, and from the anterior tubercles of the transverse processes of the four last cervical vertebræ; the fibres ascend obliquely inwards, adhering to each bone in their course, and are *inserted* into the forepart of the first, second, and third cervical vertebræ. *Use*, to bend the neck to one side, and rotate the atlas on the dentatus; or, if both muscles act, to strengthen and steady the neck, or to bend it directly forwards. This muscle appears to consist of an inferior and superior portion; the first, *arising* from the bodies of the dorsal, is *inserted* into those of the inferior cervical vertebræ; the second, *arising* from the transverse processes of the third, fourth, and fifth cervical vertebræ, is *inserted* into the bodies of the first and second. These muscles, like most of those which adhere to the vertebræ, though long, yet consist of short fibres which pass from one bone to another, are generally intermixed with tendinous substance, and are irregular as to the number of the vertebræ to which they are attached. The pharynx, œsophagus, sheath of the cervical vessels and nerves, are loosely connected to them in front.

Rectus Capitis Anticus Major, long and flat, thick above and narrow below, *arises* by small tendons from the anterior tubercles of the transverse processes of the four last cervical vertebræ; they soon unite in a fleshy substance, which ascends obliquely inwards, and is *inserted* broad into the cuneiform process of the occipital bone. *Use*, to bend forwards the neck and head. This muscle lies behind the carotid artery and sympathetic nerve, and between the longus colli and scaleni, overlapping the former. Separate this muscle from its insertion, and we expose the following:

Rectus Capitis Anticus Minor, short and narrow, *arises* from the transverse process of the atlas, ascends inwards, and is *inserted* into the cuneiform process. *Use*, to bend the head forwards, and to one side, on the atlas; this muscle lies to the outer side, but is in part concealed by the last, and by the superior ganglion of the sympathetic, it lies on the atlanto-occipital articulation.

Rectus Capitis Lateralis, very short, *arises* from the transverse process of the atlas, ascends, and is *inserted* into the semilunar ridge or jugular process of the occipital bone, which extends from the condyle to the mastoid process. *Use*, with the last muscle it can bend the head forwards or incline it to one side. This muscle is external to that last described; it lies on the vertebral artery, and is covered by the jugular vein.

Scalenus Anticus, at the root of the neck, in part continuous with the rectus anticus major, simple and broad below, but divided into slips above, *arises* tendinous from the anterior tubercles of the transverse processes of the third, fourth, fifth, and sixth cervical vertebræ; the fibres descend obliquely forwards and outwards, form a flat muscle, which is *inserted* tendinous into the upper surface of the first rib, near

its cartilage. *Use*, to bend the neck forwards and laterally, also to elevate and fix the rib, as in inspiration. The phrenic nerve descends on the anterior surface of this muscle; the subclavian vein crosses its insertion; the transverse cervical vessels, the omo-hyoid and sterno-mastoid muscles, lie anterior to it; the subclavian artery and brachial plexus are behind it, and the vertebral vessels separate it from the longus colli.

SCALENUS MEDIUS, larger and longer than the last, *arises* from the posterior tubercles of the transverse processes of four or five inferior cervical vertebræ, by small tendinous fibres; these become fleshy, descend obliquely outwards and backwards, and are *inserted* into the upper surface of the first rib, behind the subclavian artery. *Use*, similar to the last. This muscle is covered by the brachial plexus, subclavian artery, and anterior scalenus.

SCALENUS POSTICUS *arises* from the posterior tubercles of two or three lower cervical vertebræ, descends behind the former, and is *inserted* into the upper edge of the second rib, between its tubercle and angle. *Use*, to elevate the second rib, to bend the neck to one side, and a little backwards. One or two branches of the brachial plexus sometimes separate this from the middle scalenus, at other times there is no distinction between them, excepting in their insertion; behind the posterior scalenus lie the transversalis and splenius colli, also the levator anguli scapulæ, which muscles cannot be examined at present. We shall next proceed to the dissection of the thorax.

# CHAPTER III.

## DISSECTION OF THE THORAX.

## SECTION I.

### OF THE MUSCLES ON THE ANTERIOR AND LATERAL PARTS OF THE THORAX.

THE thorax, or chest, is the middle division of the body, continuous with the neck above, and abdomen below; it contains the important organs of respiration and circulation, and serves as the basis of support and of attachment for the upper extremities; it presents an anterior or sternal, a posterior or dorsal, and two lateral or costal regions.

Make one incision through the integuments along the clavicle, a second from the upper end of the sternum to the ensiform cartilage, and from this point carry a third towards the shoulder; reflect the integuments and subjacent cellular membrane from within and from below, upwards and outwards, and thus the great pectoral muscle will be exposed, the dissection of which will be facilitated if its fibres be made tense by separating the arm from the side.* The integuments are thicker mesially than at either side, and more so in the male than in the female; in the former also they are more or less furnished with hairs. The superficial fascia is very variable, it adheres to the sternal and sterno-costal ligaments, but laterally is more loose and laminated; its deeper layer adheres to the pectoral muscle, continuous above with the superficial fascia of the neck, and below with that on the abdomen; near the epigastrium it is more dense, and binds down the recti muscles. The anterior region of the chest may be divided into three, the middle or proper sternal, and the two lateral or mammary regions; in the adult female these latter are of more importance, as they contain the mammary glands, which may now be examined.

The MAMMÆ, or BREASTS, are conglomerate glands, sympathizing in a remarkable manner with the uterus, and designed to secrete the

* The student of some experience, instead of removing the skin from this region, according to the above directions, may rather practise the operation of extirpation of the breast, which can be easily accomplished by two semielliptical incisions, one below, and the other above the gland, through the integuments, and nearly parallel to the fibres of the great pectoral muscle, from which the gland can be then easily detached, unless disease should have caused any very close adhesion.

milk, that fluid which is to serve for some time as the nutriment for the infant. The importance of these organs is shewn by the fact of a very large division of the animal kingdom being named, from their existence, "*Mammalia*;" this common character also implies, that all the females of this class are viviparous. In the human species, these glands are nearly symmetrical (the left is said to be very frequently larger than the right), and but two in number; in most other animals they are more numerous, generally in the ratio of two for each of the young they ordinarily bring forth, and are mostly placed on the abdomen; while in the human race they are situated on the chest, between the third and seventh ribs, so that the upper extremities can conveniently support the infant during lactation. The mammæ are also thoracic in the quadrumana and cheiroptera.

The integument of the breast is soft and smooth; in the young virgin of a pale white, or slightly bluish tint; but in the aged, or in those who have borne children, it becomes uneven, wrinkled, thicker, and darker: a little below the centre is the *nipple*, an organ which presents great variety of appearances, cylindrical or conical, very long, or short, and even so depressed that the infant's lips can with difficulty embrace it; it usually projects forwards and outwards, with a slight turn upwards; in the virgin it is a rounded cone and nearly smooth, but in the lactating woman it presents a flattened, cribriform surface, its extremity being the broadest part; in its centre are several depressions, or sometimes but one, in which are the small orifices of the milk ducts. It is surrounded by an areola, which in the young virgin is smooth, and of a pale red, or pinkish tint, but in the pregnant female, or in one who has suckled, it acquires a dark brownish hue. A number of nervous papillæ and small tubercles, sebaceous follicles, stud the skin both of the nipple and the areola, the secretion from which defends it from excoriation during lactation, the nipple being at that period very tender and irritable, and liable to cracks or fissures. The nipple consists of a reddish, cellular, and sensible tissue, traversed by the lactiferous ducts; in the opinion of some, this is erectile tissue, but on dissection it does not present the spongy, cavernous tissue of the true erectile, but rather a vascular, fibrous sort of dartoid structure, which may account for the occasional erection of this organ, and the sudden expulsion of fluid from its ducts: the nipple is securely connected to the gland by a fascia surrounding the ducts, derived from that of the breast. The mammary gland, when separated from the surrounding adipose substance, appears of an hemispherical form, convex in front, slightly concave behind, and separated by a thin fascia from the pectoral muscle, on which it can be freely moved; its circumference is thin and irregularly defined, some lobules being loose and scattered, and easily detached, particularly towards the axillary margin, hence it often presents an elliptical form in the transverse direction; its convex surface is uneven, deep cells, or alveoli, filled with adeps, which previously smoothed off these irregularities: there is less of this adipose matter around the nipple than more externally. The

gland is surrounded by a capsule of cellular membrane, very variable in strength and distinctness; it is prolonged into the gland, and separates and connects its lobules, vessels, and nerves: these processes (ligamenta suspensoria) are analogous to the septa in the testis; anteriorly they are connected to the skin, and posteriorly to the fascia of the great pectoral; thus they also serve to suspend and maintain the organ in its position; in the old or emaciated, these become weak and elongated, and the breast no longer occupies its original seat. This tissue in some is dense and fibrous, in others loose and cellular, on those differences depend, in a great degree, the firmness or softness of the organ; the interstices between these septa are filled with adeps, on the greater or lesser quantity of which the size of the organ in a great degree depends; owing to the same cause also the breasts in the male are occasionally found of considerable magnitude.

The interior of the gland presents a white, fibrous appearance, divisible into masses, without that granular arrangement common to other conglomerate glands; during lactation, however (the most suitable condition for the examination of the organ), the glandular grains are distinct, though very minute; these granules are united into flattened lobules, and these again into lobes; from each group of lobules a small excretory duct issues, evident by its white colour; this, if injected, can be traced back into fine divisions, each of which ends, or rather commences in the fine cœcal vesicle of which each granule is composed; these ducts converge towards the areola, increasing in size but diminishing in number; near the base of the nipple these terminate by five or six branches in small ampullæ, or reservoirs; in the human subject these scarcely deserve the name, but in most other mammalia they are of considerable size; in the cow, for example, they can contain a quart of fluid. From these ampullæ the straight tubes proceed, twelve to twenty in number, and open on the cribriform surface of the nipple by very small orifices; each duct is lined by an inflexion of the skin, which then assumes the mucous character, and is covered by a fine cellulo-fibrous tissue. Injection demonstrates, that the milk ducts have no valves, also that there is but little communication between them, or between the different lobes, as these latter can be injected with different coloured fluids; hence, the breast may be regarded as an aggregate of glands, each capable of independent action, and each also liable to isolated disease.

The mammary gland derives its arteries from the thoracic branches of the axillary, from the intercostals, and from the internal mammary, which inosculates with the epigastric. The veins preponderate, and are arranged in two orders; the deep set accompany and are closely connected to the arteries; the superficial are subcutaneous and well developed, especially around the areola, where they present a plexiform anastomosis, thence they pass towards the circumference of the organ to join the deeper veins; they can often be distinctly seen during life, and are very frequently much developed, and even varicose in certain

morbid conditions of the organ, also in elderly persons, or where the organ, once large, has become atrophied.

The nerves of the gland are derived from the intercostals, and from the brachial plexus, while the integuments receive some filaments from the cervical nerves.

The absorbents are very numerous; they are superficial and deep; the first proceed from the nipple and cutaneous glands; the second from the glandular structure; these pass into the axilla, enter the absorbent glands, and then ascend, some internal, others external to the axillary vessels; some open into the angle between the jugular and subclavian veins, others join the absorbents of the arm. From the sternal side of the nipple absorbent vessels also proceed, these pass through the intercostal spaces, into the mediastinum, and some absorbent glands situated there; some of these on the right side communicate with the absorbents of the liver; all these vessels finally end in the angles between the jugular and subclavian veins. Some absorbents also pass from the posterior surface of the gland through the pectoral and intercostal muscles, accompany the intercostal vessels round to the posterior mediastinum, and either enter into the absorbent glands in that region, or at once join the thoracic duct. In the breast these different sets of absorbents communicate together.

The mammary glands in the male deserve examination, and require same brief description. The size is very variable, in some not larger than a pea, in others they equal two inches. In those of effeminate appearance, or in whom the testes are atrophied, these glands have been found of the greatest size. The nipple and the areola present papillæ and tubercles, as in the female, but smaller and less vascular. The gland consists of minute cells, and numerous small conical ducts, branching through it, these end in straight tubes which open on the nipple, and the whole is supported by a fascia. Cases are on record of the breasts in the male being found as large as in the female, and of the ducts emitting a serous fluid with the appearance of milk; such cases explain the possibility of the male parent sustaining the infant, of which some well authenticated instances are recorded.

The female breast is the seat of many morbid changes, viz., inflammation and suppuration, either in the body of the gland, or in the cellular tissue around it or behind it, that is, between it and the muscle; enlargement; atrophy; tumours of various kinds, adipose, hydatid, cartilaginous, scirrhous, cancerous, &c.; some indolent, chronic, and innocuous, others more rapid in their progress, fungoid, and malignant; some involving the entire organ, others confined to certain lobes, or certain portions of the interlobular cellular tissue.*

Pectoralis Major, flat and triangular, *arises* somewhat tendinous from the sternal half of the clavicle, from the anterior surface of the sternum, fleshy from the cartilages of the third, fourth, fifth, and sixth true ribs, and from an aponeurosis common to it and the external

* See the invaluable treatise on this organ by Sir A. Cooper.

oblique muscle; the clavicular fibres descend, the sternal pass horizontally, and the costal ascend obliquely; all pass outwards in front of the axilla towards the humerus, into which they are *inserted* by a flat tendon into the anterior edge of the bicipital groove, and by an aponeurosis into the fascia of the arm; a line of cellular membrane separates the clavicular from the sternal portion; in some cases these

*Fig.* 19.*

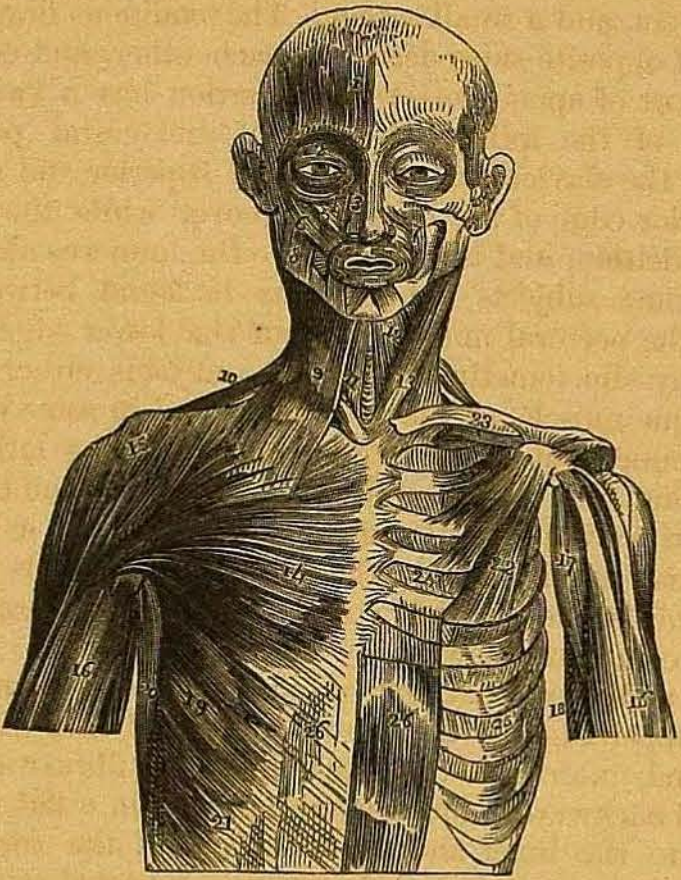

appear as distinct muscles. *Use*, the clavicular portion can raise the arm and draw it forward, the sternal can press it to the side, particularly if assisted by the latissimus dorsi, and the costal portion can draw it downwards and forwards: the whole muscle will draw the arm forwards and inwards on the chest; if the arm have been rotated outwards, it can roll it inwards, and so pronate the hand; if the arms

* The muscles of the anterior aspect of the trunk; on the right side the superficial layer is seen, and on the left side the deeper layer. 1. The frontal portion of the occipito-frontalis muscle. 2. The orbicularis palpebrarum. 3. The levator labii superioris alæque nasi. 4. The levator labii superioris proprius. 5. The zygomaticus minor. 6. The zygomaticus major. 7. The levator anguli oris. 8. The masseter. 9. The platysma myoides. 10. A portion of the trapezius. 11. The sterno-hyoid and thyroid muscles. 12. The upper portion of the omohyoid muscle. 13. The sterno cleido-mastoideus. 14. The pectoralis major. 15. The deltoid. 16. The biceps. 17. The coraco-brachialis. 18. The triceps. 19. The serratus magnus. 20. A portion of the latissimus dorsi. 21. A part of the obliquus externus abdominis. 22. The pectoralis minor. 23. The subclavius muscle. 24. One of the internal intercostal muscles. 25. One of the external intercostals. 26. The rectus abdominis; on the left side the sheath of the muscle has been removed.

be fixed, and this pair of muscles act, they will draw the ribs upwards and outwards, and thus, by enlarging the thorax, assist in inspiration. This muscle is covered by the skin, platysma, and mammary gland, and its insertion is partly concealed by the deltoid, it covers a portion of the sternum and of the true ribs, also the subclavian and lesser pectoral muscles, the coraco-clavicular ligament, the thoracic and axillary vessels and nerves. Between the clavicular portion of this muscle, and the anterior edge of the deltoid, is a space filled by cellular tissue, the cephalic vein, and a small artery. The tendinous fibres of the sternal portions of opposite sides decussate each other, and cover the sternum with a sort of aponeurosis; the insertion has a twisted appearance in front of the axilla, the sternal and costal portions being folded behind the clavicular, and *inserted* superior and posterior to it into the interior edge of the bicipital groove, while the clavicular is united to the deltoid, and is *inserted* into the humerus along with that muscle; in some subjects a bursa may be found between these two insertions of the pectoral muscle. From the lower edge of the costal portion a fleshy slip sometimes descends and joins either the rectus or external oblique muscle of the abdomen; and in some a strong muscular band connects it to the inferior margin of the latissimus dorsi; a tendinous band also has been observed to ascend from the upper edge of its insertion to the capsule of the joint. Make a perpendicular division of this muscle, reflect the edges, one towards the sternum, the other towards the shoulder; and the lesser pectoral and subclavian muscles come into view.

PECTORALIS MINOR, flat and triangular, *arises* from the external surface and upper edge of the third, fourth, and fifth ribs, sometimes from the second, external to their cartilages; the fibres ascend obliquely outwards and backwards, and converging, end in a flat tendon, which is *inserted* into the inner and upper surface of the coracoid process, near its anterior extremity, being here connected with the coraco-brachialis and short-head of the biceps; a band of this tendon frequently passes over this process through the triangular ligament, and is connected to it, or to the tendon of the supra-spinatus, or to the capsular ligament of the shoulder. *Use*, to draw the shoulder forwards, downwards, and inwards, also to assist the great pectoral in elevating the ribs in inspiration. This muscle is covered by the great pectoral, by the superior thoracic vessels and nerves, and partly at its insertion by the margin of the deltoid muscle, a few of its inferior fibres are covered only by the skin; it lies anterior to the serratus magnus, axillary vessels, and nerves. As this muscle does not ascend so high as the clavicle, it forms the inferior boundary of a small subclavicular triangular region, which is bounded above by the subclavian muscle and costo-coracoid aponeurosis, or ligament; internally by the ribs, and externally by the coracoid process: this space is traversed by the axillary vessels and brachial plexus of nerves; it is closed, or covered by the clavicular portion of the great pectoral; the cellular fissure between which and the deltoid leads into it; by expanding this, or by dividing

a portion of the great pectoral, this space can be opened sufficiently to expose the axillary artery for the purpose of tying it.

SUBCLAVIUS, small and round, *arises* by a flat tendon from the cartilage of the first rib, external to the rhomboid, or costo-clavicular ligament, soon becomes fleshy, and ascending outwards and backwards, is *inserted* into the external half of the inferior surface of the clavicle, extending as far outwards as the space between the conoid and trapezoid ligaments. *Use*, to draw the clavicle and shoulder forwards and downwards, also to elevate the first rib in inspiration, if the shoulder and clavicle be raised and fixed. This muscle is covered by the clavicle and great pectoral; it lies anterior to the axillary vessels and nerves, which separate it from the first rib; it is enclosed inferiorly in a thin but strong aponeurosis, which is attached to the cartilage of the rib, to the clavicle and subclavian muscle, from which it passes downwards and outwards to the coracoid process, arching across the great vessels, is then connected to that process, and to the tendon of the lesser pectoral; this fascia is called by some the *coraco-clavicular ligament*, by others, the *costo-coracoid;* it is sometimes very strong, and from the manner in which it is tensely extended over the vessels, and continued along them, especially the vein, it renders it difficult to feel the pulsation of the axillary artery below the clavicle, as also to separate it from the vein and nerves between which it lies.

SERRATUS MAGNUS, thin and broad, particularly anteriorly, placed behind the pectoral muscles and the axillary vessels, and between the scapula and the ribs, *arises* by eight or nine fleshy slips, from the eight or nine superior ribs; the fibres ascend obliquely backwards, and are *inserted* between the subscapular, the rhomboid, and levator anguli muscles into the base of the scapula, but particularly into the superior and inferior angles. *Use*, to depress the scapula and draw it forwards, particularly the inferior angle, and thus by rotating this bone on its axis, to raise the acromion process and the shoulder joint; when the upper extremity is fixed, this muscle can raise and draw outwards the ribs, so as to assist very considerably in inspiration. The serratus magnus lies on the ribs and intercostal muscles; also on a portion of the serratus posticus; external to it are the axillary vessels, the scapula and subscapular muscle; the trapezius, latissimus dorsi, and rhomboid muscles lie behind it, and the pectoral muscles are anterior to it; an abundance of loose cellular membrane connected to its surfaces allows it to glide on the ribs, and also facilitates the movements of the scapula upon it. The four superior digitations lie behind those of the lesser pectoral, and the four inferior, which are only covered by the skin, indigitate with the origins of the external oblique. If the clavicle be separated from the sternum, and the scapula pulled from the side, this muscle will then become tense, and in this state it appears to consist of three portions, which differ in structure and in form: the *superior* is a thick, short, and strong fasciculus, somewhat square, passing from the two first ribs beneath the axillary vessels and brachial plexus, to the superior angle of the scapula; its flat surface is directed up-

wards, and lies on a plane anterior to the next or *middle division*, which is very thin, consisting of but few fleshy fibres, connected together by an aponeurosis. This portion is of a triangular form, the apex

*Fig.* 20.*

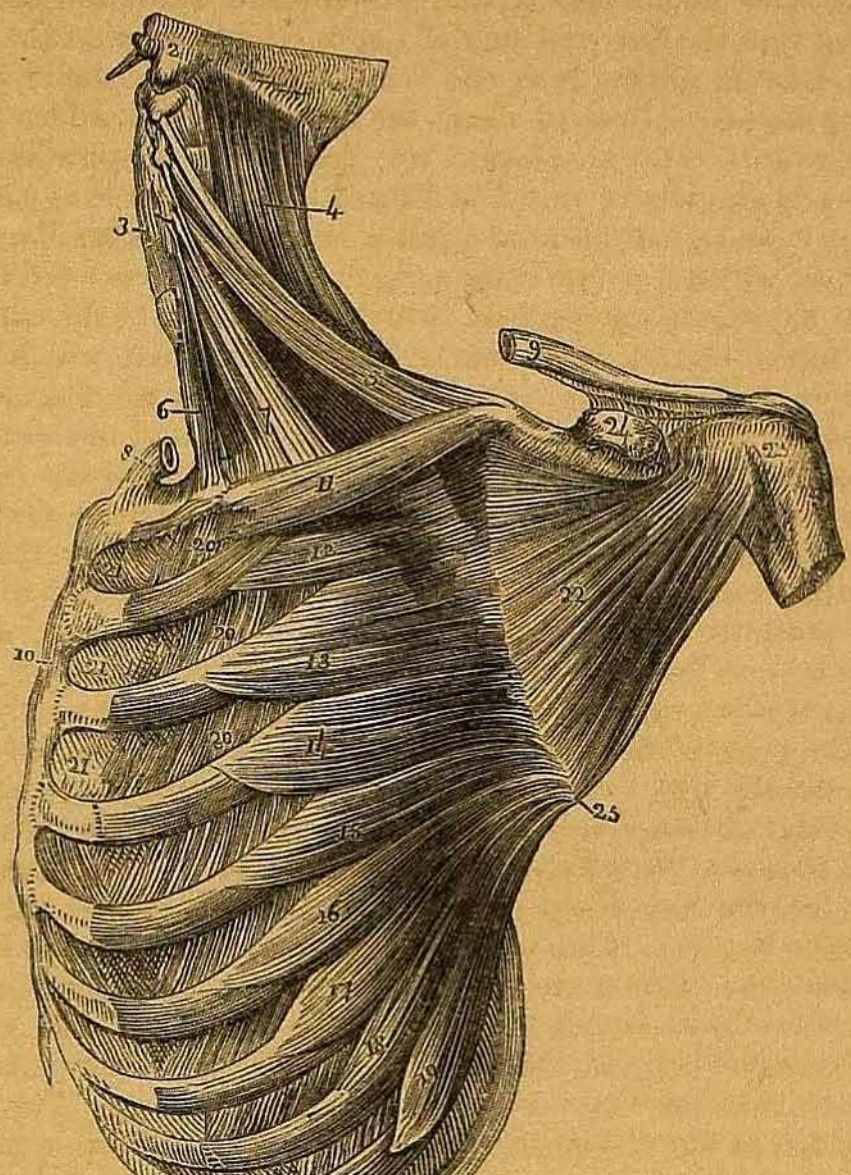

attached to the third and fourth ribs, the base to the basis of the scapula, not always to the bone, but sometimes to a strong tendinous cord, or arch, which extends along this line from the superior to the inferior

* A lateral view of the thorax and neck. 1. A portion of the occipital bone. 2. The mastoid process of the temporal bone. 3. The anterior surface of the bodies of the cervical vertebræ. 4. The deep layer of muscles of the posterior cervical region. 5. The levator anguli scapulæ. 6. The anterior scalenus muscle. 7. The middle and posterior scaleni. 8. The internal portion of the clavicle which has been sawn across. 9. Its external portion. 10. The sternum. 11. 12. 13. 14. 15. 16. 17. 18. 19. The costal attachments of the serratus magnus. 20. 20. 20. The external intercostal muscles. 21. 21. 21. Portion of the internal intercostals. 22. The subscapular muscle. 23. The head of the humerus. 24. The coracoid process of the scapula. 25. The inferior angle of the scapula.

angle and which is also common to the insertion of the greater rhomboid; in some two such tendinous arches exist, and in others none. The third, or *inferior* division of the serratus is the strongest and most extensive; it is radiated or triangular; the apex thick and fleshy, attached to the inferior angle of the scapula; the base expanded in thin and long fasciculi on the ribs: to this portion the external respiratory nerve is chiefly distributed. The serratus may be again examined when dissecting the muscles on the back of the trunk.

INTERCOSTALES are twenty-two in number on each side, eleven external and eleven internal; the *external* commence at the transverse processes of the dorsal vertebræ, *arise* from the inferior edge of each rib, descend in fasciculi obliquely forwards, and are *inserted* into the external lip of the superior edge of the rib beneath, and terminate a little behind the costal extremity of the cartilages; an aponeurosis, the fibres of which run in the same direction, supply their place as far as the sternum. The *internal intercostal muscles* take an opposite direction, and decussate the former; they commence at the sternum, and are discontinued at the angles of the ribs; they *arise* from the inner lip of the lower edge of each cartilage and rib; the fibres, paler and shorter than those of the external, descend obliquely backwards, and are *inserted* into the inner lip of the superior edge of the cartilage and rib beneath. *Use*, both laminæ cooperate to raise the ribs, the first rib being fixed by the scaleni. The intercostal muscles, in elevating the ribs, also evert their lower edges, and twist them at their vertebral and sternal ends, and thus assist in inspiration by enlarging the chest transversely, and from before backwards. The internal layer lies on the pleura, and is separated from the external by the intercostal vessels and nerves; the external layer is connected to the pleura only in the space between the angles of the ribs and the vertebræ. At the posterior extremity of the external intercostal muscles, there are the following twelve small muscles, which, however, may be seen more fully when the muscles of the back have been dissected.

LEVATORES COSTARUM *arise* narrow and tendinous from the extremity of each dorsal transverse process, descend obliquely outwards, and are *inserted* broad into the upper edge of the rib beneath, between its tubercle and angle; their name denotes their *use*. They are parallel to, and frequently appear as a portion of the external intercostals; the first levator is short, and arises from the last cervical vertebra; the inferior increase in length and size. These muscles are arranged by some, and not improperly, among those of the back. Behind the sternum are a pair of small muscles, which cannot be seen until this bone is removed; we describe them now, although their dissection may be postponed until the thorax has been opened.

TRIANGULARIS STERNI, or sterno-costalis, *arises* from the posterior surface and edge of the lower part of the sternum, and from the xiphoid cartilage; the fibres ascend obliquely outwards, the inferior pass transversely, *inserted* into the cartilages of the fourth, fifth, and sixth ribs. *Use*, to depress and draw backwards the cartilages of the

ribs, so as to assist in expiration. These muscles lie on the pleura, pericardium, and diaphragm, are covered by the sternum, cartilages of the ribs, and mammary vessels. They antagonize the external intercostals, to whose fibres, however, they are parallel, but they arise from the more fixed, and are inserted into the more moveable part of the cartilage, and this fact also explains the cause of the external intercostals terminating at the ends of the ribs, and not continuing as far forwards as the sternum. The mechanism of respiration shall be further considered when the diaphragm has been examined (see dissection of it). In connexion with the muscles of the thorax, the student should study the anatomy of the axilla.

# SECTION II.

## DISSECTION OF THE AXILLA.

THE *Axilla* is a conical, or rather a triangular, pyramidal-shaped cavity, the apex superiorly at the coracoid process and clavicle, the base below, between the pectoralis major, and the latissimus dorsi muscles, and formed by the skin and a thick fascia; it is bounded anteriorly by the great and lesser pectoral muscles, internally by the serratus magnus and the ribs, externally by the scapula, subscapular muscle, and the upper part of the humerus, and posteriorly by the serratus, latissimus dorsi, and teres major muscles. The internal and posterior walls unite in an acute angle along the base of the scapula; this angle is completely closed by the serratus muscle; the anterior and internal, or thoracic boundaries also unite in a very acute angle, which is prolonged upon the thorax, beneath the pectoral muscles; the external angle is truncated, and presents a somewhat round surface, formed by the coraco-brachialis muscle, the humerus, and the shoulder joint; the axillary artery can be compressed against the lower part of this surface. The axilla contains several lymphatic glands, vessels, and nerves, and a quantity of loose cellular and adipose tissue, which is continued from the neck beneath the clavicle, and which often presents a watery reddish appearance. When the pectoral muscles have been divided, and some cellular membrane removed, the *axillary vein* first appears; at the upper part of the axilla, this vessel is very large, and is internal and anterior to the artery, connected to it by compact cellular tissue; it here rests upon the first intercostal muscle, the second rib, and the upper part of the serratus magnus; the coraco-clavicular aponeurosis adheres to, and is continued on its anterior surface, it is also crossed by the thoracic arteries and nerves; through the rest of the axilla it approximates the artery, and descends more directly in front of it, though inclined to its inner side, and separated from it by the anterior branches of the brachial plexus of

nerves; it receives the basilic vein below, the cephalic above, and the subscapular, circumflex, and thoracic branches intermediate.

The *axillary artery* may be next seen, taking an oblique course downwards and outwards through this space, larger above, and close to the thorax, smaller below, and nearer to the arm; thoracic and acromial branches are derived from it in front, the circumflex and subscapular behind; all these branches, and even the trunk itself, are liable to varieties in size, number, position, and distribution. (See *Vascular System*). At the upper part of the axilla, the *brachial plexus of nerves* is seen behind, and to the outer side of the artery, its cords collected into a bundle; posterior to the lesser pectoral muscle it is somewhat unravelled, and its branches are entangled around the artery; it then divides into axillary and brachial nerves, the former are the anterior and posterior thoracic and subscapular, the latter are the internal, cutaneous, median, ulnar, external or musculo-cutaneous, musculo-spiral, and articular or circumflex. Two or three filaments from the superior intercostal nerves traverse this region transversely, in front of the serratus, and are entangled with the thoracic vessels and nerves. Descending on the forepart of the serratus magnus, behind the great vessels and nerves, is the external respiratory nerve, a branch derived from the first roots of the plexus in the supra clavicular region. At the lower part of the axilla, the artery may be observed in general to lie between the two roots of the median nerve, with the external cutaneous to its outer or humeral side, and with the ulnar and internal cutaneous to its inner or thoracic side, while posterior to it are the musculo-spiral and articular nerves. The general distribution of these branches will be noticed in the dissection of the upper extremity, and for their particular description see *Anatomy of the Nervous System.*

The lymphatic vessels in this region are numerous and distinct, the principal set ascend from the arm; these are joined by several from the exterior of the thorax, from the mammary region, and from the inferior posterior part of the neck. The lymphatic glands are connected to the axillary vessels by the small branches which supply them; one series of these lies posterior to the edge of the pectoral muscle; from this a chain continues up to the coracoid process, and beneath the clavicle to the glands in the neck; another series lies on the subscapular muscle, and several are scattered indifferently through the axilla. In cases of malignant affections of the breast, some of these glands are often found diseased and require to be removed by the surgeon, at the time of extirpating the former. These glands also, together with the surrounding cellular membrane, are very subject to acute inflammation and suppuration, large collections of pus are the result, which, if not opened sufficiently early, may prove troublesome, and even dangerous; by pressure on the nerves and lymphatics, œdema and debility of the arm are induced, or the fluid may burrow between or beneath the muscles, and, by compressing the chest, distress the respiration, or it may even open through one of the intercostal spaces into the cavity of the pleura.

# SECTION III.

## DISSECTION OF THE CAVITY OF THE THORAX.

The thorax is situated at the upper and anterior part of the trunk; it contains the lungs, the organs of respiration; the heart, the chief agent in the circulation of the blood, also several nerves and vessels

*Fig.* 21.

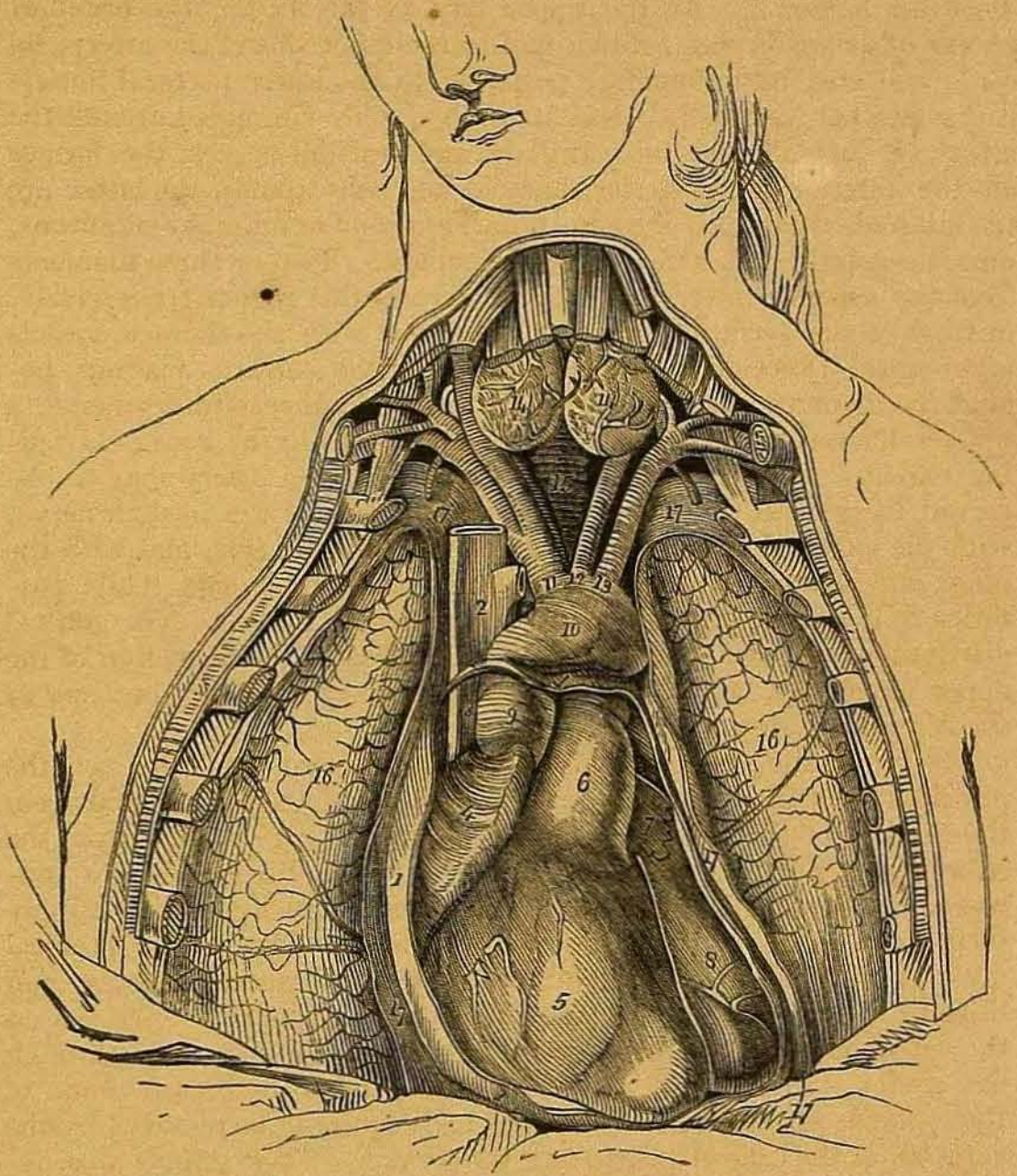


* The situation and relations of the lungs, the heart, and the great vessels in the thorax. 1. 1. The pericardium cut open and its anterior portion removed, in order to display the heart. 2. The superior vena cava. 3. The same vessel covered by the pericardium, descending to 4. The right auricle of the heart. 5. The right or pulmonic ventricle of the heart. 6. The pulmonary artery arising from the right ventricle. 7. The appendix of the left auricle. 8. The left or aortic ventricle of the heart. 9. The ascending portion of the arch of the aorta. 10. The transverse portion. 11. The arteria innominata. 12. The left carotid. 13. The left subclavian. 14. 14. The thyroid body or gland. 15. The trachea. 16. 16. The lungs. 17. 17. The pleuræ.

passing to and from the heart, and through the cavity. This region is bounded anteriorly by the sternum and costal cartilages, laterally by the ribs and intercostal muscles, posteriorly by the vertebræ and angles of the ribs, inferiorly by the diaphragm, superiorly by the several muscles and fasciæ connected to the clavicle, first rib, and sternum, and by the different parts passing into and out of the cavity. The thorax, viewed externally, presents a very different form before and after the upper extremities have been detached from it; in the former state it appears of great transverse width above, and narrow below; whereas in the latter condition, it is seen to be very contracted above, and expanded below. The thorax may be compared to a section of a cone, the posterior fourth being removed, the three anterior parts retained and united to each other. The axis of the cavity is oblique from above, downwards, and forwards; the base of the thorax is also oblique from before, backwards, and downwards, and the apex on the contrary is oblique from behind, forwards, and downwards; hence the perpendicular diameter of the thorax is much greater posteriorly than it is behind the sternum. The apex of the thorax is somewhat truncated, and presents an oval opening, longer transversely than from before backwards; this, the *superior orifice of the thorax*, is bounded anteriorly by the upper edge of the sternum and interclavicular ligament, posteriorly by the last cervical and first dorsal vertebræ, and laterally by the first ribs; the several important parts which pass through this opening shall be noticed afterwards. The inferior circumference of the thorax is five or six times more extensive than the superior; it is bounded by the xiphoid, the last true and all the false costal cartilages, and by the last dorsal and first lumbar vertebræ; its longer diameter is also transverse. Open the cavity by dividing the cartilages of the ribs on each side of the sternum, and raising the latter from below upwards; if we look under the sternum as we thus slowly raise it, we perceive that space called *anterior mediastinum* to be gradually developed, from the right and left pleuræ separating from each other as we tear the loose cellular membrane, which naturally connects these membranes and the pericardium to the posterior surface of the bone; when the sternum is removed, this region is fully exposed; it is described as being of a triangular form, the base, the sternum; the sides, the pleuræ, converging behind, so as nearly to touch each other; the apex, the small portion of pericardium left uncovered by the pleuræ; naturally, however, all the parts within the thorax are so closely applied to the parietes, that no space or cavity of a defined form, like that assigned to the anterior mediastinum, can truly be said to exist.* The dissector, however, may cause this space to ap-

* For the purpose of examining the morbid appearances after death, the cavities of the thorax and abdomen are generally opened at the same time; an incision, carried from the top of the sternum to the symphisis pubis, through the integuments, muscles, and peritoneum, will bring the latter cavity into view; next let the skin and muscles covering the front of the thorax be turned back, which will expose the cartilages connecting the ribs with the sternum; immediately at their point of connexion with the bone, these are to be cut; in doing this take care not to wound the viscera within.

pear more distinct by the following precaution; before you divide the cartilages, push your fingers from the abdomen behind the sternum, and break down the cellular connexions between it and the pleuræ, then cut the cartilages very near the sternum, and raise the latter; without this precaution before dividing the cartilages, the pleuræ, particularly the right, will be in almost every instance laid open, and so the appearance of the anterior mediastinum injured. This region in general inclines a little to the left side below, in consequence of the left pleura being more attached to the pericardium, which lies rather to the left of the middle line, whereas the right pleura is connected to the sternum in a vertical line; the anterior mediastinum is wider superiorly and inferiorly than in the centre, hence some compare it to the letter X, and describe it as consisting of two triangular spaces, their apices joined in the centre, the base of one towards the neck, and that of the other towards the diaphragm; the superior portion is larger in the fœtus, contains the origins of the sterno-hyoid and thyroid muscles, and the remains of the thymus gland; inferiorly there is much loose cellular membrane, which leads from the neck to the abdominal muscles, also lymphatic glands, and close to the sternum are the mammary vessels, and the triangularis sterni muscle of the left side. Next examine the organs on each side of the thorax; these are the lungs and their investing membranes the pleuræ; in almost all respects these organs are similar on the right and left side, and therefore either may be selected for examination; for this purpose lay open one side, suppose the right, of the thorax, by sawing through the ribs about their centre, and removing their anterior portion; the first rib may be left uninjured; thus the cavity of the right pleura will be opened, its glistening surface seen, with the lung lying collapsed; or having divided, with the saw, six or seven ribs at their angles, and cut through their cartilages near the sternum, the intervening bones may be raised by a careful dissection from the pleura, without opening the cavity of the latter.

The *pleuræ* are serous membranes, their internal surface is smooth, polished, and free; their external surface is connected by fine cellular membrane to the parietes of the thorax, and to the tissue of the lungs, over which they are reflected. That portion of each which invests the lungs is called *pleura pulmonalis*, and that which is connected to the parietes *pleura parietalis* or *costalis*, the latter portion of the membrane is much more dense and strong than the former; each pleura is a shut sac, of a conical shape, and contains only the serous vapour it exhales; for although the lung appears within the cavity, it is yet really external to it or behind it; internally each pleura pre-

In some old subjects, where the cartilages of the ribs are in some degree ossified, a saw must be employed; all the cartilages, except those of the first rib, being divided, the sternum may be raised like the lid of a box, and a very convenient hinge is made by cutting the articulation between the first and second pieces of the sternum on the inside, opposite the second rib; the figure of the thorax will thus be preserved, and a sufficient view be obtained of its contents.

sents one continuous surface, which can be traced throughout its whole extent; thus we can perceive that the right pleura passes from the

*Fig.* 22.*

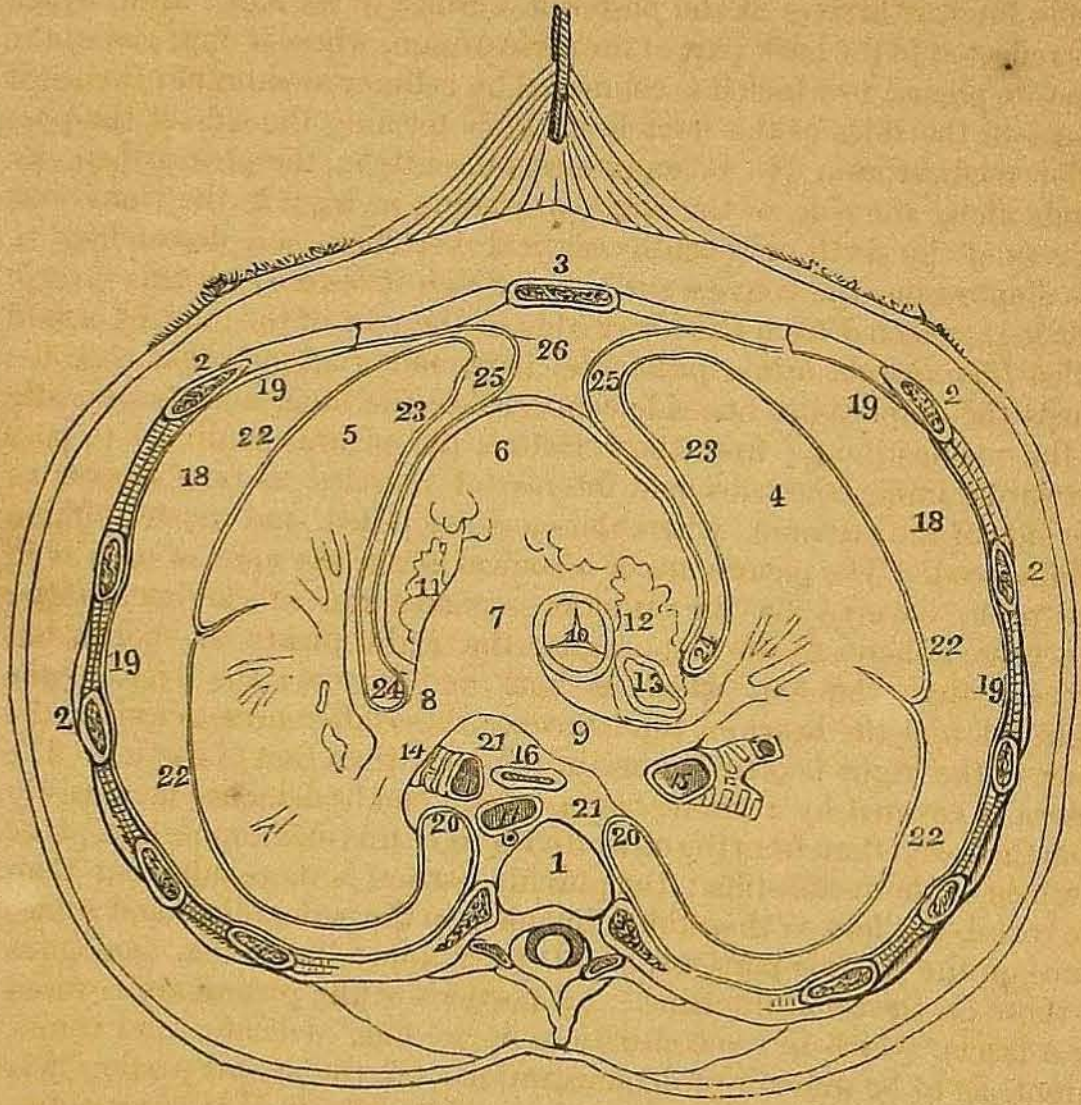


* A transverse section of the thorax opposite the fifth dorsal vertebra, to shew the relation of the pleura to the walls of the chest, to the lungs, and to the pericardium. 1. The body of the fifth dorsal vertebra. 2. 2. Sections of the ribs. 3. A section of the sternum. 4. A section of the right lung. 5. Of the left lung. 6. The anterior surface of the heart, covered by the serous layer of the pericardium. 7. The trunk of the pulmonary artery issuing from the right ventricle of the heart. 8. The left, and 9. The right branch of the pulmonary artery. 10. A section of the aorta immediately above the sigmoid valves. 11. A part of the left, and 12. Part of the right auricle. 13. The superior vena cava. 14. The left bronchus. 15. The right bronchus. 16. The œsophagus. 17. The thoracic aorta. 18. 18. The cavity of the pleura. 19. 19. The costal layer of the pleura. 20. 20. The pleuræ passing from the posterior walls of the chest, over the sides of the vertebral column to the posterior surface of the root of the lungs, leaving between them the interval, 21. 21. called the posterior mediastinum. 22. The pulmonary layer of the pleura, covering the outer surface of the lung, and sinking into its fissures. 23. 23. The same membrane covering the internal surface of the lung. 24. 24. The pleuræ, passing from the internal surface of the lungs, over the anterior surface of their roots, to attach itself to the sides of the pericardium. 25. 25. The pleura leaving the pericardium to reach the posterior surface of the anterior wall of thorax, where it is continuous with 19. the costal layer. 26. The anterior mediastinum.

back of the sternum to form the side of the anterior mediastinum, and, arriving at the forepart of the pericardium is continued along the side of that bag as far back as the root of the lung, whence it is reflected over the anterior surface of this organ, sinking into its fissures, and connecting all its lobules to each other; having thus invested the whole lung, it arrives at the posterior surface of its root, from which it is reflected to the back part of the pericardium, where it approaches the opposite pleura, to which it is connected by cellular membrane; thence it passes to the sides of the vertebræ, thus forming the side of the posterior mediastinum (to be examined presently); the pleura then expands along the side of the spine, ascending as high as the transverse process of the sixth or seventh cervical vertebra, and descending to the diaphragm, the convex surface of which it covers; on this muscle also it is reflected from the lower edge of the root of the lung by a fold called *ligamentum latum pulmonis*, loose and triangular, the base towards the diaphragm, one side connected to the lung, and the opposite to the mediastinum; from the vertebræ, the pleura continues to pass outwards, lining the ribs and intercostal muscles, as far forwards as the side of the sternum, where the sac was opened, and the description commenced. The pleuræ are of a conical form, the apex of each is in the neck, covered by the anterior scalenus and subclavian artery; the base adheres to the diaphragm; the right pleura is shorter but broader than the left, which is long and narrow; the liver on the right side and the heart on the left cause these differences to exist; the apex of the right is often higher in the neck than that of the left. The pleura is covered by a strong fascia, which can be detached more easily from the costal than from the other divisions of this membrane, except the confines of the mediastina; the phrenic portion is more adherent than the costal, but less so than the pulmonic; on the pericardiac, and sometimes on the phrenic portions, small, fatty appendices exist, analogous to those on the colon intestine. All portions of the pleuræ are covered by a fascia, which in some situations is so fine, delicate, and transparent, as to be difficult of demonstration; on the costal portion it is very strong, on the phrenic less so, on the mediastinal it is very distinct, and even appears in some places continuous with the fibrous layer of the pericardium, though separated from it in others, as in the line of the phrenic nerves; beneath the pulmonic, in a perfectly healthy lung, it is extremely thin, though strong, resisting, and elastic, and can be exposed by very cautiously scratching off the serous layer from a small portion of lung distended and held tense; the transparent fascia can then also be dissected off the air-cells; therefore, strictly speaking, the pleuræ are, like most other serous and synovial membranes, fibro-serous, and consist of three layers or tissues; the external or the adherent layer is fibrous, the middle a fine, subserous, cellular tissue, and lastly, the serous lining. In the costal, phrenic, and mediastinal portions, these three components can at all times be made distinct, and equally so in the pulmonic portion on a lung which has been long affected with chronic inflammation. This fibrous struc-

ture of the pleura serves to explain the pain of pleurodyne and pleuritis, also, as Cruveilhier remarks,* why external abscesses so seldom perforate into the cavity of the chest, and why pleuritic effusions are so long retained before they point externally; also, as Stokes† has observed, the rarity of perforations of the pleura pulmonalis in ulcerations of the lung, which have approached so near the surface as to be bounded only by this fibro-serous investment. The *uses* of the pleuræ are to serve as a fine, yielding, elastic, and insulating integument to the lungs, to strengthen the diaphragm, and to complete the walls of the thorax, while the lubricating serous exhalation which constantly moistens the polished, and at all times contiguous surfaces of their visceral and parietal layers, facilitates those mechanical changes in the form of the lungs, and in the condition of the walls of the chest, which are requisite in the respiratory process. The two pleuræ have been resembled to two bladders placed nearly parallel to each other, not having any communication, but touching each other along the mesial line; this juxta-position of the two pleuræ between the sternum and vertebræ forms a sort of partition between the right and left side of the thorax; this partition is called mediastinum; it consists of course of two laminæ, right and left, connected anteriorly to the sternum, posteriorly to the spine; these laminæ are separated from each other in three situations, in order to enclose certain organs, so that the mediastinum is divided into, first, the anterior part, or anterior mediastinum, which has been already examined; second, the middle part, or middle mediastinum, which contains the heart and pericardium, with the phrenic nerves, the ascending aorta, and superior vena cava, the division of the trachea, and the pulmonary arteries and veins; and third, the posterior mediastinum, which lies in front of the vertebræ, and which the student may next examine.

The *posterior mediastinum* extends in a vertical direction from the third to the tenth dorsal vertebra, behind the pericardium and roots of the lungs, and in front of the spine; to obtain a view of the parts contained in it, draw the right lung forward, and to the left side, and make a perpendicular division of the right pleura, between the root of the lung and the spine. This region is described as being of a triangular form, the base posteriorly, the pleuræ forming its sides, and the pericardium its apex; like the anterior mediastinum, however, it has naturally no exact figure, the pleuræ being folded round the organs which lie between them. In the posterior mediastinum we find the œsophagus and eighth pair of nerves, the thoracic duct, vena azygos, descending aorta, splanchnic nerves, several lymphatic glands, and a considerable quantity of fine, loose, cellular membrane; the division of the trachea is immediately in front of this space, just at its commencement. The *œsophagus* is anterior to the other parts in the posterior mediastinum; this tube having passed behind the left division of the trachea, enters this space, and descends obliquely forwards behind the

* Anat. Descrip. t. 2. p. 830.

† Diseases of the Chest, p. 460.

pericardium and before the aorta; above, it lies to the right side of this vessel, but below it is to the left; in the lower part of its course it is surrounded by branches of the eighth pair of nerves, and, enlarging a little, it perforates the fleshy part of the diaphragm, opposite the ninth or tenth dorsal vertebra, and joins the stomach. The *eighth pair of nerves* having passed behind the roots of the lungs, attach themselves to the œsophagus, and form by their branches a plexus around it (*the œsophageal plexus*); the left nerve then descends on the fore, and the right on the back part of this tube to the stomach.

The *thoracic aorta* enters this region about the fourth or fifth dorsal vertebra, and descends along the spine, to its left side above, but nearly in the mesial line below; about the eleventh or twelfth dorsal vertebra it passes between the crura of the diaphragm into the abdomen; in this course the aorta furnishes the following branches: two or three bronchial arteries, which go to the lungs, as many œsophageal branches, and nine or ten pair of intercostal arteries, whose name implies their destination.

The *vena azygos* commences in the abdomen by a small branch from one of the superior lumbar veins, enters the thorax behind the right side of the posterior mediastinum, covered by the right pleura; and opposite the third or fourth dorsal vertebra it arches forwards over the root of the right lung, and opens into the superior vena cava, as that vessel is entering the pericardium. The vena azygos in this course receives the bronchial, œsophageal, and intercostal veins; those of the left side often unite into one branch, which, passing behind the aorta, joins opposite the sixth or seventh vertebra, the principal trunk on the right side.

The *thoracic duct* also commences in the abdomen, on the second or third vertebra behind the aorta, in a sinus, called receptaculum chyli; contracting in size it enters the posterior mediastinum, along with, and to the right side of the aorta; it ascends close to this vessel, between it and the vena azygos, imbedded in fat, and opposite to the fifth or sixth dorsal vertebra it attaches itself to the back of the œsophagus, runs obliquely along it, behind the arch of the aorta, to the left side, and ascends in the neck behind the left carotid artery and jugular vein, as high as the sixth cervical vertebra; it then bends downwards and outwards, and enters the left subclavian, just before it joins the jugular vein. The coats of the thoracic duct are so fine and thin, that frequently it is difficult to see or trace this vessel, unless previously injected or inflated from the abdomen; it is often found divided into two or three branches which unite again. (For a more particular description of it, see *the Anatomy of the Absorbent System*). The *splanchnic nerves arise* by four or five filaments from the dorsal ganglions of the sympathetic nerve; the first is from the fifth or sixth ganglion, the rest arise in succession below it; all unite and form the splanchnic nerves, which descend obliquely forwards on each side of the aorta, along with which they enter the abdomen, where each terminates in a large ganglion, termed *semilunar*; these two ganglions are joined together

by numerous branches, which constitute the *cœliac* or *solar plexus*, from which the greater number of the abdominal viscera are supplied with nerves. In the dissection of the posterior mediastinum, the sympathetic nerve is also seen on each side; it does not lie in this space, but descends external to it, between the pleuræ and the heads of the ribs; opposite each intercostal space it forms a ganglion, from which some branches pass to join the dorsal spinal nerves, others to form the great splanchnic; and at the lower part of the thorax, two or three filaments often unite to form a small nerve, called *lesser splanchnic*, which enters the abdomen, behind or through the crura of the diaphragm, and joins the renal plexus of nerves. The sympathetic on each side enters the thorax close to the neck of the first rib, where it forms a large ganglion; it passes from this cavity by a very small filament, between the crus of the diaphragm and the psoas magnus, into the abdomen, where it again enlarges considerably. (See *the Anatomy of the Nervous System.*) The division of the trachea, the last part of any importance connected with the posterior mediastinum, does not, strictly speaking, lie in this space, but, like the heart and great vessels, it is in the middle mediastinum, or between the anterior and posterior; this tube can be more conveniently examined afterwards, when we are dissecting the parts which pass through the upper opening of the thorax. Next examine the lungs.

The *lungs* are situated at either side of the spine, and, when distended with air, as they constantly are during life, they so exactly fill each side of the thorax that the pleura pulmonalis and costalis are always in such perfect apposition, that there never can be any intermediate cavity; they are of a conical figure, the apex round and often irregularly bulged, when distended rises into the neck to a height varying from one to two inches above the level of the first rib, which bone occasionally indents it anteriorly; the apex of the right usually rises higher than that of the left; the base concave, particularly of the right, accurately moulded to the convexity of the diaphragm, presents an inclined plane from before backwards, hence the vertical diameter of the lungs is much longer behind than before; the diaphragm is so convex on the right side, that a sort of angular gutter exists between it and the ribs, particularly behind, into this the lung fits exactly, by a thin, prolonged margin; this conformation is less evident on the left side; it depends on the position of the liver, the convexity of which raises the diaphragm into the corresponding concavity in the base of the lung; this close apposition of the liver, diaphragm, and lung, explains how a wound, penetrating the right side of the chest, so high even as the fourth intercostal space, may also open the abdominal cavity, and thus injure, at once, the two layers of the pleuræ, the lung, and the diaphragm, also the two layers of peritoneum, and the liver; it also accounts for sympathy in disease, and the difficulty in diagnosis, as also for the occasional discharge of hepatic abscess into the right pleura, or into the bronchial tubes of the right lung. The posterior edge of the lung is long, thick, round, and ver-

tical, it fills the concavities of the ribs at each side of the spine. The anterior edge is much shorter, is thin, irregular, and oblique, that of the left lung presents two notches, a small, narrow one above, corresponding to the left subclavian artery, and a large open one below, opposite the apex of the heart; the anterior edge of the right lung also presents two notches, but smaller, the superior corresponds to the descending cava, the inferior to the right auricle. The external surface of each lung is convex, corresponds to the pleura costalis, and presents a deep fissure, which commences below and behind the apex, descends obliquely forwards, and ends in front of the base; it divides each lung into two lobes, one superior and anterior, the other larger, inferior, and posterior, the base of the latter is the base of the lung, that of the former is above at the apex of the organ. This interlobular fissure penetrates to a great depth, and its opposed surfaces are smooth and serous; from the middle of that on the right side, a short fissure leads forwards to the anterior edge of the lung, and cuts off the middle lobe from the superior; this does not penetrate so deeply as the great fissure, it is sometimes absent, and in some it exists on the left lung also; occasionally there are four lobes in the right, and three or four in the left, and examples are recorded of even five or six, the ordinary conformation in many other animals. The internal surface of each lung looks towards the mediastina, and is attached to the heart by its root, anterior to which, this surface particularly on the left side, is concave for the reception of the pericardium and its contents.

The *root* of each lung is situated a little above the centre of the internal surface, and about two-thirds from the anterior edge; the phrenic nerve and a few filaments of the pneumogastric nerve, which form the small anterior pulmonary plexus, lie anterior to it, and the great pulmonary plexus is posterior to it; the fold called ligamentum-latum is below it. The superior cava, and the right auricle of the heart are in front of the root of the right lung, and the vena azygos bends round its upper margin; the arch of the aorta is above that of the left side, and the descending aorta is behind it. Each root consists of several vessels and nerves connected together by cellular tissue, and all enclosed between the laminæ of the pleura; dissect off this membrane from the forepart of the root, and we shall observe the two pulmonary veins inferior, but anterior to the pulmonary artery, which is immediately above and behind them; posterior and superior to the artery is the bronchial tube; a quantity of cellular tissue connects these vessels, and contains the bronchial arteries and veins, lymphatic vessels, and glands, also several nerves, which are derived from the pulmonary plexus. In the root of the left lung the bronchial tube is rather inferior to the artery, but still posterior to it, as on the right side. The function of the several parts in the root of each lung is as follows: the two pulmonary arteries convey from the heart, through the lungs, the dark and venous blood; the four pulmonary veins return to the heart, this blood changed into bright arterial; the two bronchial tubes distribute the air through the lungs; the bronchial

arteries small, three or four on each side arise from the aorta, these, together with lymphatic vessels, and the nervous filaments, from the pneumogastric and sympathetic, are distributed through all parts

*Fig.* 23.*

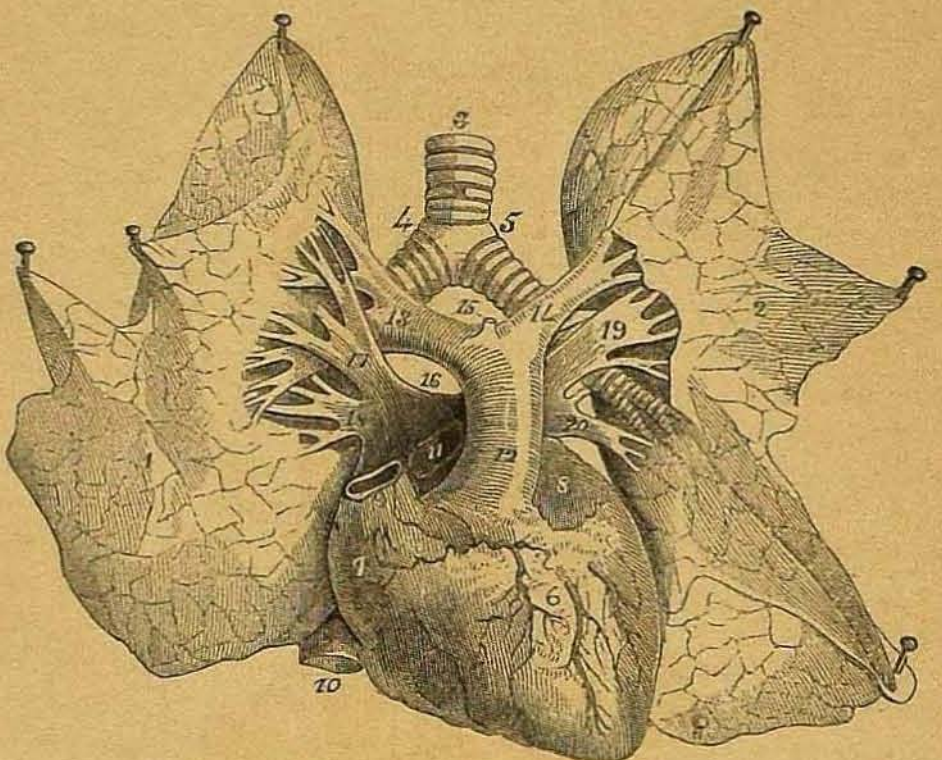


of these organs, on the parietes of the air tubes, and in the interlobular cellular tissue, for the purposes of nutrition; the corresponding bronchial veins open into the vena azygos, or into some of the intercostal veins.

The lungs have a peculiar soft, emphysematous feel, and are so light as to float in water; their colour is grey, interspersed with spots of dark blue or blackish tint; the younger the subject the redder they will be found; in the adult they are generally grey, and slightly streaked with dark lines enclosing polygonal spaces; in the old they are usually mottled with blue or black spots, which exist, not merely on the surface, but through their substance. The lungs are composed of the ramifications of the pulmonary arteries and veins, of the bronchial arteries and veins, of the pulmonary nerves, of lymphatic vessels and glands, and of the ramifications of the bronchial tubes, which end

* Anterior view of the heart and roots of the lungs; the lungs are separated from each other, and drawn outwards. 1. The right lung. 2. The left lung. 3. The inferior portion of the trachea. 4. The right bronchus. 5. The left bronchus. 6. The anterior surface of the heart. 7. The right auricle. 8. The appendix of the left auricle. 9. The superior vena cava. 10. The inferior vena cava. 11. The aorta, cut across a little above its origin. 12. The trunk of the pulmonary artery. 13. The right pulmonary artery. 14. The left pulmonary artery. 15. The ductus arteriosus. 16. The superior edge of the left auricle. 17 and 18. The superior and inferior pulmonary veins of the right side. 19 and 20. Superior and inferior pulmonary veins of the left side.

in numerous air cells, the latter, together with their connecting cellular tissue, constitute the principal bulk of the lungs. These cells are collected at first in clusters, and joined by cellular membrane into lobules; these last are again united into larger masses by the pleura,

*Fig. 24.**

so as to form lobes. The air-cells are the terminations of the bronchial vessels; they are of an irregular form, are lined by mucous membrane, and covered by a delicate, fibrous, or, as some suppose, a muscular lamina; each bronchus divides into two branches, these again subdivide into two, and so on in binary order, thus increasing in number, but diminishing in size; their final capillary branches end in small cœcal sacs or air-cells; if any one bronchial tube be inflated, these small cells and lobules become observable on the surface, marked out and bounded by depressed bands of interlobular cellular tissue, and

* The lower part of the trachea, and the left bronchus laid open (Reisseisen). 1. The orifice of the right bronchus. 2. Longitudinal and elastic fibres. 3. The mucous membrane, separated from the longitudinal fibres. 4. Transverse muscular fibres exposed by the removal of the mucous membrane and longitudinal fibres. 5. The pulmonary artery injected and cut across.

it is principally in these lines, and at their angular junctions, the dark streaks and spots already mentioned may be observed; the larger bronchial tubes are composed of the same materials as the trachea, but in the smaller branches there is no cartilaginous structure. On the delicate parietes of the latter, the fine capillaries of the pulmonary arteries and veins are spread, and here during life is effected that important change in the blood, from venous to arterial, which appears to be the great design of the function of respiration. As to the minute structure and exact arrangement of the air-cells, it is difficult to speak with confidence, Reisseisen and others maintain that each cell is but the globular dilatation of the ultimate ramification of a bronchial tube, like the cells or cœcal extremities of the excretory ducts in the secreting glands, and that each lobule is an aggregate or group of cells, connected together and attached to a bronchial tube and its ramifications, like a bunch of fruit attached each by its own pedicle to the stalk, and that these cells communicate, not directly, but through the common tube from which their ducts proceed, and through which the atmosphere enters their cavity. Although an inspection of the fœtal lungs encourages this view, yet it is by no means confirmed in those of the adult; here the cells appear far more numerous than the ramifications of the bronchial tubes can even be supposed to be, and, therefore, some anatomists believe that each fine tube does not end in a single cell, but that it leads to a cluster of cells which communicate with each other. My own observations on this minute structure, not merely in man, but in many other animals, lead me to concur in this opinion. Addison (*Phil. Trans. note*, 1842), conceives that Reisseisen's account is correct as regards these organs in the fœtus, that is, that the tubes there end, each in a cell or cœcal sac without adjacent communications, but that after respiration a change occurs; the feeble membrane composing these cells, becomes distended laterally into rounded inflations, new cells become moulded by angular pressure, and communicate freely with each other, the septa being incomplete, being mere filaments or laminæ; this open, reticulated texture in a single lobule, is analogous to the arrangement through the whole organ in some of the class reptilia.

Thus we may regard each lobule as a small, but perfect lung, possessing its air tubes and its bloodvessels, and capable of performing its functions, and often even exhibiting isolated disease, independent of the adjacent lobules; the interlobular cellular tissue is fine and reticular, never contains adeps, but is permeable to serous and emphysematous effusions; these lobules are of variable size and shape, those towards the surface are the largest, and are pyramidal or wedge-shaped, those deeper seated are of irregular figures, but accurately adapted to each other; the cells in each lobule are generally said to be globular, but they have no determined form, some are larger and more permeable to the air than others; they are small in the fœtal lung, and larger in the old than in the adult, and larger above than below; in chronic cough they are often dilated, and when very much

be c[ey] constitute the disease called pulmonary or vesicular emphy-venæ an affection very different from the cellular or interlobular em-chest ıa; the air cells and smaller air-vessels are very thin, and ante[s]s a very delicate texture, although they exhibit much power of for [a]nce in the injection or inflation of any part of the lung; they they [co]mposed of mucous membrane, covered by a cellular and fibrous lun[e], but there is no evidence of any muscular structure, the blood-sc[v]els lie between the contiguous walls of two of these air tubes and air cells, so that the capillary streams are exposed on all sides to the influence of the air.

The spongy and yielding tissue of the lungs admits of the free entrance and rapid circulation of the air through their cells, all which become distended in the moment of inspiration; in this act the lungs are wholly passive, the air distending them in the exact proportion with which the parietes of the chest are expanded; in expiration, the contraction of the thorax expels a great portion of the air from the cells, and thus the lungs become diminished in capacity; in effecting this change, the elasticity of these organs, aided by the muscular energy of the bronchial tubes, may assist the muscular and elastic power of the parietes of the chest. In expiration the air-cells are not wholly emptied, as no power can completely discharge the air from lungs that have once breathed.—See *Anatomy of the Diaphragm and Trachea.*

The pleuræ and lungs are the seat of many *morbid* changes; the pleura, when inflamed, becomes thickened and vascular, and presents a deposit of lymph on the surface, which commonly causes an adhesion between the pleura costalis and pulmonalis to a very variable extent; when these adhesions are recent, they are soft and easily broken, but when of long standing they become strong and resisting; adhesions of different extent and length are very common appearances. Portions of the pleura costalis are found sometimes converted into bony plates. Such deposits, when extensive, resemble the natural condition of the ribs in the turtle and the tortoise; this deposit takes place in the fibrous, not in the serous tissue; it occasionally occurs also in the pleura pulmonalis, which corroborates the statement of the fascia existing there also, and apparently without having caused any inflammation or inconvenience. The cavity of each pleura is also the seat of effusion; if of water or serum, it is named hydro-thorax, if of air, pneumo-thorax, if of pus, empyema; the operation of paracentesis, or tapping, is frequently required in the latter case. The place usually selected for this operation is about midway in the fifth or sixth intercostal space, just in front of the digitations of the serratus magnus.

The lungs are often found in a state of inflammation (pneumonia), this is denoted by increased density, weight, and colour, sometimes dark, sometimes very florid; the affected portion is often so heavy as to sink in water; the dark colour, from the gravitation of blood to a depending part, must not be confounded with that arising from disease. Inflammation sometimes ends in gangrene, and sometimes in abscess,

which may open into the trachea or into the pleura, and so caus pyema. The lungs are very subject to tubercles, which present variety in size, from a pin's head to that of a walnut; whe they are firm, when large they become soft, suppurate in the and form abscesses or vomicæ, which often communicate wi bronchial tubes. Tubercles are often found in the upper part right lung, when the remainder of both organs is healthy. The are also occasionally the seat of cancerous and fungoid tubercle tumour. We shall next direct our attention to the parts passin through the upper orifice of the thorax.

Posterior to the deep cervical fascia, we perceive the sterno-hyoid and thyroid muscles first ascending through this opening; behind these is a quantity of cellular membrane, and the remains of the thymus gland; next are the *right* and *left venæ innominatæ*, the former descending perpendicularly, the latter obliquely across this opening: these two veins unite opposite the first intercostal space or the cartilage of the second rib of the right side, and form the superior vena cava, which soon enters the pericardium, and empties itself into the right auricle. The venæ innominatæ are formed by the confluence of the internal jugular and subclavian, opposite the sternal end of each clavicle; the *right* is about an inch and a-half long, descends almost vertically, inclining a little inwards towards the mesial line, parallel, but superficial and external to the arteria innominata; at its commencement it is joined by the right absorbent trunk, afterwards by the vertebral, and in general also by the internal mammary and inferior thyroid veins of the right side. The *left* is much longer and a little larger, runs across this opening almost transversely, but descending a little towards the right side, is convex forwards, is covered by the sterno-clavicular joint, the upper border of the sternum, the sternal muscles, and a strong layer of cervical fascia, a lamina of which connects it to the thoracic septum and to the pericardium; it crosses over the three large arteries and the trachea, and receives at its origin the thoracic duct, and in its course the vertebral, mammary, and inferior thyroid veins of the left side, also the superior intercostal, the phrenic, thymic, mediastinic, and sometimes also the right mammary and thyroid. The superior cava is smaller than the united innominatæ, about three inches in length; descends along the right side of the mediastinum, inclining mesially, so as to be convex towards the right side, is separated from the right lung by the right pleura and the phrenic nerve, which from being external becomes rather anterior to it; the aorta is anterior and to its right side, and the remains of the thymus and cellular tissue are in front of it; opposite the upper edge of the third costal cartilage it enters the pericardium, the serous layer of which is reflected down upon it and covers its two anterior thirds, or fourths; posteriorly this portion of the cava is in contact with the pulmonary artery and superior pulmonary vein in the root of the right lung; opposite the point of serous reflection, the vena azygos enters it posteriorly, occasionally, also, small branches from the adjacent parts join it in its descent; its course and relations in the pericardium shall

be considered presently in the description of the heart. Behind the venæ innominatæ, the phrenic and eighth pair of nerves enter the chest; the former is external and anterior to the latter, and both are anterior to the subclavian arteries. The *phrenic nerves*, accompanied for a short distance by the internal mammary vessels in front of which they cross, descend through the thorax, anterior to the roots of the lungs, to the diaphragm, to which they are distributed; the *right* descends vertically along the right vena innominata, cava and pericardium, in front of the root of the lung, and to the right of the inferior cava to the diaphragm; the *left*, as it descends to the chest, lies external to the left carotid artery, and in front of the par vagum, crosses the side of the arch of the aorta, to the median line of that nerve, and reaches the pericardium, on which it takes a curved course, convex to the left, around and behind the apex of the heart, it is therefore longer, and on a plane somewhat posterior to the right; a small artery, from the internal mammary, accompanies each of these nerves. *The eighth pair*, entering the chest between the subclavian vein and artery, pass backwards behind the roots of the lungs, on which they form an extensive plexus, *pulmonary plexus;* they then enter the posterior mediastinum, and become attached to the œsophagus, which conducts them to the stomach. We next perceive the innominata, *left carotid*, and *left subclavian* arteries, ascending out of this cavity; the innominata is most anterior, and the left subclavian the most posterior of the three; the cardiac nerves are connected to these arteries. The *trachea* enters the thorax, behind these vessels, and inclines a little to the right side; this tube commences opposite the fifth cervical vertebra, descends at first in the middle line, but as it enters the chest it inclines to the right, the aorta pressing on its left side, a little lower down; in the thorax it descends obliquely backwards, and opposite the third dorsal vertebra divides into the right and left bronchial tubes; a number of dark lymphatic glands (the *bronchial glands*), of very irregular form, lie in the angle of the division, and adhere closely to the branches. Its average length is about five inches; but as it admits of elongation, and possesses considerable elasticity; it varies in this respect according as the neck is extended or flexed; the loose cellular tissue around it permits free motion longitudinally, and even laterally, which latter circumstance, in the operation of tracheotomy during life, has proved a source of difficulty and danger; its diameter varies according to age, sex, and general development of the respiratory organs; it is larger in man than in woman; the transverse exceeds a little the antero-posterior diameter, as it deviates from a cylinder, the posterior third being flattened; in this respect it differs from the cricoid cartilage, which is nearly circular, and which in other respects it equals, though in many instances I have known the trachea to exceed it in capacity; in the adult male the transverse axis is between half and three-quarters of an inch; it is sometimes a little contracted at first, or about the third or fourth ring, and it is frequently enlarged just above the bifurcation; in some it gradually enlarges as

it descends, so as to assume a conical form, the base below; it is very variable in this respect; some have remarked both general and partial dilatation, in persons afflicted with severe cough; such alterations in diameter are remarkable and normal in many of the bird tribe. The cervical and thoracic portions of the trachea are nearly of equal length; the relations of the former are as follow: the first ring is superficial; the second, third, and often the fourth are covered by the middle lobe of the thyroid body, which adheres closely; below this, the cervical fasciæ and the sterno-hyoid and thyroid muscles cover it, especially the latter, which being connected together by a sort of raphe derived from the deep fascia prevents its being even distinctly felt; behind these muscles is a considerable quantity of cellulo-adipose membrane, containing the venous plexus of the inferior thyroid veins, in their descent to the left vena innominata; a small artery (middle thyroid) frequently traverses this plexus; near the root of the neck the arteria innominata passes in front of it and to its right side, rising to a variable height; the left vena innominata also crosses it nearly on a level with the upper border of the sternum. On either side of the trachea in the neck we find the lateral lobes of the thyroid body, the sheath of the carotid artery, lymphatic glands, and much cellular and adipose tissue; its flat posterior surface rests on the œsophagus, but towards the bottom of the neck the latter projects to the left side, and supports the left recurrent nerve; the right recurrent is behind the trachea. The proximity of the œsophagus to the flat and membranous surface of the trachea accounts for the danger of suffocation from any large substance becoming impacted in the former, and the necessity for performing tracheotomy if it cannot be dislodged. This posterior flattening of the trachea has been thought by some to have been designed to facilitate deglutition, by admitting the distention of the œsophagus; however, the same structure is continued in the bronchi, where no such intention could apply; and in some animals the cartilages are perfectly annular, and in others they even project behind in an angular form. In the thorax, the trachea is between the lungs and pleura, just above and in front of the posterior mediastinum; anterior to it are the sternum with its muscles, the remains of the thymus body, much cellular tissue, and the arteria innominata; the left carotid is also in front and to its left side, a little lower down the arch of the aorta rests upon its anterior and left aspect; the division of the pulmonary artery is immediately in front of the left bronchus; these relations to the great vessels are of great interest and importance, in accounting for many of the symptoms, as well as the fatal results of aneurism of the aorta, or of any of the large arteries in this situation; posteriorly the trachea still rests on the œsophagus, on either side are the pleura and the pneumogastric nerves, and at its very entrance into the chest the recurrents also; much cellular tissue and many lymphatic glands surround it, continuous with similar structures in the neck.

The trachea, which serves as the free passage for the air to and from the lungs, and therefore requires to be permanently open, is composed

of different tissues, viz.: fibrous, cartilaginous, elastic, mucous membrane, with glands and muscular fibres. The fibrous membrane is the essential basis, it forms the continued tube, is attached above to the cricoid cartilage, divides below into the two bronchi, and is continued along their ramifications through the lungs as far, probably, as their terminations in the air cells: in this tissue the annular cartilaginous plates are deposited very close to its inner or mucous surface; the average number of these is eighteen, each forms about three-fourths of a circle, the posterior deficiency being supplied by the fibrous membrane and transverse muscular fibres; each cartilage is convex anteriorly and externally, and covered by the fibrous membrane, concave posteriorly, and lined by mucous membrane, their upper and lower margins are thin, attached to and enclosed in the fibrous tube, their extremities are blunt points; as to size they are very irregular, often larger in one part than in another, they are not, therefore, always parallel: two are sometimes partially united, occasionally one or more will be found bifurcated; the first ring is deeper than the others, particularly in front, and is sometimes continuous with the cricoid; the two last rings are also larger than those that preceded them; the last serves as the transition from the single tube into the two bronchi, it is very deep in front, and bent backwards so as to form an angular projection into the trachea between the two bronchi, the semicircular edges of this curved portion form the first cartilage in each bronchial tube. The tracheal cartilages resemble those of the nose and external ear, much more than the laryngeal; they are thin, yielding, and compressible, but very elastic and difficult to break or injure; they are rarely ossified; in very old men I have found the first and last thus partially changed, as also specks of calcareous deposit, but not true bone, in the anterior convexity of several, not unlike the appearance so often found in the middle coat of an artery. These cartilages maintain the trachea in a state of permanent patency, whilst at the same time they admit of expansion and contraction, they also prevent its closing from accidental pressure, or from the weight of the atmosphere during inspiration, which then tends to compress it, at which time the deep cervical fascia and the sterno-thyroid muscles also afford it considerable protection. The muscular structure of the trachea is found posteriorly where the cartilaginous is deficient; it may be exposed by dissecting off the fibrous membrane, or by first opening the trachea in front, and then raising the mucous; it consists of distinct transverse fibres, pale and thin, attached to the extremities of the cartilages; by their contraction they can diminish the size of the trachea, as also resist forcible expansion in violent expiratory efforts; in some cases of chronic bronchitis these fibres have been found hypertrophied. Between the muscular and mucous coat the yellow elastic tissue exists in the form of longitudinal bands, at first view like the folds of the mucous membrane, but they are not effaced by distention; they adhere closely to the membrane, but can be separated by dissection, and traced into the bronchial tubes; similar bands are also sometimes found

beneath the cartilages; this elastic tissue maintains the due length of the trachea, it admits of extension, but resists excessive elongation, and restores it to its former state. The fibrous membrane on the front and sides of the trachea occasionally presents a reddish appearance, like longitudinal muscular fibres, but none such exist in the human trachea. The mucous membrane is continued from the larynx, lines the trachea, the bronchial tubes, and all their ramifications through the lungs, also the air cells in which they terminate; it adheres very closely to the interior of these vessels, and in the trachea it is pale, fine, and thin, nearly transparent, and perforated by many small foramina, orifices of the mucous glands, which are numerous in the parietes of this tube. These glands are found in three situations; first, on the posterior flat surface of the trachea and connected to the fibrous membrane, are several of a flattened, ovoid shape, these are the largest; secondly, between this membrane and the muscular fibres, also in the interstices of the latter, we find almost a regular layer of these bodies; and lastly, between the edges of the cartilages beneath the fibrous coat, also between the former and the mucous lining a number of very small ones may be detected; these glands, no doubt, furnish that fine muco-serous secretion which constantly coats the surface of the membrane and defends it from the irritation of the air.

The arteries of the trachea are derived chiefly from the superior and inferior thyroid; the veins are superficial and deep, the latter are subjacent to the mucous membrane posteriorly and laterally, and receive branches regularly from each annular interstice, they open into the adjacent veins; the nerves are derived from the pneumo-gastric and recurrents.

The two *bronchial tubes* separate at an obtuse, or nearly a right angle; a strong, elastic, triangular ligament occupies the angle of bifurcation, and limits their separation; their united areæ exceed that of the trachea. The right tube is the larger, as the right lung exceeds the left, it takes a short and nearly transverse course into the root of the right lung, above and behind the right pulmonary artery, having the vena azygos curved round it from behind upwards and forwards; it soon divides into three branches. The left bronchus is smaller but much longer, and passes obliquely downwards into the root of the left lung, behind and below the level of the left pulmonary artery, and divides into two branches; in this course it passes through the arch of the aorta, embraced by it above, and in front of the œsophagus, thoracic duct, and descending aorta. Both bronchi are intimately connected to the great pulmonic plexus of nerves, and to several lymphatic glands, which are usually, in the adult, of a very dark colour and soft consistence, and are frequently, in a diseased or altered state, indurated into a mass, or converted into a cheesy or calcareous substance; the pneumo-gastric and the left recurrent nerves will be often found imbedded in or surrounded by these morbid structures. The pulmonary arteries in the root of each lung, at first anterior to, gradually rise above the bronchial tubes and then pass behind them; the veins at first are between the tubes and arteries, but

as they approach the heart are placed below and in front of both. In form and structure the bronchi resemble the trachea; flattened and deficient in cartilage behind, they possess all the other tissues in common with it; the right one possesses five or six annular pieces, the left nine or ten. Their arteries are derived from the bronchial branches of the aorta, and their veins open into the azygos or intercostals. As the bronchi proceed into and through the pulmonary tissue important changes occur; they rapidly branch off into numerous ramifications, diverging in every direction, and therefore difficult to follow individually to any extent; each branch first divides into two, each of these again into two, and so on, as far as we can pursue them, they adopt this dichotomous division and subdivision, though occasionally supernumerary branches arise and separate at acute angles; finally, the small terminating tubes lead each to a separate lobule, and each ends in a free communication with its air cells or vesicles; these air vessels are accompanied throughout by the pulmonary arteries and veins; the former are very close to and usually behind them, the veins are more loosely connected; these different vessels can be recognized on the surfaces of a section of the lung. The air vessels very soon lose the form and structure of the trachea and primary bronchial tubes; the fibrous and mucous coats continue through their entire course; the longitudinal elastic tissue soon disappears, but the cartilages are curiously modified and changed in a gradual manner; instead of forming large segments of a circle, they soon become divided into small curved pieces equally diffused round the whole tube, which now becomes cylindrical; these segments are of the most varied forms, and are bounded by edges and points which can mutually overlap and glide upon each other; the muscular coat is also continued circularly, and forms a thin, circular tunic, like that on the intestine; the fibres are attached to the margins and points of the cartilages; by this means the capacity of the tubes can be changed, particularly diminished, but not obliterated; this arrangement continues even in the smaller tubes, but the cartilages gradually lose the curved angular form, and are reduced in size to mere lines, patches, or grains, and, finally, at the last bifurcation of an air tube, a small cartilaginous tubercle stands in the angle of division; beyond this, the tube is wholly membranous, and, as well as the cells into which it opens, appears to be composed of nothing more than the mucous lining and a fine fibrous investment. How far the muscular coat extends, whether it ends abruptly at the last cartilaginous tubercle, or whether it is continued, of great delicacy, over the final tube and air cells, is is impossible to speak with accuracy or confidence; it is probable, however, that as soon as the cartilages cease, the muscular structure which was designed to act on them, and thereby to alter the diameter of the tube, ceases also; but as to the final tubes and cells, there being no resisting medium in these, muscular structure might prove injurious rather than beneficial; the air once inspired ever afterwards retains these in a more or less distended condition, and cannot wholly be expelled during the healthy state of the organs, but is constantly under-

going a gradual change and gradual displacement, by the admixture of fresh air in each inspiration, and by the expiratory efforts.

The respiratory tube, from the glottis above, to the terminating pulmonary air vesicles below, presents a curious series of transition structures, each change being wonderfully adapted to a special purpose: the larynx, in one part, with its delicate and beautiful locomotive apparatus and voluntary endowment, and in another composed of the unyielding and, of course, unchanging circular wall of the cricoid cartilage; the trachea and bronchi, with their crescentic and elastic plates, convex on all sides exposed to pressure, but deficient behind, and thereby capable of yielding to expansion, and recoiling by elasticity, aided by the transverse involuntary muscular fibres attached to their extremities; the pulmonary tubes, cylindrical and muscular, at the same time studded with a sufficiency of cartilaginous grains to prevent obliteration, and yet to admit of change of place and form; and lastly, the capillary air tubes and air vesicles, wholly destitute of these two elements. These modifications of structure in the different sections of this one tube, are not only interesting to the anatomist and physiologist, but are also of extreme importance to the pathologist, in connexion with the nervous and structural diseases of the respiratory organs.

Behind the trachea, the *œsophagus* is next seen entering the thorax, lying close to the spine, or rather to the left longus colli muscle; its course is slightly tortuous, like an intestine, at first a little to the left of the mesial line, afterwards to the right of that line, and as it descends through the posterior mediastinum, it again inclines to the left and a little forwards. On the left side of this tube, the thoracic duct is seen ascending from the thorax into the neck, between the left carotid and subclavian arteries. As the œsophagus enters the chest, we observe on either side of it the recurrent nerve; that of the left side passes out of this cavity, that of the right arises on a level with this opening. The œsophagus is a musculo-membranous tube, extending from the pharynx to the stomach; it commences behind the cricoid cartilage, opposite the fifth cervical vertebra, and enters the abdomen between the crura of the diaphragm. In its cervical portion the trachea is anterior to it, also the left lobe of the thyroid gland, and the inferior thyroid vessels, and recurrent nerve of the left side; the sheath of the cervical vessels is related to it laterally; and it is surrounded by loose cellular membrane, which connects it to the longi colli muscles. In the thorax it soon enters the posterior mediastinum, where it has been already examined. It is composed of muscular, mucous, and cellular tissue; the muscular is very distinct, the fibres externally are longitudinal, internally circular; both are more distinctly marked than in the digestive canal below, excepting in the rectum, to which it bears some analogy; they are red above, pale below, and expand on the stomach; these fibres belong to the involuntary muscles; cellular tissue connects them to the mucous or lining coat, which is thin and pale, thrown into longitudinal plicæ, and lined by a fine

epithelium or cuticle; when the neck is much extended, the pharynx and œsophagus become nearly one straight line. On each side of the œsophagus, and at some distance, we perceive the *sympathetic* nerve entering the chest, posterior to the phrenic and the vagus, but between both; this nerve, having formed its inferior cervical ganglion, divides into several branches which descend into the thorax, a few pass anterior to the subclavian artery, the principal pass behind it; most of these unite in its first thoracic ganglion, which is situated on the neck of the first rib; the sympathetic then descends along the side of the spine, passing over the heads of the ribs, and opposite each intercostal space forms a small triangular ganglion, from each of which two or three small branches proceed to join the dorsal spinal nerves, and from the five or six inferior the great and small splanchnic nerves arise; the sympathetic is so small inferiorly, that it is often difficult to trace it; it escapes from the thorax into the abdomen, beneath the true ligamentum arcuatum. Posterior to the œsophagus, the longi colli muscles ascend through the upper opening of the thorax; on each side of these lie the superior intercostal artery, and the anterior branch of the first dorsal nerve, ascending to join the last cervical in the brachial plexus. The apex of each lung and pleura also occupy this opening, that on the right side has in front of it the right vena innominata, the phrenic, pneumo-gastric, and cardiac nerves, the arteria innominata, and subclavia dextra; that of the left side has the left vena innominata, the corresponding nerves, the left carotid and subclavian arteries, and the thoracic duct, while posterior to each are the superior intercostal artery, the sympathetic, and the ascending branch of the first dorsal nerve. The parts which pass through the base of the thorax will be more properly considered in connexion with the diaphragm, which they perforate; they are, immediately behind the sternum, the internal mammary vessels, and cellular tissue from the anterior mediastinum; the phrenic nerves near the centre; the vena cava to the right, and the œsophagus to the left of the mesial line, and posteriorly on each side of the spine the greater and lesser splanchnic nerves, and close to the vertebræ the aorta, vena azygos, thoracic duct, and sympathetic nerves. We shall next examine the heart and pericardium.

The *pericardium* is a strong fibro-serous membrane, in the form of a conical bag, whose base is below and apex above; it is larger than the heart, which it encloses, together with a portion of the great vessels connected to it, and over whose surface its internal or serous layer is reflected; the external lamina is composed of aponeurotic fibres crossing each other in a very irregular manner, the greater number of these fibres are longitudinal. This external, or fibrous layer, is connected, inferiorly, to the central division of the cordiform tendon of the diaphragm, and to some of its fleshy portion between the central and the left divisions of that tendon; anteriorly it corresponds to the anterior mediastinum and to the sternum, to which it is connected by cellular membrane, and to the cartilages of the fifth, sixth, and seventh true

ribs of the left side, from which it is, however, separated by the left lung and pleura; posteriorly, to the œsophagus and to the other parts in the posterior mediastinum; superiorly, it is continued along the outer coat of the great vessels, while the serous layer is reflected on these towards the heart. On each side it is in a similar manner connected to the pulmonary vessels; the pleura and the phrenic nerve also are attached to it in this situation. The connexion between it and the tendon of the diaphragm, particularly towards its forepart, is very intimate; in the adult they are almost inseparable, not so, however, in the fœtus. The large vessels passing to and from the heart perforate this parietal layer, the fibres of which are prolonged as a sheath upon them, and are gradually identified with their external coat; there are nine of such perforations; one for the aorta, two for the pulmonary arteries, four for the pulmonary veins, and two for the venæ cavæ; it sends no sheath on the inferior cava. Open this bag, and we shall see that it is lined throughout by a smooth serous membrane, which, if we trace to the superior part of the sac, we shall perceive to be reflected on the vena cava on the right side, about an inch above its entrance into the right auricle, on the aorta in the middle, about two inches above its origin; and on the pulmonary artery on the left side, at nearly the same distance from the heart; on these three vessels it descends towards the heart; there is a longer portion of the aorta covered by the serous membrane, then of the vena cava or pulmonary artery, which two are nearly equal in this respect. The serous layer is reflected on the superior cava, opposite the entrance of the vena azygos; as it descends along that vessel it nearly surrounds it, except a small portion of it posteriorly: from the vena cava it continues to the right auricle, which it covers anteriorly and on the right side; from this it passes on the right pulmonary veins, covers these also partially, and is thence reflected to the fibrous layer; from the lower part of the right auricle it is continued partly round the inferior cava, and from it also it is reflected to the fibrous layer. On the aorta the serous layer descends at first on the forepart, afterwards on its sides and back part, so as to encircle it; near the heart it passes from it over the pulmonary artery, so as to connect these vessels to each other, leaving, of course, uncovered so much of each as is in apposition; along these vessels the serous membrane descends to the ventricles, and having covered all the anterior surface of the heart, from which it is separated by more or less of interposed adipose substance, it turns round its apex, covers the posterior surface, and ascending on it as high as the upper edge of the left auricle, it is thence reflected on the fibrous layer in front of the posterior mediastinum; from the left auricle also it extends to the left pulmonary veins, from which it is continued to the fibrous layer, and on this we can trace it in an uninterrupted course to that point, at which we commenced its description. These several reflexions of the visceral from the parietal layer, along the great vessels, represent processes with cornua or *cul de sacs*, especially when the vessels are empty; behind the united roots of the aorta and pulmo-

nary artery it lines a smooth, transverse passage, or sinus, which is in front of the right pulmonary artery and the left bronchial tube, and above the fleshy basis of the heart; this sinus opens at each extremity into the general cavity, but has no direct communication with the great *cul de sac* which is formed posteriorly at the back part of the heart, between the left auricle and the posterior mediastinum. The arteries of the pericardium are small, and proceed from the aorta, innominata, internal mammary, phrenic, bronchial, coronary, and œsophageal; the veins correspond to the arteries, some terminate in the vena azygos.

The pericardium, by its fibrous lamina, is of *use* in fixing the heart in its situation, and strengthening its parietes, so as to resist over-distention; this fibro-serous membrane also, by its elasticity, may assist in the contraction of its cavities, while the serous layer, being always lubricated by a fine fluid, facilitates the motions of the heart. When the pericardium is fully opened, the right auricle, the two cavæ, the appendix of the left auricle, the right or anterior ventricle, that small portion of the left which forms the apex of the heart, the aorta, and pulmonary artery, also branches of the coronary vessels, ramifying on the anterior surface of the heart, all come into view.

The pericardium is liable to acute inflammation, pericarditis; opportunities do not often occur for observing the membrane in this condition, when it will be found crowded with minute vessels, carrying florid blood; it is also more pulpy and thicker than natural; extravasated coagulable lymph is found loosely connecting it to the heart; this sometimes has a reticulated or lace-like appearance, and portions of it float on the serous fluid which exists in the cavity. In some cases large quantities of pus are formed, without any appearance of ulceration, but always accompanied with a thickened state, and a deposition of coagulable lymph on the internal surface of the membrane. The presence of a small quantity of fluid in the pericardium after death, is not to be set down as a morbid appearance, or confounded with the disease called hydrops pericardii, as in every healthy body a few drachms of fluid are found in the bag of the pericardium, arising from the condensation of the natural exhalation, which exists in all serous cavities, or from the transudation of the blood from the contraction of the heart after death.

The HEART, the central organ in the apparatus for the circulation of the blood, is a strong muscular bag, divided into four compartments, the right and left auricles, and the right and left ventricles, and is designed to receive and to propel the blood from and to all parts of the body. The heart is of great importance in zoological science, as upon its presence or absence, its simple or complex structure, many circumstances in the general organization of an animal depend. A perfect heart exists in all the vertebrata, but differently modified in the different classes. Mammalia and birds possess a perfect, single, but quadrilocular heart; in reptiles and fish it is much more simple, or bilocular, that is, it consists of a single auricle and ventricle, which latter in fish

is wholly pulmonary, or branchial, but in reptiles is both pulmonary and systemic. This organ exists in mollusca also, but in a simpler or more rudimentary form; in some there are two, or even three separate hearts placed in different parts of the animal, to regulate and assist the circulation of its blood. In mammalia and birds, notwithstanding the heart appears as single, it is yet really double, and to a certain degree symmetrical, the right heart being connected with the venous and pulmonary circulation, the left with the arterial and systemic or aortic circulation; hence the synonymous terms, right or pulmonic heart, left or aortic. In man the right heart is also anterior to the left.

The heart is of a well known form; the cone is not uniformly rounded, but is a little flattened anteriorly, as well as inferiorly, hence it presents distinct surfaces and edges, besides a base and apex. It is situated in the cavity of the thorax, near its centre, and corresponds to the union of the superior third of the body with the two inferior thirds; placed in the middle mediastinum, behind and a little to the left of the sternum, obliquely in front of the spine, between the lungs, and above the diaphragm, which separates it from the liver, stomach, and spleen; in this position it is maintained by the pericardium, the pleuræ, and the large vessels passing to and fro; it is, however, subject to slight changes of position from natural or healthy causes, such as change of posture of the body, as it reclines horizontally, or is bent forward, or to either side, also according to the different states of inspiration and of expiration; the condition of the stomach, and other abdominal viscera may also exert some influence in this respect. The heart is placed obliquely from above and from behind, downwards, forwards, and to the left side; the base looks upwards, backwards, and to the right, and corresponds to the front and right side of the mesial line of the fifth, sixth, and seventh dorsal vertebræ, it often extends in front of the fourth also, as well as of the eighth; the base lies obliquely across the spine, and is therefore well supported by it, though separated from it by the parts in the posterior mediastinum. The apex is directed downwards, forwards, and to the left side, corresponds to the costal end of the sixth rib; the lung being notched in this region, its pulsations can be felt through the fifth and sixth intercostal spaces, below the mamma. The axis of the heart, that is, a line traversing the apex and centre of the base, has an oblique course from the point, upwards, backwards, and to the right side, or towards the right scapula. The heart, or rather the ventricles, present, for our more minute examination, three surfaces, anterior, inferior, and posterior; two edges, anterior thin, posterior thick; also the base and apex. The anterior surface is the largest, flattened, and slightly convex, divided into two unequal parts by a longitudinal groove, which contains the left coronary artery imbedded in fat; there is a similar groove on the posterior surface, which also contains a branch of the left coronary artery; these two grooves correspond to the septum between the ventricles, and meet at the apex,

and divide the heart into the right, or anterior, and the left, or posterior. That portion of the anterior surface to the right of the anterior line, or groove, is larger than the left, and is formed of the right ventricle; to the touch this feels soft and flaccid, and corresponds to the sternum, while the left portion is firm and resisting, and is composed of the wall of the left ventricle, and is opposite the left costal cartilages. On this anterior surface a small white spot, of variable size, is often to be seen, sometimes two or three, probably owing to the thickening of the serous or sub-serous tissue, the result of some slight inflammatory action.

The inferior surface is flat and horizontal, of a triangular shape, is formed of the right ventricle, and rests upon the diaphragm; this surface is distinguished from the anterior by the thin edge of the heart, but is gradually rounded off into the posterior; the latter is thick and convex, is formed of the left ventricle, and rests on the inner side of the left lung; it is separated from the anterior surface by the left or thick edge of the heart, but is so continuous with the inferior that they are regarded by many as forming but one surface. The edges of the heart are two; the inferior or anterior is thin and nearly straight, or horizontal; it extends from the inferior cava to the apex, and fits into the angle between the anterior and inferior portions of the pericardium. The posterior, or left edge, does not deserve that name; it is thick, rounded, and vertical, is formed by the left ventricle bending round from the front to the back part of the heart. The base presents from right to left the two auricular processes, and the roots of the pulmonary artery and aorta; the pulmonary artery arises on the right side of the anterior cardiac groove; that portion of the right ventricle from which it arises is prolonged upwards and a little to the left side, and, contracting into a funnel form, is named the infundibulum; the artery then passes backwards and to the left side; on a plane behind this is the root of the aorta from the left ventricle, at first concealed by the infundibulum and by the root of the pulmonary artery; this vessel soon emerges from behind the latter, and appears prominently to its right side, so that these two great arteries cross obliquely, like the limbs of the letter X; on a plane behind these we find a circular groove separating the auricles from the ventricles; with this the anterior and posterior vertical grooves communicate; this groove is very deep posteriorly, where it lodges the coronary vein and branches of the coronary arteries; at the bottom of it we see the fleshy base of each ventricle folded in, as it were, to present a broad surface of support to the auricles; this surface is cut off very obliquely from before backwards and downwards, so that the anterior surface of the heart is nearly an inch longer than the posterior; in front of the anterior part of this groove, the two great arteries spring, the aorta being posterior, and nearest to the groove. There is generally, but especially in old persons, a considerable quantity of fat in this groove, as also along the whole course of the coronary arteries. The apex of the heart is often curved a little backwards, is formed in the adult wholly by the left

ventricle, but in the fœtus the right also enters into it, hence, at this age, the point is rounder, and often a little bifid from the notch uniting the two vertical grooves; this notch in the adult is filled by fat, and requires dissection to unfold it, it then lies to the right side of the apex. The heart is larger, and more muscular in proportion in the child than in the adult; in the former, also, there is no fat upon its surface, and in the adult but little; but in the elderly it increases, particularly on the surface of the right ventricle, on the anterior thin edge, and in the course of the coronary vessels; there is seldom any quantity of this deposit on the auricles.

The heart consists of four cavities, two ventricles and two auricles; these the student may examine in that order or course which the blood pursues in passing through this organ. Suppose the two venæ cavæ pour their blood into the right auricle, so as to distend it, the parietes of this cavity then contract, and empty its contents into the right ventricle; this next propels the blood into the pulmonary artery, the branches of which convey it through the lungs; from these organs it is returned by the four pulmonary veins, two on each side, into the left auricle; from this cavity it is forced into the left ventricle, which then propels it into the aorta, through whose branches it is conveyed to all parts of the body, whence it is again returned to the heart by the veins. The *superior vena cava* is seen descending obliquely forwards and inwards within the pericardium, and joining the upper and back part of the right auricle. Of the *inferior cava* but a short portion is seen within the pericardium; this vessel lies on a plane posterior to the superior cava, and passing obliquely upwards, backwards, and inwards, joins the lower and back part of the auricle; as these two veins have different aspects and are on different planes, the descending column of blood does not fall perpendicularly upon the ascending. Between these two veins the *right auricle* is situated; it is somewhat square; if distended it becomes convex anteriorly and to the right side, and concave posteriorly towards the root of the right lung, also internally towards the septum auricularum; its largest diameter is from right to left and from before backwards; it is broadest behind and below, and is prolonged anteriorly and superiorly into the appendix, or process called the auricle; this is loose and free, more or less serrated on its edges, turns forwards, and lies between the upper part of the right ventricle and the aorta. The right and posterior portion of the auricle is connected with the two cavæ, which are here continuous with each other, the expansion of the outer and posterior walls of which may, indeed be regarded as forming this region of the cavity, and which, therefore, has been named the sinus of the auricle, or the sinus venosus; this division into sinus and proper auricle is more perfectly marked in the left auricle; the right auricle is connected inferiorly to the right ventricle, and partly rests on the diaphragm; on the right side it is free, and on the left it is connected to the left auricle; lay open this cavity by a perpendicular incision from the superior down to within half an inch of the inferior cava, from the centre of this make a transverse cut towards

the anterior part of the auricle, wash out the blood; we may then observe at the back part of the sinus the *openings* of the two cavæ, and between these a slight projection, *tuberculum Loweri;* and in the auricular appendix the muscular fibres called *musculi pectinati.*

The opening of the superior or descending cava is at the upper and posterior angle of the sinus, circular, without any valve, and directed towards the passage into the right ventricle; a projecting muscular band separates it from the auricular process. The orifice of the inferior or ascending cava is larger, and on a plane posterior to that of the superior; it looks towards a remarkable depression, the fossa ovalis, and is partially protected in front by the semilunar valve of Eustachius. The tubercle of Lower projects from the right and posterior aspect of the sinus, between the two cavæ, and opposite to the auriculo-ventricular opening, and just in front of the right pulmonary vessels; this was supposed to be of some use in directing the streams of blood from the two veins towards that opening, and preventing their perpendicular pressure against each other; it appears to be produced by a slight increase of thickness in that part of the wall of the sinus, together with a little fat externally, it is, however, very variable, and sometimes indistinct, or even altogether absent. The *musculi pectinati* are those muscular fibres which line the anterior portion of the auricle and the appendix, internal to the venæ cavæ; the fasciculi pass from the auricle to the ventricular opening, chiefly in a parallel direction, leaving interstices between them, and from some fancied, but slight resemblance to the teeth of a comb have been thus named; in these interstices there is no muscular fibre, and the investing and lining membranes are in such close apposition, that the blood can be seen through them before the cavity was opened, or if the cavity be perfectly empty, these interstices appear as whitish lines, hence the auricle always presents a striped or variegated appearance externally, whereas the sinus possesses a dense, muscular wall, and is therefore uniformly opaque. The musculi pectinati are crossed irregularly by smaller fasciculi, which give rise to a reticulated muscular structure, such as is seen on the inner surface of the ventricles.

The left or internal side of the auricle is formed by a thin sheet of membranous and muscular substance, the *septum auricularum;* on the inferior part of this we may observe a depression, the *fossa ovalis*, immediately above the inferior cava, and surrounded in part by a thick lip, named its annulus; at the upper and deeper part of this fossa we frequently find, even in the adult, a small oblique passage leading into the left auricle, its obliquity, however, prevents any communication taking place during life; in the fœtus before birth, this was a free opening, the *foramen ovale*, between the two auricles. Anterior to the opening of the inferior cava, we observe the semilunar fold of the lining membrane, the *Eustachian valve:* this valve is connected by its convex edge to the angle between the vein and auricle; its concave edge is loose, and looks backwards and to the right side; its superior cornu is connected to the anterior or the left limbus of the

fossa ovalis, and the inferior to the forepart of the vena cava, and is sometimes continued round that vessel to the posterior limbus of the fossa ovalis; in the adult and old this valve is often reticulated and imperfect; in the fœtus it is generally more perfect and large, hence it is considered by many as being of *use* at that period in directing the blood from the inferior cava at once into the left auricle through the foramen ovale, and preventing its mixing with that from the superior cava. To the left side of the Eustachian valve, between it and the ventricle, is the *orifice* of the *coronary* sinus, a small thimble-like cavity with muscular walls, which is also partly covered by a semi-lunar fold of membrane, the free and concave edge of which is directed upwards; beneath this, open two or more of the coronary or cardiac veins; this fold, or valve (*valve of Thebesius*), secures these openings against the re-entrance of the blood during the contraction of the auricle; this valve is also often imperfect; on different parts of the auricle small orifices may be often seen (*foramina Thebesii*); some of these are probably the extremities of small veins, others only lead into the muscular depressions: anteriorly and to the right side of the venæ cavæ, the auricle presents the pectiniform and recticular structure already alluded to; the latter structure is also continued through the auricular appendix, or process, which communicates by a free, circular opening with the general cavity; the distinction between the auricle and the appendix is not so well defined on the right as on the left side of the heart. Inferior to this process, and opposite the tuberculum Loweri, is the large orifice leading into the right ventricle; this, the *right auriculo-ventricular opening*, is circular, and surrounded by a dense white line, which is usually designated as the right tendon of the heart. We may next examine the right ventricle: for this purpose open its cavity, by raising the anterior wall in the form of a flap from below, making one incision along its right side, and the other near the septum cordis.

The *right ventricle* occupies the anterior, inferior, and right side of the heart; of a triangular form, its base is joined to the auricle and pulmonary artery, its apex is a little short of the apex of the heart; its walls are thicker than those of the right auricle, but thinner than those of the left ventricle, it is also thinner towards the apex than at the base; its anterior and inferior walls are much thinner than the left or posterior, which is the septum ventriculorum, and which is thick, convex, and resisting, whereas the other sides are weak; hence the parietes of this cavity always feel soft and flaccid; they are rendered very irregular internally by numerous muscular projections, the *carneæ columnæ; some* of these are attached throughout their whole length, *others* are fixed by their extremities, and loose in their centre; these are the most numerous, they subdivide and form numerous areolæ; and a *third, musculi papillares*, are fixed by one end to the fleshy substance of the ventricle, by the other to thin tendinous cords which are attached to the auricular valves; the carneæ columnæ take various directions, and are all covered by the fine lining membrane of the heart, they form a very intricate net work on the walls of the

ventricle, and several cross the cavity; they are less numerous on the septum and at the base than near the apex. At the base of the right ventricle we observe the auricular and arterial openings; the latter is superior, anterior, and to the left side of the former; from the margin of the auricular opening a fold of the lining membrane descends into the ventricle; the inferior loose edge of this valve divides into three principal portions, each ending in a very irregularly notched margin, to which the chordæ tendineæ are attached; these are the *tricuspid valves;* one division is to the right side, the second is posterior, on the septum cordis, and the third, which is the largest, is anterior and to the left side, and separates the auricular from the arterial opening; this (the septum of Lieutaud) is supposed to act as a valve on the pulmonary artery, so as to prevent the blood entering it during the filling of the ventricle; many of the tendinous threads are connected to the dorsum, as well as to the edge of these folds, and cross each other as they run to the carneæ columnæ; some also are inserted into the septum; the edges of the valve are often studded with reddish tubercles. Most of the tendinous threads arise from the carneæ columnæ, or musculi papillares; though slender, they are very strong, and in their course to the valves they diverge, often bifurcate, and communicate together. The left, or anterior valve or curtain, is the largest, and prevents the filling of the pulmonary artery during the distention of the ventricle, or the systole of the auricle; the cords of this valve are inserted into a long fleshy column, which is attached to the anterior, or the yielding wall of the ventricle; from the lower part of this column a transverse muscular band passes across the cavity to the septum; the right curtain is connected by its cords partly to the long column, and partly to a second, which is also on the anterior wall; and the third valve has its cords inserted into the septum without any separate columns. The *use* of the tricuspid valves is to prevent the reflux of the blood from the ventricle into the auricle; as the former cavity is being distended, the blood separates the valves from the parietes of the ventricle, and thus becomes situated on their outer side; when the ventricle then contracts, it presses the blood against these folds, which are thus approximated to each other, and slightly raised against the opening, so as to close it; the carneæ columnæ at the same time contracting make tense the chordæ tendineæ, and thus accomplish two objects, first, they approximate the valves; and second, they prevent their being reversed, or thrown up into the auricle; if, however, the right ventricle be over distended, as a consequence of impeded pulmonary circulation, the anterior more yielding wall will carry with it the columns and cords of the anterior and right valves, and thus effect an opening or passage between them, whereby the blood may regurgitate into the auricle, and thus the ventricle will be relieved; this mechanism is said to answer the purpose of a safety valve:* another useful purpose also may have been designed in this peculiar attachment of this valve, namely, that the complete diastole of the ventricle

* See Essay by T. W. King, Guy's Hospital Reports, vol. ii.

shall clear the opening into the artery which has been closed by this curtain during the distention of the cavity.

The orifice of the pulmonary artery is small, situated at the highest point, and at the left extremity of the ventricle, anterior to, and nearly an inch to the left side of the auricular opening, from which it is separated by a prominent concave muscular ridge, and by the septum of Lieutaud; these divide the ventricle into two chambers, an auricular, which is extremely irregular, from the reticular cellular network formed by the carneæ columnæ, and an arterial, which is smooth and polished. Around the root of the artery the ventricle is prolonged into a sort of process, named from its form the *infundibulum*, or *conus arteriosus;* out of this the artery springs, being attached to the ventricle by, first, the reflected layer of the pericardium, continued a short distance upon the artery, and connected to it by cellular tissue; second, by the lining membrane being continued from the ventricle into the artery; and third, by the attachment of the middle, or yellow elastic coat of the vessel, to the firm fibrous zone, or ring, which surrounds and constricts the arterial opening. This, the *right arterial tendinous zone*, stands on a plane oblique from above and without downwards and inwards, the outer edge of its upper surface is therefore the higher; it is dense and firm, like fibro-cartilage, and appears composed of three semilunar roots, convex towards the ventricle; the cornua are blended together, and thus one continuous circle is formed with three triangular projections towards the artery; the intervals between these festoons are completed by the two serous membranes, with an intervening lamina of fibrous tissue, strong, but so thin as to be translucent. The muscular fibres of the ventricle are inserted into the lower surface of these convex roots, and into the fibrous tissue in their interstices. The middle coat of the artery is connected to the outer edge of the tendinous zone, and to its anterior projections by three semicircular roots; this connexion is very close, although there is a manifest distinction between the tissues; those fibres of the artery that are connected to the projecting cornua of the festoons form a distinct curved line, in passing from point to point, while below this they are thinner, weaker, and, of course, shorter, and correspond to three small dilatations, or sinuses, in the artery, named sinuses of Morgagni, or Valsalva; internal to each of these sinuses is a semilunar or sigmoid valve. The *sigmoid valves* are three in number, one is anterior, another posterior, and to the left, and a third is to the right side; occasionally there are but two, and very rarely four; they consist of a duplicature of the lining membrane with some fibrous tissue enclosed; each is attached by its convex edge to the inner lip of the upper surface of the fibrous zone, and strong tendinous fibres are enclosed in this situation; in the concave edge also is a distinct tendinous thread, beneath the centre of which is that small, white, or yellowish corpuscle, named corpus Arantii, which thus divides this free margin into two short lunated portions; between the concave and convex borders of each valve, finer tendinous threads exist, curving from the corpus Arantii to the border of the fes-

toon. The tendinous structure in the sigmoid valves is more developed in the aorta than in the pulmonary artery; so also are the sinuses external to these valves.* Each of these sinuses may be described as bounded thus: externally by the thin, bulging, convex, fibrous root of the artery; internally, by the sigmoid valve; inferiorly, or towards the heart, by the narrow, oblique upper surface of the tendinous zone; while superiorly or anteriorly it is open in the direction of the artery. These sinuses are better developed in the old than in the young. The sigmoid valves, though thin and transparent, are strong and resisting; as their action is perfectly mechanical, they are named passive, in contradistinction to the auriculo-ventricular, which, as requiring muscular agency, are denominated active valves. Their *use* is to prevent the reflux of blood from the pulmonary artery to the right ventricle. As the blood flows into the vessel, the valves become vertical, and are pressed towards the sides of the artery, not, however, into close contact with them, as the pulmonic sinuses, which always contain some blood, are external to the valves; in proportion as the diastole of the artery is perfected the valves are more vertical and more separate from the walls, and the sinuses become fully distended; when the systole of the artery occurs the blood is pressed backwards and inwards towards the ventricle, the valves are thereby approximated to each other, and are thrown horizontally across the calibre of the artery, towards which they are concave, while towards the ventricle they are convex, the opening into which is thereby closed, and only so much blood is forced backwards as lies between the valves, or towards the axis of the passage; it has been thought by some, that the very axis is closed by the meeting of the three tubercles of Arantius; this opinion, however, is not confirmed by careful examination, for if we imitate their supposed condition during life, we shall find that the valves do not become perfectly horizontal, but that the edges rather overlap or press against each other; these tubercles also are often very indistinct; in the young they do not project even to the edge; they are, probably, intended to give additional strength in the axis of the opening, where the reflux force will be most sensibly felt; they may also serve as a fixed point for the tendinous threads enclosed in the folds.

The *pulmonary artery* ascends obliquely backwards for about two inches within the pericardium, and just as it escapes from this cavity it divides into the right and left branch; in this course it is convex forwards and to the left, lies at first anterior to the aorta, and then crosses over it to its left side. The *right pulmonary artery* is the longer branch; it turns in a transverse direction to the right side, anterior to the right bronchus, and passes through the arch of the aorta, behind the superior cava, to the root of the right lung, and there divides into three branches. The *left pulmonary artery* is short, proceeds to the left side, and, entering the root of the left lung, anterior, and rather superior to the left bronchus, divides into two branches;

* See "Heart," by J. Reid, and "Aorta," by J. Hart, in Todd's Cyclop. of Anat. and Physiol., also Anat. Generale, by Beclard.

from the division of the pulmonary artery a ligamentous cord extends backwards and downwards, in the direction of the primitive trunk, to the lower extremity of the arch of the aorta; this is the remains of the *ductus arteriosus*, which in the fœtus conveyed the blood from the pulmonary artery into the aorta, as it could not pass in any quantity through the condensed structure of the lungs; the recurrent, or inferior laryngeal nerve of the left side winds round this substance. The pulmonary artery is composed of the same number of tunics as the aorta, but the fibrous coat is much weaker, therefore this vessel, when empty or divided, collapses. In the lungs the pulmonary arteries divide into numerous branches which accompany the bronchial tubes and pulmonary veins, the artery in general above and behind, and the vein below the bronchial vessel; finally, the capillary terminations spread minutely on the air cells in innumerable ramifications, from which commence the pulmonary veins; these unite with each other, and form larger trunks, which arrive at the root of the lungs, two on each side, where they lie anterior and inferior to the pulmonary arteries; these veins then pass inwards to join the left auricle; those of the right side are concealed by the right auricle and superior vena cava, and open into the right side of the cavity; the left veins are shorter, and open into the left side, a little nearer to each other; a few fleshy fibres are continued on these vessels from the auricle, which cavity may be next examined.

The *left auricle* is situated at the upper and back part of the base of the heart, in front of the posterior mediastinum; it may be exposed either by raising the apex of the heart, or removing this organ from the body, and placing it on its anterior surface; like the right, it may be divided into the sinus venosus, and the auricular appendix or process; the sinus is somewhat square, smaller than the right, but its parietes are thicker and stronger, and therefore more opaque; from its anterior, upper, and left extremity the appendix passes forwards, and overlaps the origin of the pulmonary artery; this appendix is longer, more curved, and irregularly notched than that on the right side, and communicates by a well defined opening with the general cavity. Open this chamber by a perpendicular incision along its posterior part in the middle line; internally we perceive it smooth, except in the appendix, where a few fleshy fasciculi appear, as in the right side; the posterior wall is flat, and corresponds to the œsophagus in the posterior mediastinum; the right side is the septum auricularum, a slight depression in which, not so distinct as that in the right auricle, marks the former situation of the foramen ovale; the four pulmonary veins are seen opening into the angles of this cavity, two on each side; those of the right are immediately behind the septum, those of the left open very near each other, and sometimes in common, beneath the opening of the appendix; at its inferior and anterior part we perceive the opening into the left ventricle, circular, smooth, and marked by an opaque, dense, white line, as in the right auriculo-ventricular opening, than which this of the left side is somewhat smaller.

The *left ventricle* occupies the left and posterior regions of the heart, and forms the principal bulk of the organ; of a conical form, the base above shorter than the right ventricle by the length of the infundibulum; its point forms the apex of the heart and extends beyond the right; it is a little longer, and apparently, though not really, smaller; its walls feel firm and resisting, and do not collapse, though empty. Continue the incision already made in the left auricle, downwards through the posterior wall of this chamber to its apex, and we shall perceive the superior thickness of its parietes, excepting near the point, where, especially in old persons, they are very thin, a fact which accounts for rupture of this cavity generally occurring in this situation; the septum cordis appears to belong to this ventricle, and is concave towards it, so that this chamber appears pushed or received into the right, particularly at the upper part, from the overlapping of the infundibulum, but not so below or at the apex; the interior is not so much, or so deeply reticulated as the right, except near the point where it is very much so. This cavity presents also the three species of carneæ columnæ; the musculi papillares are very large, but only two or three in number; they arise low down near the apex, one from the posterior wall, near the septum, the other from the junction of the left and posterior wall; they ascend, and about the middle of the cavity end in blunt points, often bifid, and sometimes trifid; to these the chordæ tendineæ are attached, which also are stronger and thicker, but fewer in number, than those in the right; some few of these threads merely pass from one papillary muscle to another; the others extend to the two valves of the auricular opening; some of these divide and are inserted into both curtains, and from each of the muscles chords pass to both valves, so that they interlace; they are attached not so much to their margin as to their dorsum, or ventricular surface, on which they form an expanded interlacement, and contribute much to their strength; from this net-work some of the chordæ tendineæ pass up to the margin of the auricular opening, and are inserted into its tendinous zone. The walls of the ventricle are smooth above towards the base, in which are seen the openings of the auricle and of the artery; the latter is smaller and directly in front of the former, and, like that of the pulmonary artery, is furnished with three sigmoid valves. The auricular opening is much larger, a little to its left side as well as behind it; and, like that in the right ventricle, though smaller, is also provided with folds or curtains, which, however, are only two in number, and are named the *mitral valves;* the auricular and aortic openings are very close, the anterior mitral valve only intervening; this is so joined to the base, or origin of the adjacent or posterior sigmoid valve of the aorta, that if these two valves be removed the base of the ventricle will then present but a single orifice. The auricular opening is in the upper and back part of this cavity, of a circular or rather oval figure, its long axis transverse, and therefore nearly at right angles with the axis of the right auricular opening, which is longer and directed from before backwards; it is surrounded

by a white and dense tendinous zone, from which a fibrous expansion descends, enclosed in the valvular duplicature of the lining membrane, the latter soon divides into two principal segments, one anterior and a little towards the right, the other posterior to this foramen and somewhat to the left; the anterior mitral valve is much larger, and directly intervenes between this and the arterial orifice, and, like the septum of Lieuteaud, in the right ventricle, divides this also into an auricular and an arterial chamber, and which can only communicate below this valve; this larger curtain also is supposed to answer the purpose of preventing the influx of blood into the aorta during the diastole of the ventricle; this object, however, is also secured by the aortic valves, for during the ventricular diastole the artery is in its state of systole, and, of course, is closed by the sigmoid valves, which are then across the mouth of the vessel. The posterior, or left curtain is shorter and more fixed, as one or two tendinous threads pass from its dorsum to the wall of the ventricle; both these curtains are strengthened not only by the fibrous expansion they enclose, and by the tendinous interlacement on their ventricular surface, but also by containing, particularly the anterior one, firm cartilaginous tubercles, and even not unfrequently bony laminæ, the former near their margin, the latter near the base. The mitral valves are stronger and more efficient as such than the tricuspid, and their office is analogous: as the blood descends into the ventricle, they are separated from the axis of the opening, and the larger is pushed beneath and across the mouth of the aorta; as the diastole of the ventricle is perfected, the blood fills every recess, and, of course, occupies the spaces between the valves and the walls of the cavity; in the systole of the ventricle they are approximated, and the papillary muscles, which must also contract, draw these curtains closer and closer, so as gradually to convert the opening into a narrow conical passage, the apex below, and finally to close it, while at the same moment that leading into the aorta is opened freely for the entrance of the fluid. The contractile efforts being directed upwards towards the base, accounts for the thinness of the apex contrasted with the muscular wall in the centre and above, at the same time it explains why, in cases of obstruction to the circulation, from any morbid cause, the former usually yields, and not unfrequently ruptures of a sudden. The opening of the aorta is directly in front and a little to the right of the auricular; leading to it, the surface of the ventricle is smooth, white, and polished; within the contracted orifice are seen the three semilunar valves, one anterior, another to the left, and the third to the right side. The attachment of the aorta to the ventricle, and the structure of its valves and corresponding sinuses, are so perfectly similar to those of the pulmonary artery, which have been already so minutely examined, that it would be superfluous to repeat the description of such analogous parts; it is only necessary to observe, that all the tissues in the aorta are stronger, the tendinous ring from which it springs is more distinct and prominent, the sinuses of Valsalva, or Morgagni, more developed, the sigmoid valves larger and thicker, and

the corpora Arantii in particular are much more prominent. Above the free margin of the anterior and left sigmoid valves are the orifices of the right and left coronary arteries, the nutrient vessels of the heart; if we press the valves against the sides of the artery, into that position in which we may suppose them placed in the systole of the ventricle, we shall find that they do not close or cover the mouths of these vessels, we may therefore infer, that the coronary arteries of the heart are filled synchronously with all the branches of the aorta. The root of the aorta is implanted into the anterior angle between the two auriculo-ventricular tendinous zones, and its posterior half is intimately connected to both; its anterior portion is directly over the septum ventriculorum, which at this spot is thin; the root of the aorta occupies a portion of that space which intervenes between the origin of the pulmonary artery and the right auriculo-ventricular zone, while that of the pulmonary artery from the infundibulum is superior, anterior, and a little to its left side; these two roots are very close together, being only separated by the upper thin edge of the septum cordis; in a horizontal section of the heart made on a level with the base of the ventricles, when the organ has been removed from the chest, the four great openings will be found to have the following relations to each other from the right to the left side: first, the right auriculo-ventricular; second, the aortic; third, the pulmonic, also on a plane anterior to all; and fourth, the left auriculo-ventricular; and as the auricles are posterior to the ventricles, their openings are behind the arterial, and their zones are conjoined towards the mesial line, while the arteries springing from the forepart of the ventricles appear to issue more from the centre of the heart, the auricular sinuses being behind, while the appendices bending forwards overlap them in front. In the common central point of attachment, between the root of the aorta and the two auricular tendinous rings, we find a dense, compact, fibrous, and even sometimes a cartilaginous tissue, of somewhat a semilunar form; this serves as a firm and incompressible point of support for these three great openings, and of attachment and action for the muscular fibres. It is in this very situation in the larger ruminantia that we find a distinct and perfect bone is placed; and in the same place, too, we not unfrequently detect in the very aged heart of man, earthy and perfect ossific deposits, which sometimes extend even into the mitral valves, particularly the anterior one, and, if small, without impairing their mobility; one example, among many others that might be adduced, of abnormal appearances in the human subject being, as it were, repetitions of, or degenerations into forms and structures which in other animals are the normal and the determined conditions. It has been just before observed, that the roots of the aorta and the pulmonary artery are very close together, the superior edge of the septum ventriculorum alone intervening; in the very young embryo this septum does not exist; it commences below and increases upwards, unlike the septum auricularum, which descends, assisted by the valve of the oval hole which rises from below. The last part of the septum cordis to be formed is the upper edge which

is immediately beneath the two great arteries; previous to the development of this septum, these vessels arise by one common tube, and this by the growing and ascending septum ultimately becomes subdivided into the pulmonary artery in front, and the aorta behind. These facts explain certain irregularities in these parts which we occasionally find in the infant, still more rarely in those of maturer years, such as a communication between the ventricles; when this exists it is found at the upper part of the septum, and may be considered as the result of some delay or arrest in the growth or completion of this partition; the same explanation will account for the aorta in some cases arising by a double origin, or rather springing out of both ventricles, as also for the aorta and pulmonary arising by a common stem, or, though rising distinctly, yet having a communication close to their roots. These and many other deviations from the established plan, and which may be regarded as abnormal, when found in the matured fœtus, and which are usually incompatible with any long continued independent existence, were yet, however, in all cases, at an earlier period, their actual, though but their transient condition; and it appears equally interesting to remark, that many of these peculiar conditions which are only temporary in the fœtus, and which are considered abnormal when continued in the adult, are, in most of the class Reptilia, the normal, the permanent, and the necessary arrangements.

The *aorta* at its origin is covered by the infundibulum and the pulmonary artery; it ascends obliquely forwards and to the right, as high as on a level with the cartilages of the second rib of each side; it then passes backwards, and to the left side; and lastly, descending as low as the fourth dorsal vertebra, it becomes closely attached to the spine; this portion of the aorta is called the *arch*, at the termination of which this vessel receives the name of thoracic or descending aorta, which descends through the posterior mediastinum, as was already stated. The *arch of the aorta* is divided into the ascending, the transverse, and the descending; the first is the longest portion, and in general is so much dilated at the upper and convex part as to have received the name of the *great sinus;* this *ascending* portion is within the pericardium, covered at first by the pulmonary artery, it afterwards lies between this vessel and the vena cava; from the commencement of this the two coronary arteries arise; the *middle* or *transverse* portion of the arch lies above the pericardium and in front of the trachea; from it arise the innominata, left carotid, and left subclavian; the *descending* portion bends behind the root of the left lung, and is connected to the pulmonary artery by the remains of the ductus arteriosus; through the arch of the aorta, the right pulmonary artery, left bronchus, and left recurrent nerve pass.

The heart is composed of several tissues, first, the reflected serous layer of the pericardium; secondly, the muscular fibres which constitute the greater portion of the organ; thirdly, tendinous and fibrous structures, which are only found at the four orifices in the heart and in the four sets of valves connected therewith; fourthly, a fine lining

membrane, in many respects resembling the serous membranes; and fifthly, the common elements of all organized parts, viz., cellular tissue, vessels, and nerves. The external serous membrane has been already described; it is thicker and more easily admits of separation on the auricles, and on the roots of the large vessels, than on the ventricles.

The inner membrane is termed the *Endocarde;* it may be traced from the entrance of the two venæ cavæ, the inner coat of which it forms, into the right auricle which it lines throughout, forms the Eustachian and the coronary valves, is smooth and polished, and adheres to the muscular fibres by such a close and fine tissue, as to be difficult of demonstration; it then passes through the right auriculo-ventricular opening, adheres closely to its fibrous boundary, increases in density, and forms the loose, pendulous valve, named tricuspid, from the root of which it is expanded over the inner surface of the ventricle, of such extreme fineness as to be perfectly transparent, involving all the carneæ columnæ and coating all the areolæ between these; as it approaches the orifice of the pulmonary artery it is stronger, adheres to the line of its origin, assists in forming the sigmoid valves, and becomes continued into the lining internal coat of that vessel and of its ramifications. In like manner, through the left cavities of the heart, we can trace it from the pulmonary veins into the left auricle, thence into the left ventricle and aorta, forming in its course the mitral and the sigmoid valves. The endocarde is thicker in the auricles than in the ventricles, and more so in the left than in the right; its smooth and polished appearance causes it to be ranked as a serous membrane, with some characters, however, peculiar to itself. It serves to connect the muscular fibres together, and, in the auricles especially, to complete the walls in their interstices; by its duplicatures it also forms the curtains in the valvular apparatuses at the different openings, while its smooth surface facilitates the passage of the blood through the chambers of the heart, and prevents its adhering to any of the irregularities they present; analogy renders it more than probable (though difficult to determine), that this membrane, not only in the heart, bnt through the whole vascular system, exhales some fine vapour which must facilitate the circulation of the blood.

The structure of the heart and the roots of the large vessels are supplied with blood by the two coronary arteries, the openings of which from the aorta have been already noticed as just above the edge of the anterior and left sigmoid valves and sinuses; these vessels can be traced without much dissection; dividing the infundibulum will expose their origin, and their course is seen by removing the serous membrane and the cellular and adipose tissue in the cardiac grooves.

The *right coronary artery* supplies the right auricle, the posterior part of both ventricles and the thin edge of the heart; it *arises* from the fore-part of the aorta, above the anterior sigmoid valve, and appears between the infundibulum and the right auricle, sinks into the auriculo-ventricular groove, winds round to the back part, sending a long branch along

the anterior thin edge of the heart which reaches to the apex, and then, opposite the posterior vertical groove, it ends in two branches, one descends in this groove along the back of the septum to the apex, and forms a vertical circular inosculation with the left coronary; the other continues round in the superior sulcus, and, meeting the left artery, forms a superior circular inosculation at right angles with the former; this horizontal coronary inosculation is partly concealed by the trunk of the great coronary vein.

The *left coronary artery* is somewhat smaller; it supplies the left auricle, left ventricle, and the septum; its origin is concealed by the infundibulum, but it soon appears between this and the left auricular appendix, descends a little to the left, and divides into an inferior and superior branch; the latter is the smaller, it winds round in the auriculo-ventricular sulcus to the back part of the heart, and meets the circular branch of the right; the other branch, which is inferior, anterior, and the larger, descends tortuously in the anterior vertical groove as far as the apex, where it joins the branches from the right; in this course it supplies the left ventricle and the septum cordis; the coronary arteries communicate freely and frequently, not only in the two circles already mentioned, but by numerous branches on the aorta and pulmonary artery, on the surface and in the substance of the parietes of the heart. These arteries are frequently found spotted with calcareous grains, and sometimes as contracted rigid tubes; in such cases the muscular structure of the heart appears pale, flaccid, and atrophied; they also often present a flattened and a whitish aspect; sometimes they appear a little dilated and very tortuous, and surrounded by serous infiltration; I have seen them slightly varicose; in an old person they are usually imbedded in fat.

The *cardiac veins* do not exactly correspond to the arteries; there is but one considerable vein, and this does not accompany either artery through its entire course. The cardiac veins are great and small.

The *great* or the *coronary vein* commences in a number of small branches about the apex, ascends in the anterior vertical groove, receiving anterior cardiac branches, both superficial and deep, and, increasing in size, it turns round the base of the heart, first to the left and then to the back part, lying in the left auriculo-ventricular sulcus, superficial to the superior arterial circle; in this situation it receives posterior cardiac branches, auricular, ventricular, and interventricular, and appears oftentimes so dilated as to have received the name of coronary sinus; it then opens into the posterior inferior part of the right auricle, to the left of the inferior cava, being previously dilated into a sort of ampulla; the opening is concealed by a semilunar valve, beneath which the orifice may be seen in a sort of smooth, deep sinus, and close to it very frequently are two or three other small venous openings. In the vertical part of its course it receives both deep and superficial branches from the ventricles and their septum, in its circular portion it receives a very large branch (the left cardiac vein), which ascends from the apex along the left side,

then, passing backwards over the corresponding artery, joins it at right angles; the coronary vein next receives several branches from the back part of the left auricle, and from the back of the left ventricle; a considerable one, also, from the septum cordis joins it near its termination, but frequently opens distinctly into the auricle in the same sinus and beneath the coronary valve.

The *small cardiac veins*, which are two or three in number, also one from the anterior edge of the heart (the vena Galeni), are situated on the anterior surface of the right ventricle, and often open separately into the lower part of the auricle; these veins return the blood from the anterior surface of the organ, while the great coronary returns it from the left and posterior regions, from the septum, and partly also from the anterior or right surface of the heart. The cardiac veins want valves except the single semilunar fold in the right auricle, but this is seldom a perfect valve; injections can very generally be made to pass from the cavæ through the auricle into this vein, and so fill all its branches; during life, however, the contraction of the surrounding muscular fibres may assist this valve in closing the subjacent sinus against regurgitation; this point, however, may be considered as doubtful, for the valve is often defective, and the circular portion of the vein is occasionally found considerably dilated; in such cases, most probably, regurgitation may have occurred during life, as it does into the venæ cavæ, especially if there have been any obstruction to the pulmonary circulation.

The *nerves* of the heart are derived from the sympathetics, par vagum, and recurrents; the branches arising from these different sources are soft and grey, they all converge to the concavity of the arch of the aorta, and form, in front of the trachea, the *cardiac plexus*, which is a very entangled network of filaments, usually enclosing one or more masses of small, irregular-shaped ganglions; the chief cardiac nerves arise on either side of the neck from the superior, middle, and inferior cervical ganglions, and are named accordingly the superior, middle, and inferior cardiac nerves, they are, however, very irregular in number and size, and often so indistinct as not to conform to any given description; frequently there are only two on the left side; these nerves are joined above by many delicate filaments from the par vagum, and lower down by several large branches from the recurrents. From the great cardiac plexus pass off two principal divisions, each of which forms a plexus surrounding either coronary artery; these are named the *coronary plexuses*, right and left, the latter is the larger, and supplies the left side of the heart; they consist of numerous very fine filaments which accompany the ramifications of the arteries, and can be traced as white lines, on the surface of the heart, beneath the serous membrane, for a considerable distance from the base towards the apex, and finally they enter into the muscular structure along with the capillaries, by such minute fibres, that the eye cannot determine their exact mode of termination; the greater number are distributed to the ventricles and but comparatively few

to the auricles; if the heart have been previously boiled or macerated in spirits, their course can be more easily traced. (See *Nervous System.*)

The fibrous and tendinous tissues in the heart have been already partially noticed; they exist at the four orifices, in the valves, and chordæ tendineæ; they form a sort of framework or foundation for the attachment of the two great arteries, and for the support of the muscular structure. Each auriculo-ventricular opening is surrounded by a strong tendinous zone, to which the muscular fibres of the auricle are attached above, and those of the ventricle below; that of the left side is stronger than the right, both are stronger and broader on the ventricular than on the auricular aspect, and the plane of each is oblique from before backwards and downwards; from each an expansion is derived, which is enclosed in the mitral and tricuspid valves, and which imparts to them considerable strength and resistance; the right margin of the left ring is closely connected to the aortic zone.

The tendinous rings surrounding the arterial openings have also been already described, they are, of course, smaller, but they are firmer than the auricular, and the aortic is more so than the pulmonic; each circle is smaller than the circumference of the artery immediately above; from these also, tendinous expansions proceed, six in number, that is, one into each semilunar valve, and one into each of the angular spaces between the thin fibrous roots of the artery; connected with the auriculo-ventricular valve also are the tendinous chords from the carneæ columnæ, these present all the characters of true tendons, they are enclosed in the fine membrane of the ventricles, and are very distinct on the dorsum of the valves, at the root or fixed edge of which they are inserted into the tendinous rings; some of these fibres often present a reddish appearance, probably only from being stained by the blood, at first view resembling muscular fibre, and some have supposed that such really exists in these valves, and that it even becomes occasionally much developed in certain diseases of the heart; however, the most careful examination fails to detect any such muscular structure in a satisfactory manner in the human subject, though in some of the larger animals it is manifest, and in birds one division of the tricuspid valve is wholly muscular. Tendinous fibres also exist, and have been already noticed in the arterial valves.

Muscular tissue is the principal component of the heart, and constitutes its most essential element; the heart, in fact, is a hollow muscle, or rather two hollow muscles, one auricular, the other ventricular, these are distinct, and independent of each other; and each of these again is subdivided into two, a right and left, which in the perfect organ, are separated by distinct septa, so that the heart is truly quadrilocular; the septa are formed of two laminæ of endocarde, with an intermediate muscular stratum derived from an inflection of fibres from the walls; the ventricular septum is very thick and eminently muscular, the endocarde being as nothing; it appears to belong to the left ventricle, and is convex towards, or, as it were, pushed into

the right; the auricular septum is much thinner, contains but little muscular tissue, and is chiefly composed of the lining membrane, the two laminæ of which are very distinct and strong; this septum appears to belong to the right auricle rather than to the left, and is convex towards the latter. The cardiac muscles are usually regarded as appertaining to the involuntary class; in point of function they do so in an eminent manner, as during health and rest they act without our consciousness, but in structure they present peculiarities which distinguish them from both the voluntary and involuntary; thus, in respect of colour and consistence, they exceed the involuntary, and equal, if not surpass, most of the voluntary, the latter also they resemble in possessing a distinct tendinous structure, which serves as a fixed point of attachment, or of origin and insertion, and some of the fleshy fibres end abruptly in the tendinous; many of the fasciculi also have a parallel course, as in the voluntary, yet again they constantly intermingle and alter their direction as do those of the involuntary muscles; the fibres and fasciculi are much more intimately united to each other than those in either class, and the mode of their connexion constitutes one of the most striking peculiarities; in all other muscles of either class the fasciculi are attached together by cellular tissue, but in the muscles of the heart there is so very little of this common vinculum, that the close connexion of their fibres must depend partly upon their compact juxta-position, and partly upon their complex interlacement. Cellular membrane is seen on the surface and edges of the organ, particularly on the anterior, also around the nutrient vessels in the vertical grooves, and in the deep circular auriculo-ventricular channel; in the latter it penetrates deep to the tendinous zones, as the fleshy fibres above and below this line are perfectly distinct, but along the vertical cardiac grooves it is confined to the vessels, and does not pass to any depth, there being only an indentation, but no separation or division of the muscular structure. It is not difficult to understand the design, and to perceive the special relation of this peculiar condition; this close intertexture of a considerable mass of muscular fibre in the walls, and the absence of any passive yielding material, impart a certain elasticity and a degree of strength well adapted to resist over-distention, while the alternate relaxation and contraction effected by this uniform structure is peculiarly well suited to its functions; the cellular tissue found more or less in all other muscles admits of motion between the fasciculi themselves, and allows one portion of the muscle to contract, while another is relaxed, but in the heart the whole of each muscle must and does contract at once; the fibres which enclose each ventricle, and those which connect both, act at the same moment; the two ventricles, with their valve muscles, and septum, being synchronous in action; and so the fibres proper to each auricle, with the connecting fibres of both, act synchronously, and there can be no partial action or partial relaxation either in the superior or inferior cardiac muscle. From this peculiar disposition of cellular membrane on the heart, we can explain the appearances which adi-

pose deposits present, and which here, as in all other situations, have this tissue as their nidus and support; on the heart fat is often deposited particularly in advanced life, and is found where the cellular tissue exists, in the circular and vertical grooves, in the course of the blood-vessels, and on the surfaces, especially the anterior, but not between the muscular fasciculi or on their internal surface; in some instances the walls of the right ventricle appear converted into fat, but the deposit has either increased from the surface, or the structure appears to have been altogether changed, the muscle becoming soft and oily, as if it were partially dissolved or degenerated into this substance; this change is very seldom found in the left ventricle or in the septum cordis; we may conclude, therefore, that the cardiac muscles cannot, in compliance with mere systematic arrangement, be placed in either class, but must stand alone, being muscles "sui generis" formed and endowed in a special manner and for a special purpose. The muscular fibres of the heart cannot be traced in the ordinary progress of dissection; the organ must be prepared with care, and much time devoted to the examination; the student will require at least two human hearts, one very young, the other adult, also the heart of an ox and calf, and of a sheep and lamb; these must be washed free from blood; the serous and cellular membrane, vessels, and nerves removed as fully as possible; they should then be boiled for a short time, then macerated, and partially dissected, then boiled and macerated again; by repeating these processes with care, the structure will become loosened, though the fibres are hardened, and the latter may be separated, so as to render the course and arrangement of the fasciculi tolerably evident.

The *muscular fibres of the auricles* are independent of those of the ventricles, and are much fewer in number, hence these chambers feel weak and flaccid when contrasted with the latter; these fibres are attached to the upper narrow border of the auriculo-ventricular tendinous rings, also to that of the aorta, they consist in some situations of two planes, a superficial and a deep; the first is common to both auricles, the latter is proper to each; these two, however, are not separate, distinct, and perfect throughout, wherever any of the superficial fibres are deficient, some of the deep layer will supply their place, and frequently the fibres of one lamina, by a change in direction and course, will become a portion of the other. The superficial or common lamina consists of fibres, mostly transverse, thinly expanded over the right auricle, and attached to its tendinous ring, they pass across the septum auricularum to envelope the left, and to connect both; on their anterior walls these transverse fibres are very distinct and strong behind the ascending aorta, towards which they present a marked concavity, and to which some fibres are usually attached; towards the borders these fibres expand and separate to enclose rather than cover the appendices, and to admit the entrance of the great veins; along the septum some fibres bend inwards into it, and surround three-fourths of the oval fossa like a sphincter; in the valve itself a few

muscular fibres may be detected, this layer is very weak on the right auricle, much stronger on the left, and most distinct on the front of each. If these superficial transverse fibres be carefully divided over the septum auricularum, and the handle of the knife insinuated into the posterior groove, we may, with much care, separate the auricles and divide the septum, provided it be complete, into two distinct portions, we shall then perceive the form and relative thickness of each, as also how the septum belongs to the right more than to the left, and the right auricle is convex towards the left and pushed into or received by it.

The deep muscular fibres are proper to each chamber, and are connected to the lining membrane; arising from the aortic and auricular zones, they mostly take a circular course round the transverse axis, many, however, pass off obliquely or in a ramose manner, some enter the septum, some become superficial, others encircle, like sphincters, the pulmonary veins, and form loops around and between them, also round the entrance into the left auricular appendix, and interlace with the superficial fibres, especially in their appendices, where their plexiform ramifications produce the peculiar reticulated texture, leaving interstices, wherein the internal and external serous membranes are in contact; the course and the irregular ramifications of these fibres are best seen from the interior of the auricles, arising from the tendinous circles the columns ascend in different directions, and soon divide and subdivide, communicating and intertwining in a manner unknown in any other muscular structure, except, perhaps, in the muscular coat of the urinary bladder, which, in this one respect, bears a remote analogy to this arrangement.

The action of the auricular muscles must be towards their fixed points, namely, the tendinous rings, they will, therefore, contract these chambers in all directions, and urge their contents through the large openings into the ventricles; it is doubtful whether they affect the venous openings, their arrangement on the pulmonary veins would incline to the opinion that their contraction may partly propel their blood into the auricle, and during the systole of the latter may also constringe their openings, so as to prevent regurgitation into them; the annular fibres also in the septum may, at an early age, assist the valve in the more perfect closure of the foramen ovale.

The muscular structure of the two ventricles constitutes the principal portion of the heart, and gives to it its peculiar form and consistence; these fibres, like those of the auricles, are divisible into superficial or oblique, and deep or circular, these can generally be made tolerably distinct and separate by dissection; the superficial are common to both cavities, and the deep are proper to each, so that (as Cruveilhier observes) the ventricles are two distinct sacs, enclosed in a common sac (vol. iii. p. 25). The superficial fibres are very long, and disposed in laminæ or bands which can be separated and raised off one another, not, however, completely, as fibres pass to and fro connecting them together, and crossing or intersecting them obliquely; none of

these fibres are perfectly vertical, or perfectly transverse, they are all oblique, and the superficial are more so than the deeper; none of them are superficial through their entire course, but only as they descend; they become deep or internal as they ascend; many of the fasciculi are of great length, arising from one part of the auricular tendinous ring, then, descending to different distances, they ascend, many of them to be again attached to the same structure. The most superficial fibres on the anterior surface arise from the inferior broad margin of the auricular tendinous ring, descend obliquely towards the left as far as the apex, here they interlace with the corresponding fibres from the posterior surface, which, though more vertical, also descend obliquely to the right, they then ascend internal to the deep fibres, some terminate in the mammillary muscles, others ascending in the septum, and in the internal wall of the left ventricle, are again inserted into the auricular ring; all these bands are common to both ventricles, being superficial in one, and deep-seated in another, and proceed in this spiral manner, and are broader near the base than the apex of the heart; the superficial are longer than those deeper seated; the ascending and descending portions of each form arches or loops, convex towards the apex, and concave upwards, and each encloses a similar but shorter loop in succession, hence the walls are thicker in the base and centre than at the apex. As the superficial oblique fibres from both surfaces converge to the apex, they present in it a curious twisted vorticose appearance, both set interlacing and then ascending on the inner surface of the parietes, or in the septum; thus the apex in its anterior and left side is formed by the fibres from the anterior or right surface, and in its posterior and in part of its right side by those from the left or posterior surface of the heart; it consists of a number of bent or convex fasciculi, which from this point radiate upwards and in a stellate manner in all lateral directions; when the serous membrane has been removed from this spot the interstices between these interlacing fasciculi can be expanded and stretched, the endocarde at the same time giving way, so that we can open into either cavity, without actually dividing any muscular fibre, because the deep layer of muscle does not descend quite to the point, hence another reason why the apex, especially of the left ventricle, is more liable to yield and to give way than any other portion of the parietes. The posterior superficial fibres ascend from the apex, partly in the septum, in the carneæ columnæ of the left ventricle, and in its posterior wall to the left auricular tendon; but very few of the superficial fibres cross the anterior vertical cardiac groove, from the right to the left ventricle, except near the apex; but several sink into the septum and intermingle with the ascending fibres, hence it is very difficult to unravel the septum in a satisfactory manner; on the posterior vertical groove a number of fibres pass across from the left to the right ventricle and gradually bend into their course, while others pass into the septum; if the fibres crossing these two grooves be divided, we can, by patiently teazing through the septum with the handle of the knife,

divide it into two laminæ, and thus separate the ventricles; we shall then be able to contrast the two, and to judge of the superior thickness and mass of the left, how it is pressed into the right, and how at the upper part, the infundibulum, or conus arteriosus of the latter, is bent over it like the beak of a bird. If the same operation have been successfully performed on the auricles, we shall then be able to separate the two perfect hearts, and again replace them, and thus accurately examine the relative position of the four openings in the circular auriculo-ventricular groove, also the position of the aortic root, behind and a little to the right side of that of the pulmonary artery, between the infundibulum and the right auriculo-ventricular foramen, and finally, the perfect crossing of these two great arteries. The deep muscular fibres of the ventricles are proper to each cavity; their direction is generally circular, though many are spiral, and some are oblique; they are placed between the descending and ascending portions of the superficial or common fibres, they are not, therefore, exposed to any extent, either externally or internally, without removing a portion of the latter, though internally they are in many places in contact with the endocarde; they encircle each cavity, the superior rings are the largest, are attached to the auricular tendons, and many of the middle bend spirally to attain the same attachment; the inferior rings diminish in size towards the apex, where they are very small and contracted; they do not extend to the very point, and through the last and smallest rings the superficial or common fibres ascend; each of these circular muscles is likened by Cruveilhier to a small oval barrel; the large end above, open into the auricle, the small end below, a little short of the apex, open also, but occupied by the ascending common fibres. The ventricular muscles differ from the auricular in being much more fleshy, red, and strong, also in the direction of the fibres; the superficial in the auricular being obliquely transverse, in the ventricular obliquely vertical, while the deep fibres in the former are circular round the transverse diameter of the cavities, and in the latter they are circular around their vertical axes. The action of the ventricular muscles must be to approximate the walls of the cavities they enclose, and as their fixed point is above at the fixed base of the heart, they must also shorten these chambers and urge their contents towards that point; and the mammillary muscles having disposed the auricular valves, so as to close the auricular openings, the blood is necessarily propelled into the two great arteries by the synchronous contraction of these muscles; the right ventricle, having to propel the blood through the pulmonary circulation only, requires less muscular energy and structure than the left, which has to influence the circulation through the entire system; and as both ventricles expel their contents superiorly, they require more muscular power in their centre and base than at the apex; for the effects of the systole must be, first to close this point, and then propel the blood from it to the centre and base of the cavity, and where, of course, a greater exertion is required to propel it into the arteries; this accounts for the thinness of the

walls at the apex contrasted with the centre and base; the most fleshy part in the left ventricle is about its middle, and in the right nearer to its base.

The changes in the cavities of the heart, and the actions of the cardiac muscles during life, have been observed to occur in the following order: first, the two auricles become distended with blood from the six great veins as well as from the cardiac; this state (diastole) is followed by their rapid synchronous contraction, or systole, this is accompanied by the enlargement, or diastole, of the two ventricles, and this is succeeded by their synchronous contraction, or systole, whereby the blood is propelled into the two great arteries; then a rest or pause ensues, during which the auricles are again gradually filled from the veins, and the same train of actions follows. The auricular diastole commences during the systole of the ventricles, and is completed during the pause or rest, in a longer or shorter time, according as the venous circulation is slow or rapid: the contractions of the auricles appear rather feeble, and are rapidly followed by the systole of the ventricles, or, as it is termed, the systole of the heart. The diastole of the ventricles presents two stages, the first occurs suddenly after their systole, in it the heart returns to its former state, as it were, of rest, and the apex retires backwards and downwards; the second stage is also rapid, and attended with a sudden and general expansion; the parietes feel smooth, soft, and flaccid: the first stage is owing, most probably, to the elasticity of the muscular tissue, the fibres of which must have been more or less under compression during the systole; the second stage depends on the systole of the auricles pouring in the blood, which, in the first stage, only flowed in a passive manner; many, however, incline to the opinion, that the diastole of the ventricles is not a mere passive or elastic yielding, but a real active dilatation, whereby the blood is drawn in to fill the vacuum, as well as impelled by the contraction of the auricles. In the systole the surface of the ventricles is rugged and firm, and the superficial veins distended, the cavities contract in every direction, the vertical and transverse axes are diminished, and the apex describes a spiral movement from right to left, and from behind forwards, so as to strike against the fifth and sixth ribs on the left side; the whole heart appears tilted a little forwards, but most probably the apex only is moved in this direction in any sensible manner. That the apex should thus advance to the wall of the thorax during the systole, that is, during the contraction and shortening of the ventricles, is contrary to what, from *a priori* reasoning, might be expected, and is, most probably, owing to the peculiar spiral arrangement of the muscular fibres, their greater length and quantity in front, their fixed attachment above to the auricular tendinous zones, their arched or looped course, and the terminations of several in the carneæ columnæ, in the septum, and in the parietes; this phenomenon, however, has also been attributed to other causes, namely, first, to the curvatures of the aorta and pulmonary artery: when the ventricles urge the blood into these arteries, it has been supposed that an effort is made to bring the heart and these

curved tubes into one straight line, but the vessels being fixed, and the apex of the heart moveable, it rotates upwards and forwards in an arc of a circle, and therefore approaches the ribs: secondly, to the position of the auricles, especially of the left, above and behind the ventricles; both auricles being distended at the moment of the ventricular systole, it has been maintained by some, must push forward the heart, and the apex in particular: and thirdly, this last agency has been supposed to be increased by the reflux of blood from the conical spaces enclosed between the tricuspid and mitral valves, meeting that which is flowing in from the large veins, and thus causing such a sudden distention of the auricles as may account for the protrusion of the heart; but none of these latter explanations will stand the test of minute examination, and we are therefore disposed to infer, that this change in position of the heart's apex rather depends on the arrangement of the muscular fibres as stated above.

The actions of the heart during life are accompanied by two distinct sounds, audible with the stethoscope; the first is dull and prolonged; the second follows this rapidly, is sharp, clear, and quick, and is succeeded by a pause, after which the same sounds are again heard. The first sound is synchronous with the impulse of the heart against the ribs, or with the ventricular systole, and with the arterial pulse near the heart; the second sound is synchronous with the first stage of the ventricular diastole; the two sounds therefore correspond to one arterial pulsation. Various explanations have been offered, to account for these phenomena, such as the "*bruit musculaire*," attending the muscular contraction, particularly of the ventricles; the impulse of the latter against the chest in the first instance, and afterwards against the thoracic viscera; the propulsion of the blood through the auriculo-ventricular openings and the falling back of their valves; the rushing of the fluid over the internal rough surface of the ventricles; the sudden meeting of the auriculo-ventricular valves, by the action of the papillary muscles; the striking of the walls of the contracted ventricles against each other; the rushing of the blood towards and through the narrow arterial mouths, against the semilunar valves; and lastly, the arterial regurgitation of the blood against these valves when thrown across these openings. The limits of a work so purely practical as the present do not permit the discussion of these hypotheses, many of them ingenious; I shall, therefore, only observe, that in all probability the first sound of the heart, which is heavy and prolonged, and synchronous with its systole, is owing partly to the "*bruit musculaire*" of the ventricular contraction, and to the impulse of the apex against the ribs, and partly to the flow of blood along the rough surface of the ventricles towards and through the narrow arterial openings, partly, also, to the rapid meeting of the auriculo-ventricular valves and the equally sudden striking asunder of the semilunar valves; while the second sound, which is sharp and short, and synchronous with the first period of the ventricular diastole, depends upon the regurgitation of the arterial blood striking down the six semilunar valves during the recoil

of the elastic coat of the arteries, and the diastole of the ventricles, which tends to draw back the blood towards themselves, by forming a vacuum beneath.

The frequency of the heart's action is very variable, being influenced by age, constitution or temperament, sex, mental emotions, state of health, form and capacity of the chest, rest, exercise, position of the body erect or horizontal, time of day, condition of other functions. In the fœtus *in utero* the pulsations are so rapid as 140 in one minute; after birth about 130, at the end of the third or fourth year about 100, at puberty 80, during middle age from 70 to 75, and in old age from 60 to 50; at this period, too, they are often very irregular, sometimes quicker, and frequently intermitting; exercise and digestion accelerate them; rest and sleep have the contrary effect; inspiration also quickens, but expiration retards the actions of the heart; in the former, however, they feel weaker than in the latter. In sthenic inflammations the heart's action is usually increased in frequency and force; but in the asthenic types it is often feeble though frequent; indeed it is important to bear in mind, that frequency and force in many diseases, and in severe injuries of the nervous centres, or of important viscera, are often in the inverse ratio, the debility in the contractile power being compensated by increased frequency of action.

The heart is subject to many *diseases*, the morbid appearances of which will be soon detected by any person well acquainted with its natural structure. Carditis, or inflammation of its substance, is rare, it is usually confined to some portion of the organ, and pus is found diffused among its fleshy fibres, or sometimes collected into a cyst. Ramollissement; in this case the heart is sometimes so soft that the finger can pass through it; the colour is brown, or deep red, if the change have been recent; if chronic, pale and yellowish; this affection sometimes ends in rupture. Induration is usually confined to some portions of the heart, which will be found so crisp as to grate under the knife. Hypertrophy, or enlargement of its cavities and thickening of its parietes; this change is most common in the left ventricle. Atrophy, or diminution of the organ; its fibres are pale, flabby, and intermingled with soft adeps; in this case the cavities are not diminished in size; this change is most frequent in the right ventricle. Tubercles are sometimes found in the parietes of the heart, and are very small. Sanguineous concretions, or coagula, incorrectly called polypi, are common in the right cavities, they are usually free from the colour of the blood, and are like a mass of fibrine; in dropsical subjects they often appear gelatinous and semi-transparent; when recent they have no adhesion, but if long formed they often adhere closely. The aortic and mitral valves are often found diseased; on the latter fleshy vegetations frequently grow, and calcareous matter is very commonly deposited both in these valves as well as in the semilunar folds at the aortic opening. The left auriculo-ventricular opening is occasionally so much contracted as to embarrass the circulation very considerably, this function is also occasionally suspended by a rupture of one of the mitral or

semilunar valves. The valves at the right side of the heart are seldom found diseased. Malformation, or imperfect development, is not uncommon in this organ; thus the foramen ovale is sometimes open; also a communication between the ventricles, through their septum, occasionally exists. These conditions are usually attended with a bluish tint of the skin and other marks of imperfectly oxygenated blood.

# CHAPTER IV.

## MUSCLES OF THE BACK.

## SECTION I.

### OF THE MUSCLES.

PLACE the subject on the forepart, raise the chest by blocks, let the head and arms hang; thus the muscles in this region will be made tense. This region may be divided into three parts, the cervical, the dorsal or thoracic, and the lumbar or abdominal, conformably to the sections of the spinal column, but there is no exact limit to each, and most of the muscles extend through two or more of these divisions. Divide the integuments along the middle line, from the occiput to the sacrum; make a transverse incision from the last cervical vertebra to the acromion, and another from the last dorsal vertebra to the posterior part of the axilla; reflect the upper and lower flap of integument from the spine towards the side, and raise the middle portion from below upwards and inwards; thus the dissector can more easily expose the trapezius and latissimus dorsi muscles; the integuments in this region are dense, also the subjacent cellular tissue, which seldom contains much adeps; inferiorly it is often anasarcous; when all this is dissected from the posterior part of the trunk, we see exposed the trapezius superiorly, the latissimus dorsi inferiorly, and between these, in a small triangular space behind the base of the scapula, a part of the great rhomboid, also two or three tendons of the sacro-lumbalis, and a portion of the seventh, eighth, and ninth ribs, and of the corresponding intercostal muscles; along the middle line of the neck a strong ligament is observed (ligamentum nuchæ), at the lower part of which is a strong aponeurosis of an oval form (the cervical aponeurosis); also covering the lumbar region another still stronger is seen (the lumbar fascia); to each of these the student should pay attention. The *ligamentum nuchæ* is *inserted* superiorly into the occipital protuberance, it descends in the median line, broad above, sinks in deep, so as to form a septum between the muscles on the right and left sides, and is *inserted* by thin slips into the spinous processes of all the cervical vertebræ except the atlas, also into the first and second dorsal spines. *Use*, to support the head in flexion of the neck, and to give attachment to muscles. In man this ligament is composed of cellulo-ligamentous tissue, and is continuous with the supra-spinal ligament.

In most quadrupeds it is very strong and elastic, and presents a good example of the yellow elastic tissue. The *cervical aponeurosis* is not an independent aponeurosis, but only an elliptical portion of the tendons of the trapezius on each side of the mesial line; it extends from the fifth cervical to the fifth dorsal vertebra, narrow at each extremity, and broad in the centre between the superior angles of the two scapulæ; the fibres are transverse, and continuous with the fibres of the trapezius on each side; it gives strength to these, and binds down the subjacent muscles. The *lumbar aponeurosis*, or *fascia*, is of great strength in the human subject; like the cervical it is not an independent structure, but a common tendon to several muscles, both of the back and of the abdomen; it is also somewhat oval, attached by its inferior extremity to the spinous processes of the sacrum, and by its superior to those of the inferior dorsal vertebræ and to the two last ribs; on either side it is connected to the crest of the ilium, and to the abdominal muscles, particularly to the transversalis, also to the latissi mus dorsi and serratus posticus inferior; its internal surface is attached along the median line to the spines of the lumbar vertebræ, and on either side to the transverse processes. In the course of the dissection of the lumbar muscles, this fascia will be found to consist of three laminæ, the first, or posterior, that which is seen at present, is very strong and deeply indented in the middle line, from being attached to the spines of the lower dorsal and to those of all the lumbar vertebræ and sacrum; it gives attachment to the latissimus dorsi, serratus posticus inferior, obliquus internus, and transversalis abdominis muscles. The second or middle layer is attached to the tips of the transverse processes of the lumbar vertebræ, and lies posterior to the quadratus lumborum muscle; and the third, or anterior layer, is in front of the quadratus and psoas muscles, and is attached to the roots of the transverse processes and to the sides of the bodies of the lumbar vertebræ. This fascia gives great support to the loins, where the skeleton is comparatively weak; like the ligamentum nuchæ it supports the trunk in flexion, it also assists in maintaining it *in equilibrio* in lateral motion, and it also serves to give attachment to several muscles, which again, in their turn, serve to keep it in a state of tension; this great tendinous expansion, together with that derived from the abdominal muscles in front, forms a sort of circular aponeurotic investment for this division of the trunk. The three laminæ of the lumbar fascia are regarded by many as the three tendinous layers of origin of the transversus abdominis muscle; the posterior layer (the true fascia lumborum) being the strongest, the anterior the weakest; the posterior and middle laminæ form one great aponeurotic sheath to enclose the erector muscles of the spine; while the middle and anterior form another, which encloses the quadratus lumborum muscle; the anterior lamina is also continued on the diaphragm, and forms the external ligamentum arcuatum; these points cannot be fully examined until the abdomen has been opened.

The muscles of the back are many of them indistinct, and vary very much in different subjects, both in their appearance and in their exact

*Fig. 25.**

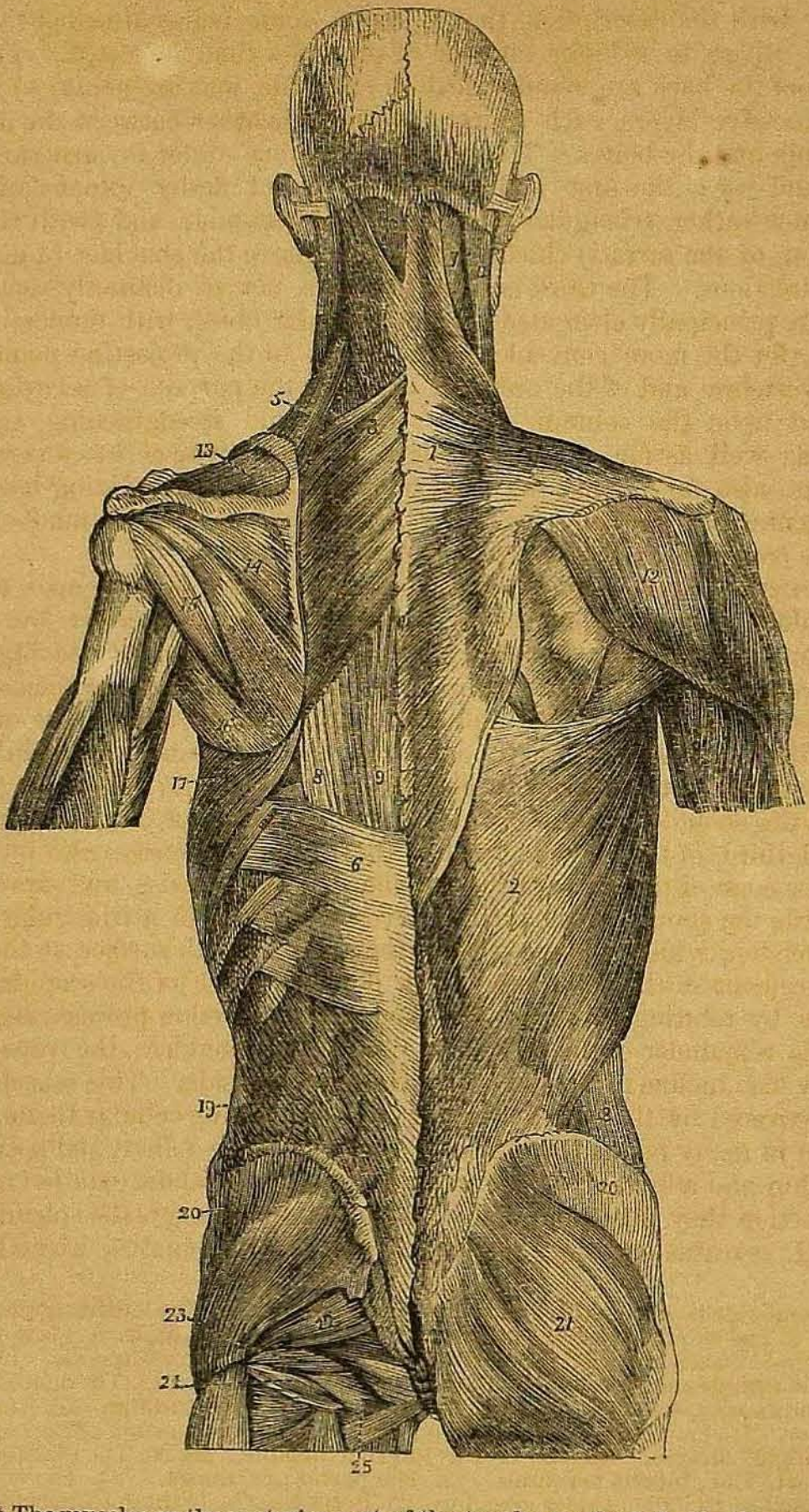


* The muscles on the posterior part of the trunk; on the left side the superficial layer has been removed. 1. The trapezius muscle. 2. The latissimus dorsi muscle.

attachments to any certain number of vertebræ; the student is not to expect, therefore, to find each muscle in this region to correspond accurately with the description that is given, some being attached to a greater, others to a lesser number of processes than is stated. The muscles of the back are symmetrical on each side, and are arranged in *four* successive layers, each nearly covering the other between the integuments and the bones. These several laminæ differ in structure, form, and use; the first and second are broad fleshy expansions, the former rather triangular, the latter quadrangular, and (with the exception of the serrati) chiefly designed to move the shoulder in different directions. The third and fourth layers, not so distinctly separable, are principally elongated slips of muscular fibres, with numerous tendons, for the more convenient attachment to the projecting points of the vertebræ and of the occipital bone, for the purpose of securing the head upon the column, and of erecting and strengthening the latter, as well as for executing slight motions between its several segments, also for moving the head upon the atlas, and rotating both on the dentatns. The muscles of the *first* layer are two in number, viz., the trapezius and the latissimus dorsi.

TRAPEZIUS, broad, triangular, the base along the spine, the apex at the shoulder, thin above and below, thick in the centre; *arises* by a thin aponeurosis from the internal third of the superior transverse ridge of the occipital bone, from the ligamentum nuchæ, and from the spinous processes of the last cervical, and of all the dorsal vertebræ; the superior fibres descend obliquely outwards and forwards; the middle pass transversely, the inferior ascend obliquely outwards; all converge towards the shoulder, and are *inserted* into the posterior border of the external third of the clavicle, and of the acromion process, also into the upper edge of the spine of the scapula. *Use*, to raise and draw backwards the shoulder; the inferior fibres, which end in a triangular-shaped tendon, which glides over the triangular smooth surface at the commencement of the spine, may draw down the base of the scapula, and thus, by rotating this bone, will elevate the acromion process, and assist the remainder of the muscle in raising the shoulder; the trapezius may also incline the head backwards and to one side. This muscle is only covered by the skin and a fine closely adhering cellular tissue; its origin in many points is continuous with that of its fellow, and both are so thin and adherent to the integuments, that without caution in the dissection they may be raised with the latter; it covers the splenii, complexi, serratus superior, levator scapulæ, supra-spinatus, a small

3. The rhomboideus minor. 4. The rhomboideus major. 5. The levator anguli scapulæ. 6. The serratus posticus inferior. 7, 7. The splenius muscle. 8. Portion of the sacro-lumbalis muscle. 9. Portion of the longissimus dorsi muscle. 10. Part of the complexus muscle. 11. Part of the sterno-mastoid. 12. The deltoid. 13. The supra-spinatus. 14. The infra-spinatus. 15. The teres minor. 16. The teres major. 17. Part of the serratus magnus. 18. Posterior portion of the external oblique muscle. 19. Part of the internal oblique. 20. 20. The glutæus medius. 21. The glutæus maximus. 22. The pyriformis muscle. 23. The superior gemellus. 24. The inferior gemellus. 25. Portion of the obturator internus.

portion of the infra-spinatus, and of the latissimus dorsi, also the rhomboid and deeper muscles; its anterior fibres are parallel to the sterno-mastoid, in contact with it above, but separated below, by fat, vessels and nerves; in some subjects a band of fleshy fibres unites these muscles above the clavicle. The spinal accessory nerve is partly distributed to this muscle, whereby it is associated with the muscles of inspiration, which it can assist by raising and fixing the bones of the shoulders.

Latissimus Dorsi is very broad, and also triangular, the superior external angle being much elongated; it covers the greater part of the lumbar and dorsal regions, and extends from these to the inner side of the arm; *arises* from the six inferior dorsal spines, and by the lumbar fascia from all the lumbar spines and supra-spinal ligament; also from the back of the sacrum, from the posterior third of the crest of the ilium, and by distinct fleshy slips from the three or four last ribs near their anterior extremity; the iliac and lumbar fibres ascend obliquely outwards; the dorsal, which are much weaker, pass transversely; and the costal are nearly vertical; all converge towards the inferior angle of the scapula, over which they glide, and from which they often derive an additional fasciculus of fleshy fibres; thence the muscle continues to ascend obliquely outwards over the teres major, and near the inside of the arm it twists beneath this muscle to its fore-part, ends in a flat broad tendon, which is closely connected to that of the teres, and is *inserted* into the concave surface and into the inner or posterior edge of the bicipital groove, anterior and superior to that tendon; a small bursa is usually found between these tendons in this situation. *Use*, to depress the shoulder and arm, to draw the arm backwards and inwards, to rotate the humerus inwards, so as to turn the palm of the hand backwards, also to depress the ribs, as in expiration; but if the upper extremity be raised and fixed, this muscle may elevate the ribs, and so assist in inspiration, as well as in raising the whole body, as in climbing.

The dorsal portion of the latissimus dorsi is covered by the trapezius; the remainder of this muscle is superficial, its origin is superior to the glutæus maximus, its anterior edge is connected to the abdominal muscles, the inferior fasciculi of the external oblique indigitate with its costal origins; it covers the serratus inferior, the lumbar muscles, and the angle of the scapula; its humeral end forms the posterior fold of the axilla; a fasciculus of fleshy fibres sometimes passes across the floor of this region, and connects the latissimus to the great pectoral muscle; between the angle of the scapula and the humerus this muscle has a twisted appearance, the lumbar and costal fibres become anterior, and are inserted into the upper part of the tendon, while the superior or dorsal become posterior, and are inserted into its inferior edge; the axillary vessels and nerves lie on this tendon at its insertion, and the bicipital groove is lined by aponeurotic fibres derived from it, and from the tendon of the great pectoral, which are thus united to each other, although previous to this they

are separated by the brachial vessels and nerves, and by the coraco-brachialis and biceps muscles; from the upper edge of the tendon a band ascends to the lesser tuberosity of the humerus, and from its lower border an expansion to join the brachial aponeurosis. Divide the trapezius and latissimus longitudinally between the spine and the scapula, reflect one portion towards the vertebræ, the other towards the side, and the second layer of the dorsal muscles will be exposed. (In dissecting off the latissimus take care not to injure the serratus inferior, which is very thin and adheres closely to it).

The second layer of muscles consists of the rhomboid, levator anguli scapulæ, serratus inferior and superior, and the splenii; a considerable portion of each of these is now seen, although they partly conceal each other.

Rhomboideus is the most superficial of this layer; broad, thin, thicker below than above; it is divided into a superior or minor portion, and an inferior or major; the *minor arises* from the lower part of the ligamentum nuchæ, and from the two last cervical spinous processes; the fibres run parallel outwards and a little downwards, and

*Fig. 26.*

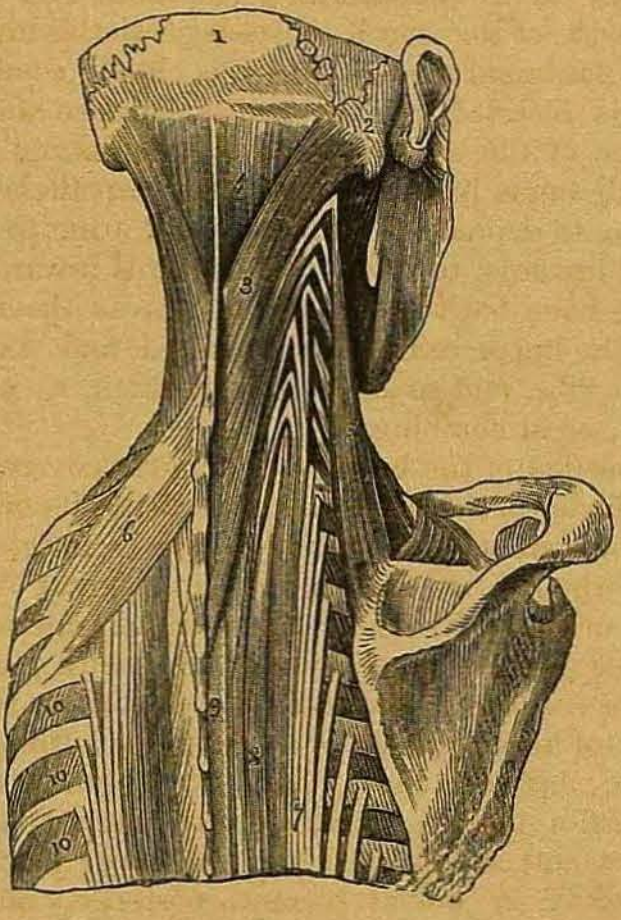


* A part of second and third layers of muscles of the back. 1. The occipital bone. 2. the mastoid process of temporal bone. 3. The splenius. 4. The complexus. 5. The levator anguli scapulæ. 6. The serratus posticus superior. 7. The sacro-lumbalis. 8. The longissimus dorsi. 9. The spinalis dorsi. 10. Portion of the external intercostal muscles.

are *inserted* into the base of the scapula, opposite to and above the spine. The *major arises* from the four or five superior dorsal spines; the fibres pass outwards and downwards, parallel to the former, and are *inserted* into a thin tendinous arch which extends along the base of the scapula from its spine to the inferior angle, also into the latter by a strong tendon with which the arch is continuous; beneath the latter, anastomosing vessels pass between the posterior and subscapular arteries. *Use*, to draw the shoulder backwards and upwards; the inferior fibres also can, by pulling back the inferior angle, rotate the scapula so as to depress the acromion process, thereby assisting the levator anguli and the pectoralis minor muscles. The rhomboid muscles are covered by the trapezius and latissimus, but a portion of the major between these muscles is subcutaneous; their origin is intimately connected with the trapezius, and their insertion is between those of the serratus magnus, and the supra and infra-spinati muscles; they conceal part of the splenii and serrati postici muscles.

Levator Anguli Scapulæ, long and flat, placed at the upper and posterior part of the side of the neck, *arises* by four or five distinct and separate tendons from the posterior tubercles of the transverse processes of the four or five superior cervical vertebræ; these soon terminate in a fleshy belly, which descends obliquely outwards and backwards, and is *inserted* into the base of the scapula, between the spine and superior angle; its *use* is to elevate the whole scapula, if assisted by the trapezius, or to elevate the superior angle alone, and to rotate the scapula so as to depress the acromion, thus cooperating with the lesser pectoral muscle; it can also bend the head a little backwards, and to its own side. It is covered by the trapezius; a small portion may be seen superiorly between this and the sterno-mastoid muscle; the tendinous origins have those of the splenius colli behind them, and of the scaleni and rectus capitis anticus major before them. Divide and reflect the rhomboid muscles; beneath these a quantity of loose cellular membrane is placed, between them and the serratus magnus, to the posterior view of which muscle the student should now attend; he may, therefore, again peruse the account given of that muscle. (See page 80.)

Serratus Posticus Superior, placed on the superior posterior part of the thorax, somewhat square, *arises* by a thin aponeurosis from the ligamentum nuchæ, and from two or three dorsal spines, forms a thin fleshy belly, which ends in three fleshy slips, which are *inserted* into the upper borders of the second, third, and fourth ribs, external to their angles. *Use*, to expand the thorax by elevating the ribs and drawing them outwards. This muscle is covered by the trapezius and rhomboid; it lies on the splenius and the deep layer of muscles; an aponeurosis is continued from it to the inferior serratus.

Serratus Posticus Inferior, at the lower part of the dorsal, and upper part of the lumbar regions, is broader and thinner than the last, *arises* by a thin tendinous expansion, which is connected through

the lumbar fascia to the two last dorsal and two upper lumbar spines; it forms a thin fleshy expansion, which divides into three or four fasciculi, which are *inserted* into the lower edges of the four inferior ribs anterior to their angles; the highest digitation is the largest, and the lowest extends as far forwards as the tip of the last rib. *Use*, by depressing the ribs it assists the abdominal muscles in *expiration;* also, by fixing the lower ribs it increases the power of the diaphragm, and by aiding this muscle in enlarging the thorax it assists in *inspiration;* the two serrati also, by making tense the aponeurosis which connects them to each other, compress and support the deep muscles in this region. This *aponeurosis* may be named *vertebral* or *dorsal*, in contradistinction to the cervical and lumbar, is broad and quadrilateral, attached internally to the dorsal spines, externally to the angles of the ribs, below to the edge of the serratus inferior, and above to that of the serratus superior, beneath which also it extends to cover the splenii muscles; the fibres are mostly transverse; though thin, and nearly transparent, it is tense and strong. The serratus posticus lies under the middle of the latissimus dorsi, to whose tendon it adheres intimately, but can be separated from it by cautious dissection; its attachment to the ribs is behind those of the external oblique and latissimus dorsi muscles. Reflect from their origin the serrati; beneath the superior, we shall see the following muscle.

Splenius is long and fat, fleshy and tendinous, lying beneath the trapezius, and extending in an oblique direction from below, upwards, forwards, and outwards; it is divided about its centre into two portions, the inferior, or splenius colli, and the superior or splenius capitis. The *splenius colli arises* from the spines of the third, fourth, fifth, and sixth dorsal, ascends obliquely outwards, and is *inserted* by distinct tendons into the transverse processes of the three or four superior cervical vertebræ behind the origins of the levator scapulæ. *Use*, to bend the neck backwards, and to one side. *Splenius capitis* is larger than the last, superior and internal to which it lies; it *arises* from the spinous processes of the two superior dorsal and three inferior cervical vertebræ, and from the ligamentum nuchæ; it ascends a little obliquely outwards, and, becoming larger, is *inserted* into the back part of the mastoid process, overlapped by the sterno-mastoid, also into the occipital bone, below its superior transverse ridge. *Use*, to bend back the head, and when one only acts to turn the head to that side; thus cooperating with the sterno-mastoid of the opposite side. The splenii are covered below by the rhomboids and serratus superior, higher up by the levator anguli scapulæ, and still higher by the sterno-mastoid muscles; strictly speaking, they are but one muscle. The splenii capitis muscles diverge superiorly, and the complexi, which converge, appear between them. Detach the splenii from the spinous processes, and divide the fascia lumborum, and the next layer of muscles will appear; this consists of the sacro-lumbalis, longissimus dorsi, and spinalis dorsi, cervicalis descendens, transversalis colli, trachelo-mastoideus, and complexus.

*Fig. 27.*

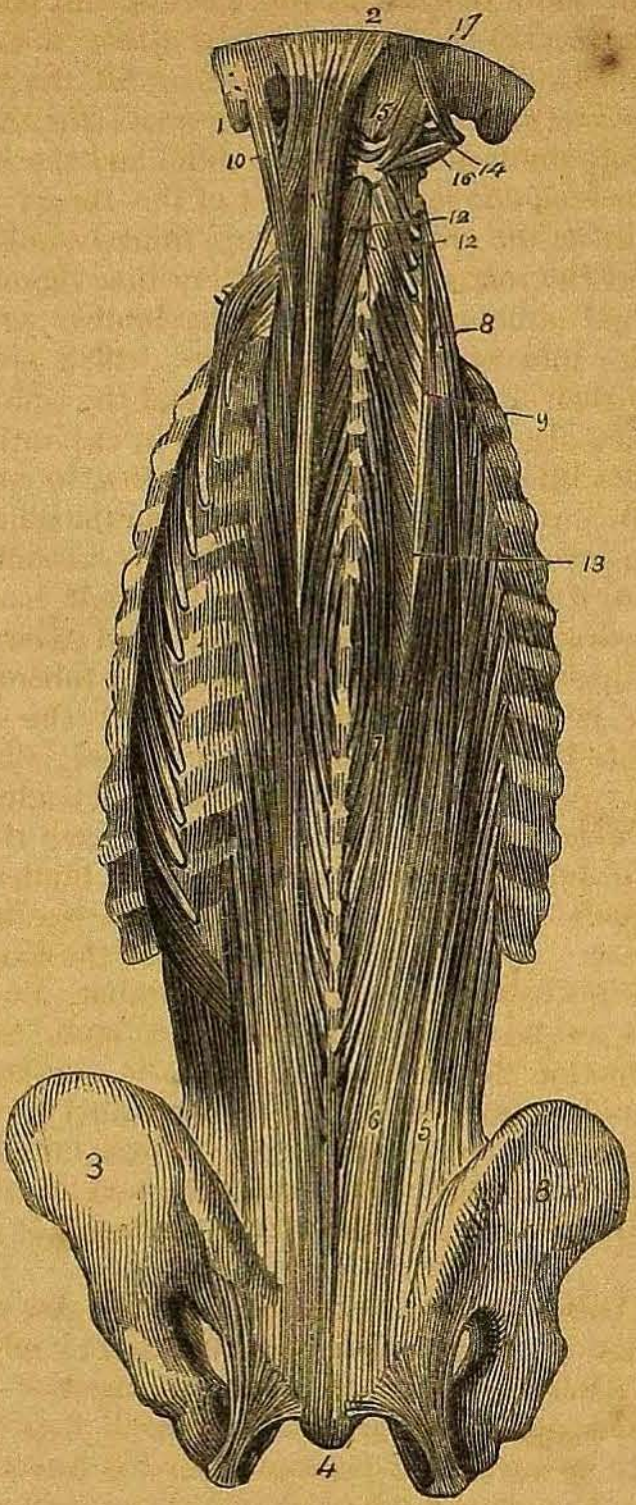


* The deep-seated muscles of the back, and posterior region of the neck. 1. 1. The mastoid process of the temporal bone. 2. A portion of the occipital bone. 3. 3. The ossa innominata. 4. The os coccygis. 5. The sacro-lumbalis muscle. 6. The longissimus dorsi. 7. The spinalis dorsi. 8. 8. The cervicalis ascendens. 9. 9. The transversalis colli. 10. The trachelo-mastoideus. 11. The complexus. 12. 12. The semi-spinalis colli. 13. The semi-spinalis dorsi. 14. The rectus capitis posticus major. 15. The rectus capitis posticus minor. 16. The obliquus capitis inferior. 17. The obliquus capitis superior.

SACRO-LUMBALIS, LONGISSIMUS DORSI, and SPINALIS DORSI, these three muscles are so closely connected inferiorly as to appear but one mass, of an oval form, narrow at the sacrum, full and prominent in the loins, and narrow in the back; several fibres must be divided in order to separate them from each other; they fill the hollow between the angles of the ribs and the spinous processes; the sacro-lumbalis is external, the longissimus dorsi in the middle, and the spinalis dorsi is internal. *Sacro-lumbalis* is the largest of the three; it *arises* from the posterior third of the crest of the ilium, from the oblique and transverse processes of the sacrum, from the sacro-iliac ligaments, and from the transverse and oblique processes of the lumbar vertebræ; it ascends and divides into several long tendons, which are *inserted* into all the ribs near their angles. *Use*, to extend the spine, and bend it a little to one side, also to depress the ribs as in expiration. The *longissimus dorsi* lies internal to the last, and *arises*, in common with it, from the posterior surface of the sacrum, and from the spinous, transverse and oblique processes of the lumbar vertebræ; ascending along the vertebral column, it is *inserted* internally by small tendons into the transverse processes of all the dorsal vertebræ, and externally by fleshy and tendinous slips into all the ribs between their tubercles and angles. *Use*, to extend, bend to one side, and support the spinal column. When we separate the sacro-lumbalis from the longissimus dorsi, and evert the former, we shall expose five or six small tendinous and fleshy fasciculi, which *arise* from the superior edge of each rib, and ascending are *inserted* into the tendons of the sacro-lumbalis; these are called the *musculi accessorii;* they are very irregular in number, structure, and size. *Spinalis dorsi* lies between the longissimus dorsi and spine; it *arises* from the two superior lumbar, and three inferior dorsal spines; it ascends close to the spinal column, and is *inserted* into the nine superior dorsal spines; its *use* is similar to the last. These three muscles are covered by, but distinct from, the lumbar fascia, and by the two preceding layers. These muscles in old subjects will be often found soft, weak, and pale, and often blended with a soft fatty substance, so as sometimes to resemble a mass of adipocere.

CERVICALIS DESCENDENS, or more properly ASCENDENS, looks like a continuation of the sacro-lumbalis, internal to which it *arises*, by four or five tendons, from as many of the superior ribs, between their tubercles and angles; these unite in a small fleshy belly, which ascends obliquely forwards and outwards, and is *inserted* by three or four tendons into the posterior tubercles of the transverse processes of the fourth, fifth, and sixth cervical vertebræ, between the splenius colli and levator scapulæ. *Use*, to extend the neck, and incline or turn it to one side; it may also assist in inspiration by elevating the ribs.

TRANSVERSALIS COLLI appears as a prolongation of the longissimus dorsi, internal to which it *arises* by small tendinous and fleshy slips from the transverse processes of five or six superior dorsal vertebræ; the fibres uniting ascend obliquely outwards and forwards, and are

*inserted* by small tendons into the transverse processes of four or five inferior cervical vertebræ, between the cervicalis descendens and the trachelo-mastoideus; its *use* is nearly similar to that of the last described muscle.

TRACHELO-MASTOIDEUS, also like a continuation of the longissimus dorsi, lies internal to the last, and external to the complexus; it *arises* by several tendinous bands from the transverse processes of three or four superior dorsal vertebræ, and from as many inferior cervical; ascending a little outward it is *inserted* into the inner and back part of the mastoid process, beneath the insertion of the splenius. *Use*, to assist in extending the neck, to bring the head backwards, and to incline and rotate it to one side. This muscle is covered by the splenius and transversalis, it lies upon the complexus, the obliqui capitis, and the digastric muscles.

COMPLEXUS, thick and strong, *arises* from the transverse and oblique processes of three or four inferior cervical, and five or six superior dorsal vertebræ, internal to the transversalis and trachelo-mastoideus; it forms a very thick muscle intersected by many tendinous bands; it ascends a little inwards, crossing the splenius, and is *inserted* close to its fellow into the occipital bone, between the two transverse ridges. *Use*, to draw back the head, to fix and support it on the spine, also to rotate it, being, in this action, an antagonist to the splenius, and an auxiliary to the sterno-mastoid of its own side. The complexus is concealed by the trapezius and splenius; its insertion, which is covered by the former only, can be felt and seen through the integuments; it lies on the semi-spinalis colli, the deep cervical artery, and the small obliqui and recti muscles; it is sometimes a digastric muscle, having a perfect tendinous intersection. Detach the complexus from the spine, and reflect it towards the occiput, and evert towards the ribs the other muscles of this layer, we shall thus expose the fourth layer of the dorsal muscles, which consist of the spinalis or semi-spinalis colli, the semi-spinalis dorsi, multifidus spinæ, interspinales, inter-transversales, and immediately below the occiput, the recti postici, major and minor, and obliqui capitis, superior and inferior.

SPINALIS, or SEMI-SPINALIS COLLI, is one of the largest muscles in this region; it *arises* from the extremity of the transverse processes of five or six superior dorsal vertebræ, ascends obliquely inwards close to the spine, and is *inserted* by four heads into the spinous processes of the second, third, fourth, and fifth cervical vertebræ. *Use*, to extend the neck and incline it a little to its own side; this thick muscle fills up the space between the spinous and transverse processes of the cervical and dorsal vertebræ; it lies external to the semi-spinalis dorsi, is overlapped by the longissimus dorsi inferiorly, the complexus superiorly, and the serratus posticus superior in the middle.

SEMI-SPINALIS DORSI is similar to the last muscle in form and attachment; indeed they appear as one long muscle, which has been thus rather unnecessarily divided into two, each named from the situa-

tion of its principal portion; *arises* by five or six tendons from the transverse processes of the dorsal vertebræ, from the fifth to the eleventh; its fibres ascend obliquely inwards, and are inserted by five or six tendons into the spinous processes of two inferior cervical, and three or four superior dorsal vertebræ. *Use*, cooperates with the last described muscle, in extending the neck, supporting the trunk, and inclining the spine backwards, and to one side; it is situated close to the spine above, and internal to the last muscle; but below, it lies on the outer side of the spinalis dorsi.

Multifidus Spinæ is close to the vertebræ, between the spinous and transverse processes, and is covered by the two last described muscles; it consists of a series of small tendinous and fleshy fasciculi; the *first arises* from the spine of the dentatus, or second vertebra, and, descending obliquely outwards, is *inserted* into the transverse process of the third; thus the succeeding muscles are attached, running obliquely from vertebra to vertebra between their spinous and transverse processes; some fasciculi extend over two or three vertebræ; the *last arises* from the spine of the last lumbar vertebra, and is *inserted* into the false transverse process of the sacrum. *Use*, to support the spinal column, extend it, and incline it to one side, also to rotate one bone upon the other, as far as their articulating surfaces will admit.

Inter-spinales are short muscles, consisting of longitudinal fibres; their name expresses their situation and attachment; between the cervical spines they are more distinct, and appear to be in pairs, right and left, as the spinous processes here are forked; some fibres in the neck deserve the name of *supra-spinous* muscles, as they pass over these processes, cover and adhere to several of them; in the back they are very indistinct, almost wanting, and in the loins they are much weaker than in the neck, chiefly consisting of ligamentous fibres, with a few muscular intermixed. *Use*, to support and extend the spine.

Inter-Transversales consist of longitudinal fibres attached and situated as their name implies; between the cervical vertebræ these muscles are more strong and distinct, and consist of two planes, an anterior and posterior; between the lumbar vertebræ they are less distinct; and still less so, indeed often wanting, between the dorsal. *Use*, to support the spine on either side, and to bend it laterally. External to these in the back, the levatores costarum muscles are seen, which have been already noticed in the description of the intercostals. Between the occiput and the first and second vertebræ, the following four pair of muscles are situated.

Rectus Capitis Posticus Major, triangular; *arises* narrow from the spinous process of the second vertebra; ascends outwards, and is *inserted* broad into the inferior transverse ridge of the occipital bone. *Use*, to extend the head, or draw it backwards, so as to turn the face upwards, also to rotate it and the atlas on the dentatus, cooperating with the splenius of the same side; this muscle is situated obliquely between the occiput and the second vertebra; it is covered

by the complexus; its insertion is overlapped by that of the superior oblique.

Rectus Capitis Posticus Minor, also triangular, *arises* narrow from the posterior part of the atlas; passes upwards, outwards, and backwards, and is *inserted* broad into the occipital bone, behind the foramen magnum. *Use*, to assist the former in drawing back the head, and steadying it on the spine; this pair is partly covered by the last muscles; a portion of them, however, is seen between these; both the recti resemble the continuation of the inter-spinous muscles, but are much more oblique, so that the name recti is by no means accurate.

Obliquus Capitis Inferior is the strongest of these small muscles; it *arises* inferior and external to the posterior rectus, and superior to the spinalis colli, from the spinous process of the second vertebra, ascends obliquely forwards and outwards, and is *inserted* into the extremity of the transverse process of the atlas. *Use*, to rotate the head and atlas on the second vertebra, cooperating with the splenius of the same side, and the sterno-mastoid of the opposite side; this muscle is covered by the complexus, trachelo-mastoideus, and trapezius, it conceals the lamina of the second vertebra, and the vertebral artery.

Obliquus Capitis Superior, smaller than the last, above the insertion of which it *arises*, narrow, from the upper part of the transverse process of the atlas, ascends obliquely inwards and backwards, overlapping the rectus, and is *inserted* broad into the occipital bone, between its transverse ridges, just behind the mastoid process, and above the rectus major. *Use*, to bend the head to one side, and to draw it a little backwards; it cannot have any rotatory power, as there is no rotation between the occipital condyles and the atlas. These four pair of muscles are but higher developments of segments of the long spinal muscles which have been traced inferiorly; the recti are analogous to the inter-spinous, the obliqui to the transverse spinous, for the mastoid process of the temporal, and the transverse ridge and tubercle of the occipital bones correspond to the projections of the spinal column. The recti and obliqui are separated from the complexi, by a strong aponeurosis, and much cellular tissue, which allows of the free motion of the atlas round the pivot of the second vertebra; these small muscles on each side bound a triangular space nearly equilateral; the recti in the middle line form the common base, the extremity of the transverse process of the atlas is the apex of each, while the superior and inferior oblique muscles form the sides; this space encloses a quantity of adeps and tough cellular tissue, deeply imbedded in which we may find the vertebral artery, a plexus of veins, some of which join the vertebral veins, others pierce the atlanto-occipital ligament, or pass through the posterior condyloid holes to open into the lateral sinus; in this region also is the posterior division of the sub-occipital nerve, dividing into its branches to supply this group of small muscles; when all these parts have been removed, we shall ex-

pose the semicircular rim of the atlas, the lamina of the dentatus, and the posterior atlanto-occipital and axoid ligaments.

The muscles of the back are found very unequally developed in different subjects; in the young, active, and robust, who have died of acute disease, they will be found red, strong, and distinct, but in those who have been enfeebled and emaciated by long illness, in the paralytic, and the bedridden, also in the very old, especially of the female sex, they often present, particularly in the lumbar and dorsal regions, a pale, weak, soft, yellowish appearance, with but little remains of the true muscular structure, and are not unlike the degenerated fatty heart occasionally found in the old and anasarcous, or the muscles adjacent to a scrofulous joint. This abnormal condition, so often met with in the aged in these particular muscles, may be partly the effect of want of exercise, and appears in conformity with the general stiffening of the spinal column, and shrivelling of the inter-vertebral ligaments, whereas, the motions of the head and neck continuing to the latest period of life, the muscles in the cervical region preserve their normal structure.

In the dissection of the muscles of the back but few vessels or nerves of size or note are met with; the arteries which supply these muscles are branches of the occipital and deep cervical superiorly; the posterior branches of the intercostals in the middle, and of the lumbar arteries below. The veins accompany the arteries and join the nearest venous trunks. The nerves are the small posterior branches of the cervical, dorsal, and lumbar spinal nerves.

# CHAPTER V.

## DISSECTION OF THE UPPER EXTREMITY.

The upper extremity is connected to the trunk by the sterno-clavicular ligaments, and by ten muscles, of which one is connected to the clavicle (subclavius), two to the humerus (pectoralis major and latissimus dorsi), and eight to the scapula, viz., trapezius, levator anguli scapulæ, omohyoid, rhomboid major and minor, serratus magnus, pectoralis minor, and latissimus dorsi; this last is also inserted into the humerus; all these muscles have been already examined; these the student may divide, then separate the extremity from the trunk, and place a block under the axilla; the dissection of the arm, however, may also be performed while it remains connected to the body. The muscles of the upper extremity are classed into those of the shoulder and arm, forearm, and hand.

## SECTION I.

### DISSECTION OF THE MUSCLES OF THE SHOULDER AND ARM.

Dissect off the integument from the shoulder and arm, as low as the bend of the elbow. The subcutaneous tissue is cellular and adipose, but very variable as to quantity and consistence, and does not deserve the name of superficial fascia; beneath this, in the dissection of the scapula and brachial regions, we meet with different aponeuroses, which are more or less continuous with each other, but differ in structure in different situations.

1. The Supra-spinous Fascia; this is strong and tense, adheres to the borders of the fossa, and covers the muscle of that name, and is gradually lost on its tendon beneath the acromion process.

2. The Infra-spinous Fascia is also very strong, is attached to the borders of the corresponding fossa, binds down the muscle within, and sends in septa between it and the teres minor and major muscles; at the posterior edge of the deltoid it divides into two laminæ, one, thin and delicate, passes over this muscle and joins the brachial aponeurosis, the other continues on the infra-spinatus and teres minor tendons, passes loosely over the joint, and is lost on the biceps and coraco-brachialis muscles.

The Subscapular Fascia, weak and thin, but distinct, covers the muscle of that name, and divides it into fasciculi by septa which pass in deep to adhere to projecting ridges on the bone.

The Brachial Aponeurosis invests the arm down to the elbow, over which it is partially continued into the fascia of the forearm; it is weak and imperfect in some places, as on the deltoid muscle, in others it is strong and well-marked; its strength and tension increase as it descends; its fibres are mostly in the circular direction, but many are spiral and vertical: above it is continuous with the fascia covering the pectoral and deltoid muscles, below the former it receives an addition from the fascia of the axilla, and from the posterior border of the latter, and from the infra-spinous fascia a considerable increase; still lower down, fibres join it from the insertions of the deltoid, pectoral, and latissimus dorsi; these last-named muscles are enabled thereby to act slightly on it, and increase its tension, as it has no distinct tensor muscle like the fascia of the thigh; about the middle of the arm the brachial aponeurosis adheres to the lateral ridges of the humerus by two septa named *internal* and *external intermuscular ligaments*, the fibres of these are oblique and vertical. The external commences at the lower part of the outer lip of the bicipital groove, receives a strong slip from the deltoid insertion, and descends to the outer condyle, is stronger and thicker above than below, it separates the triceps from the brachiæus anticus muscle, and both receive fibres from it; the musculo-spiral nerve and artery perforate it about its lower third, and then descend anterior to it. The internal is more distinct than the external, of a triangular form, the apex above thin, the base towards the inner condyle thick and strong; it commences from the inner lip of the bicipital groove, below the teres major tendon, soon becomes continuous with that of the coraco-brachial, crossing its fibres obliquely, adheres to the internal ridge of the humerus, and is inserted broad into the inner condyle; this ligament also separates the brachiæus and triceps muscles, and affords attachment to fibres of each; the ulnar nerve is anterior to it above, but perforates it, and lies behind it below; in addition to these two great septa between the flexors and extensors, this fascia also sends in thin processes to enclose the individual muscles, and to encircle the brachial vessels and nerves in an imperfect sheath; inferiorly it is prolonged into the fascia of the forearm, which we shall examine afterwards. The brachial fascia serves to confine the several muscles in their situations with such a degree of tension as not to restrain their actions; it also augments the surface of their attachment, and compresses them together so as to preserve the form and symmetry of the limb; it also protects the vessels and nerves.

Between the integuments and fascia of the arm we notice two cutaneous veins, the cephalic on the outer, and the basilic on the inner side; the *cephalic* will be found hereafter to commence about the thumb, and to ascend along the radial side of the forearm, and having passed the elbow joint, it is now seen continuing its course up the arm,

at first on the outer side of the biceps, and afterwards between the deltoid and great pectoral muscles to the clavicle, beneath which it sinks to join the axillary vein; the cephalic vein is unaccompanied by nerves in its course up the arm, but in the dissection of the forearm the external cutaneous nerve will be seen closely connected with it. The *basilic vein* will be found to commence about the little finger, to ascend along the ulnar side of the forearm, and to pass over the elbow joint; it is now seen continuing its course on the inner side of the biceps, between the skin and fascia, and about the middle of the arm it perforates the latter, to join one of the deep brachial veins; in some it continues superficial as high as the axilla, where it joins the axillary vein; the basilic vein in the arm is accompanied by the cutaneous nerves of Wrisberg, which having escaped from the intercostal branches of the second and third dorsal nerves, and passed across the axilla, are then distributed to the integuments on the inner side of the arm; inferiorly the internal cutaneous branch of the brachial plexus accompanies this vein, and continues with it along the forearm: dissect off the fascia and cellular membrane from the muscles of the shoulder and arm. The muscles of the shoulder are six in number, viz. the deltoid, supra and infra-spinatus, teres minor and major, and sub-scapularis; those of the arm are four in number, viz., the biceps, coraco-brachialis, brachialis anticus, and triceps; first examine the muscles of the shoulder.

DELTOIDES, very thick, strong, triangular, and bent so as to embrace the shoulder joint in front, externally and behind, *arises* tendinous from the lower edge of the spine of the scapula, and by fleshy fibres and tendinous plates, from the anterior edge of the acromion, and of the external third of the clavicle; the fibres converge and descend obliquely, the posterior forwards, the anterior backwards, and the middle at first outwards, and then vertically downwards; *inserted* tendinous into a rough surface, about two inches in extent, situated on the outer side of the humerus, and commencing just above its centre; this insertion will be found to be by three distinct tendons, the anterior and posterior of which are greater than the middle one; the pectoralis major is usually connected to the anterior. *Use*, to abduct and raise the arm; the anterior fibres can also draw it forwards, the posterior backwards, and when the arm is by the side, these portions can rotate it inwards or outwards. This muscle can also move the scapula on the arm when the latter is fixed, as in the case of a fall upon the hand or elbow, or in lifting a very heavy weight; under these circumstances this muscle sometimes cooperates with the great pectoral and latissimus dorsi, to dislocate the head of the humerus into the axilla. The deltoid is covered by the skin, a thin fascia, and a few fibres of the platisma; its origin corresponds to the insertion of the trapezius, with which it is often connected by aponeurotic fibres, so as to resemble a digastric muscle; its insertion is surrounded by the origin of the brachiæus anticus, and lies between the biceps and second head of the triceps; its posterior margin is thin, and is con-

nected to the strong aponeurosis which covers the infra-spinatus muscle; its anterior edge is separated from the great pectoral, by the cephalic vein, some cellular membrane, and a small artery. This muscle is fleshy on its external surface, coarse and rough, and composed of several distinct triangular fasciculi, separated by fibro-cellular septa. Divide it transversely, and reflect each portion, and we shall then see that its structure is very complex, and that its internal surface is much more tendinous; an aponeurosis exists beneath it, which is attached above to the infra-spinatus fascia, and to the triangular ligament, and lost below on the biceps and coraco-brachialis muscle; a large *bursa* is also seen which extends under the acromion, and is expanded on the tendon of the spinati muscles, and on the capsular ligament; it allows the deltoid muscle and the exterior of the shoulder joint to glide easily against each other. The deltoid also covers the coracoid process, the muscles which are attached to it, all the small muscles connected to the capsular ligament, the insertion of the great pectoral, and the circumflex vessels and nerves.

*Fig.* 28.*

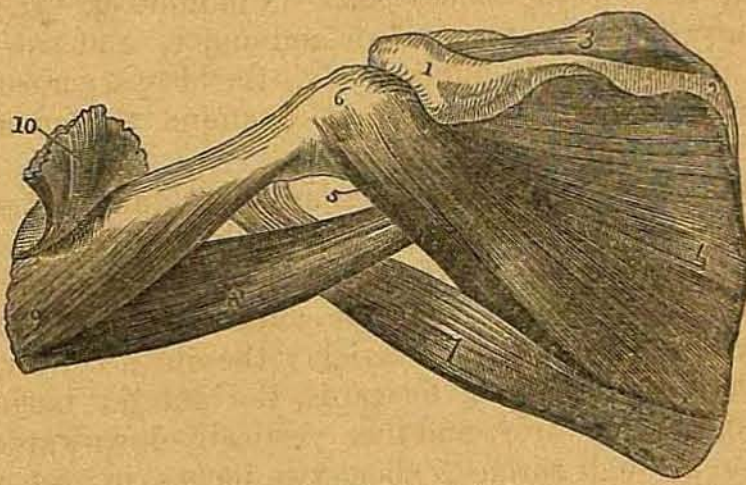


Supra-spinatus fills the fossa of that name, and *arises* from all that portion of the scapula above its spine, which is engaged in forming this fossa, also from a strong fascia which covers the muscle; the fibres pass forwards beneath the acromion process and triangular ligament, end in a tendon which glides over the neck of the scapula (a bursa intervenes); *inserted* into the upper and forepart of the great tuberosity of the humerus, into the most anterior and superior of the three depressions which are marked on that surface. *Use*, to assist the deltoid in raising and abducting the arm, it also strengthens the capsular ligament, and draws it out of the angle which is formed by the eleva-

* The muscles of the shoulder, the superior portion of the deltoid has been removed. 1. The acromion process of the scapula. 2. The spine of the scapula. 3. The supra-spinatus muscle. 4. The infra-spinatus muscle. 5. The teres minor muscle. 6. The great tuberosity on the head of the humerus, into which the last three muscles are inserted. 7. The teres major muscle. 8. The long head of the triceps muscle. 9. The external head of the triceps. 10. The inferior portion of the deltoid muscle cut across.

tion of the arm, between the humerus and the glenoid cavity; it also presses the head of the humerus and glenoid cavity towards each other, prevents the head of the former from descending out of the latter, and thus it becomes the antagonist to the pectoral, deltoid, and those other long muscles, which have a tendency to dislocate the head of the bone into the axilla, it also, on the other hand, prevents the head of the humerus being pushed upwards out of the glenoid cavity towards the acromion process, thus it affords greater security to the articulation than almost any other muscle in this region. This muscle is covered by the trapezius, much cellular membrane and fat, and by a strong aponeurosis; its insertion is concealed by the deltoid, and the large bursa beneath that muscle, also by the acromion process and triangular ligament; it covers the supra-scapular nerve and vessels, and its tendon is inseparably connected to the capsular ligament.

INFRA-SPINATUS is inferior to the last, flat and triangular; *arises* fleshy from the inferior surface of the spine of the scapula, and from the dorsum of this bone, below this process, as low down as the posterior ridge on the inferior costa, but not from the rough surface on the inferior angle of the scapula; it also arises from the aponeurosis which covers it; the inferior fibres ascend obliquely forwards, the superior run horizontally; all converge, and are *inserted* by a strong tendon, which covers and adheres to the outer part of the capsular ligament, into the middle of the external or greater tuberosity of the humerus, below the supra-spinatus. *Use*, to assist the superior part of the deltoid in raising the arm, and drawing it backwards, also in rotating it outwards; when the arm has been raised, its lower fibres can depress it; it will also draw the capsular ligament out of the joint, and strengthen the articulation; it is covered by the trapezius and deltoid; but between these and the latissimus dorsi, a portion of it is superficial. It lies on the bone, and the scapular vessels and nerves; a large bursa lies between its tendon and the neck of the scapula.

TERES MINOR, small and narrow, inseparably attached to the last muscle, along the lower edge of which it runs; it *arises* from a depression between the two ridges on the inferior costa of the scapula, extending from the neck of the bone to within an inch and a half of its inferior angle, from the fascia which covers it, and from ligamentous septa which enclose it; the fibres ascend obliquely forwards and outwards, cover and adhere to the capsule, and are *inserted* below the infra-spinatus into the inferior depression on the great tuberosity of the humerus, and into the bone a little lower down. *Use*, to cooperate with the last muscle. The origin of the teres minor is between and overlapped by the infra-spinatus and teres major muscles; its middle portion is superficial, and its insertion is covered by the deltoid; it lies on the scapula, sub-scapular vessels, capsular ligament, and long head of the triceps, which last separates it from the teres major; some fibres not unfrequently arise from the long tendon of the triceps itself.

Sub-scapularis is situated on the inner side of the scapula, opposite to the three last described muscles, broad and triangular, the base behind, the apex before; it *arises* from all the surface and circumference of the sub-scapular fossa, also by a few fibres from the long tendon of the triceps; the fibres run in thick fasciculi upwards and forwards, and all converge towards the neck of the scapula, over which they glide, in a sort of pulley, beneath the coracoid process, and the muscles which are inserted into it; they end in a tendon which is intimately united to the capsular ligament, and *inserted* into the internal or small tubercle of the humerus; this muscle is covered by the sca-

*Fig.* 29.*

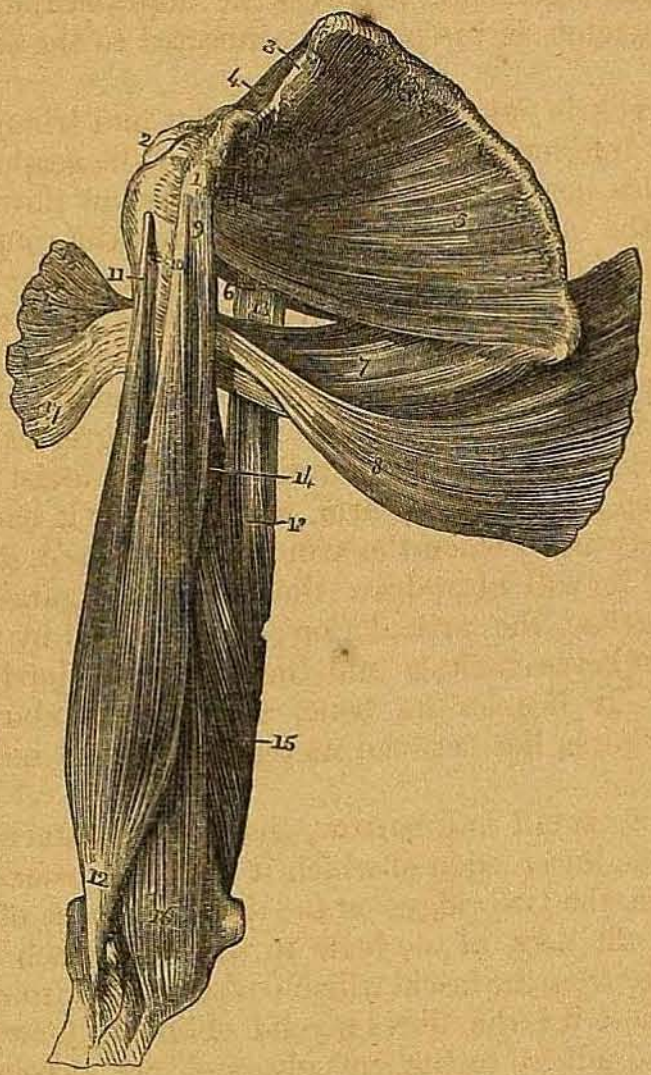

* The subscapular muscle and muscles of the arm. 1. The coracoid process of the scapula. 2. The acromion process. 3. The superior costa of the scapula. 4. The supra-spinatus muscle. 5. The subscapular muscle. 6. The inferior border of the teres minor muscle. 7. The teres major muscle. 8. Portion of the latissimus dorsi muscle. 9. The coraco-brachialis muscle. 10. The short head of the triceps muscle. 11. The long head of the triceps. 12. The tendon of the biceps inserted into the tubercle of the radius. 13. The long portion of the triceps muscle. 14. Portion of the outer head of the triceps. 15. Internal or short portion of the triceps. 16. The brachialis anticus muscle. 17. Portion of the pectoralis major muscle.

pula and the muscles of the shoulder; its inferior edge is in contact with the teres major; its internal surface, which forms part of the axilla, is connected to the serratus magnus, and to the axillary vessels and nerves, by loose cellular membrane; a large bursa, very often communicating with the joint, lies between its tendon and the neck of the scapula, beneath the coracoid process; another smaller bursa is sometimes situated lower down, between the tendon and the capsular ligament; the inter-muscular septa often separate this muscle into three portions which thus correspond to the three muscles on the other aspects of the joint. *Use*, this, which is the strongest of these *capsular* muscles, strengthens the inner side of the articulation, and guards against dislocation when the elbow is suddenly drawn backwards and outwards. This muscle can depress and adduct the arm, draw it backwards, and rotate it inwards, so as to turn the palm of the hand backwards, thus it antagonizes the infra-spinatus and teres minor muscles.

The deltoid and the four *capsular* muscles, which have been just described, are of great use to the shoulder articulation; the head of the humerus is so large, the glenoid cavity so superficial, and the capsular ligament so loose and long, that, but for these muscles, the bones could not remain in apposition; hence, in cases of paralysis of the muscles of this region, the joint becomes elongated and flattened, and a partial dislocation exists; in the dissected limb also, if we divide all the muscles surrounding the capsule, and leave the latter uninjured, the bones will no longer be in contact; these muscles, therefore, serve to strengthen the capsule, to keep the head of the humerus pressed against the glenoid cavity, and thus to counteract that tendency to dislocate the head of the bone, which the larger muscles of the limb frequently have, in consequence of their insertion being at such a distance from the centre of the joint, added to the anatomical imperfections in the latter already alluded to; which imperfections, however, are much counterbalanced by the great mobility which the joint enjoys in consequence of this formation, by the numerous opposing muscles which serve to protect the articulation, and by the rotatory motion of which the scapula is allowed to partake.

TERES MAJOR, long and flat, *arises* from a rough, flat surface on the inferior angle of the scapula, below the infra-spinatus, and from the fascia which separates it from the adjacent parts; it forms a thick fleshy belly, which ascends forwards and outwards to the inner side of the arm, and ends in a broad, thin tendon, which is at first closely connected to the back of the tendon of the latissimus dorsi; but near the humerus a small bursa intervenes, and is *inserted* into the inner or posterior edge of the bicipital groove, behind the tendon of the latissimus, and in general, but not always, extending lower down than it. *Use*, to rotate the humerus inwards, to adduct and draw it downwards and backwards; also to draw forward the inferior angle of the scapula; whereby it not only assists the capsular muscles in retaining these two bones in apposition, but it also keeps the glenoid cavity op-

posed to the head of the humerus. The origin of this muscle is superficial, but the latissimus dorsi generally overlaps it, and then, turning round its lower edge, becomes anterior to it; it is here connected to the infra-spinatus and teres minor; from the latter the long head of the triceps afterwards separates it; it passes anterior to this muscle, and assists the latissimus dorsi in forming the posterior fold of the axilla.

The four muscles of the arm are the coraco-brachialis, biceps, and brachiæus anticus in front, and the triceps behind; the latter is the extensor of the elbow joint, and is analogous to the rectus and vasti on the forepart of the femur; the biceps and brachiæus, aided by the muscles of the forearm, which arise from the inner condyle, are flexors of this joint; the flexors predominate over the extensors, the contrary is the case in the knee joint; this arrangement is conformable to the destined function of each limb; the upper extremity being for prehension and attraction towards the head and trunk, the flexors prevail, whereas the lower being for support in standing and in progression, the extensors require and accordingly possess greater power.

Coraco-Brachialis *arises* tendinous and fleshy from the point of the coracoid process, and from the tendon of the short head of the biceps; it descends obliquely forwards, and is *inserted*, chiefly tendinous, into the internal side of the humerus, a little below the middle, and into the ridge leading to the internal condyle, by an aponeurosis, which is connected to the internal inter-muscular ligament, and is thereby joined to the fascia of the arm. *Use*, to adduct, raise, and draw forwards the arm; also to rotate it outwards. The origin of this muscle cannot be separated from the short head of the biceps, but as it descends, it lies behind, and to the inner side of that muscle; it is covered above by the deltoid and pectoral; a small portion of it below is superficial, and is seen between the biceps and triceps; its insertion is just below that of the teres major, and separates the brachiæus anticus and posticus; the coraco-brachialis passes over the tendon of the subscapular, latissimus, and teres muscles; the brachial artery and median nerve at first lie to its inner side, but pass superficial to its insertion; the belly of this muscle is generally, but not always, perforated by the external, or musculo-cutaneous, or perforans Casserii nerve; one of the roots of the median nerve also sometimes passes through it.

Biceps is situated along the forepart of the humerus, and consists of two portions superiorly, the external or long, the internal or short; the *internal arises* tendinous from the coracoid process, between the coraco-brachialis and triangular ligament; it soon becomes fleshy, descends obliquely outwards, and a little above the middle of the humerus is united to the *external*, or *long* head, which *arises* by a long tendon, from the upper part of the glenoid ligament of the scapula; this tendon passes outwards through the joint over the head of the humerus, within the capsular ligament, but external to the synovial membrane; it then descends into the groove, between the two tuberosities of this bone, in which groove it is bound down by tendinous fibres, continued from the capsular ligament, and from the adjacent

tendons; the synovial membrane of the joint is reflected *on* this tendon at is origin, and is again reflected *from* it inferiorly on the parietes of the groove, between the tendons of the great pectoral, latissimus dorsi, and teres major muscles; thus, although the tendon passes through the cavity of the joint, it is, strictly speaking, external to the synovial membrane. About the middle of the humerus these two portions of the biceps unite in a large fleshy belly, which, descending to within about an inch and a half of the elbow joint, ends in a flat tendon; this sends off a process from its anterior and outer border, called the semilunar fascia, which passes obliquely inwards to join the general aponeurosis of the forearm, the tendon then sinks below the joint into a triangular hollow between the supinator longus and pronator teres, and is *inserted* into the back part of the tubercle of the radius; a bursa intervenes between this tendon and the anterior part of the tubercle, which is covered by cartilage; the *semilunar fascia*, which *arises* narrow from the forepart of this tendon, opposite the bend of the elbow, passes upwards and inwards, expanding towards the internal condyle, to which, and to the muscles proceeding from it, some of its fibres are attached; the remaining become continuous with the aponeurosis of the forearm. *Use*, to flex the forearm, and make tense its fascia; also to abduct and raise the arm. When the hand is prone, the first effect of the contraction of the biceps is to roll the radius outwards, and turn the hand supine, which it does with great power, as the tendon glides round the tubercle; the long tendon of the biceps, by passing over the head of the humerus, prevents this bone being dislocated upwards and outwards, as otherwise might occur, in consequence of a fall, or of a sudden muscular contraction; the biceps may also assist the coraco-brachialis, in rotating the scapula on the humerus, so as to depress the point of the shoulder. The long head of the biceps is concealed by the deltoid, supra-spinatus, and capsular ligament; the short head by the great pectoral and deltoid; not unfrequently this muscle has another origin from the humerus below its head; in some a fasciculus unites it to the coraco-brachialis, and in others to the brachiæus anticus muscle, which lies behind it. The belly is superficial, and lies on the brachialis anticus, so also is the tendon in its passage over the elbow joint, but as it approaches its insertion it lies very deep, and is embraced by the supinator brevis muscle, a bursa often separates it from the tendon of the brachiæus anticus; the brachial artery descends along its internal border, and somewhat overlapped by it, in the middle and lower part of the arm. This muscle or its tendon will serve as a guide in the living subject, in case we are required to tie this vessel, but superiorly the coraco-brachialis intervenes; the semilunar fascia is extended over the brachial artery and nerve, and affords them some, but not a constant protection, in performing venæsection in the median basilic vein, which vein is superficial to this fascia, but parallel, and often so close to the artery as to expose the latter to some danger in that operation. In dislocation,

and in other injuries of the shoulder joint, the long tendon of the biceps is sometimes ruptured.

BRACHIALIS ANTICUS, or EXTERNUS, improperly called by some INTERNUS, *arises* from the centre of the humerus by two fleshy slips, one on either side of the insertion of the deltoid, from the forepart of the bone down to the condyles, and on each side as far as the intermuscular ligaments; the fibres descend converging, pass anterior to the elbow joint, adhere to the synovial membrane, and are *inserted* by a strong tendon into the coronoid process of the ulna, and into a rough surface on this bone beneath that process. *Use*, to flex the forearm, and in doing so it draws the synovial membrane out of the angle of the joint; it also strengthens this articulation in its extended state, by pressing the ulna against the humerus, and supporting the joint in front; this muscle is covered by the biceps and by the brachial vessels and nerves; external to the biceps it is superficial; its external head is the longer, and lies between the deltoid and second head of the triceps; lower down the external cutaneous nerve and cephalic vein are to its outer border; and on a deeper plane, the musculo-spiral nerve and artery separate it from the supinator longus, and from the extensors of the carpus; the internal separates the deltoid from the coraco-brachialis; the tendon passes deep into the hollow at the elbow, behind the tendon of the biceps, and is inserted on its internal side; a fleshy fasciculus often unites this muscle and the biceps about the middle of the arm.

*Fig. 30.**

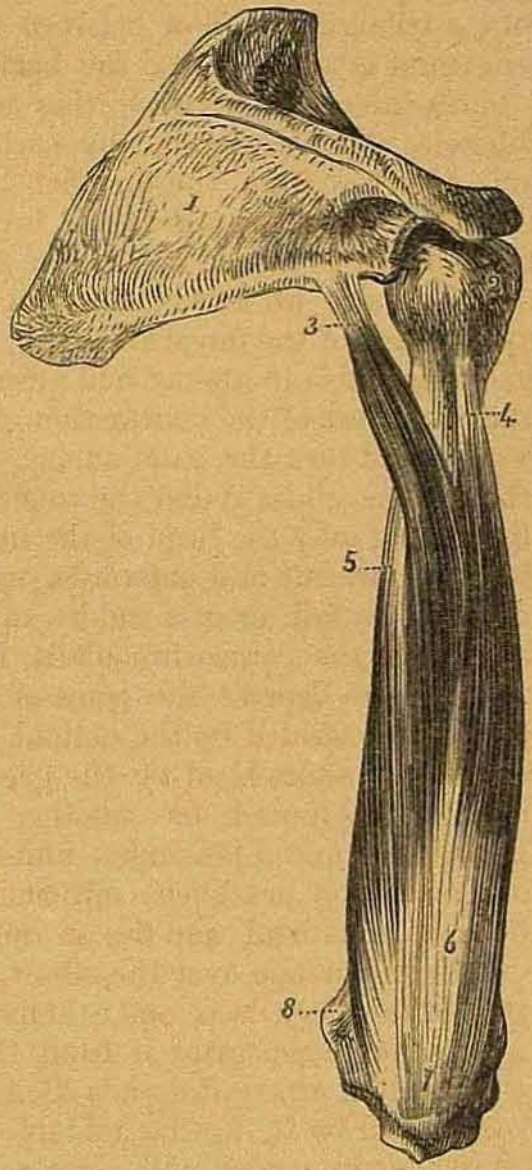


TRICEPS EXTENSOR CUBITI covers the back of the humerus, and extends from the scapula to the olecranon; it consists superiorly of three portions, viz., the middle or long, the second or external, and

* A posterior view of the upper arm. 1. The posterior surface of the scapula. 2. The capsular ligament of the shoulder joint. 3. The long or middle head of the triceps muscle. 4. Its external head. 5. Its short or internal head. 6. Common tendon of the triceps muscle inserted into 7. The olecranon process of the ulna. 8. The internal condyle of the humerus.

the third or internal, or short head, or the brachiæus internus or posticus.

The *long*, or *middle head*, *arises* by a flat short tendon, about an inch broad, from the lower part of the neck of the scapula, and from the anterior portion of the inferior costa; it also adheres to the inferior part of the capsule and to the glenoid ligament, somewhat like the biceps above, to which it is nearly opposite; it soon ends in a large fleshy belly which descends along the back part of the humerus; that surface which is towards the bone continues tendinous for some distance; about the superior third of the arm it joins the *second*, or *external head*, which *arises* immediately below the insertion of the teres minor by a narrow, tendinous, and fleshy slip, from a ridge on the outer side of the humerus commencing below the great tuberosity, and leading down to the external condyle, it also arises from the bone behind this ridge, from the intermuscular ligament, and from the external condyle, by a tendon which passes upwards and inwards, and joins the remainder of the muscle; these inferior fibres are parallel to the anconæus; the *third*, or *short head*, or *brachiæus internus*, or *posticus*, improperly called brachiæus externus, *arises* narrow on the inside of the humerus, above its centre, commencing tendinous just below the insertion of the teres major, and continuing to arise from the ridge which leads to the internal condyle, and from the internal intermuscular ligament; these three portions of the triceps unite above the middle of the arm, and, descending along its posterior part, end in a flat broad tendon, which consists of two laminæ, a superficial and a deep; the former is continued over the flat triangular surface of the olecranon into the fascia on the back part of the forearm; the latter, which is stronger but narrower, is *inserted* into the posterior border, but not the point, of the olecranon process. *Use*, to extend the forearm on the arm, and by its long portion to carry the arm backwards, and in some cases to adduct it; it also draws up the synovial membrane from between the olecranon process and the humerus, and thus protects it from pressure in the extended state of the limb. The long head gives support to the inferior part of the capsular ligament of the shoulder, and so tends to protect that joint against dislocation, in that situation where it would be most likely to occur. The sudden contraction of the triceps during life sometimes breaks off the olecranon process, and draws upwards the separated portion; of course, the individual loses for some time the power of extending the forearm; the fractured piece, however, is prevented being separated to any considerable distance partly by a ligamentous band which extends from the coronoid process along its side, and partly by the aponeurosis of the triceps which covers the olecranon, and which joins the fascia of the forearm, also by the inferior fibres of this muscle, which, being connected to the condyles, and having to ascend a little to the olecranon, tend to keep down its fractured portion. The first, or long head of the triceps, arises and descends between the two teres muscles; the second, or outer head, commences

below the the teres minor; and the third, or the brachiæus internus or posticus, below the teres major; the long and the second head are covered above by the deltoid, the remainder of them is superficial; the second lies external to the supinator longus and radial extensors of the carpus; the third, or internal head, is also superficial, and lies between the brachialis anticus and coraco-brachialis anteriorly, and the long portion of the triceps posteriorly; the ulnar nerve descends along this, and the radial or spiral separates it from the second or outer head; a small bursa lies between the tendon and the point of the olecranon, a larger one between the skin and the aponeurosis which covers that process; this superficial bursa is peculiarly liable to inflammation, (which is generally of an unhealthy character), in consequence of an injury, such as a fall upon the elbow, producing a superficial lacerated wound. In the dissection of the muscles of the arm, we should notice the course of the brachial artery and of its principal branches, also the divisions of the axillary plexus of nerves; the cutaneous veins have been already noticed; the deep veins accompany the arteries two to each.

The *brachial artery*, which is the continuation of the subclavian and axillary, descends obliquely outwards along the inner side, first of the coraco-brachialis, and afterwards of the biceps; near the elbow it inclines forwards, and then sinks beneath the fascia of the biceps, and a little below the bend of the elbow it divides into the radial and ulnar arteries. In this course it is covered by the fascia and integuments, and overlapped a little by the biceps; it is surrounded by a sheath of cellular membrane, which also contains the two venæ comites. The internal cutaneous nerve lies superficial to it; the median, or brachial, is also superficial to it above, and rather to its outer side; about the middle of the arm it crosses the artery, and inferiorly it is almost always to its ulnar or inner side. The ulnar nerve lies internal to the artery, and at some distance from it inferiorly; the radial or spiral nerve is posterior to it, and separates it above from the triceps. In this course the artery passes over the tendons of the latissimus and teres, a small part of the triceps, the coraco-brachialis, and the brachiæus anticus. The brachial artery gives off several mnscular branches from its external side; and from its internal the superior profunda, which accompanies the spiral nerve round the back of the humerus to its external side; the inferior profunda which descends along with the ulnar nerve towards the inner condyle, aud the anastomotica magna, which runs towards the inner side of the elbow joint.—See *Anatomy of the Vascular System.*

The branches of the brachial plexus of nerves, which are met with in the dissection of the arm, are six in number: first, the *internal cutaneous*, which has been already noticed; second, the *external cutaneous*, or musculo-cutaneous, or perforans Casserii, pierces the coraco-brachialis muscle, descends obliquely outwards between the biceps and brachialis anticus, to which it sends several filaments, and at the anterior edge of the supinator longus it becomes cutaneous, descending

along with the cephalic vein and its branches; third, the *median*, or brachial nerve, accompanies the brachial artery to the bend of the elbow, and sinks beneath the muscles of the forearm, in the dissection of which the remainder of its course will be exposed: fourth, the *ulnar* nerve descends along the inner portion of the triceps, or the brachiæus internus, runs behind the inner condyle, and is then distributed to the muscles of the forearm and hand; fifth, the *musculo-spiral*, or radial nerve, descends between the second and third heads of the triceps, and winds round the back part of the humerus, supplying the triceps in its course; it next runs spirally forwards to the forepart of the bone, between the supinator longus and brachialis anticus; it then descends over the forepart of the elbow joint to the muscles of the forearm, where we shall trace it afterwards; sixth, the *circumflex*, or articular nerve, accompanied by the posterior circumflex artery, passes out of the axilla, between the long head of the triceps and the neck of the humerus, winds round the latter beneath the deltoid muscle, to which its branches are distributed.

The internal cutaneous is a simple nerve of sensation, all the others are compound, that is, they consist of motor and of sensitive filaments. The brachial, ulnar, and musculo-cutaneous may be regarded as one large compound trunk, supplying sensitive branches to the anterior aspect of the forearm, and to the hand generally, and to the fingers especially, and motor filaments to the flexor and pronator muscles; the musculo-spiral, with the circumflex, may also be considered as another great compound trunk, supplying chiefly the posterior and external aspect of the arm and forearm with sensitive, and all the extensor and supinator muscles with motor filaments, for the deltoid muscle may be regarded as an extensor of the limb. The first, then, might be named the great flexor, the second, the great extensor nerve of the upper extremity.—See *Anatomy of Nervous System.*

## SECTION II.

### DISSECTION OF THE FOREARM AND HAND.

REMOVE the integuments from the front and back of the forearm and hand, and the investing fascia will be exposed, together with the sub-cutaneous nerves and veins. The bursa between the skin and olecranon has been already noticed; small and imperfect bursæ will be found over each knuckle, also occasionally over the lower end of the ulna: the subcutaneous, cellular, and adipose tissue scarcely deserve the name of superficial fascia, they are variable in density and amount; there is more of the adipose on the front, the aspect of flexion, and more of the reticular posteriorly, or the aspect of extension. On the palm of the hand the integuments are thick and hard, and marked by

many long indented lines, like the marks of folds, crossing each other obliquely; on the forepart of the fingers are many fine striæ, placed transversely, or circularly, also longitudinally on the first and middle phalanges, and in regular, spiral, and numerous arched curves on the surface of the last; beneath these the cellular tissue contains a net-work of bloodvessels and nerves, the seat of the sense of touch: in the palm, the adipose substance is granulated and compact, and both it and the skin are connected by aponeurotic fibres to the subjacent strong palmar fascia; posteriorly the skin is fine, and the cellular tissue is loose and reticular, and contains a number of large superficial veins, which are arranged in a tortuous arch across the metacarpal bones, the convexity towards the fingers receiving the digital veins; the superficial veins in the palm are very small, and most of them pass into the deep veins; from the extremities of the posterior cutaneous arch two principal branches proceed, the cephalic and basilic; the *basilic* commences by a small branch called salvatella from the side of the little finger, it then ascends along the ulnar side of the forearm, receiving in this course small branches from the front and back of the arm, and passing anterior to the internal condyle, it is joined by the median basilic; it then ascends along the inner side of the arm, passes beneath the fascia, and joins one of the deep brachial veins; sometimes it continues in a superficial course to the axilla, and joins the axillary vein. The *cephalic vein* commences by several small branches about the thumb and back of the hand; it ascends along the radial side of the forearm, passes over the bend of the elbow, is joined by the median cephalic, and then ascends along the outside of the arm to the clavicle. The *median vein* arises by small branches from the forepart of the wrist, it ascends along the forearm between the cephalic and basilic veins, and near the elbow divides into two or three branches: first, the *median basilic*, which ascends obliquely over the fascia of the biceps to join the basilic; second, the *median cephalic*, which passes obliquely upwards and outwards, and joins the cephalic vein; the third branch of the median, when present, sinks deep, and joins one of the deep veins: the cutaneous veins of the forearm are so variable as to size, number, and situation, that they seldom conform precisely to the description given by any author.—See *Venous System*.

Several subcutaneous nerves are met with in this dissection. The internal cutaneous nerve and its branches accompany the basilic vein, some passing anterior, others posterior to it, and are distributed to the anterior, internal, and posterior aspects of the limb. The external cutaneous, or musculo-cutaneous, in general lies behind the cephalic vein at the bend of the elbow, its branches afterwards twine around that vessel, and are lost on the anterior, external, and posterior parts of the forearm; the musculo-spiral nerve also gives off a cutaneous branch above the elbow, which descends on the outer and back part of the limb to the wrist; over the back of the thumb and hand ramify the dorsal branches of the radial and ulnar nerves, while the

median and ulnar supply the forepart. The relation between the cutaneous nerves and veins is liable to great variety.

*The fascia of the forearm*, though semi-transparent, is very strong, particularly on the posterior part; it consists of tendinous fibres, which run in every direction, but principally in the circular and oblique, connected on either side to the condyles, and to the muscles which are attached to these; it receives an addition from the biceps before, and from the triceps behind; as it descends, it invests the limb so closely as to give it a certain form; it sends septa between the different muscles, which separate them into superficial and deep layers, and which also give attachment to several fibres; it adheres very closely to the olecranon and to the ulna its whole length; and inferiorly it is connected to the annular ligaments of the carpus. It is perforated by numerous holes for vessels and nerves; there is also a deficiency in it just above the fascia of the biceps, whereby the subcutaneous cellular tissue communicates with the intermuscular; the fibres of this semilunar process from the biceps tendon descend obliquely towards the inner condyle, intersecting and uniting with the fibres of the aponeurosis which arises in this region; by means of this process the biceps muscle can act as tensor of the fascia of the forearm; it also bounds in front, and confines together the sides of the *anticubital fossa*, which is a sort of narrow, deep, triangular axilla, bounded internally by the pronator teres, externally by the supinator longus; the apex is below and external, the base is above and behind, formed by the brachiæus anticus covering the joint; into this hollow sink the median nerve, the brachial artery, with its venæ comites, and the tendon of the biceps a little twisted, first giving off this fascia from its outer and anterior border. The *annular ligaments* of the wrist appear formed in part by this fascia, strengthened by proper transverse fibres; the *posterior* consists of transverse and oblique fibres attached internally to the lower end of the ulna, and to the back of the pisiform bone; externally to the lower end of the radius; it is divided into several channels, or canals, by fibrous septa, which pass forwards between the tendons and are inserted into the radius; there are six of these channels, and, tracing them from within outwards are, first, for the extensor carpi ulnaris; second, the extensor minimi digiti; third, the extensor communis; fourth, the extensor pollicis major; fifth, the radial extensors of the carpus; and sixth, for the abductor, and extensor pollicis minor; all these sheaths are lined by distinct synovial bursæ which accompany the tendons some way beyond the borders of the ligament, and which materially facilitate their motions. The *anterior* is much stronger and independent of the fascia, though connected to it; attached externally in a curved manner to the scaphoid and trapezium; the sheath of the flexor carpi radialis tendon runs through this insertion; internally, to the unciform and pisiform bones, also to the tendon of the flexor carpi ulnaris; the ulnar nerve separates these osseous attachments; the fibres are trans-

verse and decussating, very strong, and almost as firm as cartilage; the fascia of the forearm is attached to it above, that of the palm below, the palmaris tendon in front, the origin of the short muscles of the thumb externally, and the palmaris brevis and muscles of the little finger internally; it forms with the forepart of the carpus a complete ring, through which pass the median nerve and nine tendons, viz.: the four deep and four superficial common flexors, also the long flexor of the thumb; the flexor radialis cannot be said to pass through it; the flexor ulnaris, and the ulnar nerve and artery, are anterior to it. This ring is lined by the great *carpal bursa*, which is reflected from the posterior surface of the ligament on the forepart of the common fasciculus of the nerve and tendons, then round their ulnar side to their back part, passing more or less between them, and thence to the front of the carpus, on which it extends considerably up and down, and prolonged for some way in the palm along the four flexor tendons. The flexor pollicis has a distinct synovial sheath which passes a considerable distance on this tendon in each direction. The carpal bursa is very liable to distention, it then bulges forward in an irregular form, above the ligament; it often contains a number of firm, small, granular bodies floating in a thin fluid; the uses of this bursa are obvious. On the back of the hand a very thin aponeurosis exists, continued from the posterior annular ligament; it consists of delicate transverse fibres which cover the extensor tendons; a loose elastic cellular tissue separates it from the integuments. Anteriorly, there is a remarkably strong fascia, the *palmar fascia:* this is of a triangular form, commences narrow at the annular ligament, from which, and from the tendon of the palmaris longus, it *arises;* it then expands over the palm of the hand, and near the fingers divides into four fasciculi, or rather into eight, as each of them is forked and *inserted* into either side of the sheaths of the flexor tendons, and into the capsular ligaments of the first phalanges; transverse bands pass across these diverging fasciculi, and prevent their divarication, and thus fibrous arches are formed under which the flexor tendons and the digital nerves and vessels pass, secure from displacement and from pressure; several fibres penetrate between the tendons, and join the metacarpal bones and the interosseous muscles; this fascia is closely connected to the integuments, but loose cellular tissue intervenes between it and the palmar vessels and nerves and the flexor tendons which thus can move easily beneath it; two strong septa pass from its deep surface to join the interosseous fasciæ, and separate the middle of the palm from the external and internal lateral portions. The connexions of the palmar aponeurosis to the sheaths of the tendons below, and to the annular ligament above, explain the effects of inflammation when seated within the former, such as the pain and tension in the palm, the fulness on the dorsum, and the extension of the disease to the forearm beneath the annular ligament. A thin aponeurosis, derived from the outer edge of the palmar fascia, covers the muscles of the thumb, and a similar one

those of the little finger. Attached to the palmar fascia is the following small cutaneous muscle.

Palmaris Brevis *arises* from the annular ligament and from the inner edge of the palmar fascia; the fasciculi pass transversely inwards, and are *inserted* by scattered fibres into the integuments on the inner side of the palm of the hand. *Use*, to deepen the hollow of the palm of the hand by drawing the integuments towards the thumb; it covers the ulnar artery and nerve, and passes across the muscles of the little finger. We have no analogous muscle to this in the foot. We may now dissect off the fascia of the hand and forearm, to expose the muscles; in some situations it is difficult and indeed unnecessary to separate this from the muscular fibres; beneath the palmar fascia we expose the superficial palmar arch of vessels and nerves passing across the flexor tendons and the lumbricales muscles.

The muscles of the forearm are so very numerous, that it will be found convenient to class them according to their situations and their use. One set of these muscles is employed in bending the forearm, wrist, and fingers: these are the *flexors:* a second, nearly allied to these, have the power of pronating the hand, that is, of rolling the radius across the ulna, so as to make the palm of the hand look downwards; these are the *pronators:* a third set, the *extensors*, can extend the forearm, hand, and fingers; and a fourth, allied to

*Fig.* 31.*

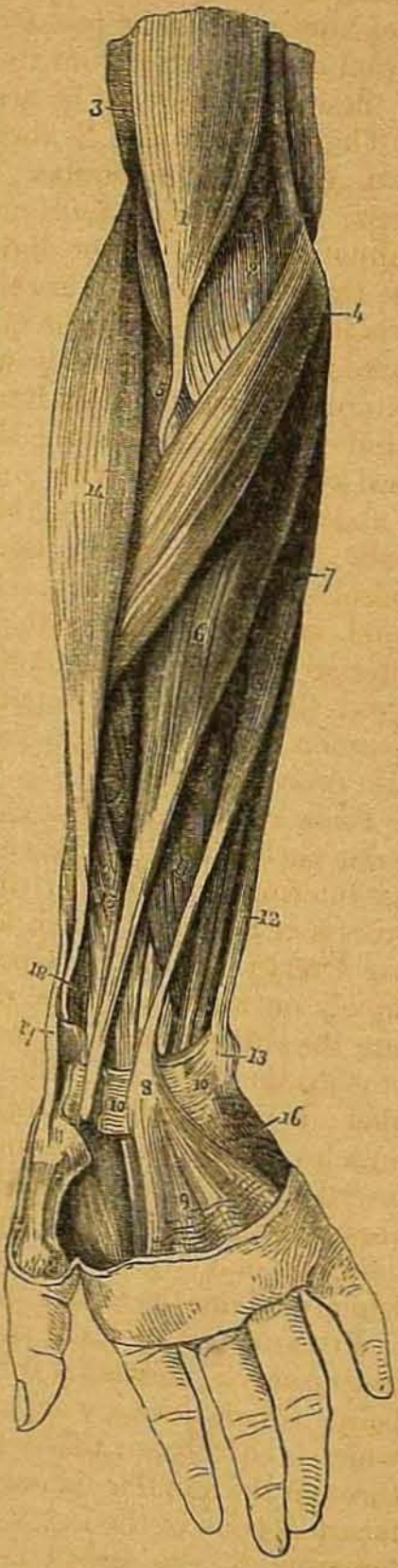

* The superficial muscles on the anterior aspect of the forearm. 1. The biceps muscle. 2. The inferior portion of the brachialis anticus muscle. 3. Inferior extremity of the external portion of the triceps. 4. The pronator teres muscle. 5. Portion of the supinator brevis muscle. 6. The flexor carpi radialis muscle. 7. The palmaris longus muscle. 8. The insertion of the tendon of the palmaris longus into the palmar fascia and anterior annular ligament. 9. The palmar fascia or aponeurosis. 10. 10. The anterior annular ligament. 11. 11. The flexor digitorum sublimis muscle. 12. The flexor carpi ulnaris muscle. 13. The pisiform bone. 14. The supinator radii longus muscle. 15. Portion of the flexor pollicis longus muscle. 16. The palmaris brevis muscle. 17. The tendon of the extensor ossis metacarpi pollicis. 18. Portion of the pronator quadratus muscle.

these, the *supinators*, can turn the hand supine; that is, place the radius and ulna on the same plane, and make the palm of the hand look upwards. The pronators and flexors arise chiefly from the internal condyle, and from the inner or ulnar side of the forearm; each of these divisions may be arranged into a superficial and deep layer.

The pronators and flexors, arising from the inner side of the forearm, are eight in number; five in the superficial layer, three in the deep; the five *superficial* are, the pronator teres, flexor carpi radialis, palmaris longus, flexor digitorum sublimis, and flexor carpi ulnaris: the three *deep* muscles are the flexor digitorum profundus, flexor pollicis longus, and pronator quadratus. In the following description of these muscles, the hand is supposed to be turned forwards, the radius externally, and the ulna internally; the elbow joint above, and the hand and fingers below; the words "internal" and "external" are used synonymously with "ulnar" and "radial;" and like the terms "abduction" and "adduction," are referred to the median line of the body; in the dissection, however, of some of the palmar and digital muscles, these latter terms have reference to the middle line of the hand, and not to that of the body. The muscles which arise from the internal condyle of the humerus are covered by the fascia of the biceps; they cannot be separated from each other above, but have a common tendinous origin from the condyle, the fascia, and its septa, also from the ulna.

Pronator Radii Teres *arises* tendinous and fleshy from the anterior part of the internal condyle, from the fascia of the forearm, and its intermuscular septa; also by a small tendon from the coronoid process of the ulna, which lies between the median nerve and the ulnar artery; the nerve separates these origins; the fibres pass obliquely outwards over the radius, and are *inserted*, chiefly tendinous, into the outer and back part of the radius, about its centre. *Use*, to pronate the hand, by rolling the radius forwards and inwards over the ulna; it is also a flexor of the forearm: this is the most external of the muscles arising from the inner condyle; it is superficial, except at its insertion, which is covered by the supinator longus, and by the radial vessels, and is inferior to the supinator brevis; this muscle forms the internal boundary of the triangular hollow at the bend of the elbow, which contains the tendon of the biceps, the brachial nerve and vessels.

Flexor Carpi Radialis *arises* narrow and tendinous from the inner condyle, and fleshy from the intermuscular septa; it forms a thick belly, which lies very superficial, and ends in a prominent flat tendon which is equally so; this descends obliquely outwards, passes beneath or through the annular ligament, and is *inserted* into the base of the metacarpal bone of the index finger. *Use*, to bend the hand, wrist, and forearm; it also assists in pronation; it may also abduct the hand. This muscle is overlapped above by the pronator teres, and covered below by the annular ligament and by the muscles of the thumb, so that its insertion cannot be seen until the palm of the hand has been dissected; it arises and descends at first between the pronator teres

and palmaris longus, afterwards between this latter and the supinator longus, from which it is separated by the radial nerve and vessels : the radial edge of this tendon may serve as a guide in cutting down on the radial artery in the living subject.

PALMARIS LONGUS *arises* by a slender tendon from the inner condyle, and from the fascia of the forearm ; forms a short belly, which ends in a flat tendon; *inserted* near the root of the thumb into the annular ligament and palmar aponeurosis. *Use*, to bend the hand and make tense the palmar fascia ; it descends between the flexor carpi radialis and ulnaris, and lies on the flexor sublimis, from which it is separated by a strong fascia. This muscle is sometimes wanting ; occasionally it arises deep, in which case it is covered in the upper two-thirds of the forearm by the flexor sublimis.

FLEXOR CARPI ULNARIS *arises* tendinous from the internal condyle, tendinous and fleshy from the inner side of the olecranon process ; the ulnar nerve and posterior ulnar recurrent arteries separate these origins ; it also arises by a tendinous expansion from the inner edge of the ulna nearly its whole length, and from the fascia of the forearm ; the fibres pass obliquely forwards to a tendon which descends in front of the ulna, and which overlaps the ulnar nerve and vessels, and is *inserted* into the pisiform bone, and by a few ligamentous fibres into the base of the fifth metacarpal bone ; this insertion is also connected to the muscles of the little finger. *Use*, to flex the hand, and adduct it, particularly when assisted by the extensor carpi ulnaris ; adduction of the hand is not so limited as abduction, in consequence of the ulna being shorter below than the radius. This muscle is superficial, and lies internal and rather posterior to the preceding muscles ; it descends between the flexor sublimis and extensor carpi ulnaris, and lies upon the flexor profundus ; the tendon passes over the annular ligament, and is connected to it by a tendinous slip which also passes over the ulnar artery and nerve.

FLEXOR DIGITORUM SUBLIMIS PERFORATUS, *arises* tendinous and fleshy from the internal condyle and internal lateral ligament ; tendinous from the coronoid process and fleshy from that portion of the radius which is below its tubercle, and internal to the pronator teres, and between the supinator brevis and flexor pollicis longus : it forms a large muscle, which ends in four tendons ; these descend, two anterior, for the middle and ring finger ; and two posterior, for the index and little finger ; they all pass beneath the annular ligament, along with the median nerve, to their outer side ; they occupy the inner half of this space, and are close to the unciform bone ; they then proceed diverging along the palm of the hand, superficial to the deep flexor tendons, and beneath the palmar fascia ; and at the first phalanx of each finger, or opposite the head of each metacarpal bone, each of these tendons becomes enclosed in a strong sheath, with one of the deep flexors, and is slightly concave over it ; this sheath is continued to the anterior extremity of the second phalanx. Near the end of the first phalanx each of the superficial flexor tendons is split for the pas-

sage of the tendon of the deep flexor, which is continued on to the last or ungual phalanx; while the divisions of each of the superficial tendons become somewhat twisted, that is, the inner or opposed edges of the slit are everted or folded out beneath the deep flexor, so as to lie nearer to the bone and to the joint, connected together by cross slips, and are inserted by two processes into the anterior margins of the second phalanx about its centre. *Use*, to flex the second joint of each finger on the hand, the hand on the forearm, and the latter on the arm. The origin of this muscle is partly concealed by the three first described muscles, which arise from the inner condyle, and to which it is connected by the intermuscular septa; inferiorly a portion of it is superficial between the flexor carpi ulnaris and palmaris longus; above it covers the ulnar vessels and nerve, which separate it from the profundus; it also covers the median nerve and the flexor pollicis longus, to which it is often connected by a fleshy slip. The tendons are enveloped in the *carpal bursa* behind the annular ligament. In the palm of the hand they are covered by the integuments, palmar fascia, and the superficial palmar arch of vessels and nerves; above the metacarpo-phalangal joints, these, together with the deep tendons and the lumbricales, are bound down by the fibrous sheaths and arches formed by the septa of the palmar fascia, and immediately after, and through the rest of their course along the fingers each tendon is enclosed in a strong fibrous sheath, which is continued to the end of the second phalanx. The *sheaths* for the flexor tendons require special attention, they are covered by the integuments, and laterally by the digital vessels and nerves; one or two may be dissected; each of these sheaths is an osteo-fibrous canal or tube; the flat surface of the phalanges forming one wall, the remainder composed of strong semicircular fibres, interlaced, and of a pearly colour, very dense opposite the phalanges, but thin, and even deficient over the angles of the articulations; they commence beyond the metacarpo-phalangal joints, and are connected to their ligaments, and terminate above, between those of the second and last, or ungual phalanx, by intermingling with the deep flexor tendons; these tubes preserve their form even when the tendons have been removed; the fibres are arranged in semicircular fasciculi, and are attached to each border of the phalanges; open one of these sheaths, and the whole tube will be found lined by a synovial membrane, which is prolonged for some distance into the palmar region, and is reflected round these two tendons, enclosing each, and forming two or three triangular folds or retinacula, one posteriorly near the base of the first phalanx, and extending from one tendon to the other; another more anterior, passes from the split in the superficial to the deep tendon; and the others pass from the deep tendon to the bone; these bursæ end in two cul de sacs, one in the palm, the other at the extremity of the second phalanx; the retinacula sometimes contain fibrous cords, they resemble the synovial folds in the knee joint, and may be designed partly to support the tendons, and partly to convey nutritious vessels to the different tissues. These sheaths are very

useful in confining the tendons close to the phalanges, and preventing their starting forwards in the action of the muscles, the latter also, in consequence of their connexion to the metacarpo-phalangal joints, are enabled to flex the first phalanges and the metacarpus, which possesses no distinct flexor, unless the flexor carpi radialis may be so considered.

Divide the flexor sublimis and carpi radialis, and the three deep muscles will be partially exposed, namely, the flexor digitorum profundus, flexor pollicis longus, and, nearly concealed by these, the pronator quadratus.

FLEXOR DIGITORUM PROFUNDUS PERFORANS *arises* fleshy from three superior fourths of the anterior surface of the ulna, and from the internal half of the interosseous ligament; it sometimes receives a small slip from the radius below its tubercle; it forms a thick muscle which descends along the middle and ulnar side of the fore-arm, between the flexor ulnaris and flexor pollicis, and ends in four flat ten-

*Fig.* 32.*

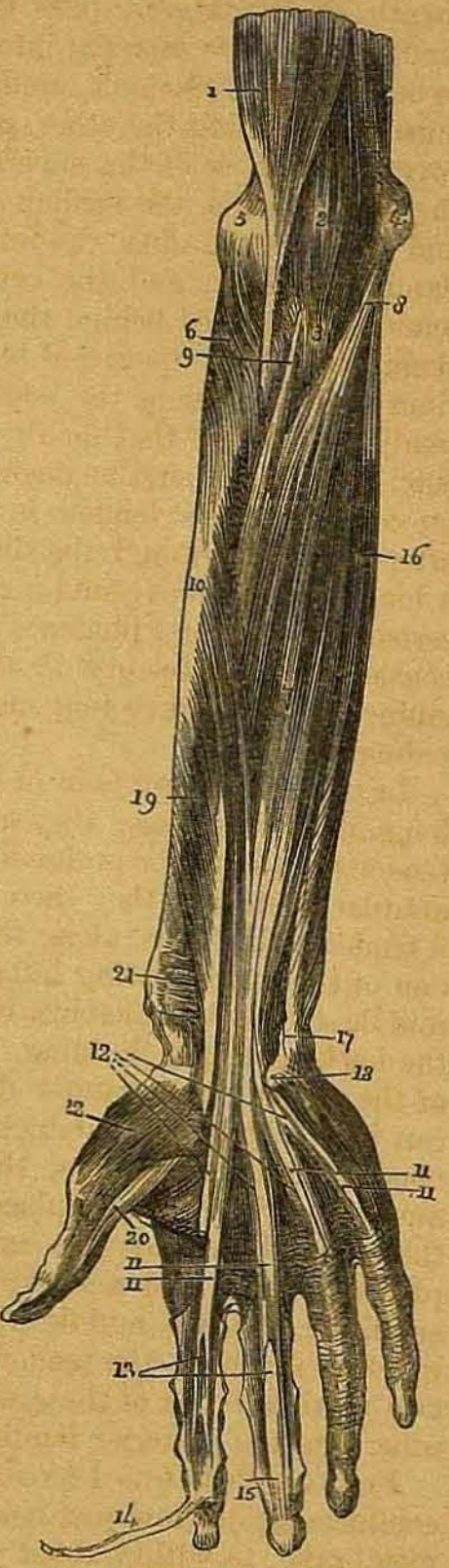

* The muscles on the anterior aspect of the forearm, part of the superficial layer having been removed. 1. The inferior extremity of the biceps muscle and its tendon, inserted into the tubercle of the radius. 2. The lower part of the brachialis anticus muscle, inserted into 3. The coronoid process of the ulna. 4. The internal condyle of the humerus. 5. The external condyle of the humerus. 6. The supinator brevis muscle. 7. The flexor digitorum sublimis muscle. 8. Its attachment to the internal condyle of the humerus. 9. Its attachment to the coronoid process of the ulna. 10. The attachment of the same muscle to the anterior surface of the radius. 11. The four tendons of the flexor digitorum sublimis. 12. The four tendons of the flexor digitorum profundus, lying beneath the tendons of the superficial flexor. 13. 13. The split in the superficial tendons through which the tendons of the deep flexor pass. 14. The tendon of the deep flexor, divided and drawn downwards to shew the disposition of the corresponding tendon of the superficial flexor. 15. A tendon of the deep flexor inserted into the last phalanx. 16. The flexor carpis ulnaris muscle. 17. The pisiform bone. 18. The hook of the unciform bone. 19. The flexor pollicis longus. 20. Its tendon passing between the two portions of the short flexor to the last phalanx of the thumb. 21. The pronator quadratus muscle. 22. The abductor pollicis muscle.

dons; these pass beneath the annular ligament, enter the ligamentous sheaths on the fingers, pass through the slits in the superficial flexor tendons, and are *inserted* into the last phalanx of each finger. *Use*, to bend the last phalanx, and to cooperate with the superficial flexor muscle in bending the other phalanges and the wrist; this muscle is covered by those of the superficial layer, which have been described; the ulnar vessels, the median and ulnar nerves, also descend along it; and it covers the ulna, the interosseous ligament and vessels, the pronator quadratus, and the carpus; beneath the annular ligament the tendons are placed behind those of the sublimis, and separated from them by folds of the carpal bursa; these deep tendons are not so distinct and separate as the superficial, but are united more or less by tendinous bands; that for the index finger, however, is usually distinct from the others, analogous in this respect to its extensor tendon; on each finger its tendon is superficial to that of the flexor sublimis after its transit through the slit; this portion of the tendon is marked by a longitudinal groove, and a retinaculum passes back from it to be inserted into the first phalanx. As the lumbricales muscles may be considered as accessory to the deep flexor, they can be now examined, or their dissection may be postponed until that of the other palmar muscles.

LUMBRICALES are four in number, small, round, and fleshy, with long delicate tendons; they *arise* from the outer and radial side of the tendons of the flexor profundus, near the carpus, a little beyond the annular ligament; they each form a small fleshy belly, which ends in a tendon; this runs along the radial side of the finger, joins the tendon of the corresponding interosseous muscle, and is *inserted* about the middle of the first phalanx into the tendinous expansion which covers the back part of each finger. *Use*, to assist in bending the first joint of the finger; they cannot do so unless the flexors are tense; they can also adduct and abduct the fingers, and when the common extensor muscle is in action, they may assist in extending them; they may also prevent the displacement of the flexor and extensor tendons; these small muscles are covered by the superficial flexor tendons, palmar vessels, and nerves; the first is the largest, the fourth the smallest; the two middle run nearly parallel, but the internal and external diverge; the tendons of the lumbricales frequently divide into two portions: one of these will be *inserted* into the first phalanx, the other into the posterior tendinous expansion.

FLEXOR POLLICIS LONGUS *arises* from the forepart of the radius, commencing narrow just below its tubercle, and from the interosseous membrane, to within about two inches of the carpus, it also very frequently arises by a long and narrow tendinous and fleshy slip from the coronoid process; this at first looks like a distinct muscle; all the fibres descend obliquely forwards to a tendon which passes beneath the annular ligament, close to the carpus, behind the median nerve, external to the deep flexor tendons, and surrounded by a distinct synovial membrane, it then runs outwards between the two portions of the

*Fig. 33.**

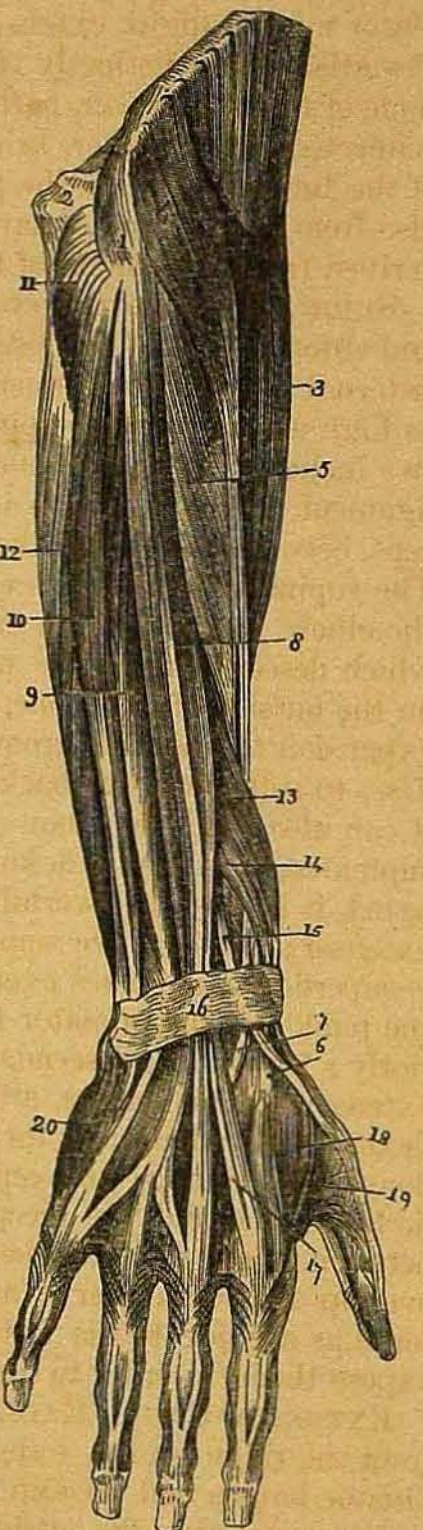


short flexor, and the two sesamoid tubercles at the extremity of the metacarpal bone; it next enters a strong ligamentous sheath lined by a bursa, and is confined by it as far as the last phalanx of the thumb, into the middle of which it is *inserted. Use*, to flex and adduct the different joints of the thumb upon the hand, and the latter upon the forearm. This muscle is covered by the flexor sublimis and radialis, and by the radial vessels, and inferiorly by the annular ligament, it descends along the radial side of the flexor profundus.

Pronator Quadratus is exposed by separating the flexor pollicis and profundus; it is a small, square muscle, situated just above the carpus, and *arises* tendinous and fleshy from the inferior fifth of the internal and anterior surface of the ulna; the fibres pass transversely outwards, winding round the ulna, and descend a little to be *inserted* into the anterior part of the inferior fourth of the radius. *Use*, to roll the radius over the ulna, and so to pronate the hand; this muscle is covered by the tendons of the preceding, and by the ulnar and radial vessels, and it lies on the interosseous ligament, the radius, and the ulna.

The muscles which are situated on the outer and back part of the forearm are supinators and extensors, and are also arranged into two layers, a superficial and a deep; the superficial consist of seven, namely, supinator radii longus, extensor

* The superficial layer of muscles on the posterior aspect of the forearm. 1. The external condyle of the humerus. 2. The olecranon process of the ulna. 3. The supinator radii longus muscle. 4. The extensor carpi radialis longus. 5. The extensor carpi radialis brevis. 6. The insertion of the tendon of the extensor carpi radialis longus into the second metacarpal bone. 7. The insertion of the tendon of the extensor carpi radialis brevis into the third metacarpal bone. 8. The extensor digitorum communis muscle. 9. The extensor minimi digiti. 10. The extensor carpi ulnaris. 11. The anconæus muscle. 12. Part of the flexor carpi ulnaris. 13. The extensor ossis metacarpi pollicis. 14. The extensor primi internodii pollicis. 15. The tendon of the extensor secundi internodii pollicis. 16. The posterior annular ligament of the carpus. 17. The tendon of the extensor indicis. 18. The first dorsal interosseous muscle. The other three dorsal interosseous muscles are seen between the metacarpal bones of the other fingers. 19. Part of the adductor pollicis. 20. The muscles of the little finger.

carpi radialis longus, and brevis, extensor digitorum communis, extensor minimi digiti, extensor carpi ulnaris and anconæus; these muscles arise more distinctly than those on the internal side of the arm; some of them, however, particularly those on the back part, are closely connected to each other, arising in common from the external condyle of the humerus, from the posterior surface of the radius and ulna, also from the intermuscular ligaments and the fascia, which is partly derived from the tendon of the triceps.

Supinator Radii Longus forms the prominence along the outer and anterior part of the forearm, *arises* tendinous and fleshy from the external ridge of the humerus, commencing a little below the deltoid, as high as the musculo-spiral groove, and continuing to within about two inches of the outer condyle; it also arises from the intermuscular ligament, which separates it from the second or outer head of the triceps, between which and the brachiæus anticus this muscle is situated. The supinator longus descends along the outer and anterior part of the elbow, and about the middle of the forearm ends in a flat tendon, which descends along the radius, and is *inserted* into a rough surface on the outside of that bone, near its styloid process, and sends off an expansion to line the groove for the extensor tendons of the thumb. *Use*, to roll the radius backwards, so as to make the hand look supine; it can also bend the elbow joint. When the forearm is extended and supinated, it is then a flexor of the elbow, but when the limb is pronated, it is then a powerful supinator; it can scarcely ever act as an extensor; it may have some influence as an abductor. This muscle is superficial; it passes over the extensor carpi radialis longus above, the tendon of the pronator teres in the middle, and the radius inferiorly; its tendon descends at first between the pronator teres and extensor radialis longus, afterwards between the latter and that of the flexor carpi radialis; at its insertion it is crossed by the extensor tendons of the thumb; the cephalic vein and external cutaneous nerve lie between it and the biceps; the musculo-spiral nerve and artery between it and the brachiæus anticus. This muscle and its tendon overlap the radial nerve and vessels; its ulnar edge, therefore, will serve as a guide to the latter, in case we are required, during life, to expose them, in order to tie a ligature around the radial artery.

Extensor Carpi Radialis Longus *arises* tendinous and fleshy from the ridge on the external side of the humerus, between the supinator longus and the external condyle; it forms a thick, short belly which passes over the outside of the joint, ends in a flat tendon, which descends along the outer and back part of the radius, runs through a groove on its lower extremity, and, passing over the wrist joint, is *inserted* into the back part of the carpal end of the metacarpal bone of the index finger, nearly opposite to that of the flexor carpi radialis. *Use*, it extends the wrist, bends the hand backwards, and abducts it a little; it may also assist in bending the elbow joint; its belly is covered by the last described muscle, but projects behind it; the tendon descends behind that of the supinator longus, and passes beneath

the extensors of the thumb and the annular ligament; it covers the supinator brevis and the following muscle.

Extensor Carpi Radialis Brevis *arises* tendinous and fleshy from the inferior and posterior part of the external condyle, and from the external lateral ligament, forms a thick belly, which descends along the back part of the radius, ends in a flat tendon, which runs through the same groove as the tendon of the last muscle, internal to which it lies: this groove is lined by a bursa, and is partly divided by a bony ridge; the tendon then passes beneath the annular ligament, and is *inserted* into the carpal extremity of the third metacarpal bone, or that of the middle finger. *Use*, similar to that of the last; it is covered superiorly by the last described muscle, and by the supinator longus, and below by the tendons of the extensor muscles of the thumb, and by that of the last muscle, and by the skin; it covers the supinator brevis and the insertion of the pronator teres.

Extensor Digitorum Communis is situated more towards the back part of the forearm than the last described muscles; it *arises*, in common with the last, and with the extensor minimi digiti, from the external condyle, the fascia, and its intermuscular processes, also from the ulna; it descends along the back of the forearm, and about the middle of the latter ends in four muscles, each of which ends in a tendon; these pass under the annular ligament in a groove in the radius, extend along the back of the hand, expanding as they approach the four fingers, into all the phalanges of which they are *inserted* by a tendinous expansion. *Use*, to extend all the joints of the fingers, also the carpus; this muscle arises between the extensor carpi radialis brevis and extensor minimi digiti; it descends superficially between these, and over the supinator brevis and extensors of the thumb; on the back of the hand the tendons are connected to each other by cross slips, but the tendon of the index finger is generally free; that which goes to the ring finger is the largest, and a strong transverse band often connects it to that of the little finger: all the tendons, as they approach the base of the first phalanx, become thick but narrow, and give off a fibrous expansion on each side to cover the joint; afterwards they enlarge and are joined by the tendons of the lumbricales and interossei; at the articulation of the first and second phalanx each divides into three bands; the middle one is inserted into the posterior surface of the upper end of the second phalanx; the lateral pass along the sides of this articulation; they afterwards converge and unite in a flat tendon, which is inserted into the base of the last or third phalanx. The back part of all the fingers is covered, so far as the last phalanx, by a tendinous expansion, derived from these tendons, and from those of the lumbricales and interossei muscles.

Extensor Carpi Ulnaris is very superficial, *arises* tendinous and fleshy between the extensor minimi digiti and anconæus, from the external condyle, fascia, and intermuscular septa; descends obliquely inwards, between the flexor ulnaris and extensor minimi digiti, towards the ulna, and receives an addition from it; it ends in a strong tendon,

which runs through a groove on the back of the ulna, then beneath the annular ligament, and behind the cuneiform bone, and is *inserted* into the carpal end of the fifth metacarpal bone. *Use*, to extend the hand and bend it backwards; also to adduct it, that is, flex it laterally towards the ulna.

Anconæus, small, triangular, and placed at the outer side of the olecranon, beneath the skin; *arises* from the posterior and inferior part of the external condyle and lateral ligament by a very distinct tendon, also by some fleshy fibres from the lower border of the triceps, forms a thick triangular mass, which adheres to the synovial membrane, and descends obliquely inwards, to be *inserted* into the external surface of the olecranon, and about the superior fifth of the posterior surface of the ulna. *Use*, to extend the forearm on the arm, and to raise the synovial membrane out of the articulation; this muscle is partly covered by the tendon and aponeurosis of the triceps; the remainder of it is superficial; it is situated between the olecranon and the extensor carpi ulnaris; it often appears as a continuation of the triceps; it covers a portion of the radio-humeral joint, of the coronary ligament, and of the supinator brevis.

Fig. 35.*

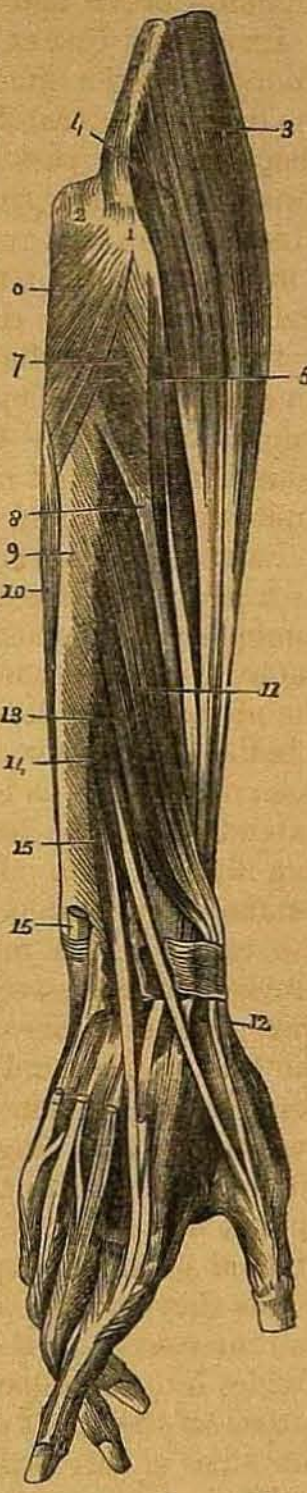


Extensor Minimi Digiti, *vel* Auricularis, *arises* in common with the extensor communis, and descends between it and the extensor carpi ulnaris; it forms a small fleshy belly, which descends very obliquely inwards, and ends in a slender tendon; this passes through a separate groove in the radius, and also through a distinct division of the annular ligament, in which situation it is frequently found divided into two, which continue in contact, and afterwards unite: this tendon becomes attached to the fourth tendon of the extensor communis, and is *inserted* along with it into the posterior part of the phalanges of the little finger. *Use*, to assist the extensor communis, and to extend and abduct the little finger independent of the others.

* The deep layer of muscles on the posterior aspect of the forearm. 1. The external condyle of the humerus. 2. The olecranon process of the ulna. 3. The supinator radii longus. 4. The extensor carpi radialis longus. 5. The extensor carpi radialis brevis. 6. The anconæus. 7. The supinator radii brevis. 8. The posterior surface of the radius. 9. The posterior surface of the ulna. 10. Portion of the flexor carpi ulnaris. 11. Extensor ossis metacarpi pollicis, or abductor pollicis longus. 12. The insertion of its tendon into the metacarpal bone of the thumb. 13. The extensor primi internodii pollicis. 14. The extensor secundi internodii pollicis. 15. The extensor indicis. 16. The inferior portion of the tendon of the extensor carpi ulnaris.

The deep muscles in this situation are five in number, they will be exposed by removing the superficial layer; they consist of the supinator radii brevis, three extensors of the thumb, and the indicator.

Supinator Radii Brevis, short and flat, surrounds the upper part of the radius, *arises* from the external condyle, external lateral, and coronary ligaments, and from a ridge on the outer side of the ulna, which commences below its lesser sigmoid cavity; the fibres adhere to the capsular ligament, and descend obliquely outwards and forwards round the upper part of the radius, and are *inserted* into the upper third of the external and anterior surface of this bone, from above its tubercle down to the insertion of the pronator teres. *Use*, to turn the radius outwards, so as to make the hand look supine, which it can effect with great power; it can also assist in extending the forearm. This muscle nearly surrounds the upper part of the radius, it is covered by the supinator longus, the radial extensors of the carpus, and the extensor digitorum communis externally; by the anconæus and extensor ulnaris posteriorly; and anteriorly by the radial nerve and vessels, and by the brachiæus and biceps; it partly surrounds the humeral and ulnar articulations of the radius; its anterior edge is notched above for the insertion of the biceps, and is overlapped by the pronator teres below; it is perforated by the posterior interosseous nerve.

Extensor Ossis Metacarpi Pollicis, or Abductor Pollicis Longus, *arises* fleshy from the middle of the posterior part of the ulna, below the anconæus, also from the interosseous ligament and posterior surface of the radius below the supinator brevis; it descends outwards and forwards, and ends in a tendon, which passes through a groove on the outside of the lower end of the radius, runs by the side of the carpus, and is *inserted* in general by two tendons, one into the os trapezium, and the other into the upper and back part of the metacarpal bone of the thumb. *Use*, to extend the first joint of the thumb, and separate it from the fingers; it also extends the wrist, and abducts the hand; it can also assist in supination. The origin of this muscle is concealed by the extensor communis and carpi ulnaris; the tendon is superficial and passes over the tendons of the radial extensors of the carpus, also over the radial vessels. I have sometimes found a second muscle analogous to this, but arising so high as from the external condyle of the humerus, and ending in a very long slender tendon which accompanied that of the last muscle, and inserted along with it into the metacarpal bone of the thumb.

Extensor Primi Internodii Pollicis, or Extensor Minor, *arises* from the back part of the ulna, below its middle, and from the interosseous ligament and radius; it descends along the ulnar side of the last muscle; its tendon passes through the same groove in the radius, and bound down by the same portion of the annular ligament, and is *inserted* into the posterior part of the first phalanx; a small slip is often continued on to the second phalanx. *Use*, to extend the second joint of the thumb, and to assist the last described muscle; its connexions are also similar.

EXTENSOR SECUNDI INTERNODII POLLICIS, or EXTENSOR MAJOR, *arises* from the posterior surface of the ulna above its centre, and from the interosseous membrane; its belly overlaps the two former muscles, its tendon passes along a distinct groove in the radius, runs over the outer side of the wrist, the metacarpal bone, and first phalanx of the thumb, and is *inserted* into the posterior part of the second or last phalanx. *Use*, to extend the last phalanx of the thumb upon the first, and to assist the former muscles in extending and supinating the hand. The tendon of this muscle is separated from the two former, on the outer and back part of the wrist, by a small space distinct through the skin, in which we perceive the tendons of the radial extensors of the carpus, and the radial artery; the relations of this muscle in other respects are nearly similar to those of the other extensors of the thumb.

EXTENSOR INDICIS, or INDICATOR, *arises* from the middle of the posterior surface of the ulna and interosseous membrane; its tendon passes under the annular ligament along with those of the common extensor, is attached to the radial side of that tendon which belongs to the forefinger, and is *inserted* along with it into its second and third phalanges. *Use*, it assists the common extensor, or produces the extension of the forefinger alone, as in pointing. This muscle is concealed by the extensor communis and ulnaris, lies to the ulnar side of the extensor pollicis major, and its tendon passes under those of the common extensor, to which it is sometimes connected by a tendinous slip. Next dissect the muscles of the hand, which consist, externally, of the muscles of the thumb; internally, of those of the little finger, and in the middle of the lumbricales superficially, and the interossei, deep-seated; the lumbricales, or the accessories to the flexor profundus, have been already examined.

In conducting the dissection of this region, the student should make frequent and careful reference to its skeleton; we may observe that few portions of the animal frame present more interesting characters for minute anatomical examination than the human hand, as it, most probably, affords the best example that could be adduced, not only of superiority in the human organization, when contrasted with that of any other created being, but also of the most perfect adaptation of structure to function, of means to an end, of design in a plan, and of perfection in its execution. The great number of small bones, twenty-seven in all, with their joints and ligaments so securely connected, and so neatly adapted, as to combine the opposite qualities of strength and freedom of motion, all collected into so small a space with the numerous long and slender tendons, elegantly shaped, and each confined in its appropriate highly polished sheath or groove; the muscles of these, some large and strong, others small and weak, all linked together in the closest sympathy, and endowed with powers of executing the most varied motions, delicate, yet rapid, powerful, yet enduring, often instinctive, and, as it were, without our thought or cognizance, yet are all these muscles voluntary and wonderfully capable of education and improvement, so as to become, not only the principal agents in most

of the physical acts of life, defensive or offensive, but also the immediate instrument in the production of every work of art, thereby, in a great measure, pourtraying the feelings of the mind, and the powers of the intellect. The large supply of bloodvessels and of nerves, imparting the highest sensibility, and the most exquisite delicacy of tact and feeling, and these properties, too, residing in a part necessarily, and almost constantly exposed to violence or injury; these, and many other circumstances connected with the organization and the functions of the hand, are eminently calculated to excite our curiosity, and, when fully and properly investigated, cannot fail to ensure admiration and respect.

The eight bones of the carpus, small, and of irregular forms, are

*Fig.* 35.*

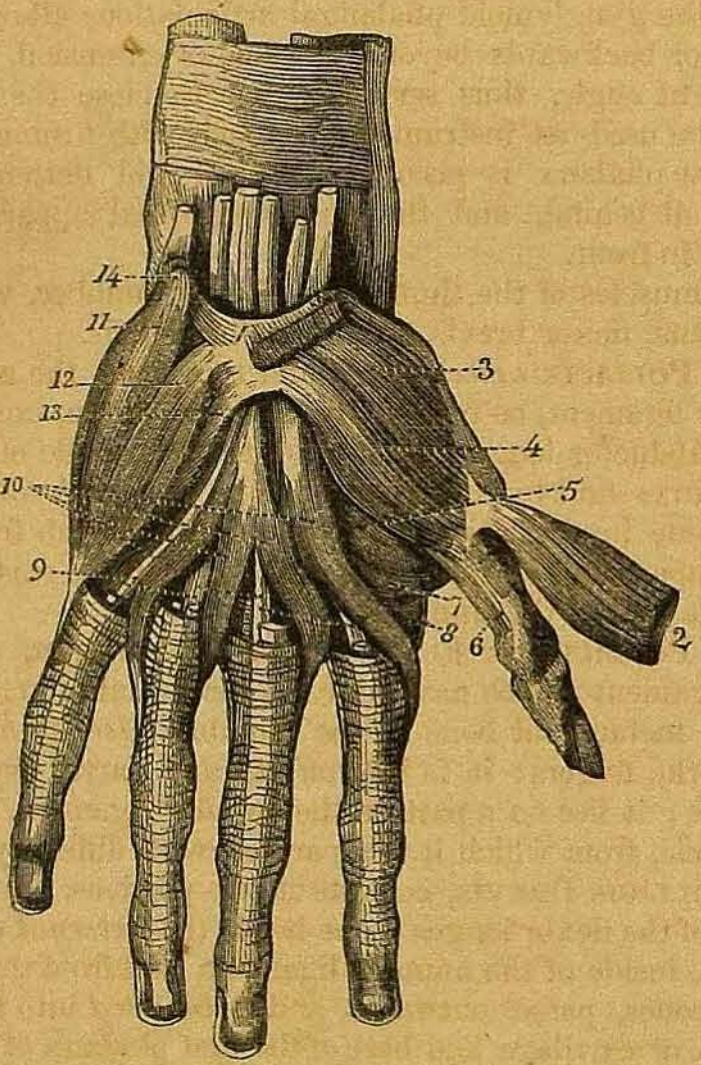


* The muscles of the hand. 1. The anterior annular ligament. 2. The abductor pollicis muscle divided close to its attachment to the annular ligament and thrown downwards. 3. The flexor ossis metacarpi, or opponens pollicis. 4. The anterior, or exernal portion of the flexor pollicis brevis. 5. The posterior, or internal portion of the same muscle. 6. The tendon of the flexor pollicis longus. 7. The adductor pollicis. 8. Portion of the first dorsal interosseous muscle. 9. Tendons of the flexor digitorum profundus. 10. The four lumbricales muscles. 11. The abductor minimi digiti. 12. The flexor brevis minimi digiti. 13. The opponens or adductor minimi digiti. 14. The os pisiforme.

compacted into an arch, which, by means of the annular ligament, is converted into a ring, thus this weak pile of bones acquires much strength, and a secure passage is provided for the tendons, vessels, and nerves. The nineteen metacarpal and phalangal bones, by their great length, add considerably to the length of the hand, and extend the sphere of its motions. The metacarpus is arched towards the palm in both directions, thereby imparting that degree of strength which it requires as a medium for supporting the weight of the body, as is occasionally required, and at the same time fitting it the better to serve as an organ of prehension; this cup-like form of the palm is beautifully completed by the muscular ball of the thumb externally, and by the muscles of the little finger internally; the very limited motions of the metacarpus on the carpus secure this form permanently, while the arthrodial metacarpo-phalangal joints admit of motion in all directions, and the gynglymoid phalangal articulations allow of no motion laterally or backwards beyond the line of extension, but can be flexed to a right angle, thus serving either to close the hand completely, or to be used as instruments of touch with firmness and precision; the last phalanx is peculiarly shaped and flattened, so as to support the nail behind, and the pulpy organized apparatus for the sense of touch in front.

The short muscles of the thumb are four in number, viz., the abductor, opponens, flexor brevis, and adductor pollicis.

Abductor Pollicis *arises* broad and thin from the anterior part of the annular ligament, os naviculàre, and trapezium, and from the tendon of the abductor longus, *inserted* into the outside of the base of the first phalanx, and by an expansion into the back of both phalanges; its name implies its *use*, to separate the thumb from the fingers; it lies superficial, and is most external of these small muscles, which form the ball of the thumb.

Opponens Pollicis, or Flexor Ossis Metacarpi, *arises* from the annular ligament and os naviculare; *inserted* into the anterior extremity of the metacarpal bone of the thumb. *Use*, to approximate the thumb to the fingers; it is internal to and partly overlapped by the last muscle; it lies on a part of the annular ligament, and of the following muscle, from which it is separated with difficulty.

Flexor Pollicis Brevis, consists of two portions, between which is the tendon of the flexor longus; one head, the *external* or *anterior*, *arises* from the inside of the annular ligament, and from the trapezium and scaphoid bones, passes outwards, and is *inserted* into the external sesamoid bone, or cartilage, and base of the first phalanx of the thumb; the second, or *internal* or *posterior*, *arises* from the os magnum, from the base of the metacarpal bone of the middle finger, and from the sheath of the flexor carpi radialis; it also passes outwards, distinct from the other at first, but afterwards united to it, and *inserted* into the internal sesamoid bone, and base of the first phalanx. *Use*, to flex the first phalanx and metacarpal bone on the carpus; this muscle is concealed by the two former, and by the first lumbricalis; it covers the two first

interossei muscles, and the tendon of the flexor carpi radialis ; its outer edge is connected to the opponens pollicis, and the internal to the adductor.

ADDUCTOR POLLICIS, triangular and broad, *arises* fleshy from three-fourths of the anterior surface of the third metacarpal bone, or that of the middle finger ; the fibres pass outwards over the second metacarpal bone, and converging are *inserted* into the inner side of the root of the first phalanx of the thumb, along with part of the last muscle ; its name denotes its *use.* This muscle at its origin is covered anteriorly by the deep flexor tendons and by the lumbricales ; its insertion is covered by the abductor indicis. The adductor pollicis may be regarded as the first of the anterior interossei ; it is, however, much stronger than any of that group, and differs from them in passing over one metacarpal bone between its origin and insertion ; this is for the purpose of increasing the extent of adduction of the thumb. The number and strength of the muscles of this finger, as well as the peculiarity of its carpal articulation, render it eminently useful, and altogether superior to the corresponding member in any other animal, even in the highest of the quadrumana ; it possesses two flexors, three extensors, one of which is a powerful abductor, also a short abductor, an opponens, and a very strong adductor ; the alternate, combined, or varied actions of these muscles can move the thumb in all directions.

On the inner side of the palm of the hand are the short muscles of the little finger, which are three in number ; also the cutaneous muscle, palmaris brevis, which has been already examined.

ABDUCTOR MINIMI DIGITI *arises* fleshy from the annular ligament and from the pisiform bone ; its fibres run along the ulnar side of the metacarpal bone, and are *inserted* tendinous into the ulnar side of the first phalanx ; its name implies its *use ;* it is superficial ; a few fibres of the palmaris only cover it ; its origin is partly continuous with the insertion of the flexor carpi ulnaris.

FLEXOR BREVIS MINIMI DIGITI *arises* from the annular ligament and unciform bone, *inserted* by a round tendon into the base of the first phalanx of the little finger. *Use*, to flex and adduct the little finger ; it lies to the radial side of the last muscle, along with which it is inserted.

ADDUCTOR, or OPPONENS MINIMI DIGITI, *arises* along with, but internal to the last, and overlapped by it, and is *inserted* into all the metacarpal bone of this finger : its name denotes its *use.*

When all the flexor and extensor tendons have been removed, we observe the intervals between the metacarpal bones to be filled by muscular fibres, which are called the interosseous muscles. As there are four interosseous spaces, there must be eight of these muscles, two in each space, but one of the anterior set has been already described as the " adductor pollicis," differing from the interossei in passing across one metacarpal bone, as it proceeds from its origin to its insertion, in order to increase the extent of adduction of the thumb. One of the posterior set, also, is sometimes described as a distinct muscle,

"abductor indicis," therefore some only enumerate six interossei muscles, three anterior, and three posterior; we shall consider them as seven in number, three in front and four behind: their actions on the fingers are chiefly adduction and abduction; these terms are applied in reference, not to the medial line of the body, as in the description of other regions, but to the middle line or axis of the hand, which corresponds to the middle finger and its metacarpal bone; adduction is the approximation of the fingers, abduction their divarication. The anterior, or palmar interossei, are adductors; their origin, or fixed point, being nearer the axis than their moveable insertion; the posterior are abductors, their origin being further from the axis than their insertion, both also act on the extensor tendons, and keep these fixed to the dorsum of the fingers in the line of their phalanges, thus answering the same purpose as the sheaths in front; they may also, in consequence of this attachment, assist in the extension of the fingers, and hence it is that they have no power of acting, especially the posterior, unless the extensors are previously in action; when the fingers are bent and the hand but partially closed, we cannot separate or abduct the fingers, but the mere act of flexion adducts them at the same time. The anterior, or palmar interossei, are three in number, the adductor pollicis being excluded; they are placed on the metacarpal bones, rather than between them, are covered anteriorly by the flexor tendons and the lumbricales, by the palmar vessels and nerves, and by the deep palmar fascia, from which septa pass between these and the posterior muscles, which also project into the palm; posteriorly they are covered by the posterior interossei; one side of each is attached to the metacarpal bone, and the other is in contact with the projecting posterior muscle, the thin fascia only intervening; they each arise by a single, but a long origin, from one metacarpal bone, and are inserted into the first phalanx of the same finger, and into its extensor tendon; the first is along the ulnar side of the metacarpal bone of the index finger and inserted into its first phalanx, it will therefore adduct that finger towards the middle; the second and third are along the radial sides of the metacarpal bones of the ring and little fingers, and, inserted into their first phalanges, will also adduct those fingers towards the middle finger; the latter has no anterior interosseous muscle attached to it, for obvious reasons, it being the axis towards which the other fingers are adducted.

First Palmar Interosseous, or Adductor Indicis, *arises* by fleshy fibres from the two upper thirds of the ulnar side of the second metacarpal bone, and from the ligament connecting it to the trapezoid; these end in a small tendon which is *inserted* into the ulnar side of the base of the first phalanx of the forefinger and into the extensor aponeurosis. *Use*, to adduct this finger; it is covered anteriorly by the adductor and flexor pollicis brevis; the second dorsal interosseous is along its inner side.

Second Palmar Interosseous, or Adductor Annularis *arises* in like manner as the last from the radial side of the fourth metacar-

pal bone, and is *inserted* into the radial side of the base of the ring finger and into its extensor tendon. *Use*, to adduct the ring finger towards the middle.

Third Palmar Interosseous, or Adductor Minimi Digiti, *arises* from the radial side of the fifth metacarpal bone, and from the ligaments connecting it to the unciform; *inserted* into the radial side of the base of the first phalanx of the little finger and into its extensor tendon; it is covered by the opponens minimi digiti; the fourth dorsal interosseous corresponds to its radial side. *Use*, to adduct the little to the ring and middle fingers. The posterior interossei are four in number; they are longer and more distinct than the anterior; they may be seen posteriorly, filling the metacarpal intervals, also anteriorly projecting beyond the bones and connected to the anterior interossei; the first is much the largest and is named the

First Posterior Interosseous, or Abductor Indicis, between the thumb and forefinger; thin, flat, and triangular, the base above, the apex at its insertion; *arises* by two origins, each from the opposed sides of the first and second metacarpal bones; a tendinous arch connects these posteriorly, behind which the radial artery passes into the palmar region; the two fasciculi proceed distinct for some way, then end in a tendon which is *inserted* into the radial side of the base of the first phalanx of the index finger and into the border of its extensor tendon. *Use*, to move this finger from the others, or from the axis of the hand towards the thumb, it also draws it forwards towards the palm; this muscle crosses behind the adductor pollicis and is subcutaneous posteriorly; it can be felt and seen in the triangular cutaneous fold between the thumb and index finger; its palmar surface is in contact with the short flexor, and adductor of the thumb and first lumbricalis.

Second Posterior Interosseous, or Externus Medii, *arises* from the opposite sides of the second and third metacarpal bones, and is *inserted* into the radial side of the middle finger, and into its extensor tendon. *Use*, to move the latter outwards or towards the index.

Third Posterior Interosseous, or Internus Medii, *arises* from the opposed sides of the middle and ring fingers, and is *inserted*, like the last, into the ulnar side of the middle. *Use*, to move the latter inwards, or towards the ring finger; thus the middle finger has two dorsal interosseous muscles; which individually move it to either side, but when both act they fix it in the extended line; this finger, therefore, requires no anterior interosseous muscle.

Fourth Posterior Interosseous, or Abductor Annularis, *arises* from the opposed sides of the fourth and fifth metacarpal bones, and is *inserted* into the ulnar side of the ring finger. *Use*, to separate this from the middle finger. No posterior interosseous muscle is inserted into the little finger, unless we regard its abductor muscle as one, its use being analogous, as it cooperates with the long abductor of the thumb, and with all the posterior interossei, in divaricating all the fingers, and thus enlarging the range of surface over which the

hand and fingers can extend. These three last interossei muscles are very similarly circumstanced, covered posteriorly by the integuments, the extensor tendons, and their connecting transverse bands, also by a fine fascia which binds them down on a plane with the metacarpal bones; they are all somewhat triangular, or prism-shaped, and their superior, or carpal extremities, are pierced by the perforating arteries from the deep palmar arch, in the same manner as the radial artery pierces that of the abductor indicis; they all arise, by double origins, from two metacarpal bones, and are inserted singly into the first phalanx of one finger, and into its extensor tendon; one origin is from the posterior lateral surface of one bone, and the other is from the entire side of the opposite; the fasciculi are penniform, and proceed very obliquely, and their tendons pass over the metacarpo-phalangal joints and then expand as they join the extensor aponeuroses. All these muscles are covered in front by the palmar tendons, vessels, and nerves.

From a review of the muscles of this region we may infer, that, as at the elbow, so at the wrist, hand, and fingers, the flexors predominate over the extensors; each of the four inner fingers possesses three flexors, the profundus perforans for the last phalanx, the sublimis perforatus for the second, the accessory, or lumbricalis, for the first; the latter may also flex the metacarpus, and the anterior interossei can assist these by pressing forwards the metacarpo-phalangal joints. The thumb has its long flexor, analogous to the profundus in the other fingers; it wants, however, the second long flexor, as it has not the middle phalanx; but it has a very strong short flexor, or accessory muscle, as also an opponens and an adductor, which cooperate with its flexors. Each of the four inner fingers has a long extensor, whose action is aided by the interossei and lumbricales; the index and little finger have also an additional extensor; and the thumb, in addition to the long abductor, or extensor of its metacarpal bone, has also an extensor for its first and for its second phalanx. The flexors have a tendency to adduct or approximate the fingers, and the anterior interossei and lumbricales can cooperate; while the extensors have a tendency slightly to abduct, and are greatly assisted in so doing by the posterior interossei. Although the thumb has no posterior interosseous muscle, yet its long abductor, arising in the posterior interosseous space in the forearm, is analogous, but superior in power; the index finger has its adductor, or anterior interosseous, and its abductor or posterior interosseous; the middle, instead of an anterior, has two posterior interossei, which can fix it and move it to either side, and therefore serves to abduct or adduct it; the ring has its anterior interosseous, or adductor, and its posterior, or abductor; and the little has the anterior interrosseous, or adductor, and its abductor, which, however, cannot be called an interosseous muscle.

In the dissection of the forearm and hand we meet with the branches of the brachial artery, with their accompanying veins; also branches of the brachial plexus of nerves: the cutaneous veins have

been already noticed. The brachial artery, when it arrives at the bend of the elbow, divides into its radial and ulnar branches. The *radial artery* descends from the elbow obliquely outwards, to the styloid process of the radius, passes over the outer side of the carpus, and then between the metacarpal bones of the thumb and of the forefinger, where it divides into three branches, radialis indicis, magna pollicis, and palmaris profunda: the radial artery at first lies between the pronator teres and supinator longus; afterwards between the supinator and flexor carpi radialis; it then winds round the carpus, over the external lateral ligament, and beneath the extensor tendons of the thumb; in the forearm it is only overlapped above by the supinator longus; in the rest of its course it is superficial; it is accompanied by two veins, and by the radial branch of the musculo-spiral nerve, which lies to its outer side. The radial artery gives off, first, the recurrent branch, which ascends in front of the external condyle, to supply the muscles attached there, and to inosculate with the superior profunda; second, in its course down the forearm, several muscular branches; third, near the wrist, the superficialis volæ, which passes to the small muscles of the thumb, and communicates with the superficial palmar artery; fourth and fifth, branches to the fore and back part of the carpus: and between the thumb and index finger it divides into its three last branches; the magna pollicis subdivides, and supplies the sides of the thumb; the radialis indicis, in like manner, supplies the forefinger; and the palmaris profunda passes beneath all the flexor tendons across the four metacarpal bones, forms the deep palmar arch, and then joins a branch from the ulnar artery. The *ulnar artery* is larger than the radial; it descends obliquely inwards, beneath the superficial flexors and pronators, and lies on the flexor profundus; it passes over the annular ligament into the palm of the hand, and there divides into a superficial and deep branch: this vessel is covered also by several muscles, inferiorly it is superficial, and lies between the tendons of the flexor sublimis and flexor carpi ulnaris; it is attended by its two veins, and in the inferior two-thirds of the forearm by the ulnar nerve, which always lies to its ulnar side; near the wrist this nerve is somewhat behind the artery. The ulnar artery sends off, first and second, its recurrent branches; the anterior, small, ascends in front of the internal condyle; the posterior, large, passes behind that condyle and joins the inferior profunda; third, the interosseous artery, which passing backwards, divides into its posterior and anterior branch; the posterior passes through the upper part of the interosseous space, and ascends in the substance of the anconæus; the anterior interosseous descends between and beneath the flexor profundus and flexor pollicis, as far as the pronator quadratus, which it supplies, and is then lost on the carpus; fourth, muscular branches; fifth and sixth, to the back and front of the carpus; and in the palm of the hand it terminates in the deep and superficial branch; the former sinks between the muscles of the little finger, to join the deep palmar arch; the superficial runs across

the flexor tendons, forming the superficial arch, from the convex side of which, the long digital arteries arise; these supply the three inner fingers.—See *Vascular System.*

In addition to the cutaneous nerves already noticed, we find the median, ulnar, and musculo-spiral descending in the forearm; the *median nerve* passes between the heads of the pronator teres, and descends beneath the flexor sublimis, giving off the anterior interosseous nerve, and branches to the muscles of the forearm; it passes beneath the annular ligament, appears superficial in the palm of the hand near the thumb, and sends off digital branches, which accompany the digital arteries to all the fingers, except the little and the ulnar side of the ring finger. The *ulnar nerve* winds round behind the internal condyle, between the heads of the flexor carpi ulnaris, and descends along the internal side of the ulnar artery to the hand, where it terminates, by dividing into a small superficial and a large deep branch. The *musculo-spiral* or *radial nerve*, is seen beneath the supinator longus, descending along the outer side of the radial artery, and supplying the adjacent muscles; near the elbow it gives off the posterior interosseous nerve, and a little below the middle of the forearm it passes beneath the tendon of the supinator, and becomes cutaneous, being distributed to the integuments of the thumb and back of the hand.—See *Anatomy of the Nervous System.*

# CHAPTER VI.

## DISSECTION OF THE ABDOMEN.

## SECTION I.

### OF THE MUSCLES ON THE ANTERIOR AND LATERAL PARTS OF THE ABDOMEN.

The structures which compose the abdominal parietes, anteriorly and laterally, are the integuments, superficial fascia, muscles and tendons, a subjacent fibrous expansion, and a serous membrane; nutrient vessels and nerves ramify in and between these several laminæ; the integument is soft and smooth, but variable; in women who have borne children it is found wrinkled, and the cuticle is marked in a peculiar reticular manner.

Divide the integuments from the sternum to the pelvis, from the crest of each ilium to the umbilicus, also from this point upwards and outwards on either side over the cartilages of the ninth and tenth ribs, as high as midway between the axilla and the border of the thorax; dissect off the flaps; the subcutaneous cellular membrane will be found dense and strong, so as to have received the name of superficial fascia; this may be removed, along with the integuments, from the superior and lateral parts of the abdomen, but inferiorly and anteriorly it may be suffered to remain for further examination, a knowledge of its structure and connexions being of practical importance in the disease of hernia. The *superficial fascia* is continued from the surface of the thorax, over the abdominal muscles; weak and thin above, it increases in density as it descends; from the abdomen it extends on either side over Poupart's ligament to the thigh, which it invests, and in the centre over the organs of generation; in the male a process of it passes round the spermatic cord on each side, descends into the scrotum, and is continuous with the fascia of the perinæum, and from the linea alba a thick portion runs to the dorsum of the penis, invests this organ, and serves as its superficial suspensory ligament and sheath; the processes which enclose the testes are distinct and separate, and by their contact form the septum scroti. In the female it is loaded with fat in this situation, and descends into the labia, but these prolongations of the fascia in the male are always free from adipose deposit. As this fascia passes over Poupart's ligament, it is connected to it, through the medium of a thin, transparent, but strong

membrane, which ascends from the fascia lata of the thigh, and is soon lost on the abdominal muscles; to this the superficial fascia is attached, so as to give the latter the appearance of adhering to Poupart's ligament, although it really is not so. This structure is sometimes called Scarpa's fascia, as that writer has described it under the name of the "Aponeurosis of the fascia lata;" we shall call it the deep fascia of the abdominal muscles; it is always present, though very unequally developed in different subjects; some of the inguinal glands separate this from the superficial fascia, so also does a femoral hernia, in its ascent on the surface of the abdomen; though generally very thin, it imparts much strength and resistance to the tendon of the external oblique, as it adheres intimately to its fibres; this fascia is also continued, as a very delicate lamina, over the spermatic cord, into the scrotum, this accounts for the fact, that when urinary effusions extend from the perinæum over the abdomen, they do not pass towards the thigh, as this membrane forms a septum between it and the abdomen. About an inch below Poupart's ligament, in the groin, the superficial adheres intimately to the fascia lata; in this situation the former is very thick and laminated, forming capsules for the inguinal lymphatic glands, and is connected to the fascia lata by vessels and nerves which perforate the latter in their course to and from these glands, the superficial fascia, and integuments; the fascia lata here also is very weak, and rather cellular, so that the superficial and deep fasciæ are continuous or identified in this situation; soon afterwards, however, they again become distinct. The superficial fascia is thinner along the sides than it is on the forepart of the abdomen; its cutaneous surface is cellular, and closely connected to the integuments, particularly in the median line; its posterior surface is more compact and smooth, and often appears to contain some elastic tissue, particularly about the lower part of the linea alba, not unlike the yellow fibrous expansion which covers the abdomen of large quadrupeds; several blood-vessels ramify between the skin and this membrane, three set on each side, viz., the external circumflex ilii, external epigastric, and external pudic arteries; these all arise in the groin, from the femoral artery, or from some of its branches, and ascend over Poupart's ligament; the first ramifies towards the anterior spinous process of the ilium; the second, which is the largest of the three, ascends towards the umbilicus; and the third passes transversely towards the pubis; these several arteries supply the integuments, and inosculate with the deep-seated vessels of the same name; they are each accompanied by one or two veins, which are often found remarkably tortuous in pregnancy or in ascites, and should be avoided in the operation of paracentesis of the abdomen; these superficial veins open into the saphena or femoral vein, below Poupart's ligament. The superficial fascia supports and connects the fleshy and tendinous fasciculi of the abdominal muscles; it also possesses some power of resistance and a good deal of elasticity, which assists these muscles in the contraction of the parietes of the abdomen; the superficial is sometimes called "Camper's fascia." Remove the integuments and fasciæ from the surface of the

abdominal muscles, and continue the dissection as far back as within two or three inches of the spine. The dissection of these muscles requires much care and attention; many of them are very thin, and in such close apposition, that the unpractised hand may have some difficulty in raising their successive laminæ; some portions of these muscles also are often very indistinctly marked, particularly if the abdomen have been long distended by dropsy, or in very weak, emaciated, or anasarcous subjects. In dissecting the external oblique muscle at its upper and anterior part, care must be taken not to raise its aponeurosis or tendon, which is so thin, as it passes over the anterior part of the thorax, that it may be mistaken for condensed cellular membrane. In order to expose the external oblique muscle, make its fibres tense by putting a block under the loins, and dissect in a line nearly parallel to its fibres; they are covered by a fine, closely-adhering, cellular coat, difficult to remove, if not already detached with the superficial fascia; to clean the posterior portion, the subject should be turned a little to the opposite side.

The abdominal muscles are ten, or five pair, viz., obliqui externi, and interni, transversales, recti, and pyramidales; the last are often wanting. Other muscles, however, are equally entitled to be called abdominal, viz., the diaphragm and the levator ani, quadratus lumborum, psoas, and iliacus. These belong to the class of flat muscles, like the latissimus dorsi and serrati, the diaphragm and the levator ani; they are placed in three laminæ, one beneath the other, and it is important to observe that the fibres of one layer decussate those of the other two; thus those of the external oblique descend obliquely forwards, those of the internal ascend obliquely forwards, and those of the transversales are circular, while in front those of the recti are vertical, and resemble longitudinal pillars opposed to the spine; the three lateral muscular layers are closely connected together by short cellular tissue, with very little adeps, and their tendinous expansions anteriorly are perfectly interlaced; thus a very compact and resisting tissue is constructed out of thin and weak materials; the fleshy fibres, though not actually interwoven, yet in effect resemble a platted texture which prevents their divarication, and the consequent protrusion or hernia of any of the enclosed viscera. If the finger be introduced through an opening made in the side of the abdomen, even where the integuments have been removed, and an effort made to protrude it through the parietes, the resistance will be found very considerable, and such as, during life, must be fully competent to prevent a separation of the fibres from any natural cause; accordingly hernia occurs only in those situations where a natural weakness or deficiency exists, except in very rare instances, where the parietes have been injured by wound or disease, or much debilitated by long distention and absorption of all adipose substance from the tendinous interstices; hence this laminated and decussating arrangement is vastly superior to a simple circular muscle, the parallel fibres of which would be much more easy of separation, unless it possessed considerable thickness, which, how-

ever, would have been not only inconvenient but even inferior to the present plan in power and variety of action; the several laminæ are now enabled to effect, not only a general and equable compression of

*Fig.* 36.*

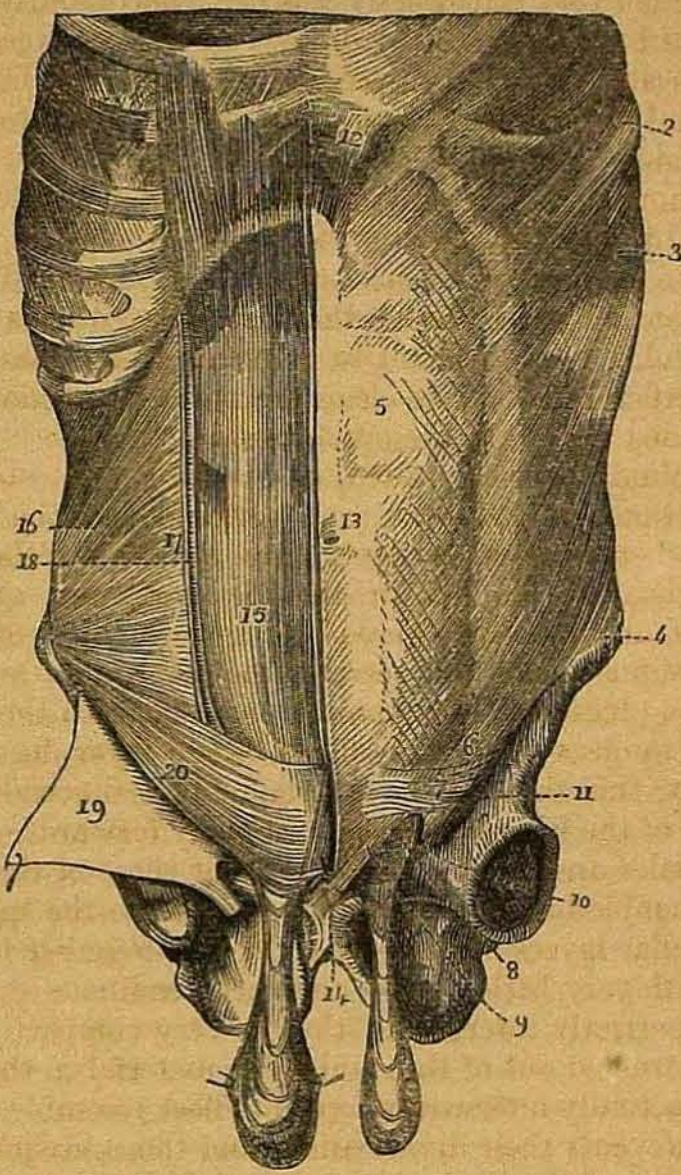


* The muscles of the anterior aspect of the abdomen; on the left side the superficial layer is seen, and on the right the deeper layer. 1. The inferior portion of the pectoralis major muscle. 2. The inferior indigitations of the serratus magnus muscle. 3. The external oblique muscle. 4. The anterior part of the crest of the ilium. 5. The aponeurosis of the external oblique passing in front of the rectus abdominis muscle. 6. The inferior border of the aponeurosis of the external oblique, forming what is termed the crural arch. 7. The intercolumnar bands. 8. The external abdominal ring. 9. The superior and internal pillar of the ring. 10. Gimbernaut's ligament. 11. Space beneath the crural arch or Poupart's ligament, through which pass muscles, vessels, and nerves. 12. The xiphoid cartilage. 13. The umbilicus. 14. The pyramidalis muscle. 15. The rectus muscle. 16. The internal oblique muscle. 17. The anterior layer of the tendon of the internal oblique, which passed in front of the rectus muscle, cut away close to its origin. 18. The posterior layer of the same tendon passing behind the rectus muscle. 19. The internal surface of the aponeurosis of the external oblique thrown downwards. 20. The inferior fibres of the internal oblique.

the abdomen, but can also assist in a variety of most useful motions of the body with considerable effect. The fibres of some laminæ being oblique, and, therefore, longer than if they were circular, possess a greater degree of contractile force; and as the fibres of one lamina have an origin, course, and insertion different from those of another, and as they can act either independently or in conjunction with the muscles on the same side, or with those on the opposite, which correspond in direction, and as both of these again may cooperate with, or antagonize other laminæ, and may act or rest reciprocally, a composition of forces is thus gained, from which must proceed an endless variety of results; thus, while all concur in compressing the abdomen, the transversi and recti do so more directly; in expiration, in like manner, though all are concerned and press the viscera upwards and backwards, against the diaphragm, yet the obliqui are most efficient, as they also depress and adduct the ribs; and again, while the entire group strengthen and support this division of the body, whose only fixed basis is the lumbar spine, some can especially steady and balance it laterally, others bend it forwards, or to either side, and others, by rotating the lumbar vertebræ, can move the whole body, as well as the pelvis and lower limbs, in almost all directions, so that no group of muscles can assist in a greater variety of purposes than those of the abdomen, although their name and their connexion with this cavity, may give rise to the impression, that their chief office is to assist in its functions, yet, most probably, this is but their secondary use, it is rather as locomotive agents, as pelvi-thoracic muscles, they claim most attention; in ordinary expiration, little more than their elasticity is required, though occasionally their full contractile power is called forth; so in the function of the abdominal organs, the transverse or circular lamina, which has some resemblance to the involuntary muscles, is most influential, yet in occasional efforts, such as vomiting, defæcation, and parturition, they all contribute to compress the viscera, and to contract the cavity. The abdominal parietes will be found chiefly tendinous posteriorly and anteriorly, and fleshy on either side; the anterior region is the most extensive, and the tendinous and fleshy strata which bind it are so arranged and proportioned, as to secure, to a certain extent, an equal degree of support, resistance, and contraction throughout, thus the external oblique is tendinous below, and fleshy above, the internal is tendinous above and fleshy below, and the transverse is fleshy above and below, and tendinous in the centre; the student may again peruse these preliminary observations after the dissection of these muscles.

Obliquus Externus, or Descendens, broad, thin, and somewhat square, extends over the anterior and lateral parts of the abdomen, fleshy above and behind, tendinous before and below: some describe (unnecessarily in my opinion) the tendons of the oblique and transverse muscles as a distinct structure, and name it "anterior abdominal aponeurosis," as opposed to the posterior or lumbar, and composed of three, or, more accurately, of four laminæ; it *arises* by eight or nine

triangular fleshy slips (sometimes there are only seven) from the lower edges and external surface of the eight or nine inferior ribs, at a little distance from their cartilages; the five superior indigitate with corresponding portions of the serratus magnus; and the three inferior with those of the latissimus dorsi, by which they are a little overlapped; this serrated origin is in the form of a long curved line, the concavity upwards and backwards. The superior fibres are thin, aponeurotic, and weak, and pass horizontally inwards; a tendinous and fleshy slip often connects this portion to the great pectoral muscle; the middle are the longest, and descend obliquely forwards and inwards in the same line as the external intercostals; the posterior are strong and fleshy, and descend almost vertically; the superior and middle fibres end in a broad tendon, which commences at a little distance external to the linea semilunaris; the outer border of this tendon extends in an irregularly concave line from the cartilage of the eighth rib, to the anterior superior spine of the ilium; this line is external and differently curved to the linea semilunaris; the tendon is continued over the forepart of the abdomen, covers the rectus muscle, and is so broad inferiorly as, when taken with its fellow, to extend from one spine of the ilium to that of the opposite side; it is very strong inferiorly, but so very thin above, where it covers the thoracic portion of the rectus, that the inexperienced dissector often removes it along with the integument. The external oblique is *inserted* tendinous into the ensiform cartilage, linea alba, pubis, Poupart's ligament (which is formed by a thickening and reflection or folding back of the lower fibres of this tendon), and into the anterior superior spinous process of the ilium, also tendinous and fleshy into the outer edge of the two anterior thirds of the crest of the ilium. *Use*, to depress and adduct the ribs, and compress the abdominal viscera, so as to assist in expiration, and in the evacuation of the urine and fæces. When both muscles act, they can bend the trunk forwards; if one only act, it will bend it to that side, and it may also rotate it to the opposite side; if the thorax be the fixed point, they can bend forwards and upwards the pelvis, and each can rotate it towards its own side. This muscle is covered by the skin and superficial fascia, its posterior border is sometimes overlapped by the latissimus dorsi; in some cases, however, these muscles do not meet, and a small part of the internal oblique is seen in the triangular space between them; in this space a lumbar hernia has been known to have occurred; in some forms of lumbar abscess, also, I have found the tumour to bulge towards the surface in this interval, which was then enlarged. On the dissected tendons of this pair of muscles, we may remark the following particulars: the linea alba and umbilicus, lineæ semilunares, lineæ transversæ, the external abdominal or inguinal rings, and Poupart's ligament on each side. The *linea alba* is a dense ligamentous cord, extending from the ensiform cartilage to the upper part of the symphisis pubis; it is formed by the intimate union and crossing of the tendinous fibres of the two oblique and transverse muscles of opposite sides; inferiorly, however, the fibres of the oppo-

site tendons only cross to be inserted into the opposite pubis, but do not unite or interlace; its greatest breadth and thickness are at the umbilicus, from this to the pubis it decreases; its superior portion is much broader than its inferior; as the recti muscles are there so close together, it is reduced to a mere line, whereas above, particularly in corpulent persons, it is often half an inch broad; in its infra-umbilical portion, where the decussating fibres of the tendons are less distinct, there is also a long, narrow, fibrous cord, which commences gradually a little below the umbilicus, and extends to the ligamentous covering of the pubes; in very thin subjects this projecting cord can often be seen and felt through the skin; as the linea alba is so narrow below, the abdomen is stronger in the middle region than above; resistance and contraction being there more necessary, and here, therefore, hernia never occurs; the integuments are more closely connected to this line, than they are at either side; hence the more fat the subject, the more indented will the skin appear along it. About the centre of the linea alba, or a little below it, is the *umbilicus;* this, in the fœtus, was a foramen, through which were transmitted the umbilical vein from the mother, and the umbilical arteries and the urachus from the child; before the integuments were removed, this spot appeared depressed, particularly if the subject have been very fat; it now projects, and seems formed of dense, cicatrized, cellular tissue, surrounded by, and connected to the adjacent tendinous fibres, and plugged up by the ligamentous remains of the three blood-vessels which diverge from its posterior surface. Umbilical hernia occurs in the infant through this opening, but in the adult in its immediate vicinity; posteriorly the peritoneum is in contact with the linea alba above, but below, the urachus, and occasionally the urinary bladder intervene. Several small openings exist in this line, through which bloodvessels pass and fatty masses protrude, and sometimes a small pouch of peritoneum; the linea alba is increased in breadth, and becomes proportionately weak when the abdomen has long suffered distention from any cause.

The linea alba is regarded by some as the continuation of the sternum, which, in some animals, is extended to the pubes; it serves as a fixed point for the oblique and transverse muscles on either side, also as a resisting, but not an elastic ligament, to connect the thorax to the pelvis, and to support the former when bending the trunk backwards, so as to resist or prevent too forcible extension of the spine. In the inferior part of this line the following operations may be performed: puncturing the bladder in retention of urine; paracentesis, or tapping of the abdomen, in ascites; and the high operation for lithotomy.

The inferior fourth or fifth part of the linea alba is sometimes deficient, as also a portion of the muscles on each side, so that the urinary bladder is superficial, and constantly exposed; in such cases the anterior part of this viscus also is wanting, and therefore its cavity and the orifices of the ureters can be perceived during life.

The *lineæ semilunares* extend from the tuberosity of the pubis on

each side upwards and outwards, about four inches from the linea alba, towards the cartilages of the eighth and ninth ribs; they appear white, and somewhat depressed, and are formed by the tendons of the internal oblique, dividing at the edge of each rectus into two layers, to enclose this muscle in a sort of sheath; the space enclosed between these two lines is oval, the larger end above; it contains the two recti and the linea alba. In the living subject this line may be traced by taking a point midway between the umbilicus and the anterior superior spinous process of the ilium, and from it drawing one line towards the tuberosity, or spine of the pubis, and another towards the cartilage of the ninth rib. The operation of tapping ovarian dropsy should always be performed in this line; and this situation is also selected by some as the best for performing paracentesis in cases of ascites. In this last-mentioned disease, however, this line is not exactly midway between the umbilicus and spine of the ilium, but half an inch nearer the latter, as the recti become flattened and expanded laterally.

The *lineæ transversæ* are three or four on each side, they cross the rectus muscle from the linea alba to the linea semilunaris; they are tendinous intersections of that muscle, particularly of its anterior part, which adhere so intimately to its sheath, as to give to the latter this indented appearance. They are much better marked in some than in others; during life they are very distinct, when the abdominal muscles are in strong action; one of these corresponds to the umbilicus, another to the ensiform cartilage, the third is midway between these; if a fourth or fifth exist, they are inferior to the umbilicus and but feebly marked. These lines will be again noticed in the dissection of the rectus. Between the linea alba and semilunaris on each side many small holes are often to be observed in the tendon of the external oblique, these are only for the transmission of small vessels and nerves, are generally of a square form, and are much larger and more numerous in some than in others; the fasciculi of the tendon also occasionally separate in a very variable manner, leaving triangular spaces between them, and in many situations they are intersected at various angles by other tendinous fibres.

The *external inguinal*, or *abdominal ring*, also named *by some anterior*, and by others, *inferior*, transmitting, in the male, the spermatic cord and cremaster muscle, with its vessels and nerves, and in the female the round ligament of the uterus, is situated external and superior to the pubis on either side. This opening is of an oval or triangular form, the base is inferior and internal at the pubis, the apex is superior and external in the tendon, and formed by the separation of its fibres; the sides are called the pillars of the ring, one of which is superior, internal, and anterior; the other, or Poupart's ligament, is inferior, external, and posterior. The first, or superior pillar, is broad, and inserted into the symphysis and into the opposite pubis; some fibres are continuous with the fascia lata of the opposite thigh; this pillar decussates with that of the opposite side, on the forepart of the pubis, and both send fibres to the dorsum of the penis; the

inferior pillar is the internal or pubic end of Poupart's ligament; the dimensions of this opening (improperly called a ring) are very variable, transversely they are about half an inch, and from an inch to an inch and a half from within and from below, upwards and outwards; it is larger in the male than in the female. The apex of this opening is rounded by a series of fibres, which serve to connect the pillars to each other. These fibres arise from Poupart's ligament at a little distance from the spine of the ilium, pass in curved lines upwards and inwards across the upper part of the ring, and are lost superiorly on the surface of the tendon; they serve, by preventing the separation of the sides of the ring, to protect this part of the abdomen against a protrusion of its contents; the same order of fibres continue their attachments to the margins of the opening, and are prolonged inferiorly as a fine membrane on the spermatic cord; in cases of long existing hernia this fascia becomes much developed, and forms one of the coverings of the sac, and is found closely connected to the subjacent cremaster muscle. Anatomists have given to the whole of this structure the appropriate name of *intercolumnar fascia;* some, however, divide it into two, and name the superior fasciculated portion, "intercolumnar bands, or fascia," and the inferior membranous portion, "spermatic, or cremaster fascia;" as, however, these two are so connected, and so allied in their use, we shall consider both as the intercolumnar fascia, only observing, that the superior portion is more distinctly tendinous and fasciculated, and the inferior more membranous; if we separate this structure from the tendon and from the margins of the ring, commencing above, we can demonstrate the whole as one continuous tissue extended indefinitely along the cord. It is this fascia, or these intercolumnal bands, that obscure this opening in many cases, and deprive it of that defined figure usually mentioned by writers, or delineated in plates. The tendon of the external oblique is alone concerned in the formation of the external abdominal ring, there being no corresponding deficiency in the internal oblique or transverse muscles; the spermatic cord, or round ligament, must therefore have taken an oblique course to arrive at this opening; this will be seen in the next stage of the dissection.

*Poupart's*, or *Fallopius' ligament*, or the *femoral*, or *crural arch*, is the inferior edge of the tendon of the external oblique, thickened and reflected upon itself from before backwards; it is very strong, and when the lower extremity is extended, and the foot and toes everted, it appears very tense, and convex downwards and outwards; it corresponds to the fold of the groin, separates, superficially, the abdomen from the thigh, and bounds anteriorly the large triangular or semilunar space, which the ilium and pubis complete posteriorly, and which space is occupied from without inwards by the iliac and psoas muscles, with the anterior crural nerve, the femoral artery and vein, internal to which are some cellular tissue, lymphatic vessels, and sometimes a lymphatic gland, also the origin of the pectinæus muscle. If we consider it as a distinct ligament, it may be described

as having an attachment to, or as *arising* from the anterior superior spinous process of the ilium, thence it at first descends obliquely, and then proceeds forwards and inwards to the pubis, into which it is *inserted* by two attachments, one anteriorly into the tuberosity or spine, and into the forepart of the bone beyond this process; the other, which consists of the reflected fibres of the tendon, is narrow at first where it is folded in under that last described, and then expands, and is inserted behind it, being continuous with it, partly into the spine, and principally into the prominent linea innominata of the pubis, or the commencement of the linea ileo-pectinea; by means of this reflection backwards of these lower fibres, a sort of groove or channel is formed, which lodges the spermatic cord, supports it below, and separates it from the thigh; the oblique tendon itself forms the front of this channel; this is named the spermatic, or inguinal channel, and will be more fully seen hereafter. The first, or iliac end of Poupart's ligament is broad and continuous above with the tendon of the oblique, and below with the fascia lata; the anterior portion of the pubal end, or the *second* insertion, is distinct and round, and can be felt through the skin; it lies behind the cord, and is connected to that portion of the fascia lata which covers the adductor muscles; the posterior pubal attachment, or the *third* insertion, also called *Gimbernaut's ligament*, is broad and thin, and lies superior, posterior, and external to the former; it may be seen by raising the cord out of the external ring, and everting Poupart's ligament a little; it is of a triangular form, the apex is anterior, at the tuberosity, or spine of the pubis; the base is external and posterior, somewhat crescentic, looking towards the femoral vessels; to it some fibres from the outer, or iliac part of the fascia lata, are attached, so as to elongate it in this direction; this third insertion of Poupart's ligament forms the internal boundary of the femoral ring, and is therefore concerned in the anatomy of femoral hernia, as will be seen hereafter. Poupart's ligament owes much of its strength to its connexion with the fascia lata of the thigh, as may be seen at present by merely flexing the limb and inverting the knee, the ligament then becomes relaxed, as also the parietes of the ring; hence this position is constantly resorted to, and often successfully, in attempting the reduction of inguinal hernia; it is this connexion to the fascia lata which gives it the arched, or curved appearance, convex towards the thigh, and which curve is straightened when the limb is bent and adducted; it is also curved in another direction, concave forwards and convex backwards towards the iliac fossa; this curvature depends on the intimate union between this ligament and the fascia iliaca and transversalis, which adds materially to the strength of this region; and as the iliac fascia is also connected to that of the thigh, the position of the latter will alter or relax this curve as well as the former; these curvatures are well marked during life in the strong and muscular man: its attachment to the fascia transversalis and iliaca will be exposed in a future stage of the dissection. Poupart's ligament is of *use* in strengthening the inferior part of the abdomen,

and affording a fixed point of attachment to the deeper muscles and to the different aponeuroses; it also protects the great femoral vessels and nerves in their passage from the abdomen to the thigh, and its third insertion partially fills up the internal portion of the crural arch. From this third insertion, and from the pubis, a band of fibres may be observed to pass upwards and inwards, behind the superior pillar of the ring, towards the linea alba; these assume in general a triangular shape, and have received the name of the *triangular ligament*, or *fascia;* the base is inferiorly at the linea ileo-pectinea; the apex is superior and internal towards the linea alba, and is continuous with the external oblique tendon of the opposite side; this fascia serves to protect the abdomen in this region; this, though delineated by others, has been first particularly described in Colles' *Surgical Anatomy*, and is therefore commonly called "*Colles' fascia;*" though described as a distinct structure, it really is only a continuation of the decussating fibres of the opposite tendons, as all through the linea alba above; in fact, each of these ligaments is but a stronger portion of the external oblique tendon of the opposite side, and might be correctly described as arising from it in the linea alba, then expanding as it descends to its insertion in the opposite ileo-pectineal ridge; it not only protects the abdomen behind the external ring, but it ties together all the surrounding textures, and confines them towards the linea alba; it may be said to connect the superior pillar of one ring with the inferior pillar of the opposite; it lies directly behind the cord, and is anterior, but inseparably united to the conjoined tendons of the internal oblique and transversalis, in front of the rectus; its development as to strength and extent is very variable, in some it is so weak as scarcely to deserve notice. Raise the external oblique, by dissecting off its serrated origins from the ribs, detach also its insertion from the crest of the ilium, and from the internal oblique muscle, cleaning at the same time the surface of the latter, throw the external oblique towards the opposite side, separating it as far forwards as its connexions will permit, that is, about half an inch internal to the linea semilunaris; divide its tendon transversely from the spine of the ilium, towards the lower third of the rectus, about an inch above the external ring, thus preserving Poupart's ligament and the external ring for further examination, in relation to the anatomy of hernia; numerous small nerves and vessels are met with in this dissection; several perforate the tendon near the linea alba, and several also pass through its fleshy costal portions. When the external oblique is raised, we see the inferior ribs, the inferior intercostal muscles, the internal oblique, and the cremaster.

Obliquus Internus, or Ascendens, is also situated at the anterior and lateral part of the abdomen, broader before than behind, and more fleshy below than above; it *arises* tendinous, but soon becomes fleshy, from the fascia lumborum, from all the crest of the ilium, and from the two external thirds of the grooved, or abdominal surface of Poupart's ligament; the fibres diverge in a radiated manner; those

from the lumbar fascia and posterior part of the ilium ascend obliquely forwards; those from the anterior part of the ilium pass transversely, and those from Poupart's ligament descend obliquely inwards; the fibres continue fleshy further forward than those of the external oblique; at the linea semilunaris they end in a flat tendon, called by some the middle layer of the anterior abdominal aponeurosis; at the edge of the rectus this divides into two layers, to enclose this muscle; the anterior is united to the tendon of the external oblique, the posterior and thinner layer is joined to the tendon of the transversalis; this does not extend so high as the anterior; it commences on a level with the cartilage of the seventh or eighth rib only, so that above this point the rectus rests on the transverse muscle, which here continues fleshy for a little way internal to the linea semilunaris; about midway between the umbilicus and the pubis, the tendon of the internal oblique does not divide, but the whole passes in front of the rectus, along with the tendon of the transversalis, to which it is closely connected; a little above the pubis these two tendons are intimately joined, and are called the *conjoined tendons.* The internal oblique is *inserted*, fleshy, into the cartilages of the four inferior ribs, the fibres meeting the internal intercostal muscles, to which they are parallel; tendinous into the ensiform cartilage, and into that of the seventh and eighth ribs, also into the whole length of the linea alba; the conjoined tendons are *inserted* into the symphisis and upper edge of the pubis, and, passing external to the rectus, are also inserted into the linea innominata, where they are connected with Gimbernaut's ligament, and inseparably joined to the fascia transversalis; while the inferior fleshy fibres pass anterior to the spermatic cord, these conjoined tendons lie posterior to it, also to the triangular ligament, and thus afford much security not only to that part of the abdomen behind the external abdominal ring, but also to the inguinal channel generally. The *use* of the internal oblique muscle is to assist the external oblique in expiration by depressing the ribs, and by compressing the abdominal viscera, also to bend the trunk forwards, or to one side; it can also rotate the trunk, but in doing so, it cooperates with the external oblique of the opposite side, with which it forms a sort of digastric muscle; this muscle is covered by the external oblique and latissimus dorsi; it lies on the transversalis muscle; some small vessels ramify between them; a small portion of the internal oblique is sometimes superficial, between the external oblique and latissimus dorsi, above the posterior part of the ilium; the lower semilunar border is variable in strength and extent, it sometimes covers the cord as low as the external ring; along this inferior border we observe the following muscle:

Cremaster, or Suspensorius Testis consists of a fasciculus of pale fleshy fibres, which *arise* from the internal surface of the external third of Poupart's ligament, and from the lower edge of the last described muscle; a few fibres also sometimes proceed from the lower edge of the transversalis muscle; it frequently, too, has a tendinous

attachment to the pubis, behind the external abdominal ring; this fourth mentioned attachment, perhaps, rather deserves the name of insertion; the fibres all pass downwards and forwards around the spermatic cord, but chiefly along its outer side, many of them in the form of arches reversed, or concave upwards; they are *inserted* into the tunica vaginalis; a few fibres are lost in the scrotum. *Use*, to support, compress, and raise the testicle and its vessels; the origin of this muscle is covered by the tendon of the external oblique, and lies on the fascia transversalis; a small but long nerve, a branch from one of the lumbar nerves, runs between its fibres; the lower part of the muscle is superficial and very pale; in cases of old hernia, the fibres of the cremaster are found greatly increased in thickness, and are often of a yellow colour; and in that form of the disease called the oblique, or common inguinal hernia, this muscle always forms one of the coverings of the sac. The cremaster is absent in the female, or at least only rudimental. This muscle is probably formed incidentally; the testis, in its descent to the scrotum, carrying before it the lower border of the internal oblique; this will account for the arched direction of some of its fasciculi; it is usually, but not always, much developed in cases of old inguinal, or scrotal hernia, also of hydrocele; if an opportunity occur for examining it in the latter, it may be sometimes found, as described by different writers, to consist of two fasciculi, *one* descending from the inside of Poupart's ligament, having arisen from it and from the internal oblique, along the external and anterior sides of the cord, as low as the tunica vaginalis testis, on the surface of which it bends upwards, and becomes the *other*, or the ascending fasciculus, which rises along the inner and posterior sides of the cord, and is inserted into the pubis by tendinous or cellular tissue; the continuity of these fasciculi is seldom satisfactorily seen; during their course along the cord they are connected by fibrous loops, or arches, concave upwards. Raise off the internal oblique from the transversalis muscle; commence above the anterior part of the crest of the ilium, where the muscles are separated by cellular membrane, and some branches of the circumflex ilii vessels, make one incision from the ilium towards the cartilage of the ninth rib, and another from the ilium towards the lower third of the linea semilunaris; carefully dissect off the posterior part of the muscle, towards the spine, and the anterior towards the rectus; this portion can be separated from the transversalis, a little beyond the linea semilunaris.

TRANSVERSALIS, somewhat square, broader anteriorly than posteriorly, *arises* tendinous from the fascia lumborum and the posterior part of the crest of the ilium, fleshy from the remaining anterior part of the crest, and from the iliac third of Poupart's ligament; it also arises tendinous from the two last ribs, and by fleshy slips from the inner side of the five succeeding; these indigitate with the origins of the diaphragm; all the fibres pass transversely forwards, except the most inferior, which are curved a little downwards; they all end in a flat tendon, which, near the linea semilunaris, joins the posterior la-

mina of the internal oblique, and is *inserted* along with it into the whole length of the linea alba, into the upper edge of the pubis, and into the linea innominata; this tendon passes behind the rectus superiorly, but inferiorly, that is, about midway between the umbilicus and the pubis the conjoined tendons pass anterior to this muscle, and are *inserted* in the manner before mentioned. The transversalis abdominis is covered by the internal and external oblique; it lies on the fascia transversalis and on the peritoneum. *Use*, to compress the abdominal viscera in the circular direction, and to assist in expiration; it can also make tense the lumbar fascia, and approximate the anterior abdominal aponeurosis to it; its fleshy fasciculi are weaker and paler than those of the obliqui; they are frequently separated by interstices, in which the peritoneum and its cellulo-fibrous covering appear; the fasciculi are connected to the latter by little slips, or pro-

*Fig. 37.**

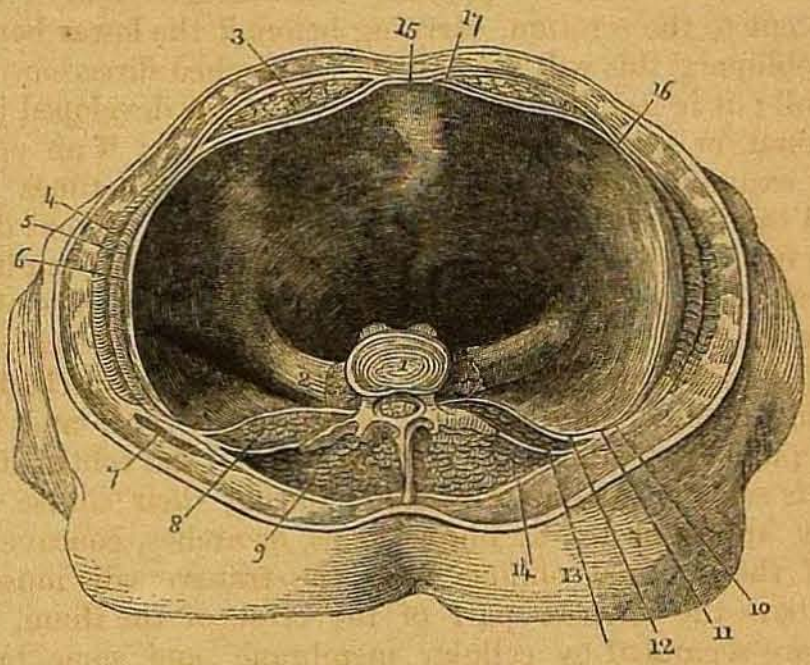


* A transverse section of the abdomen, to shew the relations of the abdominal muscles and their aponeuroses with each other, and with the neighbouring parts. 1. The upper surface of the body of the second lumbar vertebra. 2. A portion of the psoas magnus muscle. 3. A transverse section of the rectus abdominis muscle. 4. The cut edge of the external oblique muscle. 5. The internal oblique muscle. 6. The transversalis muscle. 7. The latissimus dorsi muscle. 8. The quadratus lumborum muscle. 9. The mass of muscle common to the sacro-lumbalis and longissimus dorsi muscles. 10. The aponeurosis of the internal oblique uniting itself to that of the transversalis muscle. 11. The posterior aponeurosis of the transversalis muscle dividing into three laminæ. 12. The anterior lamina of the aponeurosis of the transversalis passing in front of the quadratus lumborum to its insertion at the root of the transverse process of the vertebra. 13. The middle layer of the same aponeurosis, passing behind the quadratus lumborum and in front of the lumbar mass of muscles, to be inserted into the apex of the transverse process. 14. The posterior layer of the same aponeurosis passing behind the lumbar mass of muscles to be inserted into the extremity of the spinous process of the lumbar vertebræ. 15. The aponeurosis of the external oblique terminating in the linea alba. 16. The anterior aponeurosis of the internal oblique separating into two layers at the external border of the rectus muscle. 17. The reunion of the same layers at the linea alba.

cesses, which are very distinct, and which closely attach this muscle on each side to the lining membrane of the abdomen; it is a perfect constrictor of this cavity, and appears a sort of transition muscle between the voluntary or parietal muscles external to it, and the involuntary or visceral muscles within. This muscle is tendinous before and behind, fleshy in the middle, also above and below, contrary to the two oblique muscles; the posterior tendon is described by some, as dividing into three layers, which are, in fact, the three sheets, or leaves, of the lumbar fascia; the posterior, very strong, is continuous with the fascia lumborum; the middle, thinner and weaker, is attached to the transverse processes of the lumbar vertebræ; and is separated from the former by the lumbar muscles; and the anterior lamina, which is the weakest, is expanded over the quadratus lumborum, and the inferior part of the diaphragm, and is connected to the sides of the bodies of the lumbar vertebræ. The anterior inferior edge of the transversalis is in some degree confounded with that of the internal oblique, particularly at their origin from Poupart's ligament; its fleshy border, however, very seldom descends so low as that muscle; it crosses the cord or round ligament, just as either of these is about to pass through the internal or superior abdominal ring in the fascia transversalis; the internal oblique is on a level with the lower border of this opening, and therefore conceals it; the transversalis is parallel to its upper, and only partially covers it, and is often connected to the cord at this point, in a manner we shall consider presently. The conjoined tendons generally admit of partial separation near the pubis and behind the external ring; the tendon of the transversalis being broader and stronger than that of the oblique, its fibres may be observed to expand and curve downwards and outwards behind the cord, nearly as far as opposite the inner margin of the internal ring; this expansion is inserted, along with the oblique tendon, into Gimbernaut's ligament, and more externally into Poupart's ligament behind the cord, its transverse extent being from the rectus internally to a point externally below the internal ring; the lower muscular fibres will be found to pass obliquely inwards above and before the cord, and then bending downwards, and a little outwards, end in this tendinous expansion behind it, occasionally some fleshy fibres descend on or among the tendinous, and are inserted into the pubis or into Poupart's ligament; to the posterior surface of this tendinous expansion the fascia transversalis is intimately attached; this peculiar arrangement of the lower border of this muscle, its fleshy fibres being above and in front of the cord, and its tendinous expansion curving below and behind it, has been particularly noticed by Sir A. Cooper, in his paper on the descent of the testis; it appears designed to enable this muscle, when in action, to close or contract this opening, as also the inguinal canal, and thereby protect this part of the abdomen against protrusion of its contents. When we proceed to raise the lower fleshy border of the transversalis, we shall often find a peculiar attachment between it and the cord, as the latter is about to pass through the

internal ring; this attachment, according to Mr. Guthrie,* depends on a few fibres of the muscle passing behind the cord at this point, these then, descending inwards, join the tendon of the muscle in its course to Poupart's ligament, so that the cord actually splits the lower border of the transversalis, a small fasciculus only passing behind or between it and the fascia, and rounded so as to support it; thus a sort of transverse elliptical opening exists near the inferior border of this muscle, through which the cord passes; this posterior fasciculus is not in all cases fleshy, but only tendinous or cellulo-fibrous, connected, however, externally to the muscle, and internally to its tendinous expansion; this structure is of considerable importance, it fortifies the abdomen against hernia, and when this has occurred, it must not only exercise much influence on the tumour, but it also suggests practical hints for its treatment; this slit Mr. Guthrie proposes to call the internal abdominal ring, instead of that passage through the transverse fascia which is directly behind it; it does not, however, appear to me advisable to adopt this innovation as to name, although we may concur with much of the description. Since the publication of Mr. Guthrie's memoir, I have paid much attention to the anatomy of this part, and I freely admit that in many instances I have found his statement perfectly correct; not long since I demonstrated the cord passing through the lower border of this muscle, and surrounded by an almost perfect sphincter. I have lately also seen the same formation in a fœtus, and I have also observed the round ligament to pass through it, and to have muscular fibres prolonged upon it, which must have had the power, not only of compressing, but also of retracting this substance. I have also sometimes seen a distinct muscular fasciculus arising by a tendon from Poupart's ligament near the ilium, thence passing behind the cord to join the common insertion; and I believe that this, or some such connexion between the cord and the transversalis muscle would be more frequently detected, if we dissected the parts from within outwards, that is, first draw down the flap of the abdominal parietes, then raise off the peritoneum, and separate and examine the several laminæ of fasciæ, muscles, and tendons towards the skin. I must, however, observe, that the structure just described is by no means uniform; I have often carefully looked for it and in vain. I have, no doubt, frequently noticed a feeble cellulo-fibrous band passing behind the cord, and connected to the muscle and its tendon, by its extremities; it may have been that this band had been originally muscular, and had degenerated in course of time; in other cases this also has been wanting, and the lower border of the muscle has had no connexion whatever, direct or indirect, with the cord, and has not even descended to within an eighth of an inch of the internal ring; experience induces me to affirm, that not only is this particular structure extremely variable, but many other parts also in this region, so that the student will seldom find the appearances presented on dis-

* Guthrie on inguinal and femoral Hernia.

section to correspond exactly with the descriptions or delineations of any author, he should, therefore, make frequent examinations of this region for himself, as in that way only can he hope to obtain an accurate and satisfactory knowledge of this intricate but important subject. Replace the oblique muscles, divide their tendons along the side of the linea alba, and dissect them off the rectus towards the linea semilunaris; this anterior part of the sheath adheres so closely to the lineæ transversæ, that it is difficult to separate it from them.

Rectus, long and flat, broad and thin above, thick, strong, and narrow below, *arises* by a flat tendon, which is sometimes double, from the upper and anterior part of the pubis, between the spine and symphysis; the external tendon is the larger; it also sometimes receives fibres from the linea alba, which decussate with the opposite; the size and extent of its origin depend on the presence or absence of the pyramidal muscles; it *ascends* parallel to its fellow, becomes broad but thin above the umbilicus, and is *inserted* into the anterior part of the thorax by three fasciculi, the internal one of which is fixed to the cartilage of the seventh rib, and costo-xiphoid ligament; the middle, longer and thinner, to the cartilage of the sixth rib, and the external, still broader and thinner, to the cartilage of the fifth rib; occasionally a small fasciculus is attached to the ensiform cartilage, and it is by no means uncommon to find a slip continued into the great pectoral, more rarely this passes over it, and extends to the clavicle, or to the clavicular portion of the sterno-mastoid muscle. *Use*, to bend the chest towards the pelvis, or to raise the latter towards the chest, also to compress the abdomen. The rectus is covered superiorly by the great pectoral, in the middle by the tendon of the external, and the anterior layer of that of the internal oblique muscle, and inferiorly by the external oblique, and the conjoined tendons of the internal oblique and transversalis, also by the pyramidalis; the fascia transversalis is closely attached to the outer edge of its inferior portion. These muscles are much nearer to each other below than above; they are each enclosed in a distinct sheath, which consists, anteriorly, of the tendon of the external oblique, and the anterior lamina of the internal oblique, posteriorly of the posterior layer of the internal oblique, and the tendon of the transversalis. The *sheath* commences at the edge of the thorax, and terminates midway between the umbilicus and the pubis; below which all the tendons pass anterior to this muscle. If this part of the rectus be divided, the deficiency in the back of the sheath will be obvious, as it generally terminates abruptly by a lunated edge; in some cases, however, it ends gradually in a thin tendinous expansion; the epigastric vessels ascend within this sheath, on the posterior surface of the muscle; the posterior wall of the sheath is also deficient superiorly on the thorax; the internal mammary vessels enter it above its superior posterior border, as the epigastric do below its inferior. The sheath of the rectus serves to confine this muscle in its proper place, and to prevent it, when contracted, from injuring the abdominal viscera immediately behind it; it also strengthens the parietes of the

abdomen, and prevents the more frequent occurrence of hernia; the deficiency in the back part of the sheath below may permit the abdominal muscles to exert more direct influence on the uterus, also on the urinary bladder when distended. In wounds of the parietes in this situation, with protrusion of the intestines or omenta, we should take care, in returning them into the cavity, that they do not slip into this sheath behind the muscle; the finger should, therefore, follow the last portion, and by moving it laterally, the true course will be easily ascertained. The rectus is intersected by three or four irregular, or zigzag, transverse, tendinous lines; one of these *lineæ transversæ* is always to be found opposite the umbilicus, a second midway between this and the xiphoid cartilage, opposite to which a third is always placed; if a fourth exist, it will be found below the umbilicus; these intersections are not complete; they are generally deficient on the back part of the muscle, hence the posterior fasciculi are longer than the anterior; the anterior part of the sheath, and the linea alba, adhere intimately to each of them; by means of these lines the rectus is constituted a sort of poligastric muscle; the fibres of the first muscle arising from the anterior surface of the thorax, and inserted into the first intersection, or linea transversa; the second arising from this point, is inserted into the second intersection, and so on in succession; although the posterior fibres are not thus regularly interrupted, yet they do not continue the entire length of the muscle; some of the anterior fibres also occasionally pass over one intersection without being entangled in it; this structure enables the rectus to act in distinct or separate portions, so as to compress different parts of the abdomen in succession, each section having a distinct nerve; it also imparts considerable strength and resistance to the anterior abdominal aponeurosis, and to the linea alba, while, moreover, it associates in a most important manner, the recti with the lateral muscles, so as to enable them, not only to cooperate, but reciprocally to balance and moderate each other; when the recti contract, the viscera are pushed backwards and pressed out laterally, the obliqui then support and compress them; and when the latter act, and the viscera are thereby protruded forwards, the recti in their turn resist and support them, and one object of the interruptions in these muscles would appear to be, to enable the recti to act the better as moderators of particular sections of the obliqui, and *vice versa* in respect to the latter upon the former; by means too of this association or connexion between the lateral muscles and these transverse partitions, the influence of the recti and obliqui must be greatly and remotely extended; were the recti merely attached to the sternum and pubis, they could only compress the viscera and approximate their own attachments by flexing the spine, but as the internal oblique are intimately united to their tendinous sheaths and intersections, the recti can now act through these oblique muscles on the whole of the anterior and lateral margins of the pelvis; this apparently complex structure then in the recti, is clearly of essential service in the functions of all the abdominal muscles.

Meckel maintains that these intersections are "incontestibly" but incomplete repetitions of ribs in the abdominal walls, as the linea alba is analogous to the prolonged sternum of the crocodile, and the two oblique muscles to the two laminæ of intercostals, and the transversales to the triangulares sterni. The doctrine of analogy is, no doubt, highly interesting, and often most useful as being explanatory, but when a special structure exists for an obvious special purpose, there appears but little advantage in resorting to it. Anterior to the origin of the rectus is the following small muscle.

PYRAMIDALIS is sometimes absent, it *arises* broad and fleshy from the symphysis pubis, and from the upper edge of the bone external to it; the internal fibres ascend vertically, the external obliquely inwards, and are *inserted* narrow and tendinous into the linea alba, midway between the umbilicus and pubis. *Use*, it assists the rectus, and makes tense the linea alba; it is covered by the tendon of the external oblique, by the triangular ligament, and the conjoined tendons; it appears in some cases to be enclosed in a splitting of the latter; bony processes or ridges sometimes rise from the upper border of the pubes, in the line of these muscles, denoting a remote analogy to the supra-pubal bones and muscles in the marsupiata.

The group of muscles now described belongs to the class of voluntary muscles, with certain peculiarities; as locomotive agents, the will can excite and control them on both sides together, or on either singly; also in the acts of expiration and vomiting, defæcation and parturition, the will can influence them, although in each of these they occasionally act without even the consciousness of the individual, and thus afford remarkable examples of sympathy with different organs, the lungs and larynx, the stomach and intestines, the uterus and the bladder, sympathies which cannot be explained by any direct nervous communication, and must, therefore, depend on the excito-motor power of the nervous system. The combined actions of these muscles must be to diminish the cavity and to compress the viscera of the abdomen; in painful conditions of the peritoneum or its contents, we perceive the efforts that are made to keep these muscles in a relaxed state by bending the thighs, and approximating the pubes to the sternum, in this position. I think I have sometimes observed that a gentle action of the recti was maintained, as if to bear off all anterior weight or pressure from the tender parts within. By the simultaneous action of these muscles, the viscera are pressed backwards against the unyielding spine, upwards against the diaphragm which is thereby raised in an arched manner on either side, where it chiefly admits of this change, against the lungs, from which the air is expelled, and expiration occurs; also downwards into the pelvis, thereby pressing against the levator ani (the counterpart of the diaphragm), this then protrudes towards the perinæum, which becomes somewhat convex, and if the sphincters now assent, defæcation will result; thus the transverse and antero-posterior diameters are lessened, while the vertical axis of the abdomen is increased, and, if the contraction be mo-

derate, the parts within suffer but little compression; should the diaphragm, however, and levator ani contract at the same time, as they always do when any violent muscular effort or strain is made, then the cavity is contracted in all directions, the viscera are subjected to strong and general compression, and then it is that some weak spot in the parietes gives way, and a hernia protrudes: the surgical anatomy of the parts concerned in this disease shall next engage our attention.

Dissect off the transversalis muscle in a direction from the ilium towards the linea semilunaris, and the *fascia transversalis* will be exposed covering the peritonæum ; this fascia is connected on either side to the internal lip of the ilium and to the whole length of Poupart's ligament, as far as the pubis ; thence it extends all over the abdomen, lining the transverse muscle, covering the peritoneum, and presenting different appearances and degrees of strength in different situations, aponeurotic in some, cellular in others. It consists, at least inferiorly, of two laminæ; the external or superficial is fibrous, and distinct, and strong in each inguinal region; it lines the muscle and is closely united to its fasciculi ; this is the true fascia transversalis: the epigastric vessels intervene between it and the deep, or cellular layer, which is attached to the peritoneum, and is, in fact, its subserous tissue; in the superior and lateral regions of the abdomen the fibrous tissue is scarcely discernible, and the whole fascia appears little more than fine connecting cellular tissue; but in each inguinal region the fibrous layer is distinctly aponeurotic, and the deep cellular layer, or tissue, is thick and abundant, allowing the peritoneum to be freely separated from the iliac and inguinal fossæ, filling up the angular insterstices behind Poupart's ligament, also partially closing the femoral ring, and then extending into the pelvis. It is not, perhaps, critically correct to consider the subserous tissue as a layer of transverse fascia, although it may be convenient to do so in anatomical description; this cellular lamina cannot be seen at present, but will be again alluded to in connexion with the crural arch and femoral hernia: from Poupart's and Gimbernaut's ligament the fascia transversalis is prolonged upwards, even to the diaphragm, with the cellular coating of which it is continuous; externally, to the psoas muscle and to the spine, internally to the rectus; to the border of which it adheres so closely as to appear to end abruptly; a thin lamina, however, extends behind to join that from the other side; immediately above the pubis this close connexion to the edge of the rectus is very marked; it here also plainly separates into two laminæ, one, strong and tense, adheres to the outer and anterior border of the muscle; the other, thin and weak, passes posterior to it: between the pubis and the crest of the ilium, and for about an inch and a half above the crural arch, this fascia is generally aponeurotic and firm, and claims particular attention; immediately external to the rectus it is inserted into the linea innominata of the pubis in common with Gimbernaut's ligament, but on a plane posterior to it; tracing it outwards we observe it advancing

a little forwards, and attached to the inner border of Poupart's ligament through its whole length, as far as the spine of the ilium, and beyond this to the crest of that bone; its connexion to the ligament appears very intimate, and accounts for some writers describing the fascia, as "arising from the reflected border of the crural arch;" this is not critically correct, for dissection will shew a portion of it descending into the thigh behind this arch, through a space about two

*Fig. 38.**

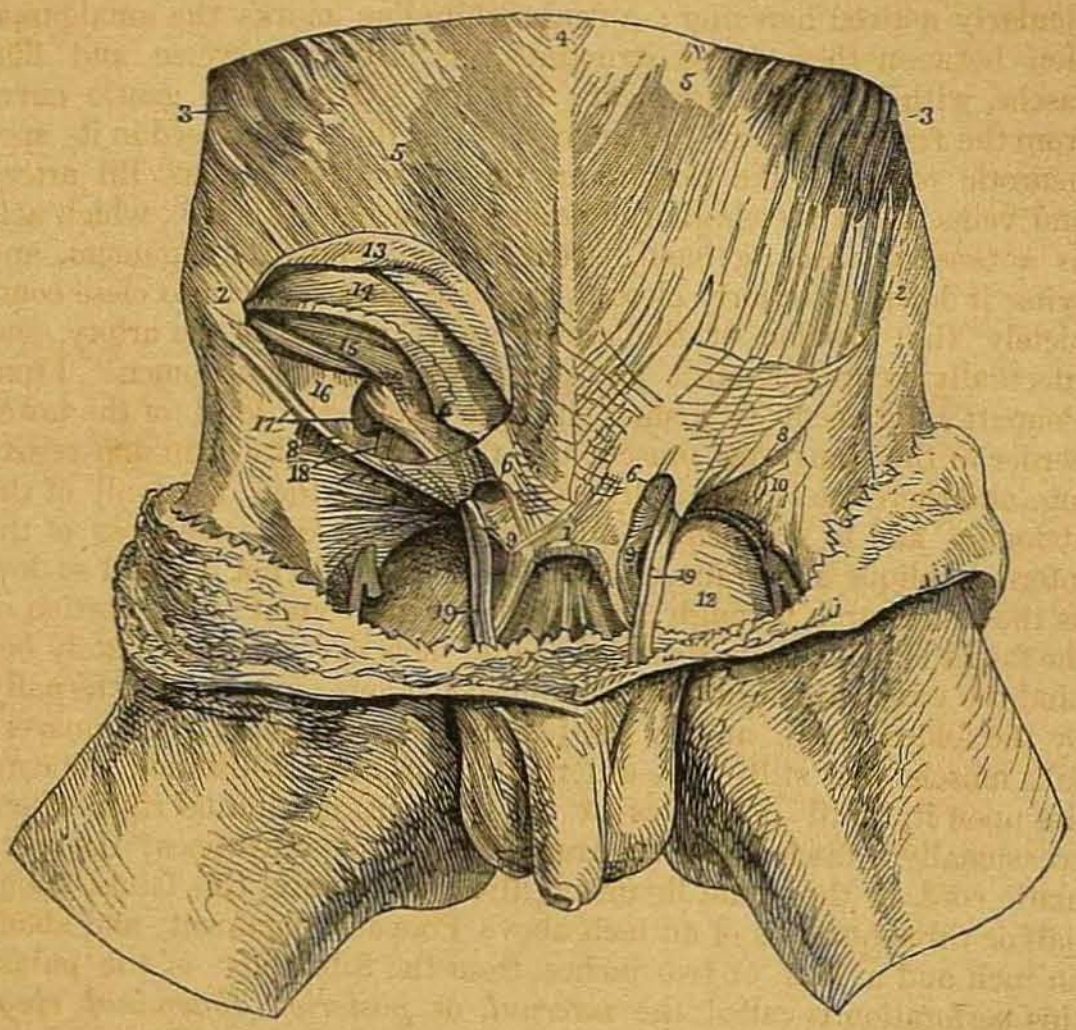

* The inguinal region in the male. 1. The symphysis pubis. 2. The anterior superior spinous process of the ilium. 3. 3. The external oblique muscles. 4. The linea alba. 5. 5. The linea semilunaris. 6. 6. The external abdominal rings. 7. The origin of the intercolumnar fibres. 8. Poupart's ligament extending from 2. to 9. The lower pillar of the abdominal ring. 10. The iliac portion of the fascia lata of the thigh. 11. The saphena vein. 12. The pubic portion of the fascia lata. 13. The tendon of the external oblique cut open, to shew the parts that are situated behind it. 14. The internal oblique muscle, its lower edge is raised and turned up. 15. The transversalis muscle, its lower edge is also raised and turned up. 16. The fascia transversalis. 17. The internal abdominal ring, the fascia is strong external and inferior to it, but weak on the pubal side, being there strengthened by the transversalis tendon. 18. The internal epigastric artery and vein, situated behind the fascia transversalis, at first on the inner side, and afterwards behind the spermatic cord. 19. 19. The spermatic cord descending from the internal abdominal ring, along the inguinal canal, through the external abdominal ring, and down to the testicle.

inches broad, in front of the crural ring, and of the femoral vessels; this process is named the "anterior sheath" of these vessels, and it can be traced as low as the junction of the saphena with the femoral vein, where it is lost in the general cellular sheath; for the present this process requires no further notice; external to the iliac or femoral artery the fascia transversalis is most intimately attached to Poupart's ligament as far as the spine of the ilium; and through this extent it is also continuous posteriorly with the fascia iliaca, which is a strong membrane covering the psoas and iliac muscles, and will be more particularly noticed hereafter; a dense white line marks the amalgamation between these three structures, viz.: the transverse and iliac fasciæ, with Poupart's ligament; this line extends in a gentle curve from the femoral artery to the crest of the ilium; enclosed in its aponeurotic or seam-like texture are the internal circumflex ilii artery and veins, these vessels give additional firmness to this line, which acts as a tense connecting band, strengthening Poupart's ligament, and tying it down posteriorly close to the iliac muscle, so as to close completely that portion of the crural arch external to the artery, and effectually secure it against any protrusion from the abdomen. From Poupart's ligament to a short distance above the level of the lower border of the transverse muscle, this fascia is usually firm and resisting, and therefore it materially serves to strengthen the wall of the abdomen, and to compensate for the deficiency and weakness of the internal oblique and transverse muscles, which do not descend so low as the crural arch through the whole of this extent; this portion of the fascia is behind the spermatic cord; it is covered immediately behind the external ring by the conjoined tendons, and more externally by the folded fibres, and by the tendinous expansion of the transversalis muscle, and still more externally, for a short distance, the cord lies upon it, until it arrives at the superior, or internal ring, where occasionally a fasciculus of the transverse muscle intervenes; the spermatic cord, or the round ligament, always perforates this fascia about half or three quarters of an inch above Poupart's ligament, and about an inch and a half or two inches from the tuberosity of the pubis; this perforation is called the *internal*, or *posterior abdominal ring*, and is situated about midway between the spine of the ilium and the symphisis pubis; it is not a distinct opening, for the fascia is prolonged in a tubular form for an indefinite distance, as one of the coverings of the cord, and, though fine, it can be traced even to the tunica vaginalis; this process is named the *infundibuliform fascia;* by gently drawing the cord towards the external ring it becomes very evident, and if this be now divided with a few circular touches of the knife, and pushed a little upwards, the internal, or superior, or posterior abdominal ring will become distinct; through this opening oblique inguinal hernia occurs, and it is in this situation that the neck of the sac suffers strangulation; about the eighth of an inch to its inner or pubal margin is placed the epigastric artery, usually with a vein on either side; these vessels are posterior to the fascia transversalis but

can generally be distinguished through it; a small hole may be made in it to expose them more distinctly; they may be considered practically, though not critically so, as forming the internal, or pubal boundary of the ring, while the transverse muscle borders it superiorly and externally; projecting through this opening we perceive the peritoneum covered by its subserous tissue, or the cellular layer of the fascia transversalis; from this projection, or bulging of the peritoneum (which will be more evident if we make gentle pressure on the abdomen above), a fine smooth fibrous process extends down along the cord; this is the remains of the tubular process of peritoneum which, in the fœtus, led from the abdomen to the scrotum, and behind which, and enveloped by it, the testicle and cord were guided from their original situation in the abdomen to their final destination in the scrotum; this tube was at first a serous canal, communicating above with the cavity of the peritoneum, and below with that of the tunica vaginalis; shortly after the descent of the testis this tube becomes closed, its sides adhere, and in process of time it loses all its original serous character; it is named the tunica vaginalis of the cord, as it serves to enclose, in a sort of sheath, all its component parts, except the cremaster muscle, which is superficial to it. Inguinal hernia in the adult descends in front of this tissue, between it and the superadded coverings of the cord; in infancy, however, this tube is not always closed sufficiently early or completely, and then an inguinal hernia may descend within it down to the testis, such form of hernia is named congenital inguinal hernia. The interval between the internal and external abdominal rings is traversed in man by the spermatic cord, and is named the *inguinal* or *spermatic canal*, to the anatomy of which the student should particularly attend, as the disease of *inguinal hernia* is situated here, in the treatment of which a correct knowledge of this region will be required. The *spermatic* or *inguinal canal* represents a sort of oblique, narrow groove, or gutter, the concave surface below, one wall, or side, in front, another behind, and, superiorly, a mere muscular interstice; it commences at the internal ring, and leads obliquely downwards, forwards, and inwards to the external, or inferior ring, where it terminates; this passage is bounded anteriorly by the skin and the two laminæ of the superficial fascia, by the tendon of the external oblique, and by the inferior fleshy margin of the internal oblique muscle; posteriorly, and from the internal to the external ring, by the transversalis fascia, covered sometimes by a few fibres of the transverse muscle, which are behind the cord, and next by the folded fibres and expanded tendon of this muscle, and lastly, by the conjoined tendons covered by the triangular ligament; inferiorly by the broad, grooved, or concave surface of Poupart's ligament and its reflected fibres proceeding to form its third insertion, or Gimbernaut's ligament, superiorly this space is closed by the apposition of its opposite sides; or rather it is occupied by the fleshy margin of the transverse muscle: as this muscle seldom descends below the upper border of the internal ring, it cannot be correctly said to form auy of the anterior boundary

of this space, though occasionally it has been so stated; not so, however, with the internal oblique, the fleshy margin of which is always anterior to this ring, and to the cord for some distance below it, whilst its tendon is posterior to it opposite the external ring; it is, perhaps, on this account, that some writers omit (I think incorrectly) this muscle from among the anterior boundaries of this canal. On the posterior, or abdominal wall of this inguinal channel we perceive a triangular depression, defined internally by the edge of the rectus, externally by the epigastric vessels, inferiorly by Poupart's ligament; this depression is bounded posteriorly by the conjoined tendons and the triangular ligament in its two inner thirds, and in its outer third by the expansion of the transversalis tendon and fascia; the lower part of this depression is opposite the external ring, and through this, direct or ventro-inguinal hernia occurs. In the male the spermatic cord and cremaster muscle, and in the female the round ligament of the womb, pass through this canal, the obliquity, or valve-like structure of which serves to protect the abdomen against a protrusion of its contents. Inguinal hernia occurs more frequently in the male than in the female sex, in consequence of the spermatic cord and the inguinal rings in man being larger than the ligamentum teres, or these openings in the female; in the infant the inguinal canal is shorter, less oblique, the rings are more nearly opposite, owing to the narrow pelvis, and to the crural arch being short, hence if the same exciting causes were present at this age, hernia would be more frequent in its occurrence than in the adult; I have, however, observed that the parietes are more muscular.

Inguinal hernia is either oblique or direct. *Oblique inguinal hernia* is the more common form; in this case the peritoneum, or hernial sac, with its contents, protrude through the internal ring along the anterior part of the spermatic vessels, carrying before it the surrounding cellular tissue and a prolongation of the fascia transversalis from the edges of the opening; the first is called the *fascia propria* of inguinal hernia, and the second the fascia infundibuliform. When the tumour has arrived at the lower edge of the internal oblique it insinuates itself between the cremaster muscle and the vessels of the cord, along which it descends to the external ring, where it is in general delayed for some time; the form of this opening and the inter-columnar fascia preventing its free passage through it; as the sac, however, descends towards the scrotum, these inter-columnar fibres become closely united to the cremaster, and are gradually elongated on the surface of the tumour. If oblique inguinal hernia which has passed the external ring be carefully dissected, it will be found covered by the following parts; beneath the integuments is the superficial fascia, in general much thickened and divisible into two or more laminæ, next is the inter-columnar fascia supporting the tumour and attaching it towards the external ring; beneath this, and generally intimately united to it, is the cremaster muscle, the fibres of which are often, but not uniformly, found considerably thickened and strengthened; these two last

mentioned structures frequently form one capsule to the tumour; deeper than this is the infundibuliform process of the fascia transversalis, derived from the margins of the internal ring, and subjacent to this is the cellular, or internal layer of the fascia transversalis, this immediately covers the hernial sac, or the peritoneum, and may be named its fascia propria; beneath this the hernial sac, or the peritoneum, will be found, which also, in cases of old hernia, will be considerably thickened; on opening the hernial sac, its contents, either omentum or intestine, will be seen; these coverings are found to be

*Fig. 39.**

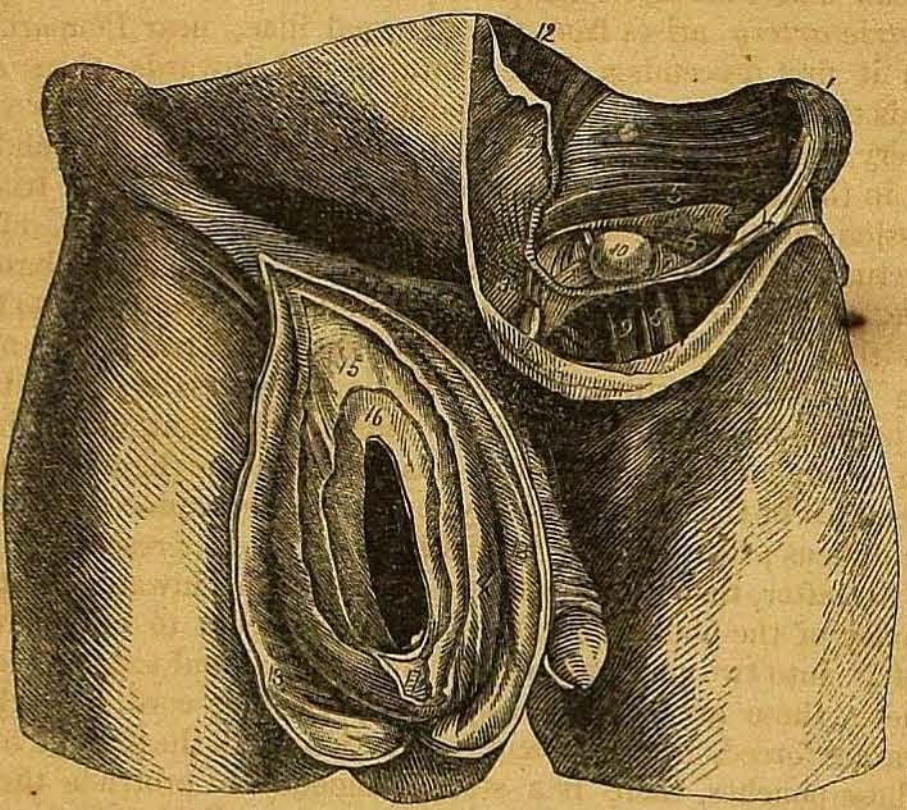


* This plate represents, on the left side, a small oblique inguinal hernia, making its appearance at the internal ring, on the outer side of the internal epigastric artery; and on the right side a scrotal hernia, with its coverings displayed by dissection.—(After Sir A. Cooper.) 1. The anterior superior spinous process of the ilium. 2. The tendon of the external oblique muscle reflected, to shew the inguinal canal. 3. The external, or superficial abdominal ring. 4. Poupart's ligament. 5. The internal oblique muscle, its lower margin is turned upwards to expose the hernial sac. 6. The lower edge of the transversalis muscle. 7. The fascia transversalis. 8. The femoral artery. 9. The femoral vein. 10. A hernia appearing at the internal abdominal ring, midway between the anterior superior spine of the ilium and the symphysis pubis; a small portion of the internal epigastric artery is seen on its inner side. 11. 11. The spermatic cord seen emerging from the internal abdominal ring behind the hernia, and taking its course through the external ring into the scrotum. 12. The rectus muscle. 13. 13. The integuments reflected, to shew the coverings of the hernia after it has reached the scrotum. 14. The fascia superficialis coming from the external abdominal ring, and forming the superficial investment of the hernia; at its upper part the transverse fibres of the external ring are seen. 15. The cremaster muscle thickened; it is seen descending under the margin of the external ring, and is lost upon the tunica vaginalis at 17. 16. The hernial sac covered by the fascia propria. 17. The testicle.

extremely variable, being sometimes easy of separation, at others, condensed and united by adhesive inflammation into one homogeneous covering, in which it is impossible to recognize the different tissues and laminæ we have enumerated. The student should next attend to the situation of the epigastric vessels and their relation to the parts concerned in oblique inguinal hernia; these vessels are placed behind the fascia transversalis between it and the peritonæum, or rather between the fibrous and cellular laminæ of the fascia, and in general can be discerned through the latter; if not, a little dissection, as has been remarked before, will render them apparent; two veins usually accompany the artery, one on either side; sometimes there is but one epigastric vein, and that is on the pubal, or inner side of the artery. The *epigastric artery* arises from the external iliac, near Poupart's ligament; it first descends a little forwards and inwards, then ascends towards the rectus muscle, immediately behind the fascia transversalis, and very near to the inner, or pubal side of the internal abdominal ring; in this course it forms the external boundary of that triangular depression on the posterior surface of the inguinal channel, of which the rectus is the inner border, and Poupart's ligament the base; this surface, as was mentioned before, is bounded posteriorly in its two internal thirds by the tendons of the oblique and transverse muscles, and in its external third, by the fascia transversalis; it is through some part of this space, internal to this artery, that direct inguinal hernia occurs; nearly parallel to this vessel is the ligamentous cord-like remains of the umbilical or hypogastric artery, proceeding towards the umbilicus; this cannot be distinctly seen at present; it will be found hereafter, that this substance, by projecting inwards, or towards the cavity of the abdomen, causes the peritoneum to bulge on either side of it into two pouches, called the internal and external inguinal pouches; these are separated by this projecting cord, and when the viscera are forced, by the violent contraction of all the parietal muscles, into these pouches, there is a strong tendency to protrude them still more, and thus this conformation is very generally believed to favour the production of hernia; the internal abdominal ring corresponds to the lower part of the external inguinal pouch; and the triangular surface just spoken of, behind the external ring, corresponds to the internal inguinal pouch. The obliterated hypogastric artery is not always parallel to the epigastric, but is sometimes a little internal to it, in which case a small pouch, or fossa of peritoneum, will exist between these, cut off by the epigastric artery from the large external inguinal pouch; this fact will be shewn directly to possess some anatomical interest, as well as practical importance. In oblique inguinal hernia, particularly if of long standing, the neck of the sac is nearly in contact with the epigastric vessels, which thus bound it on its internal side; hence the rule of practice in performing the operation for the relief of strangulated oblique inguinal hernia, when the stricture is seated in the neck of the sac, is, to direct the edge of the knife, or bistoury, upwards, or upwards and outwards. *Direct*, or *ventro-inguinal*

*hernia* protrudes directly through the external ring, without descending along the spermatic channel. The occurrence of this species is in a great degree guarded against by the fascia transversalis, and by the expansion of the tendon of the transverse muscle, also by the conjoined tendons which lie immediately behind the external ring; the contracted form of the base of this opening, together with the intercolumnar fascia, the edge of the rectus, the triangular ligament, and the spermatic cord, may be all enumerated as additional protections to this part of the abdomen. In this species of hernia the sac will be found covered by the integuments, superficial and intercolumnar fasciæ, also by an aponeurosis derived from the conjoined tendons, and from the fascia transversalis, which the tumour has pushed before it, though in some instances the latter has been found to have burst through these structures; the sac will be also covered by the usual cellular capsule; it is not covered by the cremaster, and in general it descends along the inner and anterior side of the cord, that is, the cord will be found external and inferior or posterior to it, but in some few cases the cord has been found passing across the neck of the sac, that is, anterior to it; the sac is seldom or never, however, found between the cremaster muscle and the spermatic vessels, except occasionally, in one particular form of which I shall speak directly. The epigastric vessels lie to the iliac, or outer side of the neck of the sac; in dividing the latter, therefore, in case this operation be required during life, the edge of the knife should be directed upwards, or upwards and inwards. It is safer, as a general rule, to divide the stricture directly upwards in all forms of inguinal hernia, because it is often extremely difficult, and in some cases even impossible to determine, during an operation, the exact species of the disease; thus when an oblique inguinal hernia has continued for a considerable length of time, the spermatic canal will be found altered in many respects from its natural condition; it will have become dilated and shortened, and the abdominal rings expanded and approximated, so as to render it difficult to distinguish it from a direct inguinal hernia; and again, the direct hernia sometimes protrudes more externally, that is, close to the pubal side of the epigastric vein and artery, in which case the tumour may be delayed for some time in the canal, and must descend with some obliquity to reach the external ring: direct, or ventro-inguinal hernia, therefore, appears under two different forms; one, which is the more common, protrudes directly through the external ring, on the outer edge of the rectus, this is named *internal*, or *inferior direct hernia;* the other, which is less frequent, protrudes close to the pubal side of the epigastric vessels, external to the obliterated hypogastric artery, and in the small peritoneal pouch between these, this is named *superior*, or *external direct hernia;* both forms correspond in not protruding through the internal ring, as the oblique hernia does, but through the posterior wall of the inguinal canal, and in some parts of the triangular depression before alluded to; both also are internal, or on the pubic side of the epigastric vessels; the internal, or inferior, is between the hypogastric artery and the rectus; and the

superior, or external, is between the hypogastric and epigastric arteries; the superior may be retained for a longer or shorter period in the canal, as the oblique often is, and in its course downwards may pass between the cremaster muscle and the cord, so as to be covered by the former; hence, then, the obliquity of the tumour will render it impossible, before operation or dissection, to discriminate this superior, or external direct hernia from the ordinary oblique, and even when the parts are partially exposed during life, the presence of the cremaster will render the diagnosis equally difficult and uncertain. To divide the stricture directly upwards, is, therefore, the best general rule to adopt, when it exists at the neck of the sac, which is found to be its most frequent situation; if it be in any of the more superficial tissues, the direction of the division is comparatively unimportant; great caution, however, is to be observed in all the steps of such an operation, as deviations from the common arrangements are not uncommon; thus the sac, in oblique hernia, sometimes separates the vessels of the cord from each other, and instead of their being placed posterior to it, the vas deferens, or the spermatic artery, or a plexus of veins, may be unexpectedly found crossing, or coursing along the tumour; in the direct species, also, the whole cord has been found passing in front of the sac, and in old herniæ of large size, whether oblique or direct, parts often undergo strange alterations, in structure as well as in position; it is of importance also to bear in mind, that when a stricture on a hernia is placed in the neck of the sac, a division to a very short extent only is required, the mere pressure of the edge of the bistoury against it sometimes suffices, and this is fortunate, for when the neck has become very large it will be found to have formed, not only a close lateral attachment to the epigastric artery and veins, but by the approximation and dilatation of the rings, and shortening of the canal, it will often have become partially encircled by those vessels, so that a too extensive incision directly upwards may divide them; no doubt, should such an accident occur, a little dissection will enable the operator to expose and tie them; but for obvious reasons, in this case especially, prevention is better than cure. The next point to be attended to, in connexion with the anatomy of inguinal hernia, is the disposition of the peritoneum in this region, and to which we have already partially alluded: divide the transverse fascia from the rectus to the crest of the ilium, carefully separate it and turn it down towards the thigh; a layer of cellular membrane, containing more or less adipose substance, is now exposed, covering the peritoneum; this layer some consider (as was before mentioned) the deep layer of the transverse fascia, but it is a totally different structure from it, at least in this particular region; it is mere sub-peritoneal cellular tissue, it increases in thickness as it descends to Poupart's ligament, from which it is reflected backwards and upwards on the front of the external iliac vessels, and on the back part of the peritoneum towards the spine; internally it descends into the pelvis; as it passes from Poupart's ligament towards that region it closes the femoral ring beneath this ligament on the inner side of the femoral

vein; in that locality it becomes much thickened, and is commonly named the *crural septum*, implying that it separates the thigh from the abdomen, or closes up the communicating passages between these, and as it must be pushed before a femoral hernia, and form an immediate covering to it, it is called its fascia propria; make a transverse incision through the peritoneum, from the umbilicus to the ilium, raise and hold tense the membrane, and look from above downwards into the cavity; from the umbilicus three projecting ridges are seen to descend, one in the centre (urachus) to the summit of the urinary bladder, and one on either side (obliterated umbilical, or hypogastric arteries), diverging towards each inguinal region, and then bending backwards towards the side of the pelvis; these lateral ridges are more prominent than the central one, and as each of these is covered by a duplicature of the peritoneum, they throw this membrane into three falciform processes, converging to the umbilicus and separating below; by these three folds, four pouches are formed, two on each side; these are termed the right and left external and internal inguinal pouches; the external is very large and deep, and in corpulent persons, or in long continued constipation and distention of the bowels, is often very prominent through the parietes; this external pouch extends outwardly to the ilium, and is bounded internally by the hypogastric artery, to which the epigastric is nearly parallel, though often the latter is a little external to it; the internal ring is at the inner side and lower part of this pouch, and, of course, external to the falciform projection of the hypogastric artery; when the intestines in this pouch are subjected to much pressure from the muscles of the abdomen, this process would appear to resist their slipping inwards towards the pelvis, and thereby encourage the protrusion of the peritoneum and its contents through the internal ring; accordingly oblique inguinal hernia always leads out of this external inguinal pouch into the spermatic channel. The internal inguinal pouch is much smaller and never so deep as the external; it is between the folds formed by the hypogastric artery externally and the urachus internally, and it corresponds to the external ring and posterior surface of the inguinal channel; it is this pouch which is generally protruded in direct, or ventro-inguinal hernia; when the hypogastric cord and epigastric artery are not parallel, but the latter at some distance external to the former, we shall find a small pouch, or fossa between these; this might be named the middle inguinal pouch; it is separated from the internal by the hypogastric cord, and from the external (from which it is cut off) by the epigastric artery; it corresponds to that portion of the posterior wall of the spermatic channel which is almost wholly formed by the transversalis fascia; through this pouch that rare form of hernia, called superior, or external direct, or ventro-inguinal, protrudes.

In the dissection of these muscles several vessels and nerves are met with; they are of a small size, and, with few exceptions, of little practical importance; the superficial branches from the femoral artery, which are distributed chiefly to the integuments, to the superficial

fascia, and to the external oblique muscle, have been already noticed; the five or six inferior intercostal and the lumbar arteries send branches forwards between the muscular laminæ to inosculate with the internal mammary and epigastric arteries; these two last-named vessels are chiefly distributed to the recti; inferiorly and laterally the ilio-lumbar and circumflex ilii arteries also assist in supplying the abdominal muscles; the origin and course of the mammary arteries have been already noticed; the intercostal and lumbar arise from the descending aorta, the ilio-lumbar from the internal iliac, and the epigastric and circumflex ilii from the external iliac.

THE EPIGASTRIC *arises* from the trunk a little distance above Poupart's ligament, it first descends a little forwards and inwards, with a curve concave upwards, convex downwards, it then ascends obliquely, between the fascia transversalis and the peritoneum, behind the spermatic cord, or the round ligament, and at a little distance from the inner side of the superior abdominal ring; the vas deferens appears to bend round it externally, and then passes posterior to it in its course to the pelvis; this artery, therefore, ascends behind the inguinal channel, and of course between the two rings, but much nearer to the internal, or superior, than to the external, or inferior; oblique inguinal hernia commences on its outer side and descends anterior to it; direct hernia occurs internal to it, or between it and the rectus muscle; between the pubis and umbilicus it perforates the thin fascia transversalis, enters the sheath of the rectus just below its posterior deficiency, ascends at first posterior to the muscle, but near the umbilicus it enters its substance and anastomoses with the internal mammary, the abdominal branch of which enters the sheath of the rectus above the posterior deficiency in it, just beneath the cartilage of the seventh rib, and descends to the first or second linea transversa, then enters the muscle; shortly after its origin the epigastric sends off its internal branches, which pass behind Poupart's ligament and the pubes, to anastomose with the opposite artery, and to communicate in general very freely with the obturator; when this latter communication is much developed, and at the same time the pelvic origin of the obturator diminished or wanting, then the latter vessel is said to arise from the epigastric, and this very frequently occurs: near the internal ring the epigastric gives off one or two spermatic branches, which are chiefly distributed to the cremaster muscle and other coverings of the cord; before its termination in the rectus, it gives off external branches to the lateral muscles of the abdomen; its accompanying vein or veins open into the external iliac vein, near Poupart's ligament.

THE CIRCUMFLEX ILII ARTERY *arises* opposite and near to the epigastric, it passes outwards and upwards towards the spine of the ilium, parallel to but deeper than Poupart's ligament, and enclosed in a strong fibrous canal already described; near the ilium it pierces this and runs for a short way beneath the transverse muscle, and about the middle of the crest of the ilium it passes through this muscle and then ramifies between it and the internal oblique, sending some branches for-

wards to meet those from the epigastric, and continues itself upwards and backwards parallel to the iliac crest, and anastomoses freely with the ilio-lumbar artery from the internal iliac; it also sends several branches into the iliacus muscle, which anastomose in a similar manner; its trunk is accompanied by one or two veins which pass across the external iliac artery and join the iliac vein.—See *Vascular System.*

The nerves in the anterior and lateral abdominal walls are derived from the five or six lower intercostals and from the lumbar plexus; the intercostal branches extend forwards between the internal oblique and transversalis to the sheath of the rectus, perforate this and enter the muscle; each then divides into two branches at least, one for the muscle, the other, accompanied by a small artery, pierces the muscle and its anterior sheath near the linea alba and becomes cutaneous; the last dorsal runs downwards and forwards, and sends off a large cutaneous branch which pierces the two obliqui and descends over the crest of the ilium and is distributed to the integuments over the glutæi. The branches of the lumbar plexus are only two or three in number, are of great length, and take an oblique course downwards and forwards towards the inguinal region, and are partly muscular, but principally cutaneous or superficial; the first is named by some, *superior musculo-cutaneous*, by others *ilio-inguinal*, or *scrotal;* it is derived from the first lumbar, passes through the psoas, and runs obliquely downwards and outwards in the sub-peritoneal cellular tissue; at the crest of the ilium it divides into an abdominal and a cutaneous branch; the first passes, similarly to the intercostal branches, between the oblique and transverse, to the rectus; the cutaneous branch proceeds as far as the anterior superior spine of the ilium, then proceeds parallel to Poupart's ligament and joins the spermatic cord, or round ligament, accompanies it through the canal, and is finally distributed to the integument of the pubes and groin. The next abdominal branch of the lumbar plexus, or *smaller musculo-cutaneous*, runs like the last as far as the spine of the ilium, communicates with it, accompanies the cord, and is lost in the inguinal and scrotal integuments.—See *Nervous System.*

In connexion with inguinal hernia, the student may next study the anatomy of the groin in reference to *femoral* or *crural hernia*, or he may postpone this dissection until the contents of the abdomen have been examined and removed; we shall, however, here subjoin the description of the parts concerned in this disease. Remove the integuments from the anterior part of the upper third of the thigh; the superficial fascia will be seen descending over Poupart's ligament to invest the lower extremity; in the groin this fascia is of very variable structure, sometimes it is very thick, and may be divided into several layers, which are separated by lymphatic glands and by the superficial inguinal vessels; it may be easily raised from the fascia lata on the outer and inner sides of the thigh, but in the middle of the groin and about an inch below Poupart's ligament they are almost

inseparably joined; when the superficial fascia shall have been dissected off the forepart of the thigh, we shall see several lymphatic glands, the saphena vein, and some small blood-vessels, lying on the fascia lata; the form and boundaries of the *inguinal region* also may

*Fig.* 40.*

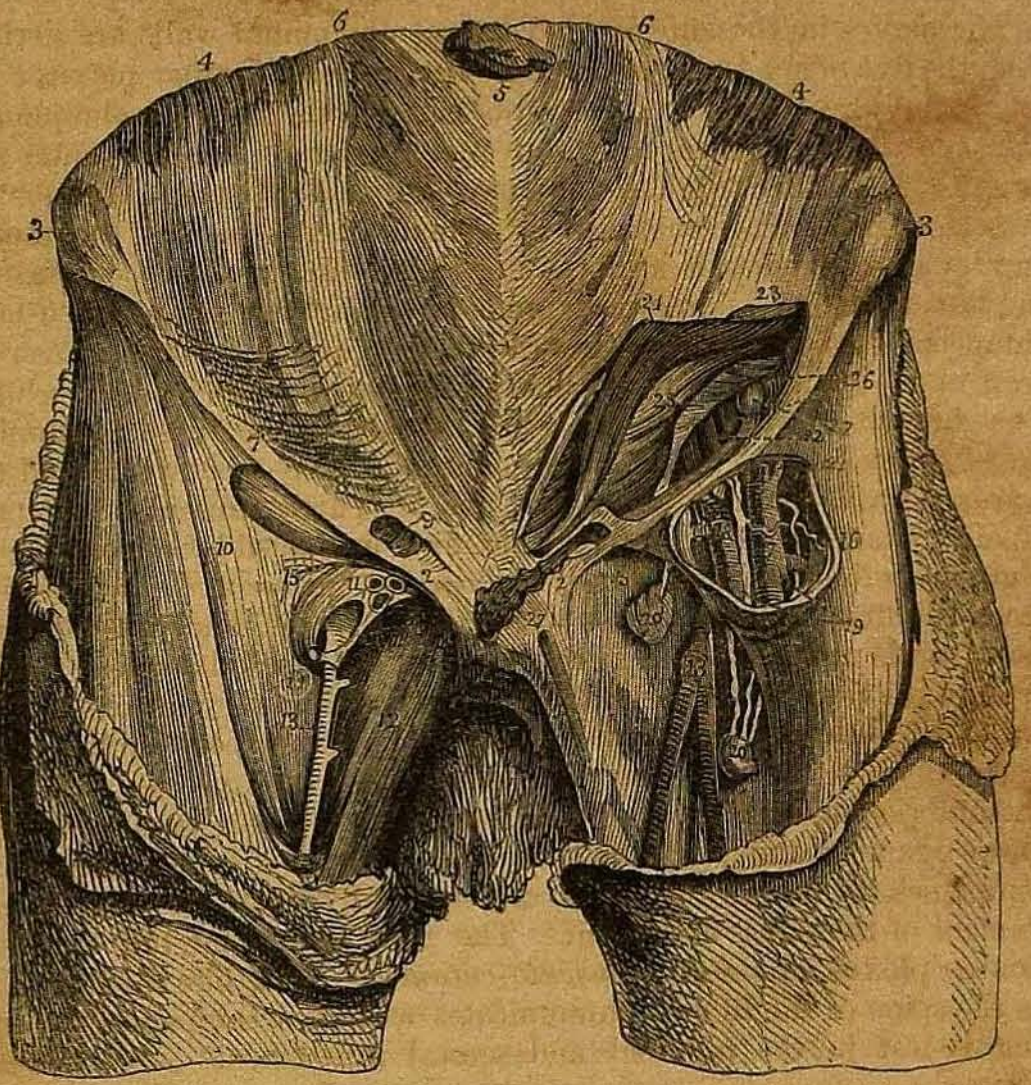

* The abdominal rings and crural arch in the female. 1. The symphysis pubis. 2. 2. The tuberosity or spine of the pubis. 3. The anterior superior spinous process of the ilium. 4. 4. The external oblique muscles. 5. The linea alba. 6. The linea semilunaris. 7. Poupart's ligament or the crural arch. 8. The intercolumnar fibres. 9. The external abdominal ring. 10. The iliac portion of the fascia lata. 11. The cribriform portion. 12. The pubic portion of the fascia lata. 13. The internal or greater saphena vein. 14. Burn's ligament. 15. Hey's ligament. 16. The femoral sheath cut open. 17. The femoral artery. 18. The femoral vein, the course of femoral hernia is on the inner side of the vein. 19. Absorbent vessels within the sheath. 20. 20. Absorbent glands. 21. The internal circumflex ilii artery. 22. The internal epigastric artery, seen through the fascia transversalis. 23. The external oblique divided and raised. 24. The internal oblique muscle turned upwards. 25. The edge of the transversalis muscle turned upwards. 26. The fascia transversalis, passing up behind the transversalis muscle. 27. 27. The round ligament of the uterus, descending through the internal abdominal ring, in the inguinal canal, above Poupart's ligament, and through the external abdominal ring, to be lost in the fat on the pubis.

then be more distinctly seen; the term *crural* is sometimes applied to this space, and that of inguinal to the smaller region above Poupart's ligament; I prefer naming the latter spermatic, and the former inguinal, or superior crural. The inguinal region is triangular, the base is Poupart's ligament; the apex is, inferiorly, formed by the meeting of the sartorius and adductor muscles, at the lower part of the upper third of the thigh; the external side is very prominent, and consists of the sartorius, iliacus, rectus, and other muscles, all covered by the fascia lata; the internal, or pubic side, is flat and on a plane posterior to the iliac; it is formed by the pectinæus and adductor muscles, also covered by the fascia lata. The *inguinal lymphatic glands* are irregular in number and size; they are in general about twelve in number, and may be divided into a superficial and a deep set; the former are the more numerous, and may be arranged, from their situation, into the superior and inferior; the superior are small, four or five in number, lie parallel to Poupart's ligament, some above, others below it; the inferior are two or three in number, larger than the former, and placed perpendicularly, or parallel to the saphena vein; in general one lies behind this vessel, near its termination, and sometimes so low down as the middle of the thigh; the *deep inguinal glands* are beneath the fascia lata, are three or four in number, and are closely connected to the sheath of the femoral vessels, chiefly to its inner side; in general one occupies the femoral ring; the inguinal glands are usually more developed in the young than in the old; their number is very uncertain and generally in an inverse ratio to their size, as if in some cases one gland was subdivided into several, and in others several united into one.

The *saphena vein* is the principal cutaneous vein of the lower extremity; it will be seen in a future dissection to arise from the dorsum and inner side of the foot, and to ascend in front of the inner ankle along the inner side of the leg, and passing behind the inner condyle of the femur it continues to ascend along the inner and anterior part of the thigh to within about an inch and a-half of Poupart's ligament, where it passes through an opening in the fascia lata (the saphenic opening), and joins the femoral vein about an inch or an inch and a-half below the crural arch. The *saphenic opening* in the fascia lata will be very distinctly seen if the vein be divided on the thigh and raised toward's Poupart's ligament, it presents a well-marked semilunar edge (Burn's ligament), the concavity looking upwards; this edge, though apparently sharp, yet if carefully examined will be found reflected backwards on the sheath of the femoral vessels: remove the superficial inguinal glands, clean the surface of the fascia lata, to the connexions of which in this region the student should next attend.

The *fascia lata* may be observed to be united to the spine of the ilium, to the whole length of Poupart's ligament, also to the linea innominata and spine of the pubis; it covers the muscles on either side of the groin, and the vessels in the middle; for the purpose of more particular examination, it may be divided in this region

into three portions, the internal, or pubic, or pectineal portion, the external or iliac, and the middle or cribriform; the *internal* or *pubic portion* covers the pectinæus, gracilis, and adductor muscles, and is inserted internally into the ramus of the ischium and pubis; superiorly into the linea innominata or ileo-pectinea, anterior to Gimbernaut's ligament; externally it passes behind the sheath of the femoral vessels, and at the edge of the psoas tendon divides into two laminæ, one passes beneath that tendon, and is attached to the capsular ligament of the hip-joint; the other passes over that tendon and is continued into the deep surface of the fascia iliaca. The *middle* portion of the fascia lata is very thin, and has been termed the *cribriform fascia:* this extends from the saphena vein to Poupart's ligament, and is connected on either side to the pubic and iliac portions of the fascia lata. The cribriform fascia is limited to a small extent, it covers the femoral vessels, adheres intimately to their sheath, and is perforated by the lymphatic vessels passing to the deep lymphatic glands; this portion of the fascia lata is more closely connected than any other to the superficial fascia; indeed in structure it resembles the latter more than the former, nor are all its fibres directly continued from those of the fascia lata; some have, therefore, considered the cribriform fascia as a deep lamina of the superficial; in many cases, however, it has an aponeurotic structure, and appears to be clearly derived from the iliac portion, and inserted into the pubic portion of the fascia lata; it presents much variety in this respect. The *external* or *iliac portion* of the fascia lata is very dense and strong, it is continued from the external surface of the thigh, and is intimately attached superiorly to the spine of the ilium, and to Poupart's ligament; and, uniting with the cribriform fascia, is continued in front of the femoral vessels, along with the inferior or reflected fibres of Poupart's ligament, and is inserted along with these into the linea innominata, thus assisting to form the external part or the base of Gimbernaut's ligament. If the cribriform fascia be removed along with the superficial fascia, then the iliac portion of the fascia lata will present the appearance of a *crescentic* or *falciform process*, extending across the femoral vessels, the concavity looking downwards and inwards; the inferior cornu joins the external cornu of the saphenic opening, and the superior cornu (Hey's ligament) is inserted, along with the reflected fibres of Poupart's ligament, or Gimbernaut's ligament, into the linea innominata, on the internal border of the crural ring; although this crescentic process appears to present a defined edge, yet if the latter be examined closely it will be found reflected backwards on the sheath of the vessels, and on the muscles external to them, in the same manner as the apparent edge at the lower part of the saphenic opening, beneath the saphena vein. When the thigh is extended and rotated outwards, this portion of the fascia lata will be found very tense, particularly the superior cornu of this falciform process, and if the limb be put into the opposite position, it will become relaxed, hence, then, in performing the taxis for the reduction of femoral hernia, the thigh should be flexed,

*Fig.* 41.*

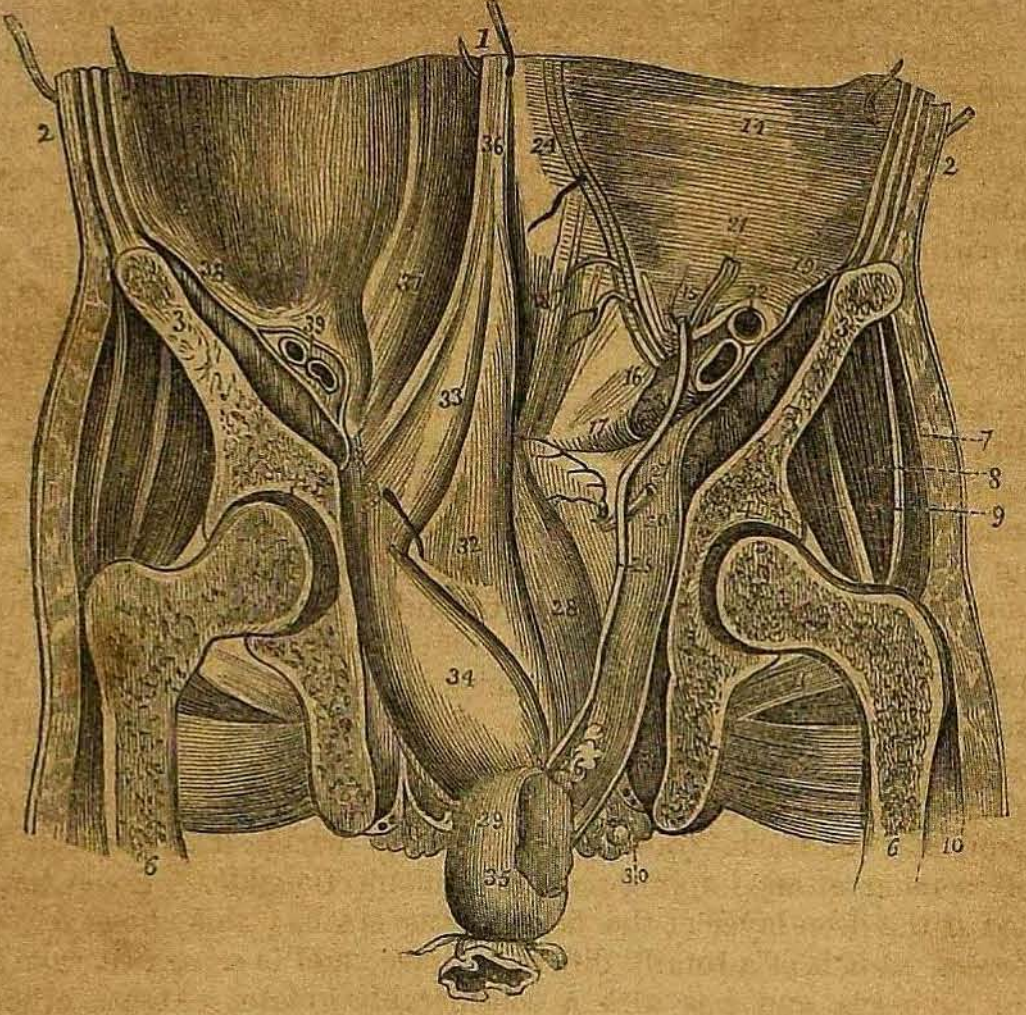


* A vertical section passing transversely through the lower part of the abdomen, and through the iliac bones, hip joints, femora, and ischia. This plate represents the peritoneum lining the inferior portion of the anterior wall of the abdomen, the posterior wall of the abdomen and pelvis having been removed. On the right side the peritoneum has been detached, and drawn over to the left side, in order to expose the parts upon which it was applied. 1. A horizontal section of the anterior wall of the abdomen a little below the umbilicus. 2. 2. A vertical section of the lateral walls, including the external oblique, internal oblique, and transversalis muscles. 3. 3. A section of the iliac bones. 4. 4. Section of the acetabula. 5. Section of the tuber ischii. 6. Section of the femur. 7. Section of the glutæus maximus. 8. Of the glutæus medius. 9. Of the glutæus minimus. 10. Section of the vastus externus. 11. The external obturator muscle. 12. Part of the adductor magnus. 13. Section of the psoas and iliac muscles. 14. The fascia transversalis exposed by the removal of the peritoneum. 15. The internal abdominal ring. 16. The posterior wall of the inguinal canal. 17. Gimbernaut's ligament. 18. The posterior surface of the rectus muscle. 19. The iliac fascia, covering the iliac and psoas muscles. 20. The pelvic fascia. 21. The spermatic vessels divided just above their entrance into the inguinal canal. 22. The divided extremity of the external iliac artery. 23. The external iliac vein. 24. The internal epigastric artery and vein. 25. The vas deferens. 26. The vesicula seminalis of right side. 27. The obturator artery. 28. Part of the posterior surface of the bladder deprived of its peritoneal coat. 29. Section of the levator ani muscle. 30. Section of the internal pudic artery and vein. 31. Section of the internal obturator muscle. 32. External surface of the peritoneum, detached from part of the posterior surface of the bladder. 33. The peritoneum passing from the anterior wall of the abdomen to the summit and posterior surface of the bladder. 34. The peritoneum covering the posterior surface of the bladder. 35. Its continuation covering the anterior surface of the

adducted, and rotated inwards; thus this process of the fascia lata will be relaxed, and the crural ring more easily enlarged, for it is obvious that these fibres bound this opening anteriorly and internally, together with the reflected fibres of Poupart's ligament: there can, I conceive, be little doubt but that the upper and internal part of this falciform process is often concerned in forming the strangulation on femoral hernia. The close connexion between Poupart's ligament and this portion of the fascia lata imparts considerable strength to this region, and draws this ligament downwards and backwards, so as to strengthen and assist in closing the external portion of the crural arch.

Next direct your attention to the internal surface of the crural arch, and to the connexion between it and the deep fasciæ of the abdomen, viz., the transversalis and iliaca: first cut across the cord or round ligament, next divide the fascia transversalis from the spine of the ilium towards the rectus muscle, and dissect it down from the peritonæum, then, in the same direction, carefully separate from the latter the cellular layer which is attached to it; finally, push upwards, and secure in that position, the peritoneum with the contained viscera; the loose connecting cellular tissue in the iliac fossa readily admits of this separation; the first object now to be attended to is the detached lamina of cellular membrane which was interposed between the peritoneum and the fascia transversalis, and to which it is difficult to apply a name at once appropriate and unobjectionable. Some have called it the deep layer of the fascia transversalis; this, however, is incorrect, as it is of a totally different tissue, and is separated from it by bloodvessels, and has also a considerably greater extent; others have named it the subperitoneal or subserous cellular tissue, which it really is; this name, however, does not seem very appropriately applied to a structure which is to be examined detached from, and unconnected to that membrane; the term crural septum has also been applied to it, and to a certain extent correctly, for it forms a partition between the thigh and the iliac region of the abdomen; it has also been designated as the *fascia propria*, because in herniæ, whether inguinal or crural, this membrane must be protruded before the peritoneal sac, to which, therefore, it forms an immediate proper covering; under this title, then, we shall examine it, admitting, however, that this name is very open to criticism, it is in fact applying to a natural or normal structure a name derived from its unnatural or abnormal state; superiorly, then, this membrane is fine and delicate, merely serving as a connecting medium to the peritoneum; inferiorly it is increased in thickness, is laminated, and contains more or less adipose substance, and is separated from the fascia transversalis by the epigastric vessels; it lines Poupart's ligament, and rounds off the angle, by filling

rectum. 36. Elevated fold of peritoneum, formed by the projection of the urachus and left umbilical artery. 37. External inguinal pouch. 38. Peritoneum, descending from the lateral wall of the abdomen over the internal iliac muscle, over 39. The external iliac artery and vein, into the cavity of the pelvis.

up the interstices, between it and the iliac vessels as they descend behind it; from this ligament the fascia propria is reflected upwards and backwards, externally over the iliac fascia, in the middle over the external iliac artery and vein, and internally it passes across the femoral ring towards the cavity of the pelvis; in the first or external portion it serves as a loose and cellular connexion between the iliac fascia and the peritoneum, as also between the former and the cœcum intestine on the right side, and the sigmoid flexure of the colon on the left; in its middle portion, that is, in its inflection on the forepart of the iliac vessels, it is thin but firm and strong, and adheres on either side of them to the iliac fascia, which is behind these vessels, it thereby retains these in their position along the margin of the pelvis, and binds the vein and artery so closely together, that in the operation of passing a ligature around the latter, much difficulty has been experienced in separating these vessels; this difficulty, however, is easily surmounted by first making a small opening in this fascia and then tearing it to the extent required; internal to these vessels, and close to Poupart's ligament and the pubis, the internal portion of this fascia becomes very thick, passes across the femoral ring, and is depressed into it, so as to present a concavity above; this portion is often strengthened by aponeurotic fibres traversing it from the fascia transversalis in front to the fascia iliaca behind, that is, from the anterior to the posterior part of the sheath of the vessels, and of the crural ring; this is the proper crural septum, it often contains a lymphatic gland; a cluster of lymphatic vessels always ascend through it; this serves to protect this portion of the crural arch against a hernia, and when the latter does occur, this is protruded before it, and as it is essentially cellular it yields to distention, and forms a regular investing capsule for the hernial sac, hence the term fascia propria; in its natural or normal state then, the term crural septum is correctly applied, but in its abnormal condition, that is, when protruded before and around a hernia, its proper title is fascia propria; the uses, therefore, of this structure generally, are: first, to serve as a connecting medium to the peritoneum, in which its nutrient vessels may ramify; secondly, to add to the strength of the inferior or inguinal regions of the abdomen, by connecting the several structures more intimately together, and by filling up the angular interstices between substances of different form and consistence; thirdly, it retains the external iliac vessels in a fixed position, and lastly, and above all, it closes the femoral ring, and thereby affords much security against the occurrence of femoral hernia. This membrane may now be detached from this region, when we shall obtain a clear view of the internal surface of Poupart's ligament, of the parts which pass beneath it, and which fill the space or cavity of the crural arch, also of the attachments between Poupart's ligament, the fascia transversalis, and iliaca.

To the *fascia iliaca* we shall next pay some attention. This is a distinct, and, in some situations, a very strong aponeurosis, principally developed in the iliac region, and hence its name; it may be said to

arise from the inner border of the entire crest of the ilium, and from Poupart's ligament external to the iliac artery; it expands over the iliac and psoas muscles, ascends on the latter as high as the diaphragm, and is attached to the ligamentum arcuatum above, and internally and laterally to the sides of the lumbar vertebræ, forming a series of tendinous arches over the lumbar arteries and the communicating branches between the sympathetic ganglions and the lumbar spinal nerves; each arch is opposite the groove on the side of the body of each vertebra; the last arch is very large and strong, extending from the last lumbar vertebra to the brim of the pelvis, the obturator and lumbo-sacral nerves pass beneath it; from the spinous process of the ilium to the iliac artery, this fascia is intimately united to Poupart's ligament by a strong tendinous attachment which is also common to the fascia transversalis; it is from this common tendinous structure, rather than from the ligament itself, that the lower fibres of the internal oblique and transverse muscles arise; a dense opaque line marks it distinctly, this encloses the internal circumflex ilii vessels; immediately on the outer side of the iliac artery the fascia separates from Poupart's ligament, presents a semilunar border towards the vessel, and then passing behind both the artery and vein and the crural ring, it descends into the thigh, forming the posterior part of the sheath of the femoral vessels, and lying in front of the psoas and iliac muscles, and of the anterior crural nerve; it adheres to these muscles, and internal to these to the pubis and to the capsule of the hip joint, and becomes continuous with the pubic or pectineal portion of the fascia lata; from the iliac fossa it also passes inwards, behind the external iliac vessels, and is implanted into the thick fibrous covering of the lateral brim of the pelvis; the psoas parvus tendon (when present) is blended with it by a broad expansion over this line, the fibres of each, however, pursue a different direction. The iliac fascia is thin superiorly on the psoas, stronger on the iliacus, but does not adhere closely to either, cellular tissue, and sometimes adeps being interposed; its fibres are mostly transverse; the lumbar nerves are all posterior to it, except some small, perforating, abdominal, and inguinal branches; as it passes behind the femoral vessels, it separates the artery in front from the anterior crural nerve, which is pressed down behind it into a groove between the psoas and iliac muscles. The iliac and transverse fasciæ are not only connected, or rather continuous with each other throughout the whole distance between the iliac artery and the spine of the ilium, but even when they have separated and descended into the thigh, the transverse in front of the vessels and the iliac behind them, they are still connected by two vertical antero-posterior processes or septa, passing from the one fascia to the other, the first is between the artery and vein, the second is on the inner side of the vein, between it and the femoral ring and canal, and, in the case of a femoral hernia, will separate the tumour from that vessel, and prevent it compressing the latter. The iliac fascia serves, in the first place, as a firm covering to the psoas and iliac muscles; secondly, it affords considerable strength to the lower part of the

abdomen, by its firm adhesion to Poupart's ligament, which it ties down so closely as to contract the crural arch, and effectually prevent any abdominal protrusion through it between the artery and the spine of the ilium; thirdly, it forms the posterior part of a smooth canal or sheath, for the passage of the femoral vessels and lymphatics, as the transversalis fascia forms the anterior, and lastly, by means of the connecting septa between these two, the sheath is retained of the necessary size only, and a strong resistance offered to its distention.

The attachments of the iliac fascia would appear capable of exerting some influence on the course of purulent collections, which have formed higher up in either the subserous, or peritoneal, or in the subaponeurotic cellular tissue; in either case it is a barrier, confining the fluid to the tissue in which it has been formed; in either case the fluid may descend towards the groin, but if it be in the subserous tissue it will lie anterior to the great vessels, whereas it will be behind these if in the subaponeurotic, at least until it arrives in the thigh, where its further course may become modified by the connexions of the fascia lata. The fascia transversalis has been already minutely described in the anatomy of inguinal hernia, we have now, therefore, only to observe its intimate attachment to the inner lip of the ilium and to Poupart's ligament from the spine of that bone, as far as the pubis, into the linea innominata of which it is inserted; here also it is inseparably joined to the conjoined tendons of the internal oblique and transverse muscles; as this fascia is passing anterior to the iliac or femoral vessels, a portion of it extends beneath Poupart's ligament, in front of these vessels, so as to form the *anterior part of their sheath*, as well as of the crural ring and crural canal; this process of the fascia transversalis soon becomes thin and indistinct, and is lost in the cribriform part of the fascia lata. The fascia transversalis and iliaca are not inaptly compared to a funnel, containing in the superior wide portion the peritoneum and its contents, and enclosing in the inferior narrow part, or pipe, the femoral vessels, and one or two lymphatic glands; of this funnel the fascia transversalis forms the anterior, and the fascia iliaca the posterior wall; these fasciæ may now be seen to be perfectly continuous with each other, between the vessels and the spine of the ilium, different names only being applied to different portions of one extensive aponeurosis; as the iliac and transverse fasciæ are continued one into the other, external to the iliac artery, the white line already noticed may be again observed.

The student should next consider how the space, commonly called the crural arch, is naturally filled; that portion of it between the spine of the ilium and the iliac or femoral artery is occupied by the psoas and iliac muscles, imbedded between which is the anterior crural nerve: on the pubic side of these muscles is the femoral artery, crossed at a right angle by the circumflex ilii vein; next to the artery is the femoral vein, and at a little distance to the pubal side of this vessel is Gimbernaut's ligament, which closes the internal part of this space; thus almost all the crural arch is filled, except a small portion

between the femoral vein and the third insertion of Poupart's or Gimbernaut's ligament ; this space is the *femoral*, or *crural ring ;* this is somewhat of a triangular form, the base, externally, is the femoral vein, the apex internally is Gimbernaut's ligament ; it is bounded anteriorly by Poupart's ligament, and by the superior fibres, or cornu of the falciform process of the fascia lata, and posteriorly by the pubis, covered by the pectineal muscle, and by the pectineal portion of the fascia lata: the spermatic cord, or the ligamentum teres, lies on the anterior boundary of this opening, and above it, and still closer to it in front, is a small artery with its vein, branches from the epigastric vessels, which are passing inwards to the back part of the pubis ; this artery generally inosculates with the obturator; this last-named artery, which is normally a branch of the internal iliac, very frequently arises from the epigastric and then takes the course of the small anastomosing branch just mentioned, in front of the ring, and then dropping along its internal side into the pelvis ; this very frequent anomaly in this vessel, we may regard as an hypertrophy, or excessive development of this anastomosis, and a proportional diminution in the size of the more regular artery ; the epigastric vein and artery ascend obliquely inwards along the outer and upper angle of this opening, so that bloodvessels surround it on all sides except posteriorly and internally, and even in the latter aspect also, when the obturator artery springs from the epigastric, as, in such a case, it may pass first in front, and then along its inner border, although occasionally it passes along the posterior border of the ring in its inward course to the pelvis. Gimbernaut's ligament prevents femoral hernia occurring internal to this space, which is the only part in the crural arch where a hernia can descend, and even here this accident is in a great degree guarded against, as a lymphatic gland generally occupies this situation, and the layer of condensed cellular membrane, already described as the crural septum, extends across the opening, and as this must be carried down before the hernial sac, so as to form a covering for it, it has been also named the *fascia propria ;* this fascia, though often weak and indistinct in the natural and healthy state, becomes very thick and strong in cases of old femoral hernia. We should bear in mind that Gimbernaut's ligament is composed of the combined fibres of Poupart's ligament, and of the falciform process of the fascia lata ; the latter fibres form its outer part, or base, that is, the portion nearest to the ring ; this marginal base is somewhat crescentic, and is very similar to the semilunar border formed by the fascia iliaca on the outer side of the iliac, or femoral artery ; so that the upper, or pelvic extremity, or opening of the crural sheath, presents a transversely elliptical figure ; its anterior boundary is formed of fascia transversalis, Poupart's ligament, and the iliac portion of the fascia lata ; its posterior boundary is formed of fascia iliaca, and the pubic portion of the fascia lata, covering the pubis, the pectineus, psoas, and iliac muscles, and the anterior crural nerve ; the lateral angles, or commissures, are the two semilunar borders just alluded to. The entire of this opening

may be considered as divided into three parts, or tubular processes, the external for the artery, the middle for the vein, and the internal is the crural ring, or canal. Crural hernia cannot occur external to the ring, as there the femoral vessels fill up the space, and strong partitions pass from the fascia transversalis to the fascia iliaca, one on the inner side of the vein, and another between it and the artery; these septa prevent the distention of the sheath; the fascia propria also rounds off the angle between the fascia transversalis and the forepart of the vessels, and prevents a hernia occurring in front of the artery or vein; external to these vessels the crural arch is completely closed by the close connexion between the fasciæ, lata, transversalis, and iliaca, to Poupart's ligament, in front of the psoas and iliac muscles. *Femoral hernia*, then, can occur only at the femoral or crural ring; this disease is more frequent in the female than in the male, the crural arch and ring being larger in the former than in the latter; femoral hernia descends through a sort of canal which commences at the crural ring, and ends at the saphenic opening in the fascia lata, narrowing as it descends; this canal is but the internal portion of the crural, or femoral sheath, and is separated from the femoral vein by the internal septum before described; it is occupied by cellular tissue, lymphatic vessels, and very frequently by a gland; it is closed above by the crural septum, or fascia propria, and below and in front by the cribriform fascia; although it descends as low as the entrance of the saphena into the femoral vein, it does not follow that when a crural hernia enters this canal, it should descend to this point before it comes forward; some writers have affirmed that it does; my own experience, however, both in the living and the dead, induces me to doubt this, for I have found that the tumour had forced through the inner side of the canal at a point much higher than this. The hernial sac, in descending, carries before it the fascia propria, descends in the sheath of the vessels along the inner side of the vein, and may remain in this situation for a considerable time; as the tumour increases in size it bursts through the sheath, and either tears or dilates some opening in the cribriform fascia, and then turns forwards into the groin; if the tumour increase still further it is found to turn upwards over Poupart's ligament between the superficial and deep fasciæ of the abdomen, and to rest on the lower part of the tendon of the external oblique, generally in the direction of Poupart's ligament, and therefore there is often some difficulty in distinguishing between a femoral and an inguinal hernia; the form of the crural ring, the course of the superficial epigastric vessels, the close connexion between the superficial and cribriform fasciæ, together with the frequent flexion of the limb, account for its ascending in this manner. If we dissect off the integuments from a femoral hernia of long standing, we shall find beneath them the superficial fascia, often so increased in thickness and vascularity as to present a compact and almost fleshy-like appearance; when this shall have been divided, the tumour can be brought down off the abdomen into the groin, and will be found covered by a dense and smooth capsule, which often pre-

sents a glossy appearance; this is the fascia propria; in dissecting off this, it will in general be found to consist of several laminæ, which sometimes separate so easily and appear so distinct as to lead an inexperienced operator to suppose that the hernial sac itself is exposed. These, then, are the coverings of the sac, which is thus placed external or superficial to the fascia lata: the neck of the sac, however, it is to be recollected, lies deep within the sheath of the vessels, and is, therefore, covered by the fascia transversalis, by the superior cornu of the falciform process of the fascia lata, and by the reflected fibres of Poupart's ligament passing backwards and inwards to their pubic insertion. Let the student now review the dissection that has been made; let him move the thigh in different directions, and he will remark that, when it is rotated inwards, Poupart's and Gimbernaut's ligaments, as well as the fascia lata, feel relaxed, and that the crural ring will become larger or more dilatable; let him also observe the relation of the femoral vein, the epigastric vessels, and the spermatic cord, or round ligament, to this opening; pass up the finger from the groin into the crural ring, and suppose that the stricture on femoral hernia was seated there, and that this opening required to be dilated, he will now perceive that this may be done with most safety, by directing the edge of the bistoury forwards and a little inwards, so as to divide the external edge or base of Gimbernaut's ligament, which edge is composed of the insertion of the superior cornu of the falciform process of the fascia lata. The stricture on femoral hernia may be, however, and I believe very often is, seated lower down than in the neck of the sac; it may be situated in that opening of the cribriform fascia through which the hernial sac has protruded; in such a case, the stricture may be easily divided by directing the edge of the knife directly inwards along the surface of the pectinæus muscle; or it may be caused by the superior cornu of the falciform process of the fascia lata twisting in from the forepart to the inner side of the tumour; the exact position of the stricture can only be known during the operation; in whatever tissue it is seated it is only necessary to pass the bistoury guided by the tip of the finger beneath it, and, turning the edge towards it, to press gently against it; this will, I believe, in all cases, effect a safe division, and one sufficiently free for all practical purposes.*

* The following measurements of the parts engaged in or referred to in the foregoing account of the anatomy of inguinal and femoral hernia have been extracted from Sir Astley Cooper's valuable work on hernia, and have been sanctioned by several other writers on the same subject: I have tested these very frequently, and though I can bear testimony to their general accuracy, I must observe, I have found deviations to have occurred so frequently, and in cases where there was no *a priori* reason to expect such, that I do not consider these numbers as facts of much value or of any material practical importance.

| | Male. | Female. |
|---|---|---|
| From the symp. pubis to the ant. sup. spinous process of the ilium, | $5\frac{3}{4}$ in. | 6 in. |
| ,, ,, to the tuberosity of pubis, . . . . . . . | $1\frac{1}{8}$ | $1\frac{3}{8}$ |
| ,, ,, to the inner margin of ext. abdominal ring, | $0\frac{7}{8}$ | 1 |
| ,, ,, to the inner edge of internal abdom. ring, . | 3 | 3 |
| ,, ,, to the middle of iliac artery, . . . . . . . | $3\frac{1}{4}$ | $3\frac{3}{8}$ |
| ,, ,, to the middle of iliac vein, . . . . . . . | $2\frac{3}{8}$ | $2\frac{3}{4}$ |

# SECTION II.

## DISSECTION OF THE VISCERA OF THE ABDOMEN.

The abdomen is the largest cavity in the body; it is of an oval form; its capacity, and in some degree its figure, differ at different ages, and in different subjects; it is bounded superiorly by the diaphragm, anteriorly and laterally by the abdominal muscles, inferiorly by the true and false pelvis, and posteriorly by the lumbar vertebræ, the crura of the diaphragm, and the psoæ and quadrati lumborum muscles. Although the expression "cavity of the abdomen" is in common use, it is not correct, for during life there is no cavity, as the diaphragm and abdominal muscles, by their alternate action, keep up such a constant and uniform pressure on the viscera, that these and the parietes are always in perfect contact. The abdomen contains the peritonæum and the organs of digestion; the kidneys, renal capsules, and ureters; also the lacteals, or absorbent vessels, with their glands, and the thoracic duct, the sympathetic nerves, the aorta, vena cava, and the numerous branches of these vessels. The abdomen is generally divided by writers into nine, but by some into twelve regions; by drawing two transverse lines, one between the extremities of the cartilages of the ninth or tenth ribs, and the other between the anterior superior spinous processes of the ossa ilii, we may define three regions; the *epigastric* above, the *umbilical* in the middle, and the *hypogastric* below; and then by drawing a vertical line on each side from the extremity of the eighth or ninth rib to the centre of Poupart's ligament, or a little external to it, we shall subdivide each of these regions into three parts; the three divisions of the epigastric region are the *epigastrium*, or scrobiculus cordis, in the centre, and the *right* and *left hypochondriac regions* on either side: the epigastrium is immediately below the ensiform cartilage, and the hypochondriac regions are covered by the false ribs; the lateral portions of the *umbilical* division are the *lumbar regions;* the middle of the hypogastric region is the *hypogastrium*, and the lateral portions are the *iliac regions;* the lower part of the hypogastrium is called by some the *pubic region*, and the lower

| | Male. | Female. |
|---|---|---|
| From the symp. pubis to the origin of epigastric artery, . . . . | 3 | $3\frac{1}{4}$ |
| " " to the epig. art. on the inner edge of ext. abdom. ring, . . . . . . . . . . . | $2\frac{3}{4}$ | $2\frac{7}{8}$ |
| " " to the middle of lunated edge of fascia lata, | $3\frac{3}{4}$ | $2\frac{3}{4}$ |
| " " to the middle of crural ring, . . . . . . . | $2\frac{1}{4}$ | $2\frac{3}{8}$ |
| From ant. edge of crural arch to saphena major vein, . . . . . | 1 | $1\frac{1}{4}$ |
| From symp. pubis to centre of orifice of femoral hernial sac, . . | 2 | $2\frac{1}{8}$ |
| From centre of orifice of do. to external iliac artery, . . . . . . | 1 | $1\frac{1}{4}$ |
| " " to centre of ext. iliac vein, . . . . | $0\frac{3}{4}$ | $0\frac{3}{4}$ |
| " " to origin of epigastric artery, . . . | $0\frac{3}{4}$ | 1 |
| " " to inner edge of int. abdominal ring, | 1 | $1\frac{1}{8}$ |
| From tuberosity of pubis to centre of orifice of fem. hernial sac, . | 1 | $1\frac{1}{8}$ |

(*Anat. and Surg. Treatment of Abdom. Hernia, by* Sir A. Cooper, Bart., *2nd Edit. by* C. A. Keys.)

part of each iliac division is called *inguinal region*, or more properly *spermatic* (the term inguinal being commonly applied to the upper and anterior part of the thigh), and contains the iliac vessels, and in

*Fig.* 42.*

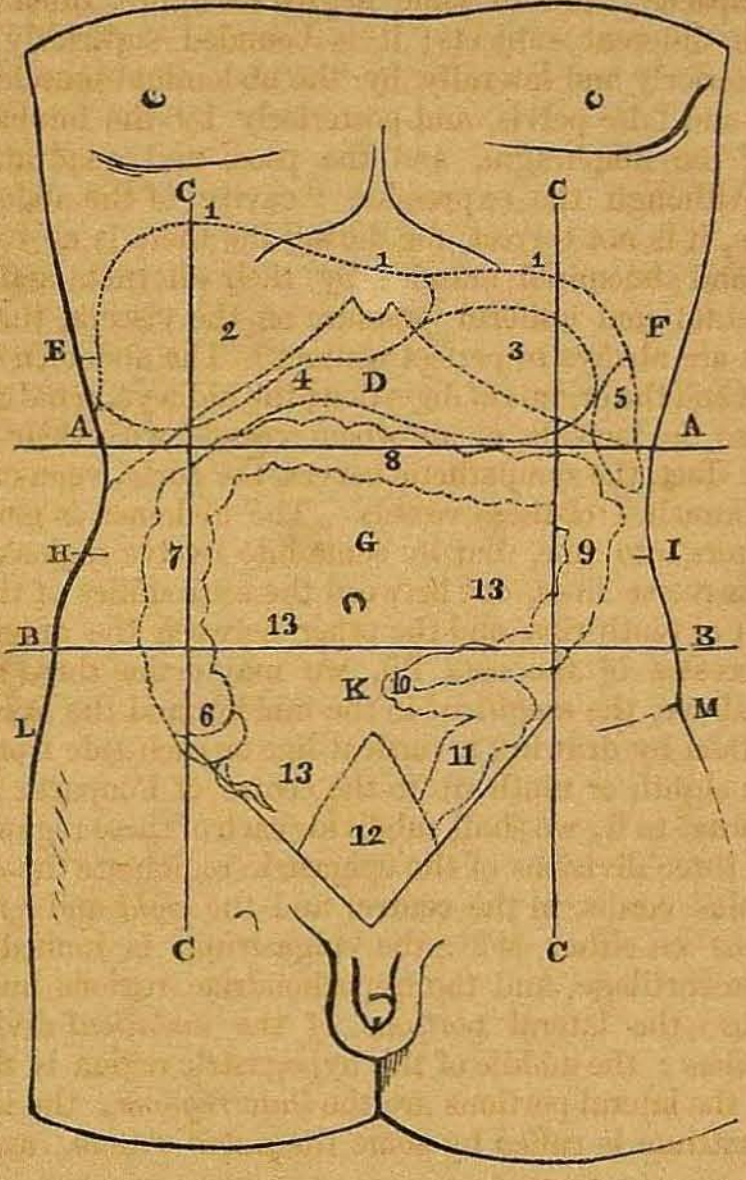


* The anterior surface of the abdomen, divided into nine regions. The dotted lines indicate the situation of the different viscera. A.A. A horizontal line extending from one side of the base of the thorax to the other. B.B. Another horizontal line extending from one iliac crest to that of the opposite side. C.C.C.C. Two vertical lines passing on each side over the anterior superior spinous process of the ilium, and extending to the base of the chest. D. The epigastrium or scrobiculus cordis. E. The right hypochondriac region. F. The left hypochondriac region. G. The umbilical region. H. The right lumbar region. I. The left lumbar region. K. The hypogastrium. L. The right iliac region. M. The left iliac region. 1. 1. 1. Line marking the upper surface of the diaphragm. 2. The liver. 3. The stomach. 4. The commencement of the duodenum. 5. The spleen. 6. The cæcum. 7. The ascending colon. 8. The transverse colon. 9. The descending colon. 10. The sigmoid flexure of the colon. 11. The commencement of the rectum. 12. The distended bladder. 13. 13. 13. Regions occupied by the small intestines, which have been omitted to avoid the confusion of lines.

the male the spermatic cord, and in the female the round ligament of the uterus. These divisions are somewhat arbitrary, there being no natural or fixed boundaries to these several compartments. The viscera, which constantly or occasionally occupy these several regions of the abdomen, will be seen when the peritonæal cavity has been opened, and with these the student should make himself familiar, as this knowledge may be of practical importance in cases of wounds penetrating this cavity, or in making an examination during life to detect any suspected organic disease. Dissect the abdominal muscles off the peritonæum; these can be easily separated laterally and inferiorly, but anteriorly, particularly near the umbilicus, it will often be found very difficult to detach the sheath of the rectus from this membrane, particularly in the adult or aged. The external surface of the peritonæum, which is thus exposed, appears rough and cellular, from its connexion to the superincumbent muscles; three ligamentous cords are seen extending along it anteriorly and inferiorly, from the summit and sides of the urinary bladder towards the umbilicus; the central one of these is the remains of the urachus, and that on each side is the obliterated umbilical or hypogastric artery; anteriorly and superiorly we perceive another ligamentous substance, ascending from the umbilicus obliquely backwards, and to the right side; this is the remains of the umbilical vein; it is at first placed between the peritonæum and the muscles, but it soon sinks deep towards the liver, carrying around it a fold of peritonæum, named the suspensory, or falciform ligament of the liver, which will be seen when the peritonæum is opened; the epigastric vessels also may be observed ascending from each inguinal region, and branches of the internal mammary arteries descending on the surface of this membrane. Next open the peritonæum by an incision from the ensiform cartilage to the umbilicus, and from this point carry another on each side obliquely downwards, to the spine of the ilium: on throwing down the inferior flap thus formed, we remark on its internal surface the projections of the three ligamentous cords, which were before noticed as ascending from the bladder to the umbilicus; we may also remark how the external of these cords, or the obliterated umbilical artery on each side, throws the lower part of the peritonæum into pouches, two on each side, the *external* and *internal inguinal pouches* or *fossæ;* the former lies between the ilium and the obliterated hypogastric vessel, the latter between this cord and the fundus of the bladder. The external pouch is large and very concave internally, and appears to protrude towards the inguinal canal: the existence of this pouch may conduce to the production of oblique inguinal as well as of femoral hernia: the internal pouch lies behind the external ring, and becomes protruded in direct or ventro-inguinal hernia; femoral hernia, also, sometimes, though rarely, protrudes this pouch. On raising the superior flap of the peritonæum, we see the remains of the umbilical vein, like a white thick cord, extending upwards and backwards to the edge of the liver, and carrying around and behind it the duplicature of the peritonæum,

named the falciform ligament of the liver. When the peritonæum has been fully opened, we perceive its inner surface smooth and polished; this, as in all other serous membranes, is the seat of constant exhalation and absorption; filling its cavity we also see the numerous digestive organs; these, though apparently within this bag, are really behind it, and only protrude the posterior side of this large sac into its cavity; nothing is contained within the peritonæum but the serous fluid, which is constantly exhaled, for the purpose of lubricating its opposite sides. We also obtain a partial view of the following organs, which in general occupy the same situation during life as we perceive them now to hold. Filling the right hypochondrium is the liver, with the fundus of the gall bladder projecting a little below it. In the epigastric region we see a portion of the liver also, resting on the stomach, and below this the pylorus and the commencement of the duodenum; in the left hypochondrium lie the spleen and great extremity of the stomach; in the right and left lumbar regions we find the colon, ascending through the former, and descending through the latter, behind which is each kidney; the duodenum also partly occupies the right lumbar region; through the proper umbilical region the transverse colon runs, not fixed, however, in any particular part of it, and from this intestine we perceive the great omentum descending towards the lower part of the abdomen, presenting, however, very different appearances in different subjects; in some, being expanded over the small intestines so as nearly to conceal them; in others, being coiled up into a narrow fold, and often concealed in some recess between the surrounding viscera: the convolutions of the jejunum and ilium intestines occupy the lower part of the umbilical, and extend indifferently into the hypogastric and iliac regions; the cæcum, or caput coli, is fixed in the right, and the sigmoid flexure of the colon in the left iliac fossa; the rectum and other pelvic viscera occupy the hypogastric regions, but will, of course, change their own situation, as well as that of the small intestines, according as they are contracted or distended. The student may next examine the anatomy of the *peritonæum;* this is the largest serous membrane in the body; it lines the abdominal muscles, and covers almost all the abdominal viscera; that portion which adheres to the parietes is called the *parietal*, and that covering the viscera the *visceral layer.* The peritonæum is a shut sac, and therefore, when opened, presents one continued surface, which may be traced throughout the whole extent without any interruption; it covers the viscera in such a manner as that they lie external, or posterior to it; the familiar example of the double nightcap on the head has been, not unaptly, adduced, to explain how the viscera may be covered by the peritonæum, and yet really lie beneath it or behind it. Let us now trace this membrane through its entire extent, commencing at the umbilicus; from the transverse incision that was made into it in this situation, we may perceive it to ascend on the internal surface of the transverse and recti muscles, as high as the margin of the thorax; then bending backwards it adheres to the inferior surface of the diaphragm, and continues very far back on

*Fig. 43.**

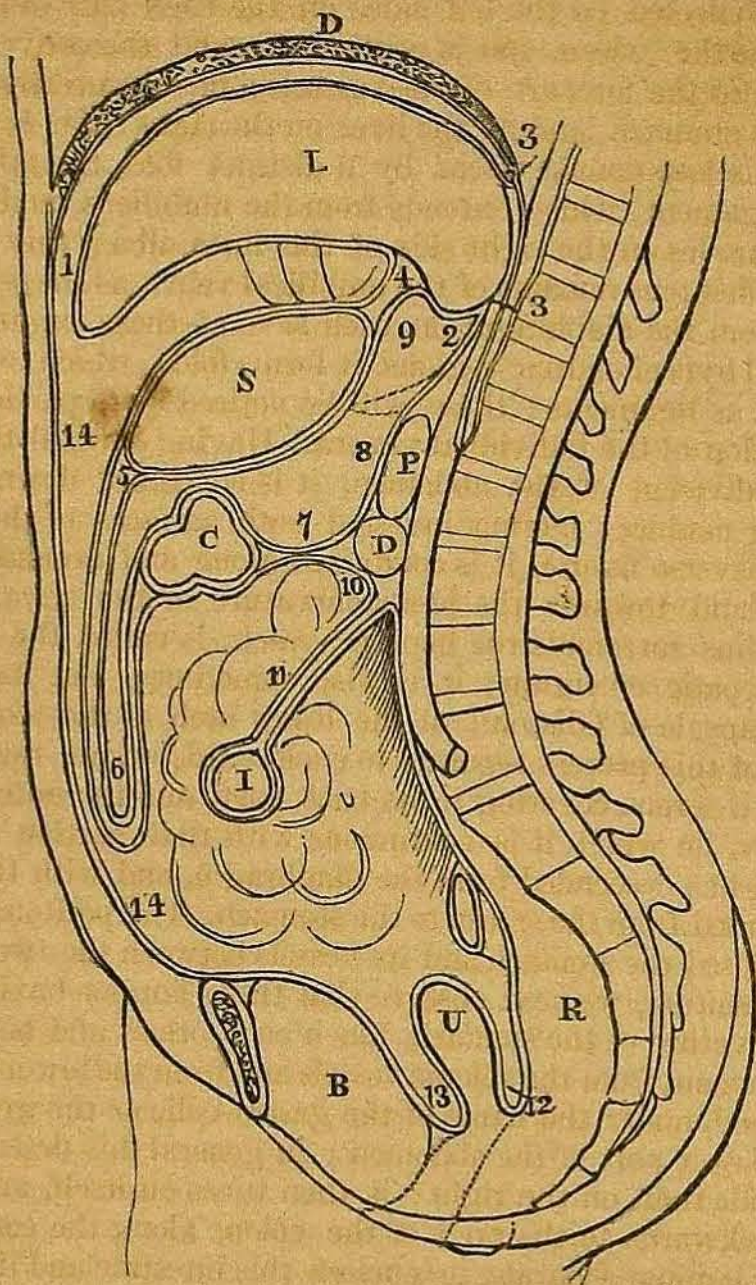


* A vertical section of the abdominal cavity and viscera, made along the median line to shew the reflections of the peritonæum. D. The diaphragm. L. The liver. S. The stomach. C. The transverse colon. D. The inferior transverse duodenum. P. The pancreas. I. The small intestines. R. The rectum. B. The bladder. V. The uterus.

1. The layer of peritonæum lining the inferior surface of the diaphragm. 2. The posterior layer. 3. 3. The two layers passing to the posterior border of the liver, and forming the coronary ligament. 4. The lesser or gastro-hepatic omentum, the two layers passing from the transverse fissure of the liver to the lesser curvature of the stomach. 5. The two layers meeting at the great curvature of the stomach, descending to the lower part of the abdomen, then turning on themselves and ascending to the transverse arch of the colon, thus forming 6. The great omentum. 7. The transverse meso-colon. 8. The ascending layer of the transverse meso-colon, passing in front of the duodenum and pancreas, to become continuous with the posterior layer, 2. 9. The foramen of Winslow. 10. The descending layer of the transverse meso-colon, passing downwards over the small intestines and their vessels, and returning along them to the spine, thus forming 11. The mesentery. 12. Reflection of peritonæum from the rectum to the back part of the vagina and uterus. 13. The continuation of this layer

this muscle, particularly in the left hypochondrium ; from the diaphragm it is reflected on the left side, on the back part of the splenic vessels, and of the spleen, and is continued round the convex surface of this organ to the forepart of its vesssels; more centrally it is reflected on the stomach, and on the liver on the right side; it is also reflected on this last-named viscus by a distinct fold, the falciform, or suspensory ligament, which extends from the umbilicus, and from the abdominal muscles on the right side of the linea alba; this fold contains the ligamentous remains of the umbilical vein : as the peritonæum is reflected from the diaphragm on each side of these organs in the epigastric and hypochondriac regions, it forms folds, which to a certain extent, serve as ligaments; these will be noticed more particularly in the examination of the individual viscera. Having covered the organs in the upper division of the abdomen, it is continued downwards in the following manner; having invested both surfaces of the liver as far as its transverse fissure, it is conducted along and around the vessels of this gland towards the lesser curvature of the stomach; this fold, which thus surrounds the hepatic vessels, is called the lesser or the gastro-hepatic omentum; it is also sometimes, but incorrectly, named the capsule of Glisson ; at the lesser arch of the stomach the two laminæ of this process separate to enclose this organ, the posterior layer giving a serous covering to its back part, and the anterior layer to its forepart, on which it is continuous with that portion of peritonæum which has descended from the diaphragm, and with that which is also continued from the spleen to the stomach. The peritonæum having thus enclosed the stomach and its vessels between the two layers of the lesser omentum, we next observe that these laminæ having passed the great curvature of the stomach, touch each other, and being joined by the peritonæum from the splenic vessels and from the lower end of the spleen, descend, under the name of the gastro-colic or the great omentum, to the lower part of the abdomen ; in general this descends lower on the left side than on the right; it then turns on itself, and ascends obliquely backwards to the arch of the colon, along the convex edge of which its laminæ separate to enclose this intestine and its vessels ; along the concave edge of the colon these laminæ again unite, and, increasing in density, form that process which is called the transverse meso-colon, which passes backwards to the spine : opposite the duodenum this process separates into an ascending and descending layer; the inferior division of the duodenum lies between these; the ascending layer proceeds in front of the lower and middle divisions of the duodenum and of the pancreas, to the back part of the right lobe of the liver, where it becomes continuous with the peritonæal tunic of that viscus, and with the posterior layer of the lesser omentum, which is de-

from the forepart of the uterus to the back of the bladder. 14. 14. The same layer passing from the superior fundus of the bladder to the abdominal muscles, on the inner surface of which it may be traced up to 1, on the inferior surface of the diaphragm.

scending along the back part of the hepatic vessels. The descending layer of the transverse meso-colon expands into each lumbar region, in which it attaches the lumbar portions of the colon by a duplicature, very variable in extent, called the right and left lumbar meso-colon; in the centre the inferior layer of the transverse meso-colon

*Fig.* 44.*

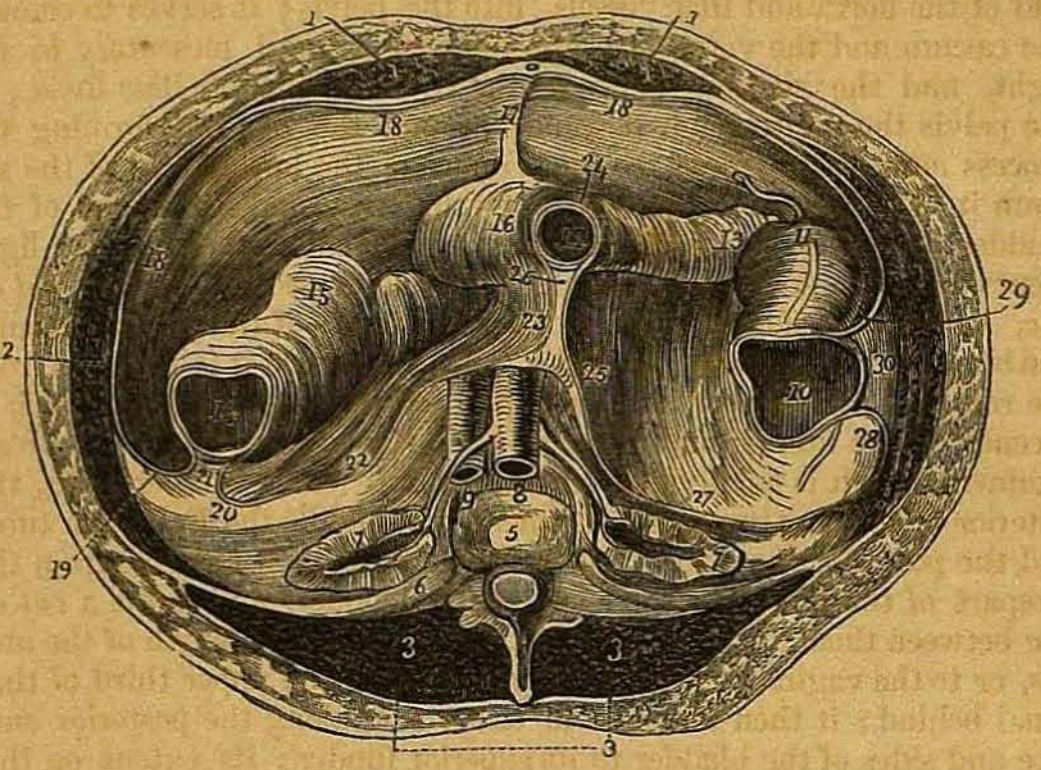


* A transverse section of the abdomen, shewing the manner in which the peritonæum forms the mesentery, and covers the intestines without inclosing them in its cavity; the section passes through the body of the last dorsal vertebra, obliquely downwards and forwards to a little below the umbilicus. Nearly the entire of the small intestines has been removed. 1. 1. Sections of the recti muscles of the abdomen. 2. A section of the external oblique, internal oblique, and transversalis muscles. 3. Section of the lumbar mass of muscles. 4. Spinous process of twelfth dorsal vertebra. 5. The body of the twelfth dorsal vertebra. 6. The twelfth rib. 7. Transverse section of the kidney. 8. The inferior vena cava. 9. The abdominal aorta. 10. The right or ascending colon cut transversely. 11. The cæcum and appendix vermiformis, as seen from above. 12. The ileum cut transversely. 13. Its termination in the cæcum. 14. The descending colon at its sigmoid flexure divided transversely. 15. the upper part of the rectum. 16. The superior fundus of the bladder, covered by the peritonæum. 17. The urachus raising up the peritonæum in the median line, as it passes to the umbilicus. 18. 18. 18. The peritonæum lining the anterior and lateral walls of the abdomen. 19. The peritonæum leaving the abdominal wall to envelope the left lumbar colon. 20. The peritonæum returning to the abdominal wall, thus forming 21. The left lumbar meso-colon. 22. The continuation of the same layer of peritonæum passing in front of the left kidney, renal vessels, abdominal aorta, and inferior cava. 23. The peritonæum leaving the great vessels, enveloping the ileum, 24. and returning to the spine, 25. thus forming 26. The mesentery. 27. The peritonæum passing in front of the right kidney to the lateral wall of the abdomen. 28. The same layer leaving the lateral wall to envelope the right lumbar colon. 29. The peritonæum leaving the colon to reach the lateral wall, thus forming 30. The right lumbar meso-colon. From this point the peritonæum may be traced along the internal surface of the lateral wall to 18. where its description commenced.

adheres to the vertebral column, and to the great vessels which lie upon it, and is thence reflected forwards and downwards, over the small intestines and their vessels, and returns around these to the spine, thus forming a very important and remarkably folded, or plaited process, named the mesentery. From the inferior surface of the mesentery the peritonæum extends laterally into either iliac region, and in the middle it descends, in front of the sacro-vertebral prominence, and of the aorta and iliac vessels, into the pelvis; it serves to connect the cæcum and the vermiform appendix by a small mesentery in the right, and the sigmoid curve of the colon in the left iliac fossa; in the pelvis the peritonæum descends around the rectum, forming the process named the meso-rectum; opposite the lower third of the sacrum it is reflected, in the male, to the lower and back part of the bladder, forming two lateral semilunar folds, called the posterior ligaments of the bladder, between which it is depressed into a deep *cul de sac*, which descends to within a short distance of the prostate gland, and between the vesiculæ seminales. In the female it is reflected from the rectum to the upper and back part of the vagina, from which it ascends on the uterus, and forms on each side of this organ the broad ligament which is subdivided superiorly into three smaller folds, the anterior containing the round ligament, the middle the Fallopian tube, and the posterior the ovary; the peritonæum is then reflected from the forepart of the uterus to the back of the bladder, and forms a *cul de sac* between them; it has no connexion to the lower fourth of the uterus, or to the vagina in front, though it covers the upper third of that canal behind; it then ascends, in either sex, along the posterior surface and sides of the bladder to its superior fundus; its extent on this organ is very variable, according as the latter is empty or distended; when it is contracted the peritonæum descends behind the pubis, but when distended it rises into the abdomen, pushing the peritonæum above it, and comes into cellular contact with the lower portion of the recti; from the bladder and from the iliac fossæ it is continued to the abdominal muscles, and may then be traced on the inner surface of the recti and transversi up to the umbilicus, where the sac was opened; between the pubis and this point it is raised by the ligamentous remains of the urachus and umbilical arteries into three falciform folds, whereby the four inguinal pouches are formed. Although the peritonæum has been thus traced as one uninterrupted surface, a sac without an opening, yet there is an exception to this statement; in the female pelvis, the serous and mucous membranes are continued into one another through the open fimbriated extremities of the Fallopian tubes; this, which is the only exception in the human body to the perfectly closed condition of serous membranes, is somewhat analogous to the lateral anal openings in the abdomen of many fish, whereby the peritonæal cavity communicates by an oblique passage on either side with the surface of the body; in the human female, however, these fimbriated extremities are probably closed at all times except when in contact with, or adhering to the ovaries; if such be the case, the serous membrane is still a shut sac, and the exception is more an apparent than a

real one; during life we never find the water in ascites escaping by these channels, neither in the dead body air or fluid when injected into the peritonæum. The different folds which the peritonæum forms in this course are termed processes, the principal of which, in addition to the ligaments of the several organs which shall be noticed in the description of the latter, are the lesser omentum, the great omentum, the splenic omentum, the colic omentum, the appendices epiploicæ, the transverse, and the right and left lumbar meso-colons, the mesentery, meso-cæcum, and meso-rectum.

The *lesser*, or *gastro-hepatic omentum*, consists of two laminæ, which extend from the transverse fissure of the liver to the lesser curvature of the stomach and to the upper part of the duodenum; it contains between its layers the vessels of the liver, viz., the hepatic artery to the left side, the ductus choledochus to the right, and the vena porta behind and between both; at its connexion to the stomach it encloses the coronary vessels of this organ; the lesser omentum lies anterior to the foramen of Winslow; it seldom contains much adipose substance.

The *great* or *gastro-colic omentum* consists of four laminæ, that is, of two descending, and two ascending; the former descend from the lower end of the spleen, and from the anterior and posterior surfaces of the stomach; between these laminæ are several long and tortuous vessels, descending from the vessels of the stomach, between its two anterior laminæ, to its lower border; they then turn up and ascend between its two posterior layers as far as the colon, on which intestine they anastomose with the colic arteries; between these laminæ also is some adipose substance, the quantity of which varies very much in different subjects; it is chiefly deposited along the blood-vessels, and often amounts to a considerable quantity in the adult; in the child the omentum is usually very thin and free from fat; in the adult also it is often cribriform, or very thin and transparent; in extent also, as well as in structure, it is very variable: the omenta are the only portions of this serous membrane visibly supplied with bloodvessels; the finest injections demonstrate a network of capillaries external to the membrane, but these never permeate it, so as to appear on the serous surface; it is difficult, therefore, to account for these omental arteries; they may maintain some useful anastomosis between the gastric and colic arteries; they exist in the omentum of the young, where there is as yet little or no adipose deposit; in fact, although the omentum is anatomically traced as a continuation of the peritonæum, it yet appears a totally different structure when minutely examined by the microscope, as well as when regarded physiologically or pathologically; various opinions are entertained as to its uses or functions, but it appears to me to be wiser to admit that these are still unknown. The great omentum descends in front of the large and small intestines to the lower part of the abdomen, in general lower on the left than on the right side; (this explains the reason why the omentum is more frequently found in a hernial sac on the left than on the right side); it then turns upwards and backwards

until it reaches the transverse arch of the colon; that portion of omentum, therefore, which is inferior to the colon, consists of four laminæ, two descending and two ascending; these, though shorter in the very young subject than in the adult, can often be separated from each other, and a distinct cavity can be seen between them; this is part of the cavity or bag of the omentum which communicates with the general cavity of the peritonæum by the opening of Winslow, and which will be more particularly described presently; at the arch of the colon the two ascending laminæ of the great omentum separate to enclose this intestine, and, again uniting, form the commencement of the following process.

The *transverse meso-colon* extends from the concave border of the arch of the colon backwards to the spine; this process is very strong and dense, it encloses the vessels of the colon, and forms a sort of division or partition in the abdomen, between the epigastric and umbilical regions, the former containing the true digestive organs, the latter those of nutrition; no communication can take place between these except that through the duodenum, and altogether behind the peritonæum: when the transverse meso-colon has arrived at the spine, its two laminæ separate, one descends the other ascends; the descending layer is very strong, expands laterally into the right and left lumbar regions, in each of which it is reflected either partially or perfectly around the ascending and descending colon, and thus forms a short fold or process very irregular in different subjects, termed the *right* and *left lumbar meso-colons;* this inferior, or descending layer of the transverse meso-colon is also continued obliquely downwards in the middle line to form the mesentery, a process which we shall trace when we have pursued the superior, or ascending layer of the meso-colon to its termination. This lamina is thin and delicate; it ascends in front of the inferior and middle portions of the duodenum, and of the pancreas; it also covers the aorta and vena cava, and continues along this latter vessel to the liver, on the Spigelian lobe of which it expands, and on it and on the right lobe, behind the foramen of Winslow, it becomes continuous with the peritonæum, which has been reflected on the back part of the liver from the diaphragm. As this ascending layer proceeds in front of the pancreas, it is continuous on each side with the posterior layer of the lesser omentum which covers the back part of the stomach. This ascending layer may be best seen and traced by dividing the great omentum a little below the stomach, and raising this organ towards the thorax; we shall thus lay open the cavity of the omentum, and shall be able to trace the parietes of this bag through their whole extent.

The *cavity or sac of the omentum* extends from the transverse fissure of the liver superiorly, to the lower border of the great omentum inferiorly; it is bounded anteriorly by the lesser omentum, the stomach, and the anterior or descending portion of the great omentum; inferiorly it is formed by the great omentum turning on itself; and posteriorly it is bounded by the ascending portion of the great omentum,

by the colon, by the transverse meso-colon, and by the superior, or ascending, layer of this process, which terminates at the liver. The cavity of the omentum communicates with the general peritonæal cavity through the foramen of Winslow; this opening is situated in the lower part of the right hypochondriac region, just above the right lumbar; it is somewhat oval, bounded anteriorly by the lesser omentum which encloses the vena porta, and the hepatic duct and artery, posteriorly by the termination of the ascending layer of the meso-colon which invests the vena cava, superiorly by the lobulus caudatus of the liver, and inferiorly by the superior portion of the duodenum. If the membrane composing the omenta be perfect, and if air be forced through this opening, it will descend behind the stomach, and will inflate the omental cavity; the great omentum, however, in general, is so cribriform that this experiment cannot be performed; the principal use of this cavity is most probably to afford a serous surface, or cavity for the stomach to move in, or to distend into posteriorly during the progress of digestion.

The *splenic omentum* extends from the fissure in the spleen to the great end of the stomach, and is continuous with the anterior layer of the great omentum; the splenic vessels and the vasa brevia are contained between the laminæ of this process.

The *colic omentum* is a fold of peritonæum which descends from the upper part of the right or ascending colon; it generally lies posterior to the great omentum; it is composed of two laminæ, between which are contained blood-vessels and adipose substance.

The *right and left lumbar meso-colons* are folds connecting the ascending and descending colons in the lumbar regions; these are usually very imperfect, or open posteriorly, so that the back part of this intestine in each lumbar region is uncovered by peritonæum, and is connected by cellular tissue to the kidney; the right colon is usually more uncovered by it on this aspect than the left, and is there also in contact with the duodenum; both are also connected to the quadratus lumborum muscles.

The *appendices epiploicæ* are attached all along the large intestine, but principally to the transverse arch of the colon; they are small prolongations of the peritonæum, filled with a soft fatty substance; they are never found attached to the small intestine; they vary very much in different subjects in number and size; their use is not ascertained.

The *mesentery* is the largest and most remarkable process of the peritonæum; it is continuous with the descending layer of the meso-colon, and extends from the left side of the second lumbar vertebra obliquely downwards to the right iliac fossa; this is the root of the mesentery; from this it expands very much, and is folded round the jejunum and ileum intestines, and then returns again to the spine or to the inferior surface of the root; the laminæ of the mesentery can be easily separated; between them we find the mesenteric arteries, veins, and nerves, also numerous absorbent vessels and glands; the mesen-

tery serves to support the convolutions of the small intestines and the numerous vessels passing to and from these.

The *meso-cæcum* is a fold of peritonæum which attaches the cæcum to the right iliac fossa; this process, however, is freqently imperfect; the posterior portion of this intestine being often deprived of a serous coat, and connected to the iliac muscle by cellular membrane.

The *meso-rectum* is a short fold of peritonæum which connects the superior portion of the rectum to the upper and anterior part of the sacrum; it encloses the hæmorrhoidal vessels and nerves.

The peritonæum covers the abdominal viscera in a very unequal manner, that is, some only partially or imperfectly, others almost entirely; no viscus can be wholly enveloped by it, as in every case some part must be free for the entrance and exit of its vessels, as these never perforate the membrane. The spleen, and the jejunum and ileum intestines, are among the most perfectly enclosed organs, as the peritonæum is unadherent only along the concave aspect of each, where the vessels and nerves are placed; next in degree are the stomach and the transverse colon, on each of these the membrane is unconnected along the convex as well as the concave aspect; on the liver also it is unattached at the great transverse fissure where the blood-vessels and nerves enter, and partially also along the convex or diaphragmatic border, where the veins escape from this organ; the gall bladder also is only partially covered by it, as it attaches this viscus to the liver, but does not pass between them; the right and left colons very generally want this coat posteriorly; the middle and inferior divisions of the duodenum are but loosely covered by it in front, and no part of the very termination of this intestine is attached to it, as the fasciculus of the superior mesenteric vessels is interposed; the lower portion of the rectum is in the same predicament; the urinary bladder, the pancreas, and kidneys are all but imperfectly covered by it; these facts are of some practical importance, and will be more particularly set forth in the description of the individual organs. The peritonæum effects several useful purposes: first, it enters more or less into the structure of the several viscera, and in some it serves as an important physical element; second, it assists in retaining the organs in a certain position, and in maintaining their different relations; third, it conducts the numerous vessels and nerves; fourth, it strengthens the walls of the abdomen, by adhering to and connecting together the muscular fasciculi of which they are chiefly composed; and lastly, by the exhalation of a lubricating fluid, it allows opposed surfaces to glide on each other without any sensible friction, it thereby facilitates the actions of the parietal muscles on the contained viscera, as well as the movements of the latter among one another.

The peritonæum is composed of the same elements as other serous membranes, namely, an external lamina which is similar to cellular or areolar tissue, containing the nutrient or functional vessels and nerves, and connected to the surrounding structure; and an internal layer, which is smooth, dense, and pearly, which appearance is sup-

posed to depend on the existence of a fine epithelium composed of innumerable laminæ of flattened vesicles with central nuclei.

The viscera contained in the abdomen are the digestive and urinary organs; the former we shall examine first. The digestive apparatus presents a series of connected or continuous organs, each of which is concerned in some especial manner in effecting certain changes on the food, whereby it becomes fit for the nutrition of the system. The term "digestion" is commonly confined to the operation of the stomach; but it should be more extensively applied, so as to include the successive changes which the food undergoes from its reception into the mouth until it is separated in the small intestines into the nutritive portion or chyle, which is there absorbed by the lacteals, and into the residuum, which is discharged by the large intestine. Indeed, in a physiological sense, the term might be still further extended, as the chyle, most probably, is not fully elaborated for nutrition until it has been duly mingled with the blood by the circulation of the latter, and along with it purified by the respiratory process. This function, then, properly includes the processes of mastication, insalivation, and deglutition, which last conveys the food into the stomach, where the next and decidedly the most interesting change takes place, that is chymification. In the duodenum chylification occurs; in the jejunum and ileum the chyme is separated and absorbed; and lastly the large intestine retains the residuum for convenience, and finally expels it from the body. The whole apparatus is one long canal, extending from the mouth to the anus, lined by mucous membrane or integument, which is continuous at either end with the general integument of the body. This tube presents various shades as to organization and physical characters in different situations; it is throughout generally well supplied with vessels and nerves, although, except in some situations, it presents but few traces of sensibility, at least in the ordinary sense of that term; it is covered throughout by laminæ of muscular fibres, which are eminently involuntary, excepting towards either extremity, where voluntary power, for obvious reasons, has been endowed: varied secretions are poured forth upon its surface, some from the folds and follicles which form part of its structure, others more elaborate are derived from organs at a distance, furnished with excretory ducts for the purpose of supply; indeed the greater portion of this tissue may be regarded as an expanded glandular membrane. The length of this canal is very considerable; it is uncertain, but probably about seven times that of the height of the body; it traverses the lower part of the face, the neck, and chest, is greatly complicated and extended in the abdomen, which it nearly occupies, also a great portion of the pelvis, and finally terminates in the anus, in front of the coccyx; in the neck it is in connexion with the respiratory, and in the pelvis, but not so intimately, with the genito-urinary apparatus. We have already examined the organs concerned in mastication, insalivation, and deglutition; we shall now proceed to that important and more voluminous portion of this apparatus which occupies the abdominal and a portion of the pelvic

*Fig. 45.**

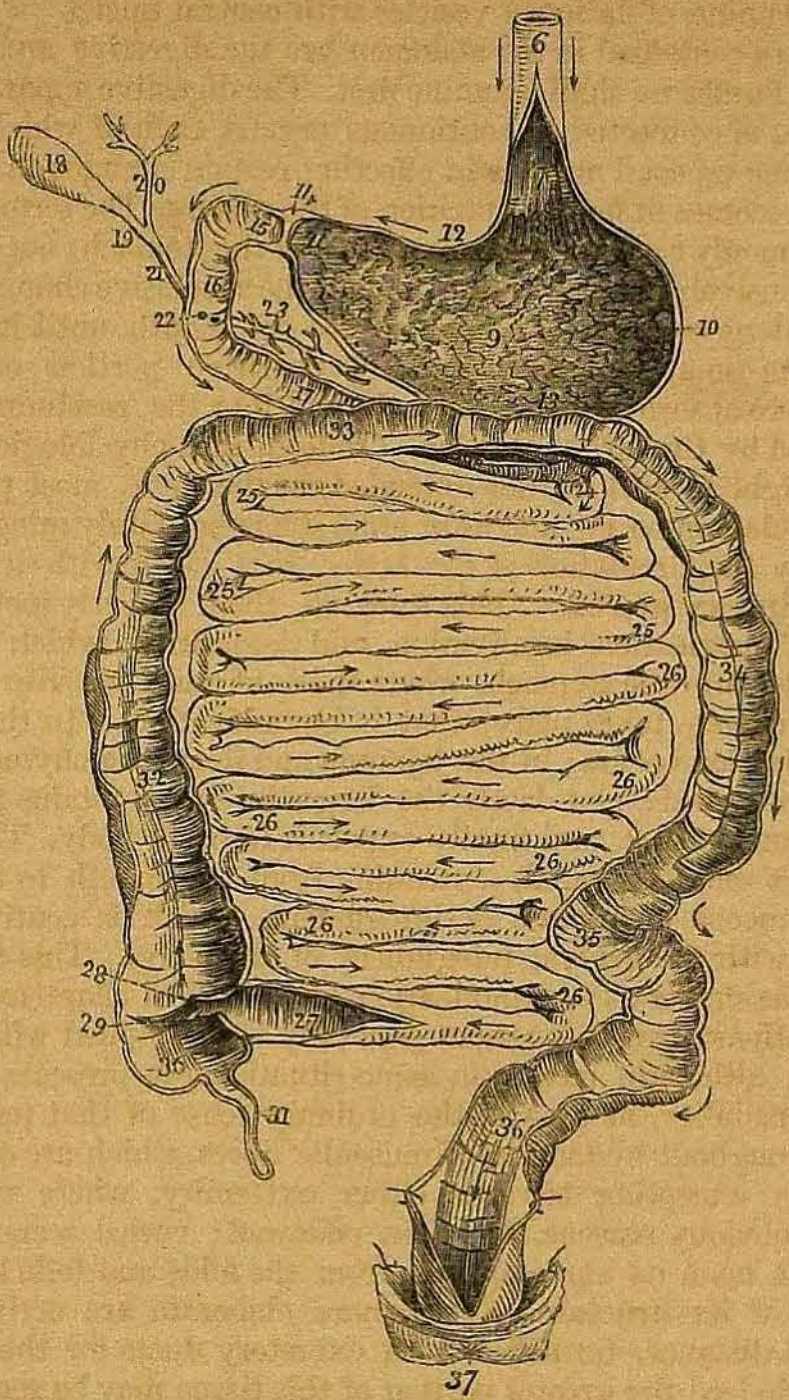


* The alimentary canal laid open from the lower extremity of the œsophagus to the rectum. 6. The œsophagus. 7. The internal surface of the œsophagus. 8. The cardiac or œsophageal orifice of the stomach. 9. The internal surface of the stomach. 10. The left or splenic extremity. 11. The right or pyloric extremity. 12. The lesser curvature of the stomach. 13. The greater curvature. 14. The pylorus. 15. The superior transverse portion of the duodenum. 16. The middle or perpendicular portion. 17. The inferior transverse portion. 18. The gall-bladder. 19. The cystic duct. 20. The hepatic duct. 21. The ductus communis choledochus. 22. Its aperture in the duodenum. 23. The duct of the pancreas dissected from the gland; its aperture in the duodenum is seen close to that of the ductus choledochus. 24. The commencement of the jejunum. 25. 25. The jejunum. 26. 26. The ileum. 27. The ileum opening into the great intestine. 28. The ileo-colic valve. 29. The ileo-cæcal valve. 30. The cavity of the cæcum. 31. The appendix vermiformis. 32. The ascending or right lumbar colon. 33. The transverse arch of the colon. 34. The left or descending colon. 35. The sigmoid flexure of the colon. 36. The rectum. 37. The anus.

cavity; it is composed of several viscera, which may be divided into the membranous or hollow, and the glandular or solid. The membranous viscera are the stomach and intestinal tube: the latter is divided into the small and large intestine: the small intestine is subdivided into the duodenum, jejunum, and ileum; the large intestine into the cæcum, colon, and rectum. The glandular viscera are the liver, spleen, and pancreas. We shall consider the membranous viscera first, and commence with the description of the *stomach*, which is the most important part of the apparatus, the principal change of the food being accomplished in this organ.

The *stomach* is the most dilated portion of the alimentary canal; its capacity is very variable, depending in part upon the degree of distension or contraction before death; it is placed between the œsophagus and the duodenum, and communicates with both; it is situated in the left hypochondriac and epigastric regions, and a small portion of it extends into the right hypochondrium: from the left side it passes across the epigastric region, obliquely downwards and forwards, and near its right or pyloric extremity it bends a little upwards and backwards. It is connected to the diaphragm by the œsophagus and by the peritonæum; to the spleen by the splenic omentum and vasa brevia; to the liver by the lesser omentum; and to the arch of the colon by the great omentum: it is, therefore, nearly a fixed viscus, and not liable to displacement, although it has been found drawn downwards in old and very large umbilical herniæ, also in cases of enlarged spleen. If the stomach be moderately distended with air or fluid, its form and connexions can be better understood; it will then appear somewhat of a conical figure, the base to the left side, the apex to the right, the intermediate part being somewhat curved; it will then also present two extremities, the left and right; two orifices, the cardiac and pyloric; two surfaces, an anterior or superior, a posterior or inferior; and two curvatures or edges, the lesser or concave, the greater or convex. The *left* or *splenic extremity* is very large (*great cul de sac*), swells into the left hypochondrium beneath the ribs, so as nearly to conceal the spleen. The right or *pyloric extremity* is much smaller, is cylindrical and slightly convoluted like an intestine: it lies anterior and inferior to the left or splenic end, and extends to the fundus of the gall bladder or to the edge of the lobulus quadratus of the liver; it sometimes descends into the umbilical region; it forms the apex of the general cone, and is distinguished from the duodenum by the circular contraction of the pylorus, a little to the left of which the stomach is often found somewhat dilated towards the convex border, into a sort of sinus or *cul de sac* (*antrum pylori*): sometimes also there is a smaller dilatation, nearly opposite to this, on the lesser curvature. The *cardiac* or *œsophageal orifice* is the highest point of the stomach; it is situated between the left or great end and the lesser curvature, about three inches distant from the former; it is surrounded by vessels and nerves, and is connected to the diaphragm by the peritonæum. The *pyloric orifice* is between the stomach and the duodenum; it lies to the right

side of the spine; it is moveable to a certain extent, its position is therefore variable; in general it is in contact with the liver and gall bladder, and is anterior to the pancreas and to the right epiploic artery; it is inferior, anterior, and to the right side of the cardiac orifice, has a peculiar firm, hard feel, and a constricted appearance. The angles at the cardiac and pyloric orifices are differently affected according as the organ is contracted or distended; in the former state there is no angle between the œsophagus and the stomach, whereas in the latter it may become even an acute one; the contrary is the case at the pyloric, during the empty state of the stomach this forms with the duodenum an acute angle, convex above; while, in the distended condition, the pylorus leads backwards and downwards into the duodenum: these alterations, in the form and aspect of these orifices, are in conformity with their respective functions. The *anterior surface* is below the xiphoid cartilage; it looks upwards and forwards, and is in contact with the diaphragm, the ribs, and the left lobe of the liver, and, when distended, with the abdominal parietes. The *posterior surface* looks backwards and downwards; it forms the front of the bag of the omentum, the cavity of which separates it from the meso-colon, pancreas, and duodenum. The lesser, or *concave edge*, looks backwards and upwards towards the spine and lobulus Spigelii of the liver; this edge, near the pylorus, is convex, the great edge being concave opposite to this; the lesser omentum is attached to it, and the coronary vessels run along it. The *great* or *convex edge* looks forwards and downwards towards the colon; to it the great omentum and the epiploic vessels are attached, and occasionally some lymphatic glands: in the empty or contracted state these edges are thin, and directed almost vertically, but when distended, they become enlarged and round, and continuous with the surfaces; the convex edge is then directed forwards as well as downwards towards the abdominal muscles, and the concave edge backwards and upwards towards the aorta and the spine.

The stomach is composed of *three proper tunics*—a serous, a muscular, and a mucous: these are connected to each other by laminæ of cellular membrane, which are regarded by some as the *common* tunics. The *serous* or *peritonæal coat* is derived, as was before explained, from the laminæ of the lesser omentum, separating at the lesser curvature, expanding over the surfaces, and uniting along the convex edge to form the great omentum; it is loosely united to the edges, but almost inseparably to the middle of each surface and to the pyloric extremity; along each edge or curvature a triangular space is left, to which this membrane does not adhere; that along the convex border is much the wider; these spaces are enlarged during the distension of the organ, and facilitate its expansion; whereas, if the peritonæum adhered in these situations as closely as to the surfaces, its want of extensibility would interfere with the sudden enlargement of the stomach. These spaces also afford a suitable enclosure for the blood-vessels; the coronary being contained in that along the lesser, and the epiploic in that along the greater curvature. A

layer of very fine subserous or cellular tissue connects this to the following tunic, the *muscular ;* this consists of fibres which run in three different directions; the first or superficial are longitudinal; they are continued from the longitudinal fibres of the œsophagus, are radiated and scattered over its surfaces, and are very strong along the curvatures, particularly on the lesser, the form of which they retain; some fibrous bands usually run superficial to these in the subserous tissue; these fibres are very strong near the pylorus; some end in its constriction, and others are continued on the duodenum. The middle layer of fibres run circularly; they commence at the left extremity, or *cul de sac*, and are arranged in nearly parallel rings; they are weak and few on the left end, but very strong to the right of the centre, where they often cause a constricted appearance around the stomach, as if dividing it into two portions. The circular fibres again increase in thickness as they approach the pylorus, the sphincter of which they form: these fibres do not form perfect circles, the extremities of each fasciculus turn obliquely to one side. The third set of fibres take a very irregular or oblique direction; they are most distinct on the great end, or *cul de sac*, and appear as a continuation of the circular fibres of the œsophagus, and run in loops or arches nearly parallel to the long axis of the stomach. The muscular coat of the stomach is very variable as to colour and development; it is usually pale, sometimes almost white and semi-transparent; along the curvatures, particularly the lesser, it is often not only strong, but very red, and sometimes contains a fibrous or tendinous band; it is always thin over the splenic end, or *cul de sac*, and much thicker at and near the pylorus; in general its strength is in an inverse ratio to the size or capacity of the organ. These several planes of fibres do not form so many distinct layers, but rather interlace, so as to form more or less of an areolar muscular tissue; the areolæ are large in the distended condition of the organ. Beneath the muscular tunic is the second lamina of cellular tissue, which contains the minute divisions of the nerves and vessels of the stomach, and has been, by some, called the nervous coat of the stomach. This coat is connected to the muscular by numerous processes or septa, and to the mucous by cellular tissue, vessels, and nerves; it is composed of a dense net-work of filaments and laminæ, which possesses considerable strength, so as to resist distension in the muscular areolæ. This tunic may be examined either by removing the serous and muscular, or, when the stomach has been everted, by raising a portion of the mucous membrane; in the fine cellular tissue, which connects this to the mucous or lining coat, is contained the net-work of capillary vessels for the supply of the latter: it gives support to the mucous membrane, and forms, as it were, the frame-work of the organ; and, therefore, some anatomists consider this tunic as the deep layer of the mucous membrane, and do not enumerate it among the distinct coats of the stomach. The internal or *mucous* coat, also called villous, from its soft, velvet-like appearance, is continuous with that lining the œsophagus and duodenum. In order to examine it the stomach should be removed from the subject, everted, or opened longitudinally, and washed

under a gentle stream of water, as it is usually covered with viscid, adhesive, mucous and alimentary matters. It presents, if recent and normal, a pale pink or rosy tint; but the shade of colour is very variable, and depends on many circumstances: in cases of sudden death, and the organ empty, it has been found of a pale red, but, if digestion had been in progress, of a more vivid tint; if some days have elapsed between death and examination, it often presents brown or black patches, chiefly in the splenic end and around the large blood-vessels; such patches are often soft, pulpy, and decomposed, and may be the effects of transudation of blood, or of putrefaction, or of solution by the gastric fluid. The shade of colour may also depend on the previous state of the organ, as to health or disease; on its state at the time of death, whether full or empty; and if in the former, on the nature of its contents, and the influence of the gastric fluid upon the latter; also on the presence of bile, &c. This membrane is always thrown into folds or rugæ, of which there are different species; the most prominent and numerous are nearly parallel to the long axis of the organ; some bend off tortuously from this direction; these rugæ are most distinct in the pyloric portion; they are obviously designed to admit of the rapid and easy distension of the stomach, particularly in the circular direction; the mucous tissue alone enters them; they have no analogy to the permanent mucous folds, or valvulæ conniventes, in the intestinal tube; these folds are intersected here and there by others, so as to give rise to an areolated appearance; these will facilitate longitudinal enlargement. If a recent and contracted stomach be filled with and immersed in spirits for some days, and then a portion of its anterior wall removed, the form of the organ and these several rugæ are well preserved. At the cardiac orifice the lining membrane is plicated longitudinally, and somewhat festooned, the borders being marked by a slight projection, which in some cases is very abrupt and very distinctly marked; but not so in others, indeed it seldom equals the representations in the engravings of this part: these plicæ chiefly consist of the epithelium continued from the œsophagus, where it is white, firm, and scaly, like epidermis; whereas in the stomach beyond this it becomes soft, thin, and of a pink or reddish tint. Corresponding to the pylorus is a remarkable circular fold, with a small aperture in the centre (*pyloric valve*); this fold is encircled by a strong band of sphincter fibres, upon which its valvular powers depend, as it has none such in the dead body; during life, when the sphincter acts, it can close the opening between the stomach and the intestine, and prevent the passage of any matter equally from one into the other. The mucous membrane, on its gastric surface, differs in organization from that on the duodenal aspect, being thicker and more follicular. If a stomach and duodenum be filled with air and dried, and in the course of a few days the pylorus with about two inches of the canal on either side removed, a very useful preparation of this valve is made; its circular, partition-like form and central aperture are well seen, and bear some analogy to the iris and the pupil.

This coat of the stomach is soft and thin, easily broken and detached, especially from the splenic end, where it is often found pulpy, and breaks off in shreds; in the pyloric portion it is thicker and stronger, and can be dissected entire from the other coats: however, these as well as other physical characters, much depend on the general condition of the organ and the length of time elapsed since death. Occasionally, in a very recent stomach, we may observe a marked line of distinction in the organization of the mucous membrane in the splenic and pyloric portions; this line will correspond to the circular constriction caused by the muscular fibres, thus shewing some approximation to the bilocular or compound multiple stomach of many inferior animals. This membrane sometimes presents a peculiar granular appearance; I have observed this more frequently along the lesser curvature, also near the pylorus; it probably depends on an hypertrophied state of the mucous glands and follicles. When the surface of this membrane is cleared of all adherent mucus, different portions of it may be removed and examined, some with a magnifying lens through a thin stratum of water, others floating in fluid beneath a glass globe, and others extended on thin plates of glass; the surface will be found to be very irregular, though so soft and smooth to the feel. Numerous follicular papillæ, but not true villi, project, and leave between them small depressions or pits studded with minute holes; these pits are more or less circular, and are bounded and separated by the follicular elevations; they are most distinct towards the pyloric portion of the stomach; four or five foramina are seen in each; these are the orifices of the small glands and ducts that elaborate the gastric fluid, the mucus probably being furnished by the follicles. If the cut margin of the membrane be examined, it will be found chiefly composed of tubes closely applied to each other, their cæcal ends lodged in the submucous tissue, and their open extremities are these small holes in the pits or alveoli on the surface of the membrane; some are short and straight, others are longer, convoluted, and partially dilated; blood-vessels pass between these, and cover them with a vascular net-work.

Much of our information as to the characters of this membrane during life, as well as of the process of digestion, has been accidentally derived from that interesting case of Martin, noticed and recorded by Beaumont, and published by Coombe. In this case a wound had divided the abdominal parietes and opened the stomach; a fistulous passage formed leading into its cavity, and the general health having recovered, an opportunity was thus obtained for the inspection of this membrane, and for the examination of many of the phenomena of digestion. The following facts are recorded :—" The inner coat, in its natural state, is of a light or pale pink colour, varying in hue according to its full or empty state, of a soft, velvet-like appearance, and constantly covered with a thin, transparent, viscid mucus. When aliment or any irritant is applied to the surface, innumerable lucid points and fine nervous or vascular papillæ can be seen arising

through the mucous coat, from which distils a pure, limpid, colourless, slightly viscid fluid. This is invariably acid. The mucous of the stomach is less fluid, more viscid, semiopaque, a little saltish, and has no acidity. The gastric fluid is never accumulated while fasting, and is seldom, if ever, discharged except under the excitement of food or other irritation; it is secreted only in proportion to the quantity of food supplied, provided there is not more of the latter than the system requires; and, if an excess of food be taken, the residue either remains in the stomach, or passes into the bowels in a crude state, and gives rise to nervous irritation, pain, and disease. In disease or partial derangement of the healthy function of this membrane, it presents various appearances; in febrile conditions, from any cause, it sometimes becomes red and dry, at other times pale and moist, and the secretions vitiated; scarcely any mucus, and the follicles flat and flaccid; sometimes it presents an appearance of eruptions, pimples here and there, sharp and red, and often filled with white purulent fluid, red patches, aphthous crusts, and abrasions of the surface; these are usually accompanied by dryness of the mouth and tongue, thirst and fever, and, when the healthy state of the stomach is restored, the tongue becomes clean and natural." We shall revert to the minute structure of this membrane when we have examined the remainder of the alimentary canal, and shall then also contrast it in different situations.

The stomach is very freely supplied with blood from the cæliac axis; the coronary and epiploic arteries, with the vasa brevia, enclose it in a sort of net-work of inosculations. During its distension the trunks of the two former arteries are extended close to the organ, along its curvatures, but, when empty, they are removed to some distance from it, and are then flaccid and coiled. The veins are numerous and large, and join the portal system. The eighth nerve of the left side expands on the anterior, and that of the right side on the posterior surface: both form a plexus around the cardiac orifice, and appear to be chiefly distributed to the muscular tunic. From the solar plexus of the sympathetic numerous nerves are also derived; these accompany the arteries, are supported by them, and penetrate the submucous tissue as far as the eye can trace them. The stomach is not provided with lacteals, at least but very sparingly; absorption of fluids, however, rapidly takes place in it, and is effected through the medium of the venous capillaries by endosmose. The mucous coat of the stomach secretes the fluid called the gastric juice or acid, which is generally believed to have the remarkable properties of being powerfully solvent and anti-putrescent. In the stomach the food undergoes the first important change in digestion, being here converted into a soft, homogeneous, pulpy mass, called chyme. To effect this important change, and which appears to be essentially chemical, the food must remain enclosed in the stomach for some time, varying as to the nature and quantity of the mass, as well as the condition of the organ and of the general health; a gentle contraction, as well as the elasticity of the structures at the cardiac and pyloric orifices, are sufficient to retain it.

As each superficial stratum is digested, it is moved on by the gentle peristaltic action of the muscular coat, and transmitted through the pylorus, the sensible and irritable endowments of which are such as to oppose, at least for a considerable period, the transit of any large or undigested substance. Beaumont has observed, "that the food entering the stomach from the œsophagus, in successive waves, is subjected to a peculiar peristaltic action, which effects an intermixture of the gastric fluid with the alimentary mass, and aids the solution of the latter by gentle trituration. The stomach is also constantly agitated by the respiratory movements. The food, after passing the œsophageal orifice, moves from right to left along the small arch, then from left to right along the large curvature, and then returns and performs similar revolutions; a revolution occupies from one to three minutes; they are slower at first than after chymification has advanced, when there is also an increased impulse towards the pylorus. It is probable that portions of chyme are constantly passing into the duodenum, as the alimentary mass progressively diminishes in bulk. This accelerated impulse appears to be effected by that portion of the circular fibres which embraces the organ about four inches from the pylorus, and which, in the latter part of the process, is found so constricted as almost to separate the two portions in an hour-glass form, so that, in introducing a long thermometer, the bulb was at first resisted, then allowed to pass, and then grasped and drawn in. Hence it is evident that this contraction tends to resist the passage of any solid matter into the pyloric portion of the stomach, while the fluid parts readily escape: these peculiar motions continue until the stomach becomes perfectly empty."

The *duodenum* is the next portion of the alimentary canal; it is so named from its length (which is from eight to nine inches), being equal to about twelve fingers' breadth: this is the first and shortest, but most dilatable division of the small intestine; it extends from the pylorus to the root of the mesentery, where the jejunum commences; it lies partly in the right hypochondriac and partly in the right lumbar and umbilical regions; the greater portion of it is deep-seated, and surrounded by cellular and adipose tissue; it takes a semicircular course around the head of the pancreas, convex to the right side. This course may be divided into three parts: the first, or superior transverse; the second, or perpendicular; and the third, or inferior transverse. The *superior transverse portion* ascends from the pylorus obliquely backwards and to the right side, beneath the edge of the liver, so as to touch the gall-bladder. Here the intestine makes a sudden or acute turn (the superior angle), and the *middle* or *perpendicular portion* of it commences; this descends in front of the right kidney, as low as the third lumbar vertebra, where it makes a second turn (the inferior angle), from which the *inferior transverse portion* extends obliquely upwards across the spine; and at the left side of the first or second lumbar vertebra ends in the jejunum. The duodenum differs so materially in function and structure from the remainder of

the small intestine as to have been regarded by some as a second stomach; it is fixed in its situation, being only partially covered by the peritonæum, and is of much larger calibre, particularly near the inferior angle; it can never be protruded in hernia; its muscular coat is very strong, and the valvulæ conniventes very numerous and large. The superior transverse portion, about two inches in length, is more contracted than any other part of it, and is covered on both surfaces by the peritonæum, like the stomach, and is, therefore, more moveable than the rest of the intestine. The perpendicular portion is concealed by the omentum and by the colon, and is covered by the ascending layer of the meso-colon; this portion lies on the right kidney, vena cava, and ductus choledochus, and has no peritonæum posterior to it; it is, therefore, fixed, and is dilatable; it is above three inches long. The biliary and pancreatic ducts perforate the inner side of this division of the duodenum; these pass through its coats very obliquely, and open into the intestine, sometimes distinctly and at other times conjointly, on a small papilla, opposite the inferior angle; and hence the necessity for this intestine being fixed. The inferior transverse part of the duodenum passes across the spine, the right crus of the diaphragm, the aorta, and the right renal vessels; like the middle portion, it is only partially covered by the peritonæum, being placed between the layers of the meso-colon; the sac of the omentum separates it from the back of the stomach. Its lower border may be seen, without dissection, projecting through the inferior layer of the meso-colon; its upper border adheres to the pancreas, except where the superior mesenteric vessels intervene; these pass in front of the termination of this part of the duodenum, and appear to compress it against the aorta, so as to retard the passage of its contents into the jejunum; a marked line or angle of distinction is thus made externally between the duodenum and jejunum, but internally no definite line is to be observed. The arteries of the duodenum are derived from the hepatic, splenic, and superior mesenteric; the veins join the porta, and the nerves are from the solar plexus. In the duodenum the process of digestion is completed; the chyme is mixed with the biliary and pancreatic fluids, and a separation takes place between the chyle and the excrementitious part of the food. We shall consider the structure of this intestine presently.

The *jejunum* and *ileum intestines* are partially concealed by the omentum. If we raise this process and the arch of the colon, and place them on the edge of the thorax, the convolutions of these intestines will be seen in the umbilical, hypogastric, and iliac regions, convex anteriorly, concave posteriorly, and attached to the mesentery; the jejunum commences in the left lumbar, and the ileum ends in the right iliac region. There is no exact division between these two intestines; the upper two-fifths are named the jejunum, and are placed higher in the abdomen than the ileum, which is the name given to the three remaining fifths; the former is redder, feels thicker, and is larger than the latter, which is pale and thin. These

differences are striking when we compare the commencement of the jejunum with the terminating portion of the ileum; in the intermediate space, however, they are gradually lost; they depend on the greater vascularity and number of valvulæ conniventes in the first than in the second, but there is certainly no accurate anatomical reason for this division. From the duodenum the jejunum first passes forwards and to the left side; it then descends into the middle of the abdomen, is folded upon itself over and over again, and extends into different regions, and, finally, the terminating portion of the ileum rises out of the pelvis from left to right, and joins the cæcum at an acute angle convex upwards. The general direction of the canal is from the left side downwards and to the right, and its dimensions decrease in this course, though the ileum is often dilated near its entrance into the cæcum. The distance between the commencement of the jejunum and the end of the ileum is not more than five or six inches; yet, if the coils of the tube be unfolded, it may be extended to fifteen, or even twenty feet. The length of the canal, however, cannot be accurately determined; if detached from the body, flaccid and extended, it will measure longer than if distended and *in situ;* it does not bear any uniform ratio to the height of the individual, but usually it is three or four times as long. The mesentery being broader in the centre than at its extremities, supports the numerous convolutions in a wonderful manner, free from any entanglement, compression, or obstruction, and though to a certain degree retained in their position, yet they enjoy considerable mobility; this, together with the yielding tissue of which they are composed, allow them to mould themselves to the adjacent parts, and to accommodate themselves to every alteration induced by change of position or by muscular action. At the same time, however, this mobility, which is greater in some convolutions than in others, admits of the frequent occurrence of hernia, as also of intussusceptio or invagination. Each convolution is curved into more than a semicircle, convex forwards, concave towards the mesentery, but the size and figure of each is constantly varying. These intestines are in contact with the abdominal parietes, except where the omentum intervenes, and they are separated from the spleen, stomach, and liver by the transverse colon and meso-colon; the large intestine encircles them; the arch of the colon is anterior, but the right and left colons and the rectum are behind them. Several coils occupy the peritonæal *cul de sac* in the pelvis, between the bladder and rectum in the male, and before and behind the uterus in the female. To the ileum, near the lower end, a small digital appendix or diverticulum is occasionally found attached, the embryonic remnant of the vitelline sac. The form of the small intestine is nearly circular, but a little concave posteriorly where the mesentery is attached, and where there is a small triangular space in which the peritonæum does not adhere; this loose cellular space facilitates the distension of the intestine and encloses its vessels and nerves. We shall consider the structure presently.

The *large intestine*, from four to five feet long, forms about one-fifth

of the canal; is divided into cæcum, colon, and rectum; it differs from the small not merely in size, but in being cellular or sacculated when distended; small processes also (appendices epiploicæ) are attached to it; three strong, longitudinal, muscular bands may also be observed, chiefly in the cæcum and colon, and appear to pucker it, and so cause the cellular appearance; these bands also possess much elasticity, and in some animals are decidedly elastic. The large intestine is pale and thin, and has but few valvulæ conniventes; it extends from the right iliac region to the anus, encircling the convolutions of the small intestine; in some situations it is superficial, in others deep-seated; a portion of it is found in every region of the abdomen; from the right iliac it ascends through the lumbar into the right hypochondriac, then traverses the epigastric and the umbilical tortuously; it next sinks into the left hypochondriac, descends through the lumbar into the left iliac, and finally sinks through the hypogastric into the pelvis; its lumbar portions are fixed, but its transverse arch and left iliac coils are very moveable. Its size is variable, though in general larger than the small intestine, yet it is often found in the child contracted into a cord-like form, while in the adult and aged it is sometimes dilated and distended with air to a surprising extent. The cæcum is the largest part; from this it gradually decreases until within about two inches of the anus, where it is usually expanded previous to the contracted anal opening.

The *cæcum*, or *caput coli*, is a *cul de sac* in the right iliac fossa, which it nearly fills, fixed by the peritonæum, which in general covers it only inferiorly, anteriorly, and laterally, while cellular membrane connects it posteriorly to the iliac and psoas muscles and iliac fascia: in some, however, the peritonæum covers it all round, and connects it so loosely by a meso-cæcum that it may escape in hernia; it is covered by the abdominal muscles, and sometimes partially by the coils of the ileum; it lies beneath the kidney, and is continuous with the ileum and the colon; is somewhat triangular, the apex below, and directed inwards to the left side; the base above, and somewhat to the right, joins the colon at an obtuse angle, convex outwards; there is no exact limit between them; on its external surface are three irregular protuberances, one anteriorly and two posteriorly. The *appendix vermiformis* proceeds from the left side of its lower and posterior part; this is a small, tortuous, tubular *cul de sac*, about the size of a goose-quill; it falls over the brim of the pelvis, and communicates with the cæcum, just below the ileum, by a semi-valvular opening; a mesentery connects it in its situation; variable as to size and length,—in some only an inch long, or less, in others five or six,—its position also varies, being sometimes turned up behind the cæcum; it has been also found in inguinal and femoral hernia, and it has even caused an internal strangulation, by having become twisted round a convolution of the ileum. Its use is not ascertained; it may be regarded as an arrest of development, or rudiment of the more highly developed cæcum of other animals. Before birth it proceeds from the lower end of the cæcum, and appears like its contracted, tapering end, from which the

longitudinal bands proceed; but as the cæcum enlarges it bulges forwards and downwards, while the appendix assumes the appearance of an offset directed inwards and backwards towards the pelvis. The ileum joins the left or inner side of the cæcum at an acute angle, it appears to perforate it, the peritonæum and external muscular fibres of the ileum being continued into the corresponding parietes of the cæcum, while the circular fibres and mucous coat of the ileum protrude into the cæcum to form valves, as may be seen by opening the latter in a perpendicular direction on the opposite, that is, on the right side, and washing out its contents. We then perceive the opening of the ileum, narrow, like a transverse or button-hole slit, looking obliquely downwards and outwards towards the right os ilii, and protected by two semilunar folds of mucous membrane, which enclose a few muscular fibres. These valves should be examined both in the recent state, *in situ*, or removed and floated in water, or in a dry, distended preparation. The inferior, or *ileo-cæcal valve*, is the larger, is somewhat vertical, it secures the ileum against regurgitation from the cæcum; the superior or *ileo-colic valve* is smaller, and rather horizontal, it secures the ileum against regurgitation from the colon; these are united at their extremities (*commissures*), and from each commissure a fold is continued round on the inner side of the cæcum, these are the fræna or *retinacula* of the valves, through the medium of which, and of the commissures, the distension of the cæcum closes the ileo-cæcal foramen. Each valve is composed of two laminæ of mucous membrane, enclosing cellular tissue and a few muscular fibres; the iliac surface of each differs in organization from the cæcal. These valves are unlike that of the pylorus, or the valvulæ conniventes; in the dead body their valvular powers vary; I have sometimes been unable to force even air through them from the cæcum or colon, but in other cases they have offered but little resistance; they appear perfectly adequate to oppose the reflux of any solid or consistent substance, and they are certainly more effective in a recent specimen than in one long dead. The cæcum is provided with the same longitudinal bands and appen-

*Fig.* 46.*

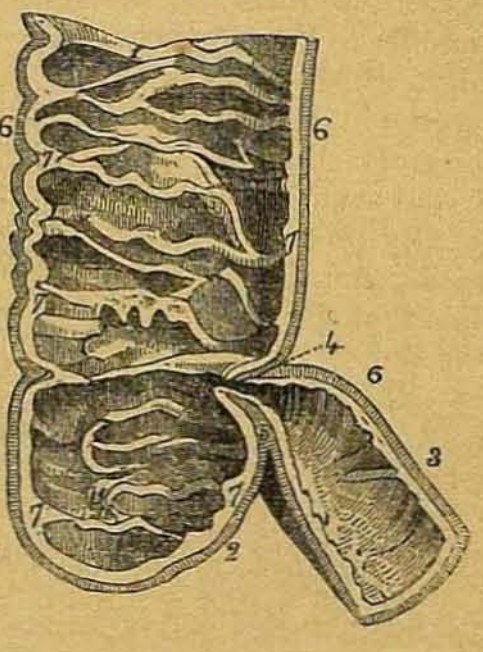


* The termination of the ileum and the commencement of the large intestine. 1. Portion of the right or ascending colon. 2. The cæcum or caput coli. 3. Portion of the ileum. 4. The ileo-colic valve. 5. The ileo-cæcal valve. 6. 6. Muscular coat, the peritonæum having been removed. 7. 7. Submucous and mucous coats, forming folds.

dices epiploicæ, and presents the same sacculated appearance as the colon; it has no valvulæ conniventes. The *colon* extends from the cæcum to the rectum; it is divided into four portions, the right or ascending, the middle or transverse arch, the left or descending, and the sigmoid flexure; there is, however, no mark of distinction whatever as to structure between these different divisions.

The *ascending colon* extends from the cæcum to the inferior surface of the right lobe of the liver, which it marks with a superficial depression. This portion of the colon is concave anteriorly, and covered by the peritonæum and by the abdominal muscles; it lies on the right kidney and quadratus lumborum muscle; the duodenum and psoas muscle are connected to it internally; the superior extremity is generally tinged with bile, from being in contact with the gall bladder; it is fixed by the peritonæum, which only passes in front of it, though occasionally it extends round it and forms the right lumbar meso-colon; the convolutions of the small intestines separate it from the abdominal parietes.

The *transverse arch of the colon* turns off at a right angle from the last, and extends tortuously from the gall bladder in the right hypochondrium across the inferior part of the epigastric and the umbilical region, as far as the spleen, in the left hypochondrium; it is covered by the abdominal muscles and the great omentum, and lies anterior to the small intestines: on the right side it is connected to the liver, in the middle to the stomach and to the great omentum; and its left extremity, which is superior and posterior to the right, is attached to the spleen by the peritonæum; it is very moveable, is sometimes close to the stomach in the epigastrium; at other times it lies in the umbilical, and even descends into the hypogastric region, and is therefore frequently protruded in hernia; the convexity of the arch is directed forwards, and the concavity backwards, but its course is often so serpentine that the term "arch" is not very applicable. It is supported by the transverse meso-colon, which is attached to its posterior concavity; the two laminæ of the great omentum descend in front of it without adhering to it, but when these have ascended they are attached to its anterior border, and then separate to enclose this intestine in their progress to become the meso-colon. The appendices epiploicæ are very numerous on this part of the colon.

The *left* or *descending colon* extends from the spleen to the iliac region, behind the small intestines, is longer than the right, and deeper seated; it is connected posteriorly to the kidney and to the quadratus lumborum and psoas muscles by cellular tissue; the peritonæum covers it only in front; from this circumstance, and from its proximity to the rectum, it has been selected as the most suitable situation for making an artificial anus, in case of obstruction in the rectum. The anatomical relations of the right colon, with respect to the peritonæum, are equally favourable, if not more so, for such an operation. In some cases, on the left side, as upon the right, the peritonæum envelopes this intestine, and forms a fold called "left meso-colon;" if the intestine

be contracted, this is more distinct, but, if the former be distended, the latter becomes expanded, and the intestine bulges posteriorly between its layers, so as to be uncovered by the peritonæum, and therefore more eligible for puncture.

The *sigmoid flexure* is connected so loosely in the iliac fossa that a great portion of it often lies in the pelvis : this part of the colon is partially covered by the small intestines, and connected to the psoas and iliac muscles, to the ureter and spermatic vessels; it is surrounded by peritonæum, which forms a loose fold (the iliac meso-colon) of very variable extent: this fold is often so loose that this part of the colon is as free and floating as the small intestines; it may, therefore, be found in other regions of the abdomen and in the pelvis, and may also protrude in hernia. It first passes upwards in front of the left colon, then descending it forms two or more coils, and joins the rectum opposite the left ilio-sacral symphysis, but without any precise distinction; its size as well as length vary considerably; it usually occupies the greater portion of the iliac fossa, and, if distended, can be felt and examined during life through the abdominal parietes.

The *rectum*, or straight intestine, extends from the sigmoid flexure of the colon to the anus; it commences opposite the left ilio-sacral articulation, and descends obliquely towards the middle line as far as the lower end of the sacrum; it then bends forwards towards the perinæum, and lastly, turning a little backwards and downwards, it ends at the anus an inch or an inch and a half from the coccyx; its course, therefore, is not straight, but curved both in the lateral and antero-posterior direction. As to the former, it commences opposite the left ilio-sacral symphisis, and descends obliquely to the median line as far as the middle of the sacrum, and then continues in that line to the anus. This course, however, is variable; it not unfrequently happens that the rectum commences opposite the right side of the base of the sacrum, and descends obliquely to the left; the antero-posterior curvature is double, the first or superior is concave forwards, is long and gradual; the second, or inferior, is short and convex forwards, and is in relation to the parts in the perinæum rather than to those in the pelvis; by this latter curvature backwards it separates from the urethra in the male, and from the vagina in the female. These points, however, cannot be fully ascertained until the dissection of the pelvis and perinæum; in the examination of these regions, therefore, we shall revert to those connexions of the rectum: in the fœtus these curvatures scarcely exist, and this intestine is then nearly straight, as it is in most other animals. The rectum is connected posteriorly to the sacrum and coccyx by the meso-rectum superiorly, and by vessels and nerves inferiorly, and is separated from the former by the pyriform muscles and sciatic plexus of nerves; anteriorly to the peritonæum above, and below, in the male subject, to the inferior fundus of the bladder, the vesiculæ seminales, and the prostate gland; in the female, to the left ovary and Fallopian tube, uterus, and vagina: along the sides of the rectum is a considerable quantity of

cellular tissue, also several vessels, particularly tortuous veins; inferiorly the levatores ani muscles cover and support the sides of this intestine, and its lower extremity is surrounded by the orbicular and cutaneous sphincters; it is fixed not only by these several attachments, but also by the pelvic fascia, which is reflected upon its forepart and sides; it cannot, therefore, be displaced in hernia, but is liable to invagination from above, and to eversion or prolapsus of its mucous coat below, improperly called "prolapsus ani." The rectum is separated superiorly from the bladder in the male and from the uterus in the female by the *cul de sac* of the peritonæum, which may or may not contain some of the small intestine, according to the state of the pelvic viscera. The rectum is only partially covered by the peritonæum; in the superior third this membrane covers the intestine all around, forming the meso-rectum behind it; in the middle third it is only connected to the forepart, and somewhat to its sides; and to its inferior third it is wholly unattached. The rectum is more cylindrical and less sacculated than the colon, and the cells present a different arrangement in consequence of the peculiar disposition of the lining membrane; it is found in general much dilated about an inch above the anus.

As the food is propelled onwards through the intestines, both large and small, it becomes mingled with a vast quantity of fluid (*succus intestinalis*), secreted by the mucous glands and follicles. In the jejunum and ileum the chyle is absorbed by their numerous villi; the length and tortuosity of the tube, and its numerous valvulæ conniventes, are admirably adapted to increase the extent of this secreting and absorbing surface, and at the same time to retard the progress of the food, and to penetrate and subdivide the mass, so as to search out, as it were, and extract all the nutriment or chyle it may contain. In the large intestine the contents acquire their fæculent properties, the first traces of which they exhibit in the cæcum. In their passage along this part of the canal the absorbents may probably continue to take up any chyle that may have escaped those in the ileum, as also the watery parts of the food, and the fæces become hardened by degrees, and moulded or figured according to the length of time they are lodged in the cells of the colon; the great length of this tube, as well as its yielding structure, adapt it as a reservoir capable of retaining a considerable quantity, and thus obviating the inconvenience of frequent defæcation. The rectum also contributes to the same effect, being retained in a closed state by the sphincters and supported by the levatores ani muscles. When the evacuation of the bowels is called for by the peculiar sensations in the part, the contents are expelled partly by the muscular action of the rectum and the concurring relaxation of its sphincter, aided by the voluntary contraction of the diaphragm and abdominal muscles.

The large and small intestines possess the same structure or number of coats, viz., the serous, muscular, fibrous, and mucous, but these, being differently modified in different situations, require to be exa-

mined distinctly in each division of the tube. Remove the following portions of intestine, including each part between ligatures, having first distended them with air or fluid: a portion of duodenum, of jejunum near its commencement, of ileum near its termination, of the arch of the colon, and of the upper part of the rectum; portions of each also should be inflated, dried, and opened, while other sections may be everted and suspended in fluid.

*Structure of the Duodenum.*—It has been already stated that the serous tunic is only partial; the superior transverse portion, like the stomach, is perfectly invested by it, excepting along the superior and inferior borders, where its laminæ enclose small triangular spaces; the middle and inferior divisions are covered by peritonæum only in front, and are very loosely connected with it; laterally and behind cellular tissue fixes this intestine in its place; the very termination of it has no connexion whatever to serous membrane, as the superior mesenteric vessels intervene and lie in front of it. The muscular coat is formed of strong red fibres, which take a circular direction; there are very few longitudinal fibres to be observed along it, except on the superior transverse portion, which portion, being moveable, can be shortened by their action; but on the middle and inferior divisions, which are fixed, such fibres would be useless. The fibrous and mucous coats are analogous to those of the jejunum and ileum, and may be examined at the same time.

*Structure of the Jejunum and Ileum.*—The serous coat forms a perfect investment, excepting in the small triangular space along their concave border, which encloses the nutrient vessels and nerves, and by the expansion of which the distension of the tube is admitted without undue extension of the investing membrane itself. The peritonæum is very fine, and connected to the next coat by extremely delicate cellular tissue, in which adeps is never deposited. Although this serous coat is transparent, and so thin as to be difficult of removal, yet it is wonderfully strong, and serves to limit or restrict the distension of the tube. The muscular coat is not so strong as on the duodenum, but more evidently consists of two sets of fibres; the longitudinal are the most superficial; they are very pale and indistinct, except along the anterior or convex side of the intestine; they are usually torn off with the peritonæum in the dissection, they are so thin and transparent; they are short; the ends of one fasciculus being received between those of two others. The circular fibres lie beneath these; they are more distinct, but also very pale: no fibre passes perfectly round the tube, but the extremities of each slant obliquely downwards, so as to form a series of spiral curves rather than annular bands. This coat of the intestine exerts an important influence in the digestive function; the circular fibres, which are stronger throughout than the longitudinal, especially on the duodenum, must have the effect of constricting or compressing the canal, thereby intermingling its contents and urging them onwards to the cæcum, while the longitudinal fibres shorten the tube, and thus co-

operate with the former by raising each successive convolution to receive the contents expelled from the preceding by the circular contraction. These actions follow each other gradually, but sometimes in rapid succession along the tube, and are commonly named the vermicular and peristaltic motions; the former are effected by the circular, the latter by the longitudinal fibres. The fibrous coat of the small intestine is analogous to that of the stomach. The mucous or internal coat is connected to the latter by vessels and nerves, and by a fine cellular tissue, which is sufficiently loose to admit of separation by the knife, or to be permeated by air and rendered emphysematous by the blow-pipe. This membrane is continuous with and very similar to that of the stomach in its general characters, but presents some peculiarities which deserve attention, one of the most important of which is the series of folds or duplicatures, named valvulæ conniventes; these are permanent processes or duplicatures of the membrane, and not effaced by distension, and therefore totally unlike the rugæ of the stomach, which are merely accidental foldings of the lining tunic seen only in the contracted or empty, and effaced during the distended state of the organ: the valvulæ conniventes should be inspected in a portion of recent intestine opened and suspended in water, or everted and then suspended, or in a section that has been inflated, dried, and opened. They commence in the vertical portion of the duodenum, at first few and small, but soon increase in number and size, and exist in the remainder of the duodenum, in the whole of the jejunum, and upper half of the ileum; they then again decrease in number and size, and are almost wholly absent in the last two or three feet of the ileum; they are best seen in the jejunum; they are semilunar folds or arches, extending round one-half or three-fourths of the tube perpendicular to its axis, broad in the middle, and narrow at the ends, which are often forked, and bend off obliquely, or end in vertical folds; they are nearly parallel, and in some places so close that the edge of one will reach the base of the next, but they never overlap; when the intestine is empty they lie flaccid, oblique, and vertical; rugæ are then also seen; but, when distended, they become extended into shelf-like partitions, not exactly parallel, but inclined a little obliquely downwards, and alternating with one another on opposite sides, so as to render the canal a sort of spiral tube or winding passage. A view of the dried preparation of these valves exhibits many of these characters very distinctly, but of course exaggerated as to strength and resistance, as they are naturally soft and flaccid, and can be folded in either direction, so that they cannot resist regurgitation, or act as true valves, like the pyloric or ileo-cæcal; each valve is composed of a fold of the lining membrane, enclosing nerves, blood-vessels, and absorbents; the convex and concave edge of each appears stronger than the intermediate portion, from the existence of a fine fibrous band, which is most distinctly developed in the duodenal folds; they are very unequal in size, seldom exceeding a quarter of an inch, but are generally much smaller. They also vary much in different

individuals, as also in different tribes of animals. These valves are of use in increasing the extent of a highly organized surface, and in delaying the food in its passage along the canal, thus affording to the absorbents a better opportunity to imbibe all the nutritious matter or chyle which it may contain; in proportion also as the intestine becomes distended, these valves become more tense, and project into the canal, so as to separate the food into smaller portions, and thus expose the entire mass to the action of the absorbents. The whole mucous surface of the small intestine is furnished with follicles and mucous glands; it also presents numerous projecting processes, called villi, which are very distinctly seen on a portion of the membrane everted and suspended in fluid, and which give to it a fine velvet-like appearance. The follicles of Lieberkühn are simple pouches of the membrane, very small, and scattered very numerously over the surface. They become very evident in enteritis, and are then filled with an opaque, whitish fluid; their openings can be seen with a lens; their cæcal ends rest in the submucous tissue; they generally surround the villi. The more elaborate intestinal glands present different appearances, and are known by the very inappropriate names of glandulæ Brunneri and glandulæ Peyeri, also glandulæ agminatæ, and solitariæ, or sparsæ. The glands of Brun are chiefly in the duodenum, in the submucous tissue, they surround the intestine in the form of a lamina of white bodies, each of the size of hemp-seeds; each consists of small lobules, the ducts opening into a common tube, and are very analogous to the pancreas and salivary glands, being of the same complex structure. They do not extend beyond the commencement of the duodenum. The glands of Peyer are sometimes collected into clusters (agminatæ), sometimes scattered separately in the lower part of the canal (solitariæ); the former are more properly the glandulæ Peyeri: in the healthy membrane they appear as small circular spots, white and slightly raised; over these there are few, if any, villi; the small openings of the follicles surround them; they are chiefly along the convex part of the intestine, and are sometimes seen distinctly by holding up a portion of the extended and semi-transparent surface between the eye and the light; no excretory duct can be seen, however, leading from these glandular patches, but on rupturing one of them it is found to contain a cavity filled with mucous and small vesicles or cells; it is supposed that at times an excretory duct opens from it and discharges the fluid of these cells or vesicles, or probably it has some communication with the adjacent follicles. Ulceration frequently destroys this investing membrane, and in such cases these glands appear as shallow, open ulcers. The use of these glands or bodies is unknown, as the nature of their secretion has not been ascertained; indeed the latter remark is applicable to the whole extent of the intestinal mucous membrane; the secretions which are produced from the different follicles and glands cannot be procured separately, or examined distinctly, nor cannot it be determined whether they should be regarded as accessory to digestion in the same way as the

gastric, hepatic, and pancreatic fluids, or as excrementitious secretions, separating from the blood effete or noxious ingredients. We may, however, infer from the great extent of the surface, and from the abundance of secretion it affords, that any material alteration in its quantity must exercise an important influence on the general economy. The *villi* are those short cylindrical, or conical processes seen on the mucous membrane in the small intestine, in some situations so numerous as to give to the surface a fleecy appearance; these little processes, when examined with magnifying powers, are found to be covered not only by epithelium, but also by a fine membrane, and to contain a minute plexus of blood-vessels, through the medium of which the absorption of fluids from the canal takes place: the lacteal vessels also commence in each villus by fine branches; but the most accurate and trustworthy observers of the present day deny that they open on the surface by free orifices, as was formerly supposed and very generally described; and the same remark applies to the lymphatic vessels which arise in the various other tissues of the body. In each villus, near its extremity, the interstices between the capillary vessels are occupied, while chylous absorption is proceeding, by very small spherical vesicles or cells containing an opalescent fluid, and, where the vesicles approach the granular texture of the substance of the villus, minute granular or oily particles are seen. When the intestine contains no more chyme, the vesicles disappear almost entirely, the lacteals empty themselves, and the villi become flaccid; the epithelium, which had fallen off during the process of absorption, is then renewed. The vesicles at the ends of the villi may be regarded as cells whose lives are of short duration, selecting from the food the materials in contact with the villi, and appropriating these to their own growth, then liberating them by solution or disruption of the cell-wall in a situation where they can be absorbed by the lacteals. This power of selection is probably a peculiar vital endowment of the cells at the extremities of the villi rather than of the lacteals, and appears analogous to the property possessed by the different cells of plants, of selecting from the common pabulum the materials requisite for the elaboration of their own peculiar products, such as colouring matter, starch, oil, &c. From our present state of knowledge of the function of absorption, which, however, is by no means perfect, it appears reasonable to conclude that the nutritive material, or the chyle, which may be regarded as imperfectly-elaborated blood, is thus absorbed by the lacteals; and from the uniformity of its composition, notwithstanding the diversity of the food, that these vessels, or rather the cells, at the extremities of the villi, have the power of selecting the ingredients of which it is composed; whereas the veins only are concerned in the absorption of the fluids in the alimentary canal, these vessels being copiously distributed on the walls of the stomach and intestinal tube, and it is highly probable that the fluids are taken into them by the simple process of endosmose.—See Goodsir, Edinb. New Phil. Jour., July, 1842; and Carpenter's Human Physiol., p. 393.

*Structure of the large Intestine.*—This, in some situations, as has been already observed, is but partially covered by peritonæum: this membrane is more loosely connected to the transverse arch of the colon than it is to the small intestine, being unattached in two triangular spaces, one along the posterior concave border, between the laminæ of the meso-colon, the other along the anterior convex, between the layers of the great omentum; these favour its distension; it partially covers the cæcum, ascending and descending colon, but is variable in this respect; it surrounds the sigmoid flexure of the colon and the upper part of the rectum, as it does the small intestine; from the cæcum to the middle of the rectum it forms a number of processes, or *cul de sacs*, like omental, fatty appendices (append. epiploicæ), which vary very much in size and number; they often contain a great quantity of adeps; they diminish in size when the intestine is distended, and are elongated when it is contracted; they have been found so long as to have caused strangulation of an intestine, or to have been engaged in a hernia: in the child they exist, but instead of adeps they contain a reddish cellular tissue. The muscular coat of the large intestine also consists of longitudinal and circular fibres; the latter form a deep layer, pale and weak, and arranged as in the small intestine: the former, however, are collected into three fasciculi, all of which commence at the vermiform process, and pass along the cæcum and colon to the rectum; of these bands one is anterior on the cæcum; the others are posterior, one internal, the other external; they are about equidistant, and a quarter of an inch broad; they are white and strong, and possess considerable elasticity; that which is anterior on the cæcum, and on the ascending and descending colon, is somewhat inferior and anterior on the arch of the colon, and is enclosed between the laminæ of the great omentum; it is the strongest band; the posterior external band on the right and left colons and cæcum, is superior and posterior on the arch, and is between the laminæ of the meso-colon; the posterior internal on the lateral colons, is inferior on the arch, and is free and smooth. These two posterior bands usually unite into a broad and scattered lamina on the sigmoid flexure; they are all shorter than the tube itself nearly by one-half, and therefore produce the peculiar cellular or sacculated form, the pouches bulging out between the bands, and constricted by circular, muscular, and cellular cord-like fibres; the cells themselves being very thinly covered. If the intestine be inflated and extended, and then these longitudinal bands divided in different places, the tube will admit of extension to a considerable degree, and the pouches will be obliterated in the same proportion; scattered, short, longitudinal fibres, also, are occasionally observed along the course of the colon. On the rectum the muscular tunic increases in thickness, and resembles that of the œsophagus; the superficial or longitudinal lamina is continued from the bands of the colon, which have been previously expanding, but which now form a thick and perfect tunic, the vertical fasciculi of which are very obvious near the anus, where they also become confounded with

those of the levator ani muscle of each side. Adipose substance is interposed between these and the peritonæum. The circular fibres also increase in strength and redness as we descend, and are collected into a thick annular fasciculus a little above the anus; this is termed the internal sphincter ani. The anal orifice is also furnished with a superficial or cutaneous sphincter, the anatomy of which, however, appertains to the perinæal region, in the examination of which, as well as of the pelvis, the rectum will again come under our notice. The internal or mucous coat of the large intestine is pale, and forms but few and imperfect folds. When distended and dried it presents internally several crests or semi-lunar ridges, separating the cells in the cæcum and colon, but these are formed by all the coats, except the longitudinal bands. This membrane has no villi, but when examined minutely presents the honeycomb or irregularly pitted appearance of the mucous membrane of the stomach, the pits or alveoli being studded with small foramina, the orifices of numerous follicles; it differs, therefore, very obviously from the lining of the small intestine, and this distinction is abruptly marked at the ileo-cæcal valves. In the vermiform appendix the follicles are large, close, and distinct; in the rectum the mucous membrane is more loosely connected to the muscular, particularly below, hence the frequency of its protrusion or eversion, in this situation also it is surrounded by numerous veins; in this intestine the mucous membrane is thrown into several longitudinal plicæ, as in the œsophagus; these are to admit of distension: it also presents some transverse or horizontal folds, one at its upper extremity, another about the middle, and the third lower down, this is the most regular, and extends from the anterior wall, opposite the lower fundus of the bladder; these folds are very distinct, in a distended and dried intestine; they are, however, by no means regular in number or size. Mr. Houston, who has particularly described them (Dublin Hosp. Reports, vol. v.), considers that they are sufficiently large and strong to support the fæcal mass, and thus to relieve the anus from its pressure; the mucous surface of the rectum, particularly below, is furnished with many follicles, some of considerable size, and with very distinct orifices.

We shall conclude this article with a few remarks on mucous membrane generally, our knowledge of the minute structure and functions of which has been considerably elucidated of late years by the assistance of the microscope. The term "mucous membrane" is applied to those great membranous expansions which are continued from the skin to line all the internal organs and the various glandular ducts and follicles; they form, in fact, the internal integument, and, as they are always in contact more or less with extraneous matters, they are coated with a viscid secretion, termed mucus, which serves not only to defend their surface from contact, but also to lubricate the passage. The entire of the digestive and respiratory apparatus is lined by this structure, also the urinary and generative; these two great mucous

surfaces are named, the former the gastro-pulmonary, the latter the genito-urinary; to the first our present remarks chiefly apply.

The gastro-pulmonary mucous membrane is continuous with the skin at the margins of the eyelids, nares, lips, and anus, lines the sinuses and recesses of the nose, the Eustachian tubes and tympana, covers the tongue, cheeks, palate, fauces, and pharynx, and at the lower part of the latter separates into two tubular prolongations; one, anterior, descends into the larynx, trachea, and bronchial tubes, into the cæcal terminations of which it is continued; the other, the posterior, lines the œsophagus, the stomach, and the entire alimentary canal, the pancreatic and biliary ducts and gall bladder, and the innumerable ducts and follicles that open upon this extensive surface. Although the appearance and character of this membrane vary in different situations, its structure being modified according to the function of each part, yet a general similarity in tissue prevails throughout. Mucous membrane is now considered as composed of three elements; first, the epithelium, which covers its free surface; second, the basement or papillary membrane, subjacent to the last; and third, the areolar tissue, which contains the nutrient and functional vessels and nerves, forms the principal portion of its bulk or substance, and serves to connect it to the surrounding tissues.

The epithelium bears some analogy, as to structure and use, to the cuticle or epidermis on the external integument, but presents considerable variety in different situations; in the mouth it consists of laminæ, composed of cytoblasts, cells, and polygonal scales; each cell and each scale has a central nucleus, within which are one or more nucleus corpuscles: the deepest lamina consists of cytoblasts only; in the next the investing cell or vesicle is developed; the cells by degrees become large and flattened, and in the superficial laminæ are converted into thin scales. The nuclei, cells, and scales are connected together by a glutinous substance containing opaque granules; the superficial scales exfoliate continually, and give place to the deeper layers: in the stomach and intestines these bodies are pyriform and columnar, the apices applied to the basement membrane, and the bases forming by their approximation the free surface. Each column has a central nucleus and nucleus corpuscle, which can be seen through the base of the transparent column. The columnar epithelium is produced in the same manner as the laminated, in cytoblasts, cells, and columns, and the latter are continually thrown off to give place to successive layers. As it is always in contact with fluids, it is soft and pliant, and, like the cuticle, it is constantly undergoing exfoliation and as constantly renewed; like it, also, it is composed of small nucleated cells, which are sometimes tesselated, sometimes cylindrical; the cells of the tesselated are polygonal, and composed of but few layers; those of the cylindrical have the form of long cylinders or truncated cones, arranged side by side, one end free, the other resting on the basement membrane. Both forms sometimes co-exist, as in the

glandular ducts; and here also the cylinders are often ciliated, the motions of the cilia being towards the outlets of the canals they line. The cylinder epithelium is found in the stomach and intestinal canal, and in all the glandular ducts opening upon these; also in those of the salivary glands. The epidermoid tissues have the simplest structure, and are the most easily renewed, of any solid parts in the body; there appears no limit to their reproduction; their origin appears to be in germs supplied by the basement membrane, through which the formative plasma transudes; their duration varies in different parts; the epidermic cells, exposed on one side to the air, soon dry, and are abraded gradually by friction or any other desquamating cause. On the internal serous surfaces, and in some few mucous, they are more permanent, but on most of the latter loss and renewal are almost incessant. The epithelial cells, on the mucous expansions and in the glandular ducts, are considered as the really operative agents in the elaboration of the mucous secretions; the cells are being continually cast off and replaced by fresh ones, and in this act of cell-growth the secreting process is accomplished. These cells of the tubes and follicles select from the blood those particles which it is their peculiar province to assimilate, and then discharge upon the surface; but we are totally ignorant of the reason why, in one situation, cells should select one peculiar set of elements, and, in another, another, and thus produce from each organ a different secretion; all that can be considered as ascertained is, that the act of secretion is effected by the process of cell-growth, and that secretion and nutrition, or growth, appear to be analogous functions, or to be effected by analogous agencies, for as the cells in the extremities of the villi select from the alimentary mass the nutritious particles which are to be absorbed, so the cells of the secreting ducts and follicles select from the blood those effete particles which it is their province to assimilate and discharge upon the surface of those canals whereby they will be removed from the system.—See Nasmyth's Mem. on the Teeth and Epithelium; also Muc. Memb. in Todd's Cyclopædia of Anatomy and Phys., by Bowman.

The second lamina of mucous membrane is by some named "the basement membrane," by others "the papillary layer;" from it is produced the epithelium; its surface presents different appearances in different situations; in the stomach it forms the cells or alveoli into which the follicles open; in the small intestine it covers the numerous projections called villi, and in the large intestine again it presents polygonal cells like those in the stomach.

The third element in mucous membrane is the fibrous lamina which gives it support, strength, and form, and so far is analogous to the corium in the skin, but seldom equals it in density; it is also more loosely connected to the proper mucous lamina than the corium is to the papillary layer of the skin; it is chiefly composed of areolar tissue, in which the white and yellow fibrous elements can be detected; these connect it to the sub-mucous tissue, from which indeed

it cannot be separated as a distinct lamina; it contains the capillary blood-vessels, nerves, and absorbents.

The *peritonæum* and alimentary canal present many *morbid* appearances. *Peritonitis*, or inflammation of the peritonæum, is denoted by an increased and a reddish vascularity of the membrane, a number of small red vessels can be distinctly seen; it loses its transparency, and becomes somewhat thick and pulpy; the parietal and visceral layers are sometimes found agglutinated by coagulable lymph, which also cements the several intestinal convolutions, but sometimes the cavity is filled with serous or sero-purulent fluid, with shreds of lymph: peritonitis more frequently ends in some such effusion than in the adhesive process; the contrary is more frequent in pleuritis; peritonitis also sometimes exhibits gangrenous patches, but if it have been chronic, adhesive bands and false membranes are very apparent. In *ascites* or dropsy of this membrane, the tissue of the latter appears sound, sometimes remarkably clear or pearly; the intestines are usually compressed towards the spine, the fluid being accumulated in front; in this disease some of the viscera, particularly the liver, are often found in an abnormal state.

The *omentum* is sometimes the seat of general induration, or of particular tumours, adipose, sarcomatous, and fungoid. The omenta and the peritonæum generally, but especially where it invests the small intestines, are not unfrequently the seat of tubercular deposit; the tubercles are often small, or miliary and innumerable. This morbid appearance is more frequently found in very young subjects.

The *stomach* may be the seat of acute inflammation, or *gastritis;* the coats will then appear more thick and vascular than usual, and blood is sometimes seen effused between them. *Ulcers* also are frequently found in the stomach, of an oval or circular form, with thin and firm edges. Independent of disease, the stomach not unfrequently presents considerable red patches on its mucous surface; the coats are also sometimes nearly destroyed in some places, presenting a soft and ragged appearance; this is caused by the gastric fluid digesting or dissolving the tissue after death. Both the cardiac and pyloric ends of the stomach are the frequent seat of *cancer;* this principally involves the mucous and muscular tissues; the latter becomes much thickened and intersected with grey, fibrous matter. On the former large fungoid masses are thrown out, which more or less constrict or obstruct the orifices of the organ, and impair its general functions.

The *intestinal tube* is subject to numerous diseases, in most of which the effects of inflammation are more or less visible: inflammation, or *enteritis*, is denoted by increased vascularity of the mucous surface and thickening of the tunics; in some cases the peritonæum is also engaged; the colour of the intestine is a deep or dark red; acute inflammation sometimes ends in gangrene and effusion, sometimes in ulceration. The whole of the intestinal surface may be the seat of ulceration; in the small intestines the ulcers are generally small, and are often found in the situation of the mucous glands; in the large

intestines they are usually in larger patches, and in cases of dysentery are often very extensive. The intestinal tunics are occasionally the seat of malignant tubercle, which may obstruct the course of the contents of the tube; of all parts of the intestinal canal the rectum is most frequently the seat of scirrhus and its consequences.

The glandular viscera of the abdomen, which are subservient to digestion, are the liver, spleen, and pancreas.

The *liver* is the largest and heaviest secreting gland in the body; it fills the right hypochondrium, extends through the anterior part of the epigastric region into the left hypochondrium, as far as the cardiac orifice of the stomach, beyond which, however, it frequently extends, even to the spleen; it is situated below the diaphragm, and above the right kidney, the stomach, duodenum, and lesser omentum; is protected by the seven or eight lower ribs of the right side, and is supported in this situation by several folds of peritonæum, termed inaccurately ligaments of the liver, viz., the falciform, round, right, left, and coronary; these connect it to the diaphragm and to the abdominal muscles, and the lesser omentum attaches it to the stomach and duodenum; the inferior cava passes through it, is intimately attached to it, and also serves to retain it in its situation. Although the liver may be considered as a fixed viscus, its position can be affected by change of posture, by inspiration and expiration, and by abnormal conditions of the viscera of the abdomen, or of the thorax. Its weight, size, and figure are extremely variable, and consequently its position and extent must vary in proportion; its weight varies from three to five pounds, and must in some measure depend on the quantity of blood it contains; its transverse diameter is the longest, and is about ten or twelve inches; the vertical diameter in the deepest part of the right lobe is about seven inches, but these dimensions are very variable; it is in general larger in the male than in the female.

The *suspensory* or *falciform ligament* is a fold of peritonæum attached anteriorly by its convex border to the linea alba, to the rectus muscle of the right side, and to the diaphragm; it passes obliquely backwards and to the right side, and is attached by its posterior or concave edge to the upper or convex surface of the liver, which it thus marks into two unequal portions, of which the right is the larger; on these its laminæ separate, and expand over each side of this organ; enclosed in the inferior edge of this fold is the obliterated umbilical vein, which substance in the adult is named the *ligamentum teres*; this, which is enumerated as the second ligament of the liver, ascends from the umbilicus obliquely backwards, and to the right side, and is inserted into a notch in the thin or anterior edge of the liver, which notch is the commencement of the umbilical or horizontal fissure of the liver. The falciform or suspensory ligament is improperly so called; it cannot have the effect of supporting this organ, as it is never on the stretch. If the abdomen were much distended, it might sustain the anterior surface and the inferior margin of the liver. The use or design of this fold was clearly to conduct

and protect the umbilical vein in fœtal life. The *right* and *left lateral* ligaments are triangular folds, connecting the right and left lobes of the liver to the diaphragm: the left lateral ligament lies anterior to the cardiac orifice of the stomach; the right lateral ligament is directly above the right kidney. The left is much broader and more distinct; between its laminæ are observed plexures of vessels derived from those of the gland; if minutely injected, the hepatic ducts may be seen dividing and subdividing, anastomosing with each other, and entangled, among hepatic arteries, some portal and hepatic veins; displaying, in fact, the simple or rudimental structure of the liver. The *coronary ligament* is situated at the upper extremity of the falciform process, and consists of two laminæ of peritonæum, which separate from each other, and connect the superior thick edge of the liver to the diaphragm; between the laminæ of this process the liver is deprived of a serous covering, and is in contact with the diaphragm; this space lies anterior to the inferior vena cava; in it a cellulo-vascular and nervous connexion exists between this and other organs, which accounts for some phenomena in disease; thus irritation, inflammation, and chronic disease in the liver may simulate disease of the right pleura or lung, as these and the diaphragm are so contiguous; and the action of the muscle in inspiration will increase the pain and uneasiness in the right side. The origin, connexion, and terminations of the phrenic nerve account for the uneasiness and pain in the right shoulder and scapular region. Abscess of the liver may open into the right pleura, and cause empyema; or it may, by the adhesive and ulcerative processes, open into and be discharged through the right bronchial tubes, &c. &c.

The liver is of such an irregular form that it cannot be likened to any known figure; it is longer transversely than from before backwards, and its right extremity is so much larger and thicker than the left, which often ends in a sort of tongue or thin prolongation, as to give some resemblance to a flattened oval or pyramid, the base filling up and moulded to the right hypochondrium, the apex thin, and of irregular extent, often passing the cardia and touching the spleen; its posterior edge is very thick, and in contact with the diaphragm; its anterior edge is thin, convex, and on a level with the edge of the right hypochondrium and with the lower part of the epigastric region. Two notches may be observed in this edge; one below the falciform ligament, into which the round ligament or obliterated umbilical vein enters, the other corresponds to the gall bladder.

The superior or anterior surface is smooth and convex, and divided by the suspensory ligament into a right and left portion; the right is larger and much more convex than the left, is contiguous to the diaphragm, and corresponds to the seven or eight inferior ribs, which often make impressions upon its surface, particularly if the organ be very large; the upper part of this surface is occasionally grooved or fluted, apparently by corresponding fasciculi of the diaphragm; the left portion corresponds to the abdominal parietes in the epigastrium,

and in the normal state descends no further than a transverse line connecting the eighth ribs of opposite sides; in the fœtus and infant it extends much lower, and very frequently also in the adult.

The inferior surface has an aspect backwards and downwards; it is very irregular, marked by several projections and depressions; the former are called *lobes*, and are five in number, viz., first, the *great* or *right lobe*, which fills the right hypochondrium, and is thick and massy; second, the *left*, thin and variable in size, separated from the former by the horizontal fissure on this surface, and by the falciform fold on the upper; this lobe occupies the epigastrium and part of the left hypochondrium, and rests on the stomach; third, the *Spigelian* or *middle lobe;* this is situated behind the lesser omentum, above and behind the transverse fissure, and between the œsophagus and the cava; it corresponds to the lesser curvature of the stomach, and projects into the upper part of the sac of the omentum, towards the head of the pancreas; the transverse fissure bounds it in front, the thick margin of the liver behind, the groove for the ductus venosus on the left side, and that for the vena cava on the right; it is very variable in size and extent; it has a mamillary form, the smooth and convex apex below embraced by the branches of the cæliac axis of arteries; it is connected to the right lobe by two roots; one is thin, and placed vertically between the fissure for the vena cava and that for the ductus venosus; the other is thick, and placed transversely, and is called *lobulus caudatus*, or the fourth lobe, of the liver; the lobulus caudatus is immediately behind the transverse fissure, and in front of that for the inferior cava, and extends from the Spigelian obliquely outwards and forwards along the right lobe between the depressions marked by the colon and right kidney. Fifth, the *lobulus quadratus*, or *anonymus*, is at the anterior part of the right lobe, in front of the transverse fissure, and between the gall bladder and horizontal fissure; its posterior border is sometimes so prominent as to have led to the name of the anterior portal eminence, as the Spigelian and caudatus lobes have been called the posterior.

The principal depressions or fissures on the inferior surface of the liver are the following: first, the *transverse fissure*, or *porta*, which is situated between the lobulus quadratus and caudatus, and extends from the horizontal fissure transversely to the right; it is very broad, and nearly two inches in length; it is about the centre of the organ, but a little nearer to the posterior edge than to the anterior, and to the left than to the right extremity: the horizontal fissure bounds it on the left and communicates with it, and thus marks the course of the inosculation during fœtal life between the umbilical and portal veins; the lesser omentum is attached to its margins; the sinus and the two great branches of the vena porta, the hepatic artery and duct, lymphatic vessels and nerves, and much cellular tissue, occupy this depression. Second, the *horizontal fissure* extends from the notch in the anterior edge of the liver backwards and upwards between the right and left lobes; the anterior part of this fissure contains the fibrous re-

mains of the obliterated umbilical vein, the posterior part those of the obliterated ductus venosus. The anterior half is deeper than the posterior, and is often converted into a complete tube by a transverse bridge of glandular or fibrous tissue; the posterior half leads obliquely to the left of the Spigelian lobe, and communicates with the termination of the groove for the vena cava, and thus marks the course of the inosculation in fœtal life between the ductus venosus and the inferior cava, or rather one of the hepatic veins close to that trunk. Third, the *fissure for the vena cava* is between the lobulus Spigelii and the right lobe; this, like the anterior part of the horizontal fissure, is frequently converted into a tube by a fibrous or glandular band. Fourth, *the depression of the gall bladder* is on the inferior surface of the right lobe, and to the right side of the lobulus quadratus; the substance of the liver is sometimes deficient over this bag. Fifth and sixth, *superficial depressions* on the under surface of the right lobe; the anterior corresponds to the *colon*, the posterior to the *right kidney* and its capsule. These depressions are indistinctly marked in some subjects; they are separated from each other by the extremity of the lobulus caudatus Seventh, a superficial depression on the under surface of the left lobe, corresponding to the anterior surface of the stomach. Eighth, a broad notch in the posterior edge of the liver, corresponding to the spine and to the right crus of the diaphragm; the venæ cavæ hepaticæ leave the liver in this situation. The five principal fissures, namely, the horizontal and transverse, with those for the vena cava and gall bladder, have been resembled to the letter H; the left limb being the umbilical fissure anteriorly, and that for the ductus venosus posteriorly; the right limb, the groove for the gall bladder in front, and that for the vena cava behind, while the transverse fissure is the connecting bar. It is obvious that these five fissures are concerned in marking the divisions into the five lobes; the distinctions, however, between these are merely accidental, and are only superficial, and do not exist on the upper surface, so that, strictly speaking, this great conglomerate gland is but one mass or lobe. The *circumference* of the liver presents anteriorly and inferiorly a thin, sharp edge, leading from the right side obliquely upwards and to the left; on the right this edge corresponds to the border of the thorax, and looks forwards and downwards; on it are two notches, one, very deep, leads into the horizontal fissure, and receives the fibrous remains of the umbilical vein; the other is to the right side of this, corresponds to the base of the gall bladder, and varies in extent and depth. The greater portion of this margin of the liver can be felt during life, when the abdominal parietes are in a relaxed position. The right extremity of the circumference is thick, round, and smooth, and attached by the right lateral fold or ligament; the left extremity is thin and elongated to a variable extent; the broad left lateral ligament fixes it to the diaphragm. The posterior part of the circumference is round, and thicker on the right side than on the left, adheres to the diaphragm by cellular tissue within the laminæ of the coronary fold or ligament, and presents the

deep and broad notch to correspond to the right crus of that muscle and to the spinal column. The groove for the vena cava terminates at this notch, and the large hepatic veins escape from the liver, and join that trunk.

The liver is of a peculiar brown colour, interspersed with yellow; in some subjects it is much darker than in others; in the very young it is red and soft, and in the old it is generally pale and yellow, and often hard and brittle; the tints and shades are of infinite variety, dark red, deep purple, brown chocolate, green, slate, pale yellow, grey, and even white; all these depend on different degrees of congestion, either venous or biliary, and there is no valid reason for attributing them to two differently coloured tissues in the liver, the red and the yellow, as was considered to be the case by some. The consistence of the liver, like the colour, is very variable, even in the absence of actual disease; it is usually dense, firm, and resisting to the feel, but sometimes it is very compact, and even hard, the edges, particularly, brittle or friable; in such cases, it may be torn or broken, and the fractured surfaces will present a granular texture; in other cases it is so soft as to retain the impression of the finger, or to break down under the slightest pressure; in such instances, however, there is often a fatty degeneration of the organ.

The liver has two coats, a serous and fibrous; the serous or peritonæal tunic covers the whole surface of the liver, except in those situations where the vessels, either pervious or obliterated, are situated, and between the laminæ of the coronary ligament, also the depression in which the gall bladder is lodged; this tunic is very thin, and adheres intimately to the fibrous capsule; it gives support and connexion to the granules or lobules of the gland, and allows it and the adjacent parts to glide smoothly on each other.

The second, or fibrous coat, is the immediate capsule to the gland; it is thin, little more than condensed cellular membrane; it is most distinct and strong where the serous coat is deficient; it covers the whole surface of the liver, and adheres to it by innumerable shreds or processes, which pass into its substance between the granules, and forms a capsule for each lobule; it also accompanies the three vessels of the liver which enter or leave the transverse fissure, and forms a capsule or sheath around their ramifications throughout the entire organ; this sheath receives the name of the *capsule of Glisson;* its processes or sheaths surround the vessels very loosely, as they also enclose loose cellular tissue; externally these sheaths adhere to the lobules of the liver, as each sends off numerous processes to enclose the several granules similarly to these derived from the surface; there is also an inflection of this tissue at the upper part of the liver, where the venæ cavæ hepaticæ escape, but it contains no loose cellular tissue, hence it is that if the three sets of vessels, which pass from the transverse fissure in a radiated direction through the organ, from the centre towards the circumference, be divided by a perpendicular incision through the liver, they will be found to collapse and recede; whereas,

if the venæ cavæ hepaticæ, which run from the thin towards the thick edge of the liver, be divided by a transverse incision through this organ, they will not recede or collapse, but remain perfectly open, in consequence of the absence of this cellular tissue, and of their close adhesion to this membranous tube, to which the substance of the gland intimately adheres. This structure may be considered as the basis or foundation of the whole organ, forming not only a general covering for its surface, but for each of the granules of which it is composed, while it is also continued from the transverse fissure around the vena porta, hepatic artery, and biliary ducts, to form sheaths for these vessels, even to their ultimate ramifications. This capsule, though generally regarded as fibrous tissue, yet is really "a cellulo-vascular membrane in which the vessels divide with great minuteness; it lines the portal canals, enters the interlobular fissures, and forms capsules for the lobules, and expands over the secreting biliary ducts;" it commences in front of the spine, accompanies the hepatic vessels through the lesser omentum, and then through the organ, in the substance of which it may be divided into three portions, the vaginal, the interlobular, and the lobular. The *vaginal* portion surrounds the hepatic artery and duct, and the vena porta in the portal canals; the *interlobular* portion fills the interlobular fissures and spaces; and the *lobular* portion supports the tissue of the lobules, and forms a capsule for each.

The structure of the liver consists of numerous small granulations or lobules of a brown and yellow colour, connected together by the branches of the hepatic arteries and veins, and of the vena porta and biliary ducts, and by lymphatics and nerves, the whole of which are cemented together by Glisson's capsule, or the tunic just described. The arrangement of these several tissues has been admirably made out by Mr. Kiernan, and described by him in his excellent memoir published in the Phil. Trans. for the year 1833. To his account of this organ little can be added, and I therefore confidently refer the reader to his description of it. Although the surface of the liver is generally so smooth and compact as to appear one homogeneous structure, yet if its coats be removed, or if a portion of the gland be broken or torn, the surface presents an irregular aspect, rugged and granulated, evidently shewing that this organ is composed of numerous minute bodies or grains closely connected together; these, which are termed lobules, together with the ramifications of the vena porta, biliary ducts, hepatic artery and veins, lymphatics and nerves, all of which are cemented together by the fibro-cellulo-vascular tissue, or Glisson's capsule, constitute the mass of this very large conglomerate gland. On each of these we shall offer a few remarks.

The *lobules* are small granules, of the size of millet seeds, but of irregular forms, rounded, and with angular prominences; each presents a base which rests upon an hepatic vein, which is therefore called sublobular vein, the remainder of this lobule is invested with a capsule from Glisson's membrane; this surface is connected to the capsular surfaces of the adjacent lobules; the intervals between these

lobules are called interlobular fissures, and the angular spaces formed by the apposition of several of these lobules are called interlobular spaces. The lobules on the surface are larger and more flattened than those which are internal. Each lobule is composed of a plexus of biliary ducts, of a portal venous plexus, of an interlobular branch of an hepatic vein, and of minute arteries; nerves and absorbents cannot be traced, but may be presumed to exist in each. The microscope exhibits the lobule as composed of numerous minute yellowish bodies, of various forms, and connected together by vessels; these minute bodies are the acini of Malpighi, and they are probably the cæcal extremities or plexiform terminations of the biliary ducts: each lobule may be regarded as a very minute though a perfect gland, and the whole liver is but the aggregation and close union of these.

Through the liver *four* sets of vessels ramify, in addition to numerous lymphatics, viz., the branches of the hepatic arteries, venæ portarum, hepatic ducts, and hepatic veins: the venæ portarum are supposed to be the vessels from which the bile is secreted; the hepatic arteries nourish the substance of the liver, and join the vena portal plexus; the hepatic ducts carry the bile from this organ, and the venæ cavæ hepaticæ return the blood which has circulated through the liver to the inferior vena cava, just as this vessel is passing through the diaphragm.

The *vena porta* is a very large, a very important and peculiar vessel; though it arises in the abdomen as a vein, and serves the same office, yet in the liver it terminates like an artery, and has a secreting function; it returns the blood from all the chylopoietic viscera to be distributed through the liver, and in the latter organ it receives the venous blood from the terminations of the hepatic artery. It is four or five inches long, is formed by the confluence of the splenic and mesenteric veins behind the pancreas, in front of the aorta and to the left of the inferior cava; it ascends obliquely to the right side, receiving branches from the pancreas, duodenum, stomach, and gall bladder, enclosed in and conducted by the lesser omentum to the transverse fissure of the liver, the left extremity of which it enters, and then divides into a right and left branch; these separate so widely as to form a short trunk or swell at right angles with the vein itself (sinus of the porta), then enter the liver, divide and subdivide into numerous branches, which radiate towards the circumference in horizontal directions, and lodged in canals, termed the portal canals, which are formed of the vaginal processes of the capsule of Glisson, and, like the superficies of the organ, by the capsular surfaces of the lobules. Each of these canals contains a portal vein and its branches, also an artery and a duct; in the large canals these vessels are surrounded more loosely by the capsule, but in the smaller canals the parietes are in close contact with the vein on one side, and with the artery and duct on the other. The branches of the vein are the vaginal, interlobular, and lobular. The *vaginal* arise in the portal canals, pass into the sheath formed by Glisson's capsule, and form in

it the vaginal plexus. The *interlobular* branches arise from the vaginal plexus, enter the interlobular spaces, and divide into branches which cover all sides of the lobules, except their bases on their peritonæal surface; these branches form a free communication through the entire organ. The *lobular* branches arise from the last, enter and form a plexus in each lobule, and end in a minute intralobular vein; this may be called the lobular venous plexus, and is between the interlobular portal veins and intralobular hepatic veins. In the meshes of this plexus are seen, by means of the microscope, the acini of Malpighi, or portions of the lobular biliary plexus. The capsular veins of the liver not only join the porta, but also inosculate with the phrenic veins. In some cases of atrophy of the liver and obstructed circulation of the blood, collateral circulation has been maintained by the anastomoses between these veins, as also between the capsular branches of the hepatic artery and the phrenic and others. The *hepatic artery* is a branch of the cæliac axis; it ascends in the lesser omentum to the left side of the bile duct, and in front of the vena porta enters the liver with this vein and with the hepatic ducts, pursues the same course, and divides into the corresponding branches, vaginal, interlobular, and lobular. The *vaginal* branches form a vaginal plexus; the *interlobular* ramify in the interlobular fissures, and are chiefly distributed to the coats of the biliary ducts; small branches also ramify in the capsule of the liver and anastomose with branches from the phrenic, internal mammary, and suprarenal arteries. The *lobular* branches are very small and few; they are the nutrient vessels of the lobule, and end in the lobular venous plexus of the vena porta. Kiernan maintains the opinion, and adduces strong evidence in its support, that the office of this artery is nutrient, and not secreting; minute injections of it colour very highly the cellular tissue and the coats of the ducts and of the other vessels, as also the gall bladder, but produce very little effect on the lobules themselves. The terminating branches of this artery have no communication with the hepatic veins, but all join the lobular venous plexus of the porta, which is the secreting agent; the intralobular veins, which are the radicles of the hepatic veins, receive the blood, not from the arterial capillaries, but from the lobular venous plexus. The *hepatic ducts* may be traced from the transverse fissure along with the last-mentioned vessels, and present the same order of branches, vaginal, interlobular, and lobular; the first form a vaginal biliary plexus, from which proceed the interlobular, which ramify on the capsular surface of the lobules, and freely communicate with each other; the lobular ducts proceed from these, some also from the vaginal plexus; these enter the lobule, and form within it the lobular biliary plexus, in which the ducts end either in cæcal extremities, or in anastomosing arches. The coats of the ducts are very vascular; they possess many mucous follicles: these are distributed irregularly in the large ducts, but are arranged in two longitudinal and parallel rows in the smaller.

*Hepatic veins* convey the blood from all parts of the liver to the

vena cava; they are also divisible into the three orders: intralobular, sublobular, and hepatic trunks. The *intralobular* pass through the central axis of the lobule and through the centre of its base, and end in the sublobular veins. The *sublobular* veins are lodged in canals formed by the bases of the lobules, and are in close contact with the latter without the intervention of any of Glisson's capsule; they are thin and transparent, and, if laid open, the bases of the lobules will be distinctly seen, separated by the interlobular fissures, and perforated in the centre by the intralobular vein. The hepatic veins are formed by the union of the sublobular veins; they are lodged in canals lined by the capsule of the liver, but not surrounded by cellular tissue or vaginal plexus; they all proceed from before and from below upwards and backwards, and end in two or three large trunks, which open into the cava close to the diaphragm: in this course they cross the branches of the porta which radiate from the centre towards the margins of the liver. When cut at right angles they remain open, and retain their cylindrical form, as they are closely connected to the lining of the hepatic canals in which they are lodged: no other vessel is enclosed with them, whereas every branch of the vena porta is accompanied by a small artery and bile duct, and the three are enveloped in the capsule of Glisson. The *right* and *left hepatic ducts* are nearly of equal size, and, on clearing the transverse fissure, unite at an obtuse angle, and form the *hepatic duct*, which descends for about one inch and a half along the right side of the lesser omentum, is then joined at an acute angle by the cystic duct, from the gall bladder: the union of these forms the *ductus communus choledochus;* or rather the hepatic duct may be said to give off the cystic, which, passing backwards and to the right side, dilates so as to form the gall bladder, and the ductus choledochus may then be regarded as the continued hepatic duct. This vessel, about three or three-and-a-half inches long, descends obliquely backwards, at first in the lesser omentum, in front of the vena porta, and to the right of the hepatic artery; then it passes behind the pylorus, the upper part of the duodenum and the pancreas, and is imbedded in the substance of the latter; about the middle of the internal or concave side of the middle division of the duodenum it perforates the coats of this intestine in a very oblique direction, and opens on a small papilla internally, opposite the lower angle of the duodenum: as the ductus choledochus is about to perforate the duodenum, it is in general joined on the left side by the duct from the pancreas.

The lymphatic vessels of the liver are very numerous, and are arranged into a superficial and deep set; the former present a network appearance beneath the peritonæum, often very distinct; the latter are larger, escape by the transverse fissure, enter the lesser omentum, and end some in the adjacent lymphatic glands, and others in the thoracic duct.

The nerves are small; a few from the pneumogastric, and probably some fine filaments from the right phrenic; but the principal supply

is from the solar plexus; these form a plexus around the hepatic artery, and some also around the vena porta, and accompany these vessels as far as the eye can trace them.

The *gall bladder* is of very variable size, is situated in the right hypochondrium in a depression on the inferior surface of the right lobe of the liver, between the right extremity of the transverse fissure and its anterior margin, and to the right side of the lobulus quadratus; this membranous sac is of a pyriform figure; the large extremity or fundus being directed forwards and downwards, and to the right; in some it projects below the liver against the abdominal muscles, opposite the outer border of the right rectus muscle, and the cartilages of the ninth and tenth ribs; it is generally contiguous to the pylorus and to the colon; the smaller extremity or neck is directed upwards, backwards, and to the left; is a little convoluted, and ends in the *cystic duct*, which is about an inch and a half long: this duct bends downwards and inwards, and joins the hepatic duct at an acute angle, the union with which forms, as was before mentioned, the ductus choledochus. The gall bladder is closely united to the liver by the peritonæum, which passes over it; also by cellular membrane and small blood-vessels; it is composed of three coats: a serous, which is only partial, a perfect cellulo-fibrous coat, and a lining mucous membrane; the latter has a peculiar honey-comb-like appearance, and in the duct is disposed in a spiral valvular lamina; there is no appearance of a muscular coat.

This viscus serves as a reservoir for the bile, when this fluid is not required in the intestinal canal; and that its office is but secondary may be inferred from its absence in many animals; it is wanting in all invertebrata; the biliary ducts in these open on the surface of the digestive organ. In fishes it first appears, but is absent in many genera, and rudimentary in others, as a mere dilatation of the bile duct. It exists in all the reptilia; in the ophidia it lies at a distance from the liver, and has therefore a very long cystic duct; in the chelonia it is buried in the substance of the organ, and receives the bile by hepato-cystic ducts. In many birds it is absent, and in many it is present; in the latter the bile is brought to it from the liver by an hepato-cystic duct; the hepatic opens into the duodenum near the cystic; there is no choledechus duct. In mammalia it is very uncertain; it is absent in most herbivora, as horse, elephant, stag, but is present in many, as ox, sheep, and goat; in one giraffe it was wanting, in another it was double. The hepatic, cystic, and choledochus ducts are all composed of similar tissues, viz., a fine lining mucous membrane, thin and follicular, continuous with that of the duodenum and the gall bladder; a middle, fibrous, and areolar texture, which most probably possesses some contractile property, and are external, cellular, and partial peritonæal covering; they are all thin and very dilatable; the latter property is exemplified throughout the whole series when the flow of bile is arrested by any obstruction at the duodenal extremity of the ductus choledochus.

The bile is secreted in the liver, flows down the hepatic duct, and, if not required in the duodenum, or if obstructed in the ductus chole-

*Fig. 47.**

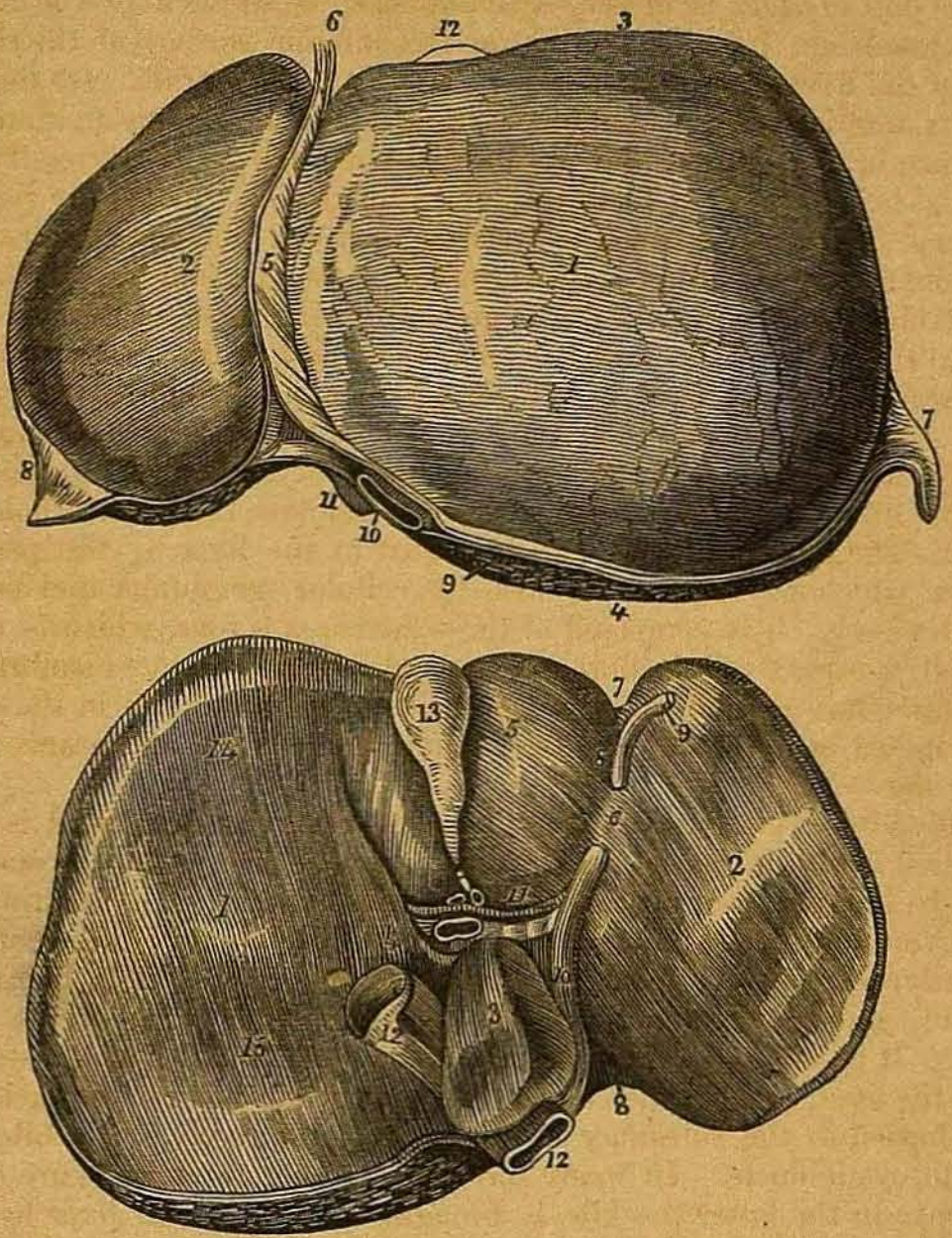


* The superior surface of the liver. 1. The right lobe. 2. The left lobe. 3. The anterior thin edge. 4. The posterior thick edge. 5. The suspensory or falciform ligament. 6. The ligamentum teres. 7. The right lateral ligament. 8. The left lateral ligament. 9. The portion of the thick border of the liver which is uncovered by the peritonæum, and surrounded by the coronary ligament. 10. The inferior vena cava cut across. 11. The posterior extremity of the Spigelian lobe. 12. The fundus of the gall bladder, projecting beyond the anterior edge of the liver.

The inferior surface of the liver. 1. The right lobe. 2. The left lobe. 3. The Spigelian or middle lobe. 4. The lobulus caudatus. 5. The lobulus quadratus. 6. The pons hepatis, not always present. 7. The notch in the anterior edge of the liver, forming the commencement of 8. 8. The horizontal fissure. 9. The obliterated umbilical vein. 10. The obliterated ductus venosus. 11. The transverse fissure. 12. 12. The vena cava inferior. 13. The gall bladder. 14. A superficial depression, corresponding to the colon. 15. A similar one corresponding to the right kidney and supra renal capsule.

dochus, passes into the cystic duct to the gall bladder, where it remains a longer or shorter period, during which some of its watery part is absorbed; at the end of some time, when required to assist in digestion, it is forced out of the gall bladder, and then flows again along the same cystic duct to the ductus choledochus, and so to the duodenum. The bile is not secreted in the gall bladder, nor can it possibly enter or leave this viscus by any other channel than through the cystic duct, as there are no hepato-cystic vessels, as in reptiles and in some birds.

The office or *use* of the liver is to secrete the bile; it is most probable also that it exerts an important influence in sanguification, or in the purification of the blood. The secretion takes place in the lobules from the great venous plexus of the portal vein, and as the blood of the hepatic artery has become venous previous to its passage into the lobular venous plexus, this secretion must be wholly from venous blood; the elements which are thus separated from the venous blood of the chylopoietic viscera, and which constitute the bile, are useful in digestion, and are supposed to act chemically on the chyme in the duodenum, and to produce the separation of the chyle; the bile also combines with the residual or fæcal matter, to which it imparts its peculiar colouring matter, and it also stimulates the mucous surface of the intestinal tube to pour forth its secretions, and the muscular coat to contract upon its contents. That the liver also exerts some additional function in depurating the blood may be inferred from the great size of this organ compared with that of its excretory apparatus; the considerable magnitude of it in fœtal life, when the biliary secretion is scanty and not required in digestion; the large venous system that is expanded through it; the proportion it bears inversely to the lungs, but directly to the necessity for removing from the blood a larger quantity of hydrogen and carbon; in the herbivorous animals, in the quadrumana, and in man, it is not so large as in the carnivora; in birds it is larger, as there is great need of highly oxygenated blood; in fish and in reptiles, with cold blood and imperfect respiration, it is still larger; it is also very large in the invertebrata.

No viscus in the abdomen presents such frequent and varied abnormal appearances as the liver. The pathology of many of these has been much elucidated by the anatomical and physiological researches of Kiernan.

*Inflammation*, acute or chronic, of its peritonæal coat, or *membranous hepatitis*, is marked by the usual characters of serous inflammation. The capillaries are injected with blood and coagulable lymph is effused, agglutinating the adjacent parts; adhesions more frequently occur on its convex than concave surface. This condition may exist independently of inflammation of the organ itself, though some congestion in the latter is commonly present.

The mucous lining of its excretory vessels may also be in a state of acute or chronic inflammation, caused by extension of irritation from the mucous membrane of the gall bladder, duodenum, or alimentary

canal. This induces thickening, contraction, and partial obliteration of the ducts, and may thus become the source of many chronic diseases of the liver, and abnormal changes in its tissue.

*Hepatitis*, or acute inflammation of its parenchyma, is seldom seen in the dead body; it is denoted by a deep red or purple colour, a firm and heavy feel, and some increase in size; the investing membranes are easily detached, and the subjacent surface is very granular and vascular. Hepatitis often ends in suppuration; the pus may be collected in several small cysts through the liver, or diffused among its lobules, or it may be collected into one large abscess, the contents of which may be discharged in various directions, and recovery ensue. Adhesive inflammation attaches its walls to the surrounding parts, or to some adjacent viscus, and ulceration gives exit to its contents without any effusion into the abdomen. By this process an hepatic abscess may point, and be opened by the surgeon through the abdominal parietes, or between the ribs, or it may burst into the pleura, or by the continuation of the same adhesive process it may become attached to the lung, and the matter may escape into the bronchial tubes, and be coughed up, or it may open into the stomach, or duodenum, or colon, and be discharged through the alimentary canal; it has also been known to have opened into the pericardium and into the vena cava. The liver, containing an extensive venous expansion, is frequently the seat of abscess, in consequence of injuries of the head, or of the bones, or of wounds, or operations in any part of the body in which phlebitis has occurred. From a number of observations and ingenious experiments, Cruveilhier has concluded that in all these cases there has been a capillary phlebitis in the part injured, and that the globules of pus carried thence to the lungs and liver have produced irritation and suppuration in these organs. In all such cases of hepatic suppuration he has found similar purulent deposits in the lungs; in all visceral abscesses from this cause we find around the inflamed veins induration, effusion of blood, lymph, and pus; the latter also is found in the minute veins, and, when in the liver, diffused among the lobules, producing a sort of granite-like appearance.

*Venous congestion* in the liver is very frequently seen in the dead body, and is to be considered rather as an effect depending on the abnormal state of some other organ or function than as a disease of this organ itself; congestion may be partial or general, and it may be in the hepatic venous system, or in the portal. In hepatic venous congestion, the hepatic veins, their intralobular branches, and the central portions of their lobular plexuses, are all congested; the centres of the lobules are red, while their non-congested margins are white, or yellow, or green, according to the quantity of bile in the ducts. This is the usual state of the liver after death, and arises from an impediment to the flow of flood through the hepatic veins, while the portal circulation still continues. This form of congestion will be very strongly marked in some diseases of the heart, and in acute disease of the lungs or pleuræ; in such cases the liver will be found large and full, from

the quantity of blood it contains; sometimes also it will be in a state of biliary congestion: this combination gives rise to various appearances, known under the name of "nutmeg or dram-drinker's liver."

Portal venous congestion is very rare, and has been only seen in children. In this the congested portions are never so red as in the last form; the centres of the lobules are pale and non-congested, while the interlobular fissures and spaces are strongly so, and of a much deeper colour than natural; from the liver this congestion may extend to the vessels of the alimentary canal, and give rise to gastric and intestinal hæmorrhages, also to hæmorrhoids and ascites.

In general congestion the whole substance of the liver presents a diffused red colour, the central portions of the lobules being of a deeper hue than the margins.

*Hypertrophy* differs from congestion, and implies an actual increase in size and growth; it may be the result of chronic inflammation of the mucous tissue, or of any cause that has obstructed the circulation. In some instances it is found congested also, but in others pale and anemic.

*Atrophy* is denoted by diminished size of the whole or of a part; the lobules are indistinct, and often appear compressed by the cellular tissue, which is increased; the hepatic venous congestion is sometimes combined; the surface is often marked by irregular lines or grooves. This condition of the liver has been thought to have been induced in some cases by the injudicious pressure of tight dress; it may also be the result of antecedent chronic inflammation.

*Cirrhosis* is atrophy of the parenchyma and hypertrophy of the cellular tissue or basis of the liver; some lobules are wholly, others partially atrophied, and the remainder are in a state of biliary congestion; the organ is often diminished to one-half its size, and changed into a shapeless mass, the surface withered, with furrows, ridges, and wrinkles of varying tints of green and yellow. On dividing it the structure feels dense, and is irregularly granulated; ascites, jaundice, and thoracic disease, are often concomitants to this abnormal condition of the liver.

The liver is sometimes *indurated* to an extraordinary degree with or without hypertrophy or atrophy; it is not unfrequently preternaturally *softened*, so as to break into a grumous pulp under very slight pressure; it is also sometimes so loaded with a fatty or oily matter as to resemble the liver of the cetacea; this state is termed *fatty degeneration.*

The liver is the deposit of various species of *tubercle;* the common scrofulous, the small diffused, the large circumscribed, the soft brown, the scirrhous, the fungoid, the melanotic, the hydatid; this latter is in the form of a cyst, which sometimes contains several smaller hydatids, one enclosing the other; these hydatids are classed by some under the head of the acephalyst entozoa; small intestinal worms also have been occasionally found in the biliary ducts; these probably have ascended from the duodenum through the choledochus duct.

The morbid appearances found in the gall bladder are: great distension from obstructed ductus choledochus, or total obliteration of its cavity from obstruction in the cystic duct; it often contains biliary calculi; if one only, it is usually large and ovoid; if many, as is commonly the case, they present every variety of form and size, with smooth sides and defined angles, the probable effects of constant friction one against the other.

The *spleen* is a soft, spongy, vascular mass, very variable in size and consistence; its texture, even in a healthy state, is often so weak and soft, or so brittle, as to break down under the slightest pressure. It has no excretory duct; but as its vein directly joins the porta, and so reaches the liver, it may with great probability be regarded as accessory to this organ in its function of sanguification or of depuration of the blood. It is situated in the left hypochondrium, between the stomach and the ribs, beneath the diaphragm, and above the kidney and the colon: it is in contact with and connected to the diaphragm by the peritonæum, also to the stomach and pancreas by vessels and by the peritonæum. It is somewhat of an oval form, or a longitudinal section of an ellipse; convex towards the ribs, and concave towards the stomach. On the latter surface there are several holes, and about the centre of it a depression or fissure, with a row of foramina for the entrance and exit of the blood-vessels and nerves; this depression is named *hilus of the spleen.* The gastro-splenic omentum, which contains the vasa brevia, is attached in this situation; all this surface is not equally concave; the part anterior to the vessels is most so, and is more or less closely related to the *cul de sac* of the stomach. The posterior portion is often convex, and is related to the left kidney, suprarenal capsule, left end of the pancreas, and left crus of the diaphragm, which separates it from the side of the spine. The smooth convex surface is in contact with the diaphragm, and by it is separated from the three or four last ribs. The upper extremity, large and round, is in contact with the diaphragm, and sometimes with the edge of the left lobe of the liver; the inferior end smaller, thin, and flattened, is in contact with the left part of the arch of the colon, rests on the mesocolon, and is moveable; the posterior margin is thick and round, and often deeply notched; the anterior edge is more thin and sharp, and is also often deeply notched; these notches are uncertain, and appear rudimental divisions into lobes.

The spleen, though a fixed viscus, partakes of some motion or change of place according to the state of the surrounding parts, particularly of the diaphragm and stomach; in deep inspiration it descends a little, and when the stomach is distended the lower extremity is turned somewhat forwards; it is then also more closely applied to the surface of its *cul de sac*, and has more of a horizontal than a vertical position. The size of the spleen is very variable, even more so than that of the liver; in some it appears shrunk, with its capsules wrinkled and loose, in others they are full and tense. It would appear, therefore, to be subject to distension and collapse, and many suppose

that these conditions alternate in the inverse ratio with the corresponding states of the stomach.

The colour of the spleen is very variable, from a deep, dark red to a pale grey, purple, livid, marbled, often like a leech; long exposure to the air brightens the red colour.

The spleen possesses two coats, serous and fibrous; the serous or peritonæal invests all portions of it except the hilus, which corresponds to the space between the laminæ of the gastro-splenic omentum; it gives a smooth covering, and attaches it to the surrounding organs. The fibrous or proper coat is thin and transparent, but very elastic; the serous is closely united to it externally, and from its internal surface numerous shreds pass into the spleen all over its surface, while at the hilus it is not perforated, but inflected around the vessels, the ramifications of which it accompanies, and joins the processes derived from the surface, so as to constitute a cellular or areolar basis or frame-work to lodge and to support the vascular tissue of the organ; this areolar tissue may be well seen by macerating and washing away the blood from a divided spleen. Injection and inflation also demonstrate the same structure; this tissue is divided into compartments, and hence injection will sometimes fill some of these only, leaving the others flaccid. These fibrous cells are filled with a substance like grumous blood; they also contain a number of small red corpuscles, the nature of which is not understood. In addition to these cells and their contents this organ is essentially composed of blood-vessels. The splenic artery is the largest branch of the cœliac axis; it is remarkably tortuous, and enters the spleen by five or six branches; each of these pursues the same tortuous course within its substance, and divides into many ramifications; those from one branch do not join those from another, so that the spleen may be regarded as a number of spleens, as in the case of conglomerate glands; the spleen occasionally receives additional arteries from the phrenic, lumbar, and suprarenal. The splenic vein is much larger than the artery, and is the principal root of the vena porta; its branches form the greater portion or bulk of the organ, so that it resembles a venous erectile tissue; the cells are believed to communicate with the veins, or rather perhaps the former are but modifications of the latter, and that they are in fact composed of the lining membrane of the veins, supported by the fibrous sheaths and bands of the areolar texture.

The nerves of the spleen are very distinct; they are derived from the solar plexus, and twine around the artery and its divisions; some small filaments also from the pneumo-gastric, in the gastro-splenic omentum, pass towards it in the course of the vasa brevia.

The lymphatic vessels are superficial and deep; some pass from the stomach towards the hilus, and enter the lymphatic glands. The exact use or function of this viscus is not yet ascertained; sometimes two or more small bodies, of the same colour and structure as the spleen, are found in its vicinity between the laminæ of the omentum.

The spleen is not often found *diseased;* the greatest possible variety

as to size and consistence is observed without any morbid change; in some cases it is so soft as to break under the slightest pressure: its coats are subject to thickening and induration, cartilaginous and even bony tubercles or patches are very common occurrences in its fibrous capsule.

The *pancreas* lies behind the stomach, and may be exposed by dividing the great omentum between this organ and the colon. This conglomerate gland, in colour and texture, is very similar to the salivary glands; it is flat, thin, and elongated, about seven inches long, and an inch and a half broad; it extends from the lower part of the left hypochondriac and epigastric regions obliquely downwards and forwards into the umbilical region, where it is surrounded by the duodenum; it is covered by the stomach and the ascending layer of the mesocolon; it lies anterior to the left crus of the diaphragm, the vena porta, the aorta, the vena cava, superior mesenteric artery, left kidney and suprarenal capsule, and the two first lumbar vertebræ; the great end or head is encircled by the duodenum, the concave border of which it overlaps, and to which it adheres very closely, somewhat as the sublingual salivary gland does to the mucous membrane of the mouth: the middle portion is called the *body*. The splenic or left extremity (its *tail*) is small compared with the right, which is broad and flat, and is named the *head;* the anterior surface looks a little upwards, the inferior edge being raised forwards and separated from the duodenum by the superior mesenteric artery and vein, which pass behind it through a deep groove or tubular passage in the gland; a groove may also be remarked on its posterior and upper part, which contains the splenic artery and vein. The *pancreatic duct* is imbedded in its substance, and may be seen by scraping off some of the surface of the gland about its centre. This duct is remarkably white and thin; it commences in the small extremity of the gland, and extends to the large end, receiving in its course numerous branches on each side: it very generally joins the ductus choledochus in a small, ampulla-like dilatation, just before the duodenal opening; sometimes there is a second duct, which opens into the duodenum distinctly; attached to the head of the pancreas there is sometimes a glandular mass of the same structure as the pancreas, and opening by a small vessel into the pancreatic duct; this is named the *lesser pancreas.* The pancreatic fluid is supposed to be of use in diluting the bile, and rendering it and the contents of the duodenum more miscible with each other. The structure of the pancreas is similar to that of the salivary glands, and is thence called by some the abdominal salivary gland.

The pancreas is not often found in a *morbid* state; induration of its structure and calculi in its duct may be occasionally noticed, and in some cases distending the latter into a serous cyst: it is sometimes found adherent to the back part of the stomach, and in chronic ulceration of the coats of the latter this gland has been found supplying

the deficiency, and thus preventing effusion from its cavity: its proximity to the aorta and to the pylorus renders it at times extremely difficult to distinguish between the diseases of each.

## SECTION III.

### OF THE VESSELS AND NERVES OF THE ABDOMEN.

THE abdominal aorta gives off three large branches to supply the organs of digestion, viz., the cœliac axis, the superior mesenteric and inferior mesenteric arteries. The *cœliac axis* may be seen by tearing through the lesser omentum above the lesser curvature of the stomach; it arises from the forepart of the aorta, at the upper edge of the pancreas, is about half an inch long, and divides into three branches, the gastric, hepatic, and splenic; the *gastric* artery and its branches run between the laminæ of the lesser omentum, along the concave edge of the stomach, and supply both surfaces of this organ. The *hepatic artery* accompanies the vena porta and the biliary duct to the transverse fissure of the liver, first sending off a small branch to the pylorus (pylorica superior), next a large branch (gastro duodenalis), which descends behind the pylorus, and subdivides into two branches, the pancreatico-duodenalis and gastro-epiploica dextra; the former supplies the pancreas and duodenum; the latter runs along the convex edge of the stomach, between the layers of the great omentum; the hepatic artery then divides into the right and left hepatic arteries, which supply the right and left lobes of the liver; the right hepatic is the larger, and gives off a small branch, arteria cystica, to the gall bladder. The *splenic artery* is the longest and largest branch of the cœliac axis; it passes along the upper and posterior part of the pancreas, to which it gives many branches; near the spleen it sends off the gastro-epiploica sinistra, which runs along the convex edge of the stomach, between the layers of the great omentum; the splenic artery then divides into five or six branches, which enter the foramina in the concave surface of the spleen: from these splenic branches five or six small arteries, the vasa brevia, pass to the left or great end of the stomach. The *superior mesenteric artery* arises about an inch or less below the cœliac axis, behind the pancreas; it descends in front of the duodenum, enters the mesentery, and bends obliquely towards the right iliac fossa; from its left or convex side it sends off sixteen or eighteen branches, which supply the jejunum and the ileum, and from its concave or right side arise three branches, the ileo-colica, colica dextra, and media; these arteries supply the corresponding portions of the colon, and inosculate with each other. The *inferior mesenteric artery* arises a little above the division of the aorta into the iliac vessels; it

descends to the left side, and divides into three branches: the colica sinistra, which supplies the left lumbar colon, and inosculates with the colica media; the sigmoid artery, which supplies the sigmoid flexure of the colon; and the superior hæmorrhoidal, which is distributed to the rectum. These arteries are accompanied by corresponding veins, which all unite to form the vena porta. The *inferior mesenteric vein* accompanies the artery of that name to the aorta, and there joins the *superior mesenteric vein*, which is a very considerable vessel; this common trunk then ascends behind the pancreas, and is joined by a very large vein from the spleen; the confluence of the splenic and mesenteric veins forms the commencement of the *vena porta;* this vessel ascends obliquely to the right side, surrounded by nerves and cellular membrane, and enclosed in the lesser omentum; near the transverse fissure it becomes dilated (the sinus of the porta), and divides into the right and left branches; the former is the larger, the latter the longer of the two; each branches out through the liver, surrounded by the capsule of Glisson, and runs in a transverse direction: by the assistance of minute injections their terminating branches can be traced to the lobular venous plexus, in which they end.

The nerves which supply the digestive organs are the eighth pair, and the splanchnic branches, from the sympathetic: the *eighth pair* descend along the œsophagus, and are distributed almost wholly to the stomach; some few branches pass along the lesser omentum to the liver, some also join the solar plexus. The *splanchnic nerves* are two in number, a right and left; they are each formed by filaments from the dorsal ganglions of the sympathetic nerve in the thorax; they enter the abdomen either along with the aorta, or perforate the crura of the diaphragm on either side of that vessel; in the abdomen each nerve soon ends in a large ganglion, the *semilunar ganglion*, from which numerous branches pass across the aorta, around the cœliac axis, and, communicating with each other, form the nervous plexus, named *solar* or *cœliac plexus*, from which a fasciculus of nerves extends along each of the branches of the cœliac artery to supply the viscera in the epigastric region; thus a few accompany the gastric artery, and communicate with the eighth pair on the stomach; several surround the hepatic artery, and by it are conducted to the liver; in like manner others also pass to the spleen. From the lower part of the solar plexus several large branches descend, and become attached to the superior and inferior mesenteric arteries, form plexuses around these vessels, and receive additional branches from the lumbar or abdominal ganglions of the sympathetic nerves; these nerves then twine around the mesenteric arteries and their branches, and are thus conducted to the intestines, in the internal tunic of which they terminate. *See* Anatomy of the Nervous System. The student may now remove the abdominal viscera. Tie the lower extremity of the œsophagus and the upper end of the rectum, each with two ligatures, and divide these tubes between them; dissect out the vena cava from the liver, cut across the hepatic vessels, the cœliac axis, the superior and

inferior mesenteric arteries; and then separate the liver, spleen, pancreas, and alimentary canal, from their connexions to the parietes of the abdomen; next clean the surface of the abdominal aorta and vena cava, the right and left kidneys, and the renal capsules. The *abdominal aorta* may be now seen to pass into the abdomen, between the crura of the diaphragm, opposite the last dorsal vertebra; it then descends obliquely to the left side of the median line, and divides on the body of the fourth lumbar vertebra into the right and left iliac arteries. The abdominal aorta sends off the following branches: first, the two phrenic arteries; second, the cœliac axis; third, the superior mesenteric artery; fourth, the two renal arteries; fifth, the spermatic arteries; sixth, the inferior mesenteric artery; also four or five pair of lumbar arteries from its posterior part; and lastly, from the angle of its division the middle sacral artery descends. The *right* and *left iliac arteries* descend obliquely outwards and backwards; that of the right side is the longer of the two; opposite each ilio-sacral articulation each common iliac artery divides into the internal and external iliac. The *external* proceeds along the inner side of the psoas magnus, and, passing beneath Poupart's ligament, becomes the femoral artery; just above this ligament it sends off two branches, the epigastric and the circumflex ilii. The *internal iliac artery* descends into the pelvis, and gives off several branches, which shall be noticed afterwards in the dissection of that cavity. The veins in the abdomen correspond to the arteries; each *external iliac vein* ascends along the inner side of the artery of the same name, and near the sacrum is joined by the *internal iliac vein*, which ascends from the pelvis; the union of these on each side form the *common iliac veins;* each of these ascends behind its accompanying artery; and opposite the right side of the fourth or fifth lumbar vertebra these veins unite, and form the inferior or ascending vena cava; the left common iliac vein is longer than the right, and passes behind the right iliac artery. The *vena cava* ascends along the right side of the aorta, and receives the spermatic, renal, and lumbar veins; it lies, inferiorly, on the right psoas muscle, and on the right crus of the diaphragm; superiorly, it inclines forwards and to the right side, and enters the fissure in the liver; here it receives the venæ cavæ hepaticæ; it then passes through the opening in the tendon of the diaphragm, and arrives at the right auricle of the heart. On each side of the abdominal aorta the *sympathetic nerves* may be seen; they pass from the thorax into the abdomen, beneath the true ligamentum arcuatum, and then descend between the crus of the diaphragm and the psoas magnus on each side; in this course they form three or four oval ganglions. At the last lumbar vertebra these nerves pass outwards and backwards, and then descend into the pelvis.

The commencement of the *vena azygos* may be observed on the right side of the aorta; it is formed by the first or second lumbar veins, which communicate with the renal and inferior lumbar veins, and sometimes with the inferior vena cava. The vena azygos enters the

thorax between the aorta and the right crus of the diaphragm, and then ascends along the posterior mediastinum. The *thoracic duct* also may be seen to commence in the abdomen by the union of several absorbent vessels on the body of the third lumbar vertebra; this vessel, being larger here than it is above, has received the name of *receptaculum chyli;* this, however, does not always exist. The thoracic duct is covered at first by the aorta; it then ascends obliquely to its right side, and enters the thorax between it and the vena azygos.

Let the student next examine the urinary organs; these consist, first, of the two kidneys, which secrete the urine; second, of the two excretory ducts, the ureters, which convey this fluid to, third, the urinary bladder, which retains it for a longer or shorter time; and fourth, the urethra, which discharges it externally, and which, in the male, is common to both the urinary and genital organs.

## SECTION IV.

### DISSECTION OF THE KIDNEY AND URETERS.

THE *kidneys* present the well-known form of the kidney-bean; the size is not so variable as that of some other glandular organs, yet one is often found larger than the other; in general both are larger in the infant, and in the female than in the male. The average dimensions are from four to four and a half inches in length, about two in breadth, and one in thickness. Sometimes there is only one kidney, which is then very large, of an irregular shape, and partly extended across the spine like the pancreas; sometimes the two kidneys are connected by a transverse glandular band, and resemble a horse-shoe, the concavity upwards, in the same manner as the lateral lobes of the thyroid body are connected by the transverse or middle lobe, the concavity of which is also upwards. The colour is a dark, brown red; the texture is very firm to the touch.

Each kidney is situated in the posterior part of each lumbar region, behind the peritonæum, between the last rib and the crest of the ilium, and corresponds to the two last dorsal and two first lumbar vertebræ; the right kidney is often a little lower than the left, particularly in the female, also if the liver be larger than usual; they are imbedded in a quantity of adipose substance, and lie on the diaphragm, psoas, and quadratus lumborum muscles, the fascia of the tranversalis abdominis intervening; the right kidney is also sometimes in contact with the iliacus internus muscle: the ascending colon and duodenum lie anterior to the right, and the descending colon to the left kidney; the right is in contact with the liver above and with the cæcum below; and the left with the spleen above and the sigmoid flexure of the colon below. The anterior surface of each is convex and directed

outwards; the posterior is flat, and directed inwards; in the young subject the surfaces are very uneven, the kidneys at that age being lobulated. The external border of each is smooth and convex, and directed outwards and backwards; the concave edge is of much less extent, looks forwards and inwards, and presents the notch, or hilus, or pelvis, which is more open or distinct anteriorly; it contains the arteries, veins, and excretory duct; the veins are usually, but by no means constantly, anterior; the arteries, five or six in number, are behind these; and the ureter is posterior and inferior to both; a plexus of nerves and lymphatics accompany these vessels. The superior end of each kidney is rounder, larger, and nearer to the spine than the inferior, which is directed outwards; it is also surmounted by the suprarenal body. The kidney is described by some as having three tunics: serous, cellulo-adipose, and fibrous; the latter, however, alone deserves this name; the peritonæum is but very partially connected to its anterior surface only, and to a variable extent; the cellular and adipose substance, in which each organ is imbedded, differs in quantity and quality; in the young the cellular tissue predominates, in the old the adipose; the proper coat is a strong, smooth, fibrous membrane, which adheres closely to its substance, preserves its form, and is continued into its interior, along the vessels, as far as the calyces of the kidney; it also sends in small shreds or processes from almost every point of the surface; these are friable, and break in tearing this membrane from the gland, which is easily effected, and in doing which it can be divided into two distinct laminæ. Remove one kidney from the subject, and divide it by a perpendicular incision from the convex to the concave edge; the gland will then be found to consist of two distinct substances, the external or vascular, the internal or membranous, or the tubular cones. The external, vascular, or *cortical substance*, forms the superficial lamina of the gland, is about two lines thick, and sends long prolongations inwards, between the tubular fasciculi; it is of a deep red colour, like muscle, particularly along its internal margin; when the three vessels of the kidney are

*Fig.* 48.*

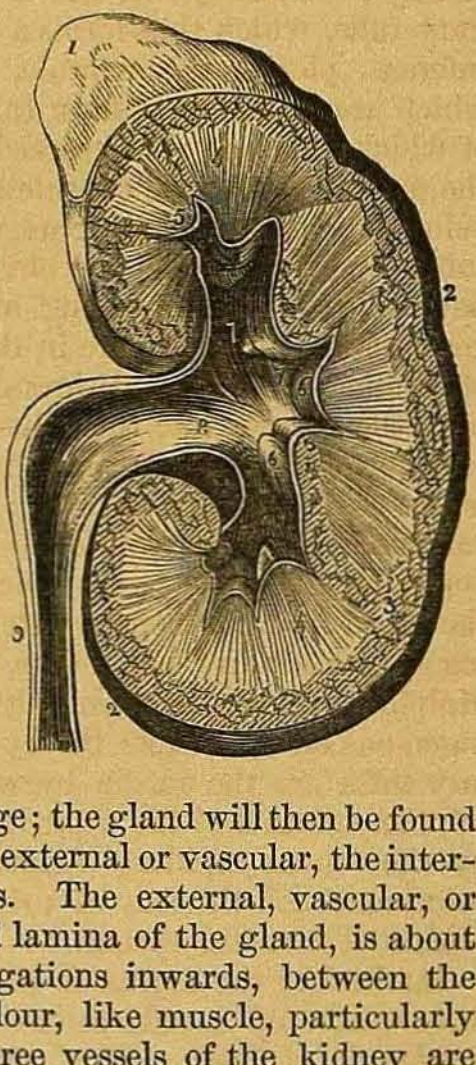


* A section of the kidney, shewing its internal structure. 1. The suprarenal capsule, attached to the upper extremity of the kidney. 2. 2. The fibrous tunic of the kidney. 3. The vascular or cortical substance. 4. 4. The tubular portion. 5. 5. The papillæ. 6. 6. The calyces. 7. 7. 7. The infundibula. 8. The pelvis of the kidney. 9. The ureter.

injected minutely with differently coloured fluids, and sections made of the cortex, the latter will be found to be very vascular and very tubular, as well as granular or glandular in appearance; the minute arterial and venous ramifications are entangled with convoluted uriniferous tubes (tubes of Ferrein), and by the aid of the microscope an immense number of small granules can be detected in connexion with these tubes; these are the corpora or acini of Malpighi. The intimate structure of these Malpighian corpuscles has been ably investigated by Mr. Bowman (the account of his anatomical researches, as well as his physiological views respecting the probable function of these bodies, have been published in his excellent paper in the Phil. Trans., 1842); they are very minute, about the $\frac{1}{100}$ of an inch in diameter; their number corresponds with that of the convoluted urinous tubes, within the extremity of one of which each of them is lodged: a Malpighian corpuscle is a tuft of capillary arteries, arranged in loops closely pressed together and enclosed in a slight dilatation of the urinary tube, which thus forms a capsule for it: a small artery, called vas inferens, pierces this capsule, and then divides into the branches, which are coiled up to form this little vascular ball, from the interior of which a minute vein proceeds (vas efferens), which is smaller than the artery, pierces the capsule close to it, and along with other similar veins enters the venous plexus, which surrounds the convoluted urinous tubes, and from which the blood is ultimately conveyed from the kidney by branches converging and uniting to form the renal or emulgent vein. Thus there are in this gland two perfectly distinct systems of capillary vessels, and through both the blood passes in its course from the arteries into the veins: the first is an arterial capillary system, forming the Malpighian tufts enclosed within the dilated extremities of the uriniferous tubes; the second is the venous plexus, which surrounds these convoluted tubes; this latter plexus resembles the portal plexus in the liver, which is entirely venous, though it receives the blood from the hepatic artery, and is in that gland the true secreting agent: so this renal plexus, which receives the efferent vessels of the Malpighian tufts, is essentially venous. Mr. Bowman advances the ingenious and plausible theory that the Malpighian or arterial capillary tufts are the media by which water, and the more simple and soluble elements of the urine, are discharged from the blood; whereas by the venous capillary plexus, which is analogous to the portal, the proximate constituents of urine, such as urea, lithic acid, &c., are separated from the system.

Internal to the cortex is the *tubular substance*, which consists of fine vessels of a pale colour and dense structure; arranged in pyramids or striated conical fasciculi, about fifteen in number; the base of each is directed towards the circumference, the apex towards the hilus of the kidney; the base adheres to the cortex, which, by its prolongations inwards, envelopes each cone completely, except its apex or papilla; all these envelopes are continuous; the section of this gland, therefore, shews that it is lobulated; each lobe is a perfect kid-

ney; these lobes are partially separate in the fœtus, but in many animals are still more so during their whole life; in some they are so separate as to resemble a bunch of grapes; in partial disease of this organ, also, this lobular structure is occasionally well marked. These tubes are like fine hairs; they are numerous towards the cortex, but diminish in number as they approach the apex or papilla; although their diameter must be extremely minute, yet pressure on the cortical substance causes the urine to exude distinctly from these cut tubes, not only when they have been divided in the section, but also through numerous puncta on each papilla; in tracing these ducts from the apex of each cone towards the base, or towards the cortex, their number appears to increase by dichotomous division, and on arriving at the cortex a total change takes place in their appearance; at first view they would seem to end, or to commence abruptly at that line, but close inspection proves that they are continued into the cortical tissue, but altered in appearance and in direction; they become ramose and tortuous, are inseparably entangled with the venous plexus and the arterial capillaries, and end either in cæca or in loops or arches; hence the tubular structure of the kidney may be considered as consisting of two portions, one is convoluted and distributed through the cortex, the other is arranged in converging striæ to form the cones or pyramids, and is only enveloped by the cortex; this latter portion, or the tubular cones, are probably only excretory in their office; while the former, or the convoluted tubes, being surrounded by the venous plexus, and enclosing the Malpighian tufts, must be the seat of the essential part of the secreting process: at the junction of the cortex and the pyramids a line of a deep red or purple hue is observable, marking, in an undulating course, the whole extent of the inner surface of the former; in this line some peculiar mode of division and inosculation occurs between the renal arteries of each lobule, which up to this point have been distinct.

The *papillæ* or the *mamillary* processes form the apices of the cones, and as two of the latter often converge into one point, the number of papillæ is less by four or six than that of the cones; each papilla is perforated by several small holes, through which the urine may be observed to flow when the tubular cones are compressed; some of them are blunt-pointed or cupped, with the orifices in their depressions; each papilla is covered by a fine mucous membrane, which is continued through the foramina into the tubuli; this membrane is also expanded round its base, and forms a little cup or calyx, which receives the fluid as it distils from the puncta; the papillæ possess no peculiar tissue, and are, therefore, essentially similar to the tubular cones which end in it, or which form it; in its mucous epithelium, probably, there is some difference.

The calyces are the membranous or fibro-mucous cups which, by one extremity, embrace the bases of the papillæ, and by the other join the adjacent calyces to commence the ureter; their number, six or eight, is less than that of the papillæ, as two of the latter often

unite into one, and are received into the same calyx; they are dense and white, composed externally of the fibrous coat of the kidney, and internally of a fine mucous membrane, which is continued from the ureter along the pelvis of the kidney, lines all the calyces, and is reflected in the form of a very fine membrane over each papilla, and most probably is continued into the tubuli uriniferi. The calyces in each extremity, as also those in the centre, unite into three small tubes, which, being of a funnel shape, are called *infundibula;* these have but a short course, and soon terminate in the *pelvis* of the kidney, which is a membranous reservoir formed by the union of the calyces or the infundibula, of a flattened oval figure, placed behind the blood-vessels of the kidney, and terminating in the ureter, which it resembles in structure; adipose substance generally surrounds it, as well as the infundibula and the calyces. Each kidney receives a very large artery (the renal or emulgent), which arises at right angles from the aorta: this divides into six or eight branches, which enter the notch in the gland, subdivide into numerous fine vessels, which proceed between the tubular portions to the cortex; at the line of junction of these two, or along the convexity of each conical fasciculus, these branches form a net-work of inosculating arches, from which proceed numerous capillaries; some are for the nutrient functions, and others, according to Mr. Bowman's views, become the vasa inferentia for the Malpighian corpuscles, in which they divide and subdivide, and finally converge to the vasa efferentia, or the efferent veins, which are smaller than the arteries: these veins then proceed to join the capillary venous plexus surrounding the cortical or the convoluted uriniferous ducts. The arterial plexus in the corpora Malpighiana separate the aqueous and saline, and the venous plexus the proximate principles of the urine, into the convoluted ducts; thence the fluid passes into the conical tubuli uriniferi, which convey it to the papillæ, through the small pores of which it gradually flows into the calyces, and from these into the pelvis, and so into the ureter. From the renal venous plexus the blood is conveyed by veins which converge to form the renal or emulgent veins; these veins, one on each side, open distinctly into the cava; the left renal receives the spermatic veins, is longer than the right, and passes in front of the aorta, below the vena porta and behind the duodenum and the superior mesenteric vessels.

The nerves are derived from the solar plexus, lesser splanchnic, and lumbar ganglions of the sympathetic. The lymphatics join the lumbar glands.

The function of the kidneys is to separate or excrete certain effete azotized substances, especially urea, which cannot be retained in the body with safety to health, or even with long continuance of life; these substances have accumulated in the blood during its circulation, and, if not removed, soon give rise to general disturbance of the system; the nervous centres in particular become deranged in function, and suffer as if under the influence of narcotic poison.

The *ureter* is the excretory duct of the kidney, and extends from it to the urinary bladder; each ureter is about eighteen inches long, and about the size of a goose-quill; its coats are very pale, and always appear collapsed. These vessels take an oblique course downwards and inwards to the pelvis; each then inclines a little forwards, continuing still to run downwards and inwards to the inferior and posterior part of the bladder, passes obliquely between the muscular and mucous coats of this viscus, and perforates the latter at the posterior angle of the trigone. Each ureter passes anterior to the psoas magnus and to the iliac vessels, is covered by the peritonæum, and crossed obliquely by the spermatic vessels, and near its termination in the male subject by the vas deferens; and in the female by the Fallopian tube and broad ligament of the uterus. In the male each ureter attaches itself to the bladder at the posterior extremity of each vesicula seminalis, and now much diminished in size, it runs obliquely for the extent of an inch between the tunics of the bladder, and opens internally (as will be seen hereafter in the dissection of the pelvic viscera) about an inch and a half from the commencement of the urethra, and about the same distance from its fellow. In the female the pelvic portion of each ureter is longer than the male; they also lie at a greater distance from each other, and perforate the bladder nearer to its neck than in the male subject. The ureter is very dilatable; it is composed externally of a fibrous coat, and internally of a pale mucous membrane, without any valves or folds; it is surrounded by cellular tissue, and in some situations is partially covered by peritonæum; muscular fibres ascend from the bladder, and can be traced for some inches along its parietes. The ureters are larger at their commencement and smaller at their termination; the intermediate portion of each is nearly of one uniform diameter: two ureters on one or both sides are occasionally met with. The mucous membrane of the ureters and kidneys will be more particularly examined in connexion with that of the bladder and urethra.

Attached to the upper extremity of each kidney is a small gland-like substance, named *renal capsule*, or the *suprarenal* or *atrabiliary body;* of a crescentic shape, the base attached to the kidney by cellular membrane and by small blood-vessels, the apex inclining inwards and forwards; these organs lie on the diaphragm, and on the semilunar ganglion of each side, opposite the tenth dorsal vertebra, and are covered, that on the right side by the vena cava and duodenum, and on the left by the spleen and pancreas; a vein also runs along their anterior surface; the right adheres to the under surface of the liver, the left is in contact with the spleen; these bodies are composed of an external thick lamina or cortex, which is of a yellow colour and striated with perpendicular lines, and of an internal substance, soft or medullary, of a dark brown colour, spongy, and traversed by vessels, often so soft and pulpy as to break down under examination. These organs receive several arteries; they are derived from the phrenic, the aorta, and the renal; the veins are larger, and open into the

cava or the renal vein: the nerves are numerous, they are from the semilunar ganglion and from the solar and renal plexus. In the interior of each we often find the appearance of a small triangular cavity filled with a brownish fluid; the walls of this cavity are very rough, no excretory duct can be found leading from it: the presence of this cavity is by no means uniform, some deny its existence altogether, and attribute the appearance of it either to decomposition or laceration, or to the opening of the vein. The exact use of these bodies is not ascertained. The renal capsules in the adult are thin, and of a brownish yellow colour, and very variable as to size; the right has been observed to be larger and of a different form from the left: in the fœtus they are very large and vascular, nearly equal to the kidney in size, and contain a quantity of reddish fluid. These bodies, though usually described as appendages to the kidneys, yet have no such intimate connexion with them as to lead to the idea that there is any functional association between these organs; there is more reason to suppose that they are influential in sanguification during uterine life, and, like the liver, thymus, and thyroid bodies, all large at that age, are concerned in the economy of the fœtus, and probably assist in performing some offices connected with embryonic existence, nutrition, and growth.

The kidneys occasionally present the following *morbid* appearances: inflammation or nephritis is denoted by increased redness, of a dark tint, vascularity, and induration, and sometimes attended with purulent infiltration; when the ureter is engaged it is also found thicker and redder than natural, with purulent matter on its inner surface. Inflammation also sometimes ends in a well-defined abscess in the kidney. The inflammation may have involved all the tissue in the gland as well as its coverings; or it may be confined to the former without the latter being engaged, or it may be seated in the mucous lining of the calyces and pelvis of the ureter. In both acute and chronic inflammation of this organ red dots and ecchymosed spots are often observable both on the surface and in the cortical tissue; similar dots are also often seen in the early stage of Bright's disease, or granular degeneration with albuminous urine; these probably indicate inflammation of the Malpighian corpuscles, which, as they become enlarged and indurated, impair the other tissues, and the function of the gland is proportionably deranged. These glands are frequently the seat of scrofulous abscess, in which the pus is white and curdy. Calculi are very common in the kidney, sometimes they are small, and found in the tubular portion, but generally they are large, and fill up more or less of the pelvis of the ureter, not unfrequently extending by a stalk a short distance along that tube, and presenting a branched appearance at the opposite extremity corresponding to the infundibula. When the calculus is large and obstructs the flow of urine, the membranous portions of the gland become dilated, and should the stone be impacted lower down in the ureter, this tube will also become greatly dilated above the seat of the obstruction; in such cases the interior of the kidney will be-

come more and more compressed and absorbed, and in time nothing will remain but the thickened capsule with a thin layer of vascular and glandular matter, containing several cells which communicate freely; sometimes the whole of the sac will be found in a state of suppuration. Hydatids are common formations in the kidney, they are found on its surface and beneath its capsule; they are generally scattered, each in its distinct cell. The kidneys present great variety as to form, size, colour, and consistence, without any known corresponding difference in function. In diabetes they have been found large, vascular, soft, and easily torn; in purpura with hematuria the lining membrane has appeared turgid, and petechiæ have been distinctly seen beneath it. The kidneys may be the seat of cancer, fungus hæmatodes, and melanosis.

The bladder and urethra are the next divisions of the urinary organs to be examined; as these, however, are pelvic viscera, we shall postpone their consideration for the present, and the student should next examine the deep muscles of the abdomen, viz., the diaphragm, the quadratus lumborum, psoas parvus, psoas magnus, and iliacus internus of each side.

## SECTION V.

### DISSECTION OF THE DEEP MUSCLES OF THE ABDOMEN.

The diaphragm is one of the most important muscles in the human body, second only to the heart; it is the principal agent in respiration, and belongs to the class of mixed muscles; volition can influence it to a great degree, but cannot wholly control its actions, which continue with surprising regularity through the whole of life, during sleeping and waking time, almost without our cognizance; its structure also partakes of the mixed character; in colour, in the possession of tendon and of fixed osseous attachments, it is like the voluntary, while in thin tissue and expanded form, and in being single, it resembles the involuntary or the hollow muscles; and though it is attached to or encircled by bones, yet it is not designed to act on these as levers, like the voluntary muscles, which latter always lie around or external to the bones they are to move, whereas its contractions are only intended to influence the regions and the viscera between which it is interposed. This muscle should be examined both on its abdominal and on its thoracic aspect; in the former it is exposed when the abdomen has been opened, its viscera removed, and the peritonæum with the connecting lamina of fine and closely adhering cellular tissue dissected from it; in the latter the thorax must be opened before the abdomen, and the heart and lungs, with the pericardium and pleuræ, detached: the inferior surface is generally selected for dissection and

description. The diaphragm may be said to divide the body into an upper and a lower half, and to constitute an active and moving septum between the thorax and the abdomen, forming an irregularly convex floor to the former, and a vaulted or concave ceiling to the latter; it

*Fig. 49.**

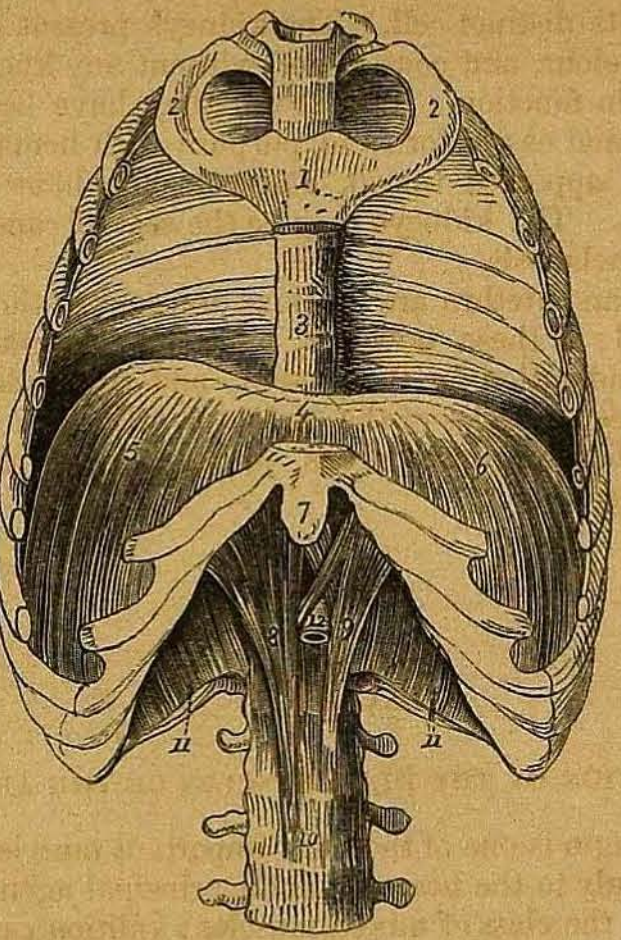


crosses the median line, and, being but partially allied to the voluntary muscles, it wants the lateral symmetry of that system, although it is partially divided before and behind into right and left; the former, however, is more extended and more deeply arched than the latter. It is usually divided by the anatomist into two portions, but which are not to be considered as distinct muscles: one is superior, large, and broad transversely (the true or costal diaphragm); the other is inferior and posterior, small, thick, and narrow (the appendix, crura, or pillars, or vertebral diaphragm); these two portions, though separate at their osseous attachments, are yet blended together in the common central tendon, and present a fan-shaped expansion, bent at their junction, the broad superior expanded portion being nearly horizontal or with an aspect downwards and forwards, while the posterior infe-

* A view of the diaphragm during expiration. 1. The superior extremity of the sternum. 2. The first rib. 3. The dorsal region of the spine. 4. The superior surface of the central tendon of the diaphragm. 5. The right lateral portion of the diaphragm. 6. The left lateral portion. 7. The xiphoid cartilage. 8. The right crus or pillar of the diaphragm. 9. The left crus. 10. The body of the third lumbar vertebra. 11. The posterior fibres of the diaphragm. 12. The aorta passing between and behind the pillars of the diaphragm.

rior portion is vertical, and joined to the former at nearly a right angle, and has its surfaces directed forwards and backwards.

The *superior* or true *diaphragm* is broad, thin, and circular, or rather transversely elliptical, being narrower from the sternum to the spine than from side to side, fleshy in the circumference, tendinous in the

*Fig.* 50.*

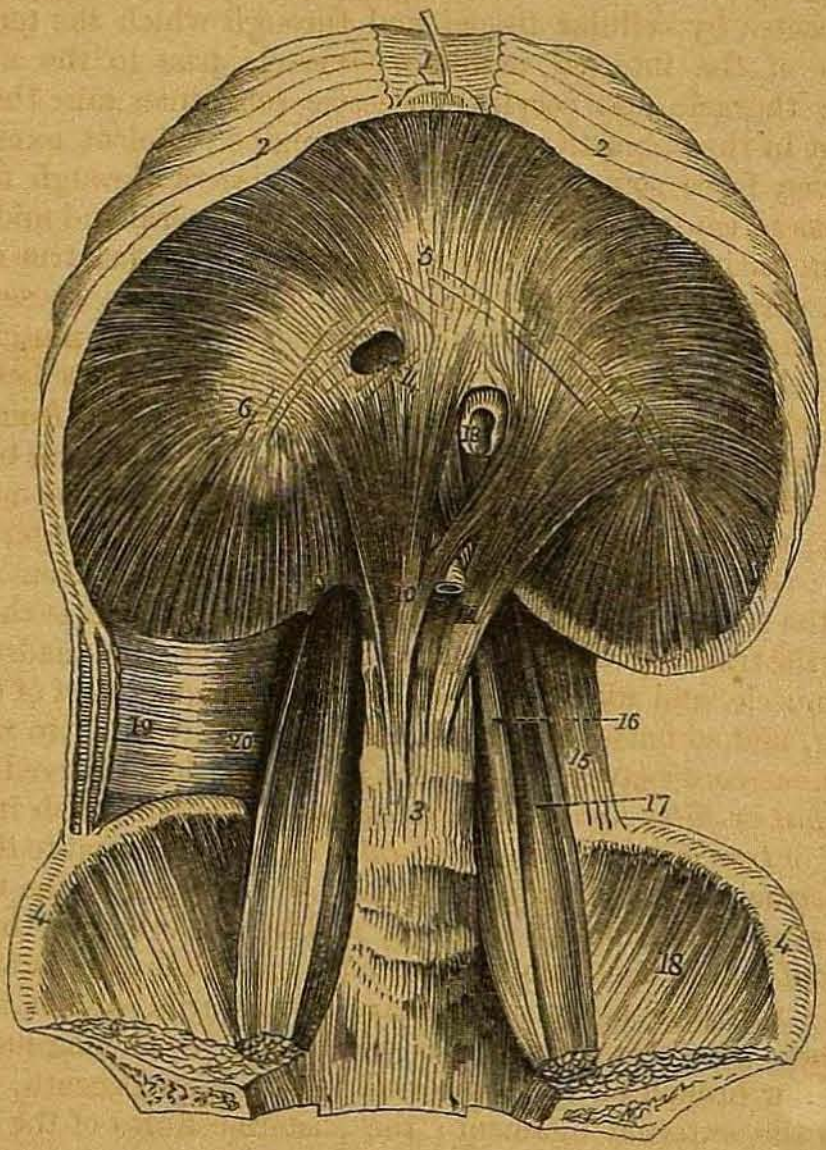


* The inferior or abdominal surface of the diaphragm. 1. The sternum. 2. 2. The costal cartilages. 3. The body of the third lumbar vertebra. 4. 4. The crests of the ilium. 5. 6. 7. The superior or true diaphragm: the figure 5 is placed on the anterior portion of the central tendon, the figure 6 upon the right, and the figure 7 upon the left division. 8. The posterior fibres of the diaphragm arising from the false or external ligamentum arcuatum. 9. The true ligamentum arcuatum. 10. The right crus of the diaphragm. 11. The left crus. 12. The aortic opening in the diaphragm through which the aorta is seen passing. 13. The inferior extremity of the œsophagus passing through the œsophageal opening. 14. The opening for the vena cava. 15. The quadratus lumborum muscle. 16. The psoas parvus. 17. The psoas magnus. 18. The iliacus internus: the inferior extremities of the last three muscles have been removed. 19. The posterior portion of the transversalis abdominis muscle giving origin to its posterior tendon, the anterior lamina of which (20) is seen passing in front of the quadratus lumborum muscle.

centre, *arises* anteriorly from the back part of the xiphoid cartilage by two weak fasciculi, separated by a line of cellular tissue (the median line, analogous to that which separates the crura posteriorly); these fibres are sometimes absent, and then a considerable deficiency exists in this situation; in some they are very strong, and appear to draw the cartilage inwards and backwards; external to these, and between them and the lateral fibres, there is in general a well-marked triangular space on either side, in which the pleuræ and peritonæum are connected by cellular tissue, and through which the terminating branches of the internal mammary vessels pass to the abdominal parietes; thoracic and cervical abscesses sometimes take this course, and point in the epigastric or umbilical region; violent exertion also might even force some of the abdominal viscera through this weak part, so as to cause diaphragmatic hernia; the lateral and middle fibres arise from the internal surface of the cartilages of the last true and of all the false ribs, and from their contiguous bony portions, these fasciculi, at their origin, indigitate with those of the transverse muscles of the abdomen; the anterior are the shortest; the middle, those between the eighth and eleventh ribs, are the longest; the fasciculi from the two last ribs are often attached to a considerable portion of these bones, and are also often connected to the transverse muscles by a common aponeurosis; the posterior fibres are thin and weak, but longer than the anterior; they arise between the last rib and the spine, from the upper part of the strong but thin tendinous expansion, which is the anterior layer of the transversalis tendon, and which covers the quadratus lumborum muscle, and adheres to the last rib; the upper part of this fascia is strong, and so tense, when the last rib is everted, as to resemble a ligamentous cord between it and the spine, and has received the name of *external* or *false ligamentum arcuatum*, to distinguish it from the *internal* or *true ligamentum arcuatum*, which lies internal to the former, and is a true tendinous arch, attached by one cornu to the transverse process of the first lumbar vertebra, and by the other to the body of the second and to the tendon of the adjacent pillar or crus of the diaphragm; this true ligament, concave downwards, arches across the sympathetic nerve and the upper end of the psoas magnus muscle; the anterior branch of the last dorsal nerve passes beneath, or rather through the external ligament; the posterior fibres of the true diaphragm arise from these two ligamentous structures; those from the true or internal ligament are stronger, and are in connexion with the outer border of each crus; those from the external or false ligament are pale, weak, and indistinct, and very often deficient in muscular structure; from this extensive circular origin the fibres converge towards the central tendon, like radii from the circumference to the centre of a circle; the anterior, short and slender, pass backwards and upwards to its border, the lateral or middle fibres inwards and upwards, and then a little downwards to its sides, forming curved lines or arches concave downwards, convex upwards; those on the right side are longer and more arched than those on the left, the con-

vexity of the former being on a level with the fourth rib, that of the latter with the fifth or sixth; these long, curved, lateral fibres are immediately beneath the lungs; the posterior fibres pass upwards and forwards to reach the back part of the tendon.

The *central* or *cordiform tendon* of the diaphragm (phrenic centre) occupies considerable extent, and being surrounded or insulated by fleshy fibres, it constitutes the diaphragm a digastric muscle both from before backwards, and from side to side. It is a thin, tendinous expansion, of great transverse breadth. Its figure has been compared, not unaptly, to the trefoil leaf, the posterior notch receiving the insertion of the crura as the stalk, one leaf or lobe extending towards the left side, beneath the left pleura; this is the smallest division, is long and narrow: a second leading forward towards the xiphoid cartilage; this is usually the broadest and strongest portion, lies on a plane inferior to the others, and is immediately beneath the heart and pericardium: the third, extending to the right side, is larger than the left, and very often equal to the anterior or middle division. The relative size of these lobes is variable, and the tendon altogether is smaller in proportion in the young than in the old; its fibres radiate from behind forwards and outwards, but are interlaced by transverse and oblique bands, in addition to which strong accessory fasciculi are attached to it, and cross it in different directions; some of these are unattached in their centre, these are chiefly seen on the right leaf. This platted texture is more distinct on the abdominal than on the thoracic surface; it obviously imparts mechanical strength to this thin expansion. Behind the left division is the fleshy opening for the passage of the œsophagus; and behind the right, or rather in the angle between it and the middle lobe, is the tendinous one for the vena cava; of these we shall speak presently. The tendon is the highest part of the diaphragm, less arched and more fixed than the fleshy portion.

Behind and below this tendon are the two *crura* or *appendices*, or *vertebral portions* of the *diaphragm*, nearly parallel to the spine. The *right* crus, longer, thicker, and on a plane anterior to the left, *arises* by tendinous fibres from the anterior and right lateral surface of the bodies of the first four lumbar vertebræ and their intervertebral ligaments; the *left*, smaller and on a posterior plane, *arises* from the left side of the two first vertebræ; both are confounded with the anterior vertebral ligament, and both also receive their external fibres from the true ligamentum arcuatum; they ascend obliquely forwards, diverging a little, but are soon connected to each other by a semilunar tendinous band, concave downwards, which is arched over the aorta and thoracic duct; this tense cord is opposite the last dorsal vertebra; it might be named the middle ligamentum arcuatum; from its convex edge fleshy fibres proceed to each crus. A little above this the crura not only approximate so closely as to appear as one, but each sends a fasciculus to join the other; these are named the *decussating fasciculi*: that from the right crus is the larger, that from the left is smaller, and sometimes it crosses the former on a plane anterior to it. The exact

arrangement of these fibres is very variable, but they always separate the aortic from the œsophageal opening. The crura continue their course upwards and forwards, and, increasing in breadth, are inserted into the notch and into the posterior border of the central tendon. The right crus is immediately covered by the vena cava, the right suprarenal body, the semilunar ganglion, and the liver; the left by the aorta, left suprarenal body, and semilunar ganglion, spleen, and stomach. The duodenum, pancreas, and vena cava are also anterior to both. The superior or true diaphragm is related inferiorly to the liver, stomach, spleen, and kidneys; it is lined throughout by the peritonæum, except at the coronary ligament of the liver, where the latter organ is in contact with it; also posteriorly the kidneys intervene. It adheres to the muscular fibres by means of a fine but compact lamina of cellular tissue; much of the physical strength of the muscle depends on this connexion; the fasciculi are often separated by considerable intervals, particularly near the ribs, and in the interstices the pleura and peritonæum are in juxtaposition. The thoracic surface is covered by three serous membranes, the pleura at each side, and the pericardium in the centre; this surface is flat in the middle, and convex on each side, particularly the right; the fibrous lamina of the pericardium adheres most intimately to the circumference of the anterior division of the tendon, particularly in front, where fibres of the latter ascend upon the former, and are lost in its tissue; these serve to fix the tendon, and prevent its depression or descent. The serous lamina is connected to the tendon more loosely within this fibrous attachment; the pericardium is also attached to the fleshy fibres between the anterior and left lobes; the adhesion between this membrane and the tendon is much less intimate in the child, and in some animals scarcely exists; in the mediastinal spaces, before and behind the pericardium, the pleuræ have no connexion to the diaphragm; these membranes cover the superior lateral surfaces very perfectly, except small portions of their circumference, where the fleshy fibres come into contact with the triangulares sterni, intercostal, psoas magnus, and quadratus lumborum muscles; the diaphragmatic portions of the pleuræ and the connecting cellular tissue are not so dense as the corresponding structures on the lower surface, and do not impart such physical strength. Indeed the diaphragm is very variable as to texture or apparent strength; in some the fasciculi are very pale, weak, and separate; and in all cases, when both surfaces have been cleanly dissected, it possesses but little firmness or cohesion, loses its form, and becomes soft and flaccid; much, therefore, of its normal strength and tension depend upon its investments, particularly upon that of the lower surface

Three large openings exist in the diaphragm: one for the aorta, of a semilunar form, and in the median line; one for the inferior cava, nearly square and to the right side; and one for the œsophagus, elliptical and to the left side.

The *aortic opening* leads from the posterior mediastinum into the

abdomen, opposite the last dorsal vertebra, and nearly in the mesial line; it is rather a tendinous passage behind and between the crura, which fold inwards and meet in an aponeurotic expansion behind the artery, while, anterior to the vessel, is their connecting tendinous semilunar cord. The thoracic duct and vena azygos ascend through it along the right side of the aorta; the splanchnic nerves also, especially the left, sometimes escape by it; but these nerves, particularly the right, very often perforate the crus on each side, and thus divide one or both into secondary crura or pillars. This is almost always the case with the lesser splanchnic nerves; the parietes of this foramen are fixed, strong, and tense, and the fleshy fibres, which arise from its margin, cannot possibly contract its calibre, or constrict the parts passing through, as some have supposed.

The *opening* for the *œsophagus* and eighth pair of nerves, is superior, anterior, and to the left of the aortic, opposite the ninth or tenth dorsal vertebra, but not perfectly fixed, of an oval form, about an inch and a half long, and directed obliquely backwards and downwards; it is immediately behind the central tendon, which sometimes bounds its anterior extremity; the decussating fasciculi form its parietes, separate it from the aortic passage, and would appear capable of contracting it, and thereby closing the cardiac orifice of the stomach so as to prevent regurgitation of its contents when subjected to the pressure of the abdominal parietes.

The *opening* for the *vena cava* is at the back part of the right tendinous leaf, in the angle between it and the anterior, in front of the insertion of the right crus and opposite the ninth dorsal vertebra, on a higher plane than either the aortic or œsophageal, to the right side of the median line, and nearly fixed in its position; its figure is an irregular square, the anterior or right sides being longer than the others; it appears larger than the vein, along which small filaments of the phrenic nerves also enter the abdomen; its margins are perfectly tendinous, with fasciculi crossing at right angles, and are attached to and prolonged upon the vessel, so as to form a sort of tendinous and valvular passage; the anterior and lateral descending to the liver, the posterior ascending to the pericardium and to the right auricle; the contraction of the diaphragm, so far from constricting this opening, must have an opposite effect, as the fleshy fibres, which are attached to three of its sides, will have a tendency to divaricate them, and so to enlarge the opening. The dimensions of the œsophageal and vena caval openings are so accurately adapted to the parts passing through them as to leave no opportunity for the escape of any of the viscera of the abdomen into the thorax; therefore, the diaphragm can be scarcely said to be deficient in these situations. The same remark applies to the five tendinous arches posteriorly, namely, the aortic in the middle, and the two ligamenta arcuata on each side; the first is fully occupied by the vessels passing through it, and its edges are connected by a dense tissue to the artery and to its great cœliac branch; the space beneath the true ligamentum arcuatum is filled by the sympathetic

nerve and psoas magnus muscle, and a fascia is continued from its margins along the surface of the latter; there is no space or deficiency beneath the external ligamentum arcuatum; in addition to the three openings just described, there are numerous small ones for the passage of nerves and vessels, but too variable as to situation, and too insignificant in size, to merit particular attention.

The diaphragm is well supplied with blood; it is the seat of many inosculations between vessels from different and distant sources, whereby a due supply is secured, one proportioned to its importance in the economy, and adequate to maintain its irritability and power of long continued action; the phrenic arteries behind and other small branches from the aorta, from the renal and lumbars of both sides, the internal mammary in front, and the intercostals all around, are freely distributed to its tissue; the veins open into the cava either directly or into other veins proceeding to this trunk.

The nerves are numerous, and, in conformity with the mixed character of the muscle, are derived from the spinal and from the sympathetic systems. The spinal nerves are symmetrical; of these the two phrenic are the most important; they arise from the cervical segment of the spinal cord, or from the third and fourth cervical nerves, descend along the anterior scaleni into the thorax, and, passing on either side of the pericardium, arrive at the diaphragm; at the lower part of the neck they communicate with the sympathetic, pneumogastric and descendens colli nerves; near the diaphragm they divide into four or five branches, most of which pierce the muscle anterior to the tendon, but one or two accompany the vena cava on the right side; they ramify on the abdominal surface, the larger pass backwards, and many of them communicate with branches from the solar plexus; the intercostal branches of the five or six inferior dorsal nerves are distributed to its costal fasciculi, and branches from the superior lumbar to the crura; delicate filaments from the pneumogastric nerves are also sent to it from the cardiac portion of the stomach, and each phrenic artery is accompanied by a fasciculus from the solar plexus; these latter follow the divisions of these vessels into the most minute ramifications. Pathological research, and experiments on living animals, have established the fact that the phrenic nerves are the most influential agents in the respiratory actions of this muscle; the inosculations between these and the eighth, ninth, and sympathetic, establish important sympathies between this muscle and the tongue, larynx, lungs, heart, and stomach: the dorsal and lumbar branches probably associate it with the muscles of the trunk, as we find it co-operating with these in all the violent exertions of the body, while the branches of the solar plexus, which accompany its chief nutrient arteries, may be regarded as essential to its organization, as well as establishing a sympathetic connexion with the abdominal viscera. No other muscle in the body, then, receives nervous endowments from so many and from such varied sources,—a fact fully in accordance not only

with its use and power, but also with the extensive sympathy it maintains with all the organic and animal functions of the system.

*Use.* It is the principal muscle in effecting inspiration, as it enlarges the chest in the perpendicular direction, and almost exclusively on each side; the crura act as long muscles do towards their origin, and slightly depress and draw backwards the central tendon; they also fix it. The superior diaphragm acts more like the hollow muscles; the border of the tendon, and the margins of the ribs, which are held steadily everted by the intercostal muscles, serve as its fixed points, and when the fibres contract they descend, and then, instead of being curved and convex upwards, become nearly straight, so as to present a plane surface to the abdomen, looking downwards and forwards; as the fleshy fibres are longest at the sides, it is here the greatest descent in the muscle occurs, consequently the thorax is most enlarged beneath each lung, and in proportion as this change takes place the air rushes into these organs by the larynx and trachea, to fill the enlarging thorax, and ordinary inspiration is said to have taken place. There is but little enlargement or alteration in the centre beneath the heart and great vessels; any such change in that situation would be not only useless, but injurious. When the diaphragm relaxes, its own elasticity, together with that of the pleuræ and pericardium, which are connected to its superior surface, aided by the pressure of the abdominal parietes against the viscera they enclose, cause it to re-ascend, so as again to present a concave surface to the abdomen, and to diminish the capacity of the thorax. The lungs are compressed in the same proportion; the air is expelled, and then expiration is said to have occurred. Although the diaphragm is commonly said to descend in inspiration, yet this assertion must be taken with some limitation; the tendinous centre admits of very little change in this direction, and the fleshy fibres can only become straight; accordingly the liver, stomach, and spleen are not much depressed, but these, as well as the other abdominal viscera, are pushed forwards rather than downwards; this may be ascertained by inspecting the abdomen during life in any person lying in the horizontal position on the back, prominence of the abdomen being synchronous with inspiration; but the most careful examination can hardly discover any descent of the margin of the liver in ordinary breathing; if, however, a very full inspiration be made, the viscera are then perceptibly depressed, and even a fulness in the perinæum is perceived; the attachment of the diaphragm to the ribs would, no doubt, tend to draw these bones inwards, and thereby contract the thorax transversely, which would be contrary to the general intention, but synchronous with its action is that of the intercostal and levatores costarum muscles, which, by fixing these bones, not only prevent such a result, but also actually enlarge the thorax by slightly elevating and everting their lower margins. In ordinary inspiration these are the only agents employed, the diaphragm and intercostal muscles; but in forced or in laborious breathing several

other muscles of the trunk and of the upper extremities assist, such as the sterno-mastoid, scaleni, subclavian, serratus magnus, trapezius, pectorals, latissimi dorsi, and serrati postici. Expiration does not require the same muscular exertion; its ordinary degree is chiefly effected by elasticity and by the gentle resilient contraction of the abdominal parietes; the ribs and their cartilages, the lungs, the diaphragm, and the textures connected to its upper surface, all possess this property, and tend to produce this condition without any distinct muscular action, thus presenting an example of an elastic or mechanical force saving an expenditure of a vital power; in violent expiration the abdominal muscles and levatores ani act with increased force, the triangulares sterni depress the cartilages of the ribs, the quadrati lumborum muscles assist in depressing these bones, the serrati postici inferiores may cooperate, so may the latissimi dorsi, by acting towards the lumbar vertebræ, and the arms themselves may be made to contribute by compressing the walls of the thorax; and should the last rib be fixed, it is also possible that the series of intercostals may become muscles for expiration: besides these ordinary respiratory movements, the diaphragm is also essentially concerned in other phænomena more or less connected with this function, such as snuffing, sighing, yawning, hiccough, &c. Neither is its influence on the abdominal viscera to be overlooked, its alternate depression and elevation must contribute to their functions; the secretions of the liver and pancreas, the contents of the gall bladder, stomach, and intestines, and the general circulation of the blood throughout this cavity, cannot fail to be beneficially affected by the constant motion and pressure of this muscle; in vomiting also it is concerned, a full inspiration preceding the expulsive efforts of the abdominal muscles and of the stomach itself; this is instantly followed by its relaxation, which opens the cardiac orifice: in the forcible expulsion of the urine and fæces it is retained in a state of strong contraction, and presents a resisting surface against which the abdominal muscles press the viscera, and thus expel their contents. In these abdominal actions it principally cooperates with the tranversales, the only muscles with which it indigitates; a striking resemblance in structure exists between these and the diaphragm; the two transverse with their weak and loosely attached fasciculi and their central tendon, being a sort of digastric muscle expanded around the peritonæum, and forming with the diaphragm one continuous muscular sac, enveloping and compressing the digestive apparatus. We may regard this muscular envelope as completed below by the levatores ani, which, though described as two, yet might be considered a single muscle like the diaphragm, with its median aperture, opposed to it in situation, and in function, as far as respiration is concerned, but allied to it and cooperating with it and with the transversi as general compressors and supporters of the abdominal viscera. The diaphragm also affords powerful assistance in many of the violent muscular exertions of the body, such as straining, wrestling, raising weights, &c.; by maintaining the thorax in an

expanded state it steadies the ribs, strengthens the trunk, and affords a firm support for the muscles that are engaged. We have already alluded to the possibility of diaphragmatic hernia occurring as the result of violent muscular efforts, either enlarging some of the natural openings, or bursting through some naturally weak or defective spot, or rupturing the muscle itself. Congenital deficiencies have been not unfrequently met with, but such are seldom compatible with continued existence, though some rare exceptions are recorded; such defects are to be considered as arrests of development, as the muscle in the very early periods of fœtal life is deficient, and grows only by degrees from the circumference towards the centre. Mammalia alone possess a perfect muscular diaphragm; in birds it is rudimental, the pillars and central tendon being absent, and the costal fasciculi inserted into the base of each lung; it is wanting in reptiles, fishes, and invertebrate animals.

*Quadratus lumborum* is thick, flat, round on its outer edge, irregularly square, the greater diameter being from above downwards, and the outer and lower borders longer than the upper and inner, situated in the lumbar region next the spine, between the ilium and last rib, forming part of the posterior wall of the abdomen, and, like the rectus muscle in front, enclosed in a strong aponuerotic sheath, formed by the anterior and middle laminæ of the tendon of the transversalis muscle, behind the colon and the kidney, the psoas and the diaphragm, and in front of the extensor muscles of the spine, and anterior to the sacro-lumbalis; *arises* tendinous from the posterior fourth of the crest of the ilium, and from the ilio-lumbar ligament; the fibres ascend obliquely inwards, and are *inserted* into the extremity of the transverse processes of the four first lumbar vertebræ and of the last dorsal; also into the internal surface of the posterior half of the last rib, beneath the external or false ligamentum arcuatum; the external or ilio-costal fibres are more vertical, the internal or ilio-lumbar more oblique; these latter are usually crossed in front by another lamina of fibres, which ascend obliquely outwards from the three last transverse processes to the edge of the last rib. *Use*, to bend the spine to one side, to depress the last rib, and thus assist in expiration, being directly opposed to the scaleni; when both muscles act they support the spinal column in the perpendicular direction. The complex structure of this muscle gives additional strength and more varied power of action, and is analogous to the decussating laminæ of the other abdominal muscles, or to the double layer of the intercostals, of which it may be regarded as a modified continuation.

*Psoas parvus*, long, flat, thin, and narrow, fleshy in its upper third, tendinous below; situated in front of the psoas magnus, and on its outer aspect above, its inner below; arises by short, fleshy, and aponeurotic fibres from the lower edge of the side of the body of the last dorsal vertebra, and sometimes from its transverse process, also from the body of the first lumbar, and the intervertebral substance; the fibres descend in a direction outwards, and opposite the fourth vertebra, end in a thin, glistening tendon, which crosses the psoas magnus,

descends on its inner side, and is *inserted* broad and thin into the ileo-pectinæal eminence and adjacent part of the brim of the pelvis; it is also attached externally to the iliac fascia by a broad aponeurotic expansion, which binds down the psoas and internal iliac muscles; inferiorly it is connected to the inner and back part of the crural arch, and to the pubic portion of the fascia lata behind the femoral vessels, and in front of the common tendon of the psoas and iliacus. *Use*, it assists in bending the body forwards, or in raising the pelvis; it makes tense the crural arch, and diminishes the aperture beneath it. This muscle is often wanting; when present, it is connected to the psoas magnus by cellular tissue, and is partly concealed above by the diaphragm, the renal vessels, and the peritonæum, and below by the external iliac vein and artery.

*Psoas magnus*, long, round, thick in the centre, small in the extremities, fleshy above, tendinous below, extends along the sides of the lumbar vertebræ, the brim of the pelvis, and the anterior and inner part of the thigh. It *arises* by two planes of fleshy and aponeurotic fasciculi; one large, anterior, and internal; the other small, posterior, and external: the first arises from the side of the bodies of the two last dorsal and four first lumbar vertebræ, and from their intervertebral ligaments; the fibres are attached to the upper and lower margins only of the vertebræ, and in the intervals to a series of tendinous arches, which are extended over the lateral grooves on these bones, to protect the lumbar vessels and the nerves which communicate between the sympathetic and the lumbar: the posterior fasciculi arise from the bases of the transverse processes. In the space between these two planes the lumbar plexus of the spinal nerves is contained, as the brachial plexus separates the scaleni muscles. The fibres all descend, at first vertically, afterwards obliquely outwards, along the brim of the pelvis, and, beneath Poupart's ligament, end in a tendon, which has been previously concealed among the fleshy fasciculi; this receives the fibres of the iliacus muscle externally, and is, therefore, the common or conjoined tendon of these two muscles. This tendon descends obliquely outwards to about the centre of the crural arch, and escapes into the thigh beneath Poupart's ligament, in the groove between the inferior spine of the ilium and the ilio-pubal eminence; it then descends very obliquely inwards and backwards, being somewhat twisted round the hip joint, so that its anterior surface becomes turned inwards, and its outer edge forwards, and is *inserted* into and around the lesser trochanter of the femur; some fleshy fibres of the iliacus are also inserted into a ridge extending below to the linea aspera; as the tendon glides round this process a small bursa is usually interposed, and a very large one always exists between it and the pubis and the fore-part of the capsule of the hip joint, and is sometimes found to communicate with the synovial membrane of the latter. *Use*, to flex the thigh on the pelvis, or the body on the thigh; it also rotates the thigh outwards; in standing it supports the spine, and prevents it bending backwards; it can then, also, especially by its iliac portion, rotate the

body so as to turn its front to the opposite side; in walking it is particularly engaged, raises and throws forward the lower extremity, assisted by the rectus femoris, at the same time turning the knee and foot outwards: its power is greatly increased by the reflection of the tendon over the pully-like surface of the ilium, whereby its direction becomes more perpendicular to its insertion. This muscle is situated between the psoas parvus and the quadratus lumborum above, and between the former muscle and the iliacus below; and in the groin, between the sartorius and the pectinæus. Its insertion is between the vastus internus and the pectinæus, and as it extends round to the back part of the lesser trochanter, will be found to correspond to the horizontal line of separation between the quadratus femoris and the adductor magnus; the lesser trochanter projects a little in this line or cellular interval, and, if the body be placed on the forepart, this insertion may be exposed posteriorly without injuring any muscle, by dividing the skin just below the fold of the natis and on the outer side of the hamstring muscles, between the tuber ischii and the great trochanter. The psoas is covered in the lumbar region by the diaphragm, the ligamentum arcuatum, the psoas parvus, the sympathetic nerves, the kidney and its vessels; also on the right side by the vena cava and ascending colon, and on the left by the aorta and descending colon. In the middle or pelvic division it lies between the external iliac vessels internally, and the iliac muscle and anterior crural nerve externally; is covered by the peritonæum, on the right side also by the ileum, cæcum, and vermiform appendix, and on the left by the sigmoid flexure of the colon. The two psoæ, together with the external iliac vessels, in this situation, overhang the margins of the pelvis, so as to diminish the transverse diameter of the upper orifice by at least half an inch; the psoas is here also covered by the iliac fascia and the expansion of the psoas parvus; the external iliac artery and vein are to its inner or pelvic side above, but, inferiorly, the artery is in front of it; these vessels are connected to the muscle and its investing aponeurosis by the fascia propria; the anterior crural nerve is external to it, but on a deeper plane, being imbedded in the groove between it and the iliacus, and behind the iliac fascia; in its lower or inguinal division it is partly covered by the femoral artery and vein, and by some of their branches, also by the inguinal glands, and by a considerable quantity of cellular membrane, which separates it from the fascia lata. The internal circumflex vessels follow the course of the tendon to the back part of the thigh, and separate it from the pectinæus muscle. The psoas lies anterior to the transverse processes of the lumbar vertebræ, to the quadratus lumborum, the lumbar nerves, the inner edge of the iliacus internus, the ilio-pubal symphisis, the acetabulum, and the capsular ligament of the hip. The structure of this muscle is peculiar, not only in man, but in animals, as is well seen in those fattened for the table; the fasciculi are very long and very tender, the connecting cellular membrane being very soft and delicate, and devoid of all fibrous and elastic tissue; the investing sheath also is thin and

fine. In chronic inflammation of this muscle, ending in suppuration, this sheath becomes very thick, and confines the pus as in a sac; it is lined by organized lymph, and some pale, attenuated muscular fibres are expanded on it; the form of the muscle is preserved, but enlarged; this disease is termed "psoas abscess," and is in general connected with disease of the lumbar vertebræ, or intervertebral ligaments.

*Iliacus internus*, flat, or rather concave, radiated or triangular, *arises* fleshy from the transverse process of the last lumbar vertebra, ilio-lumbar ligament, base of the sacrum, the inner margin of three anterior fourths of the crest of the ilium, the two anterior spinous processes of this bone, and the intervening notch, from the brim of the acetabulum and the capsular ligament, also from the iliac fossa, and from the strong aponeurosis, the iliac fascia, which covers it. This fascia is attached to the crest of the ilium and to Poupart's ligament as far inwards as the iliac artery, behind which it passes and becomes continuous with the pubic portion of the fascia lata; the fibres of this muscle all descend obliquely inwards, join the outer side of the tendon of the psoas magnus, and are *inserted* along with it, or rather into it; the inferior fleshy fibres, which are attached to the inferior iliac spine and to the capsule of the hip joint, are also inserted into the anterior and inner surface of the femur, below the lesser trochanter; these fibres often appear as a separate muscle, which has been named ilio-capsular. *Use*, to assist the psoas in flexing the thigh, and in rotating it outwards; also in abduction, it protects the forepart of the capsular ligament, and in flexion of the thigh draws it out of the angle between the neck of the femur and the edge of the acetabulum: it fills up the concavity of the iliac fossa, some inguino-cutaneous nerves descend upon it; on the right side it is covered by the cæcum, on the left by the colon; in the groin it is partly covered by the sartorius, and lies upon the rectus and on the capsular ligament, anterior to the glutæus medius, and internal and posterior to the tensor vaginæ femoris. We may next proceed to the dissection of the perinæum and the viscera of the pelvis.

## SECTION VI.

### DISSECTION OF THE PERINÆUM IN THE MALE.

PLACE the subject on the back, bend the thighs and knees upon the trunk, and secure them in the same position as in the lateral operation of lithotomy; the dissection will be facilitated if the pelvis be raised by a block placed beneath it; moderately distend the lower end of the rectum with sponge or curled hair; introduce a staff or catheter into the urethra and bladder; secure the penis to it by a ligature, and raise up the scrotum. The *perinæum* extends from the os coccygis

behind to the arch of the pubis before; is bounded on each side by the rami of the pubis and ischium, by the tuber ischii, and by the great sacro-sciatic ligament, which extends from that process to the side of the sacrum and coccyx; the glutæus maximus overhangs this ligament; the tuberosity and ramus of the ischium can be felt through the integuments, also (unless the subject be very fat) the ramus of the pubis leading obliquely upwards on each side to the symphisis. The form and extent of the perinæum are much influenced by the position of the body and lower extremities; when the latter are approximated, it is but a narrow space or groove containing the anal opening and the root of the scrotum and penis; but when the thighs are divaricated and flexed on the pelvis, it presents a considerable area, the average diameters of which measure, transversely, that is from one tuber ischii to the other, three inches or three and a half, and from pubis to coccyx four inches or four and a half.

*Fig.* 51.*

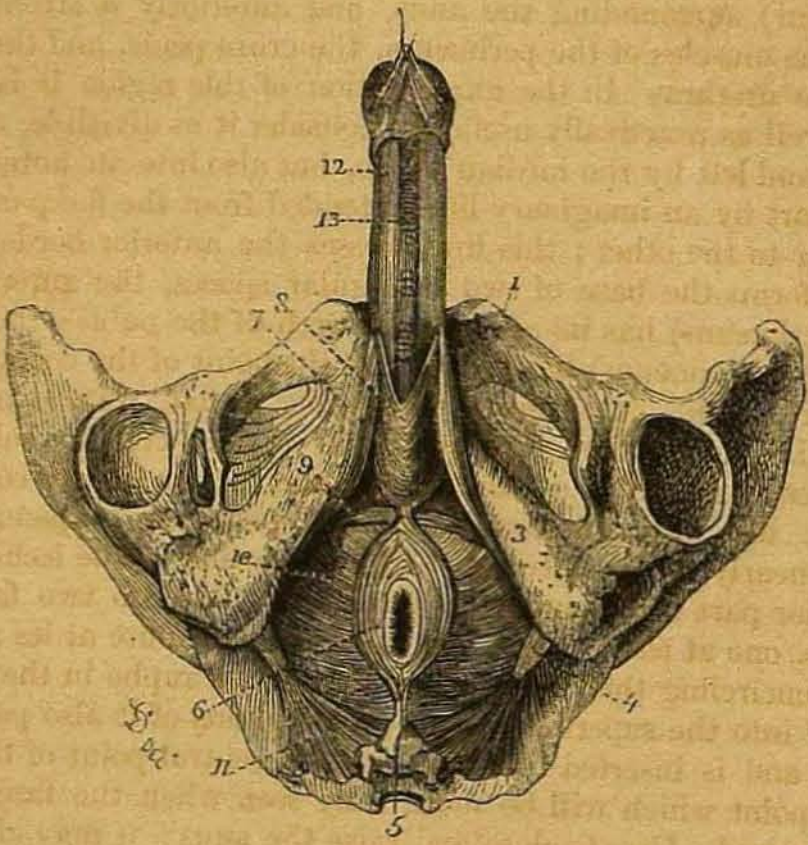


The integuments of the perinæum and scrotum are generally of a dark brownish colour in the adult, and of a reddish hue in the child; very thin around the anus, and covering the scrotum, but dense in the intermediate space: along the mesial line a prominent hard ridge is

* The muscles of the perinæum. 1. The os pubis. 2. The tuber ischii. 3. The ascending ramus of the ischium. 4. The spine of the ischium. 5. The coccyx. 6. The sphincter ani. 7. The erector penis. 8. The accelerator urinæ. 9. The transversalis perinæi. 10. The inferior surface of the levator ani. 11. The coccygæus muscle. 12. The corpus cavernosum penis. 13. The corpus spongiosum urethræ.

observable, the *raphe* of the perinæum; this line commences in front of the anus, and extends along the perinæum, scrotum, and penis, as far as the prepuce of the latter. Beneath the raphe the prominence of the urethra can be felt, commencing a little in front of the anus.

The *anus*, the inferior opening of the alimentary canal, is deeply placed in the groove between the nates, midway between the tuberosities of the ischia, about an inch or an inch and a half in front of the coccyx, and three inches from the arch of the pubes: the integument is inflected through it to be continuous with the mucous membrane of the intestine; the skin around is thin, studded with sebaceous follicles, and in the adult male with a few hairs; it is puckered into radiated plaits, extending inwards and very distinct when the opening is contracted, but effaced when distended; the cuticle can be traced inwards about a quarter of an inch, and ends in a regularly waved or festooned border, concave upwards. Cautiously cut through the skin all round this opening, and dissect off the integuments from all the perineal region, we thus expose, posteriorly, a cutaneous muscle (the sphincter ani) surrounding the anus, and anteriorly a strong fascia covering the muscles of the perinæum, the crura penis, and the corpus spongiosum urethræ. In the examination of this region it is convenient, as well as practically useful, to consider it as divisible, not only into right and left by the median raphe, but also into an anterior and posterior part by an imaginary line extended from the forepart of one tuber ischii to the other; this line crosses the anterior border of the anus, and forms the base of two triangular spaces, the anterior (the urethral perinæum) has its apex at the arch of the pubis; the posterior (the anal perinæum) has its apex at the point of the coccyx.

Sphincter Ani, cutaneous or externus, is flat, thin, oval, pale, and open in the middle; it *arises* from a fibro-cellular substance, which extends from the os coccygis to the rectum (recto-coccygeal ligament); the fibres descend obliquely forwards, expanding on either side nearly as far outwards as the tuberosity of the ischium; at the posterior part of the anus the muscle divides into two fasciculi, which pass, one at each side of this opening, and unite at its anterior part, thus encircling this orifice; *inserted* into the raphe in the integuments, and into the superficial fascia; a fasciculus of it also perforates the latter, and is inserted into the common central point of the perinæum; a point which will be more fully seen when the fascia shall have been raised. *Use*, to close and raise the anus; it may also draw the bulb of the urethra backwards and downwards, and compress it; this muscle is almost constantly in a state of contraction, and, like all the sphincters, belongs to the class of mixed muscles; one surface looks downwards, and is superficial; the other looks upwards, and is connected to the levatores ani muscles; one edge is internal, the other external; its lateral extent is much greater in some subjects than in others; a few of its external fibres must be divided in the first incision in the lateral operation of lithotomy; in the male the anterior fasciculus is often very long, but its mode of insertion variable; in the

female the sphincter is shorter, broader, and more rounded in front. Beneath and internal to this muscle we may expose the following with very little dissection.

Sphincter Internus *vel* Orbicularis, consists of a thick, but pale fasciculus of muscular fibres, encircling the lower extremity of the rectum, having no attachment to the coccyx behind, and but a slight one to the central point before, but is in close contact with the mucous membrane of the intestine; its surfaces are internal and external, its edges superior and inferior. *Use*, to assist the former in closing the extremity of the rectum; also in defæcation it assists in the expulsion of the residual portions of the fœcal matter by the sudden or almost spasmodic action which succeeds its relaxation; it also strongly opposes the entrance of any foreign body by the anus, and may be considered as analogous to the pylorus; its upper edge is continuous with the circular fibres of the rectum, its lower edge is only separated by a cellular line from the cutaneous sphincter. The subcutaneous or submucous tissue of the anus has some of the characters of erectile tissue, it contains a net-work of minute arterial inosculations, and a plexus of numerous tortuous veins; these are very liable to become varicose, and to lead to the formation of hæmorrhoids and hemorrhoidal tumours, of which there is a great variety; in some cases there is merely a dilated vein or veins, in others there are prominent, firm tumours, of a livid or purple hue, very thinly covered and liable to abrasion and hæmorrhage; these are often connected with the veins; in some there are vascular, cutaneous folds, and in others fleshy-looking growths from the mucous membrane, which occasionally protrude through the anus, particularly during defæcation, and bleed so freely as to cause some alarm for the safety of the patient; these veins join the hæmorrhoidal or inferior mesenteric vein, which is one of the roots of the vena porta.*

Anterior to, and on each side of the anus, we find beneath the integuments a condensed cellular texture, covering the other muscles in the perinæum; this is the *superficial fascia;* it is continued from the inner side of one thigh across the perinæum to the opposite, adhering to the fibrous tissue which covers the rami of the ischium and pubis on each side; this fascia is very dense about the middle of the perinæum; posteriorly, on either side of the anus, it is loaded with soft, large-grained, adipose substance, and is continuous with the cellular tissue in the ischio-rectal spaces behind the transversi perinæi muscles; anteriorly it extends over the scrotum, becomes thin and fine, like reticular membrane, and is continuous with the superficial fascia from the abdomen; it is covered by the superficial sphincter, and by the dartos, which is prolonged upon it in the median line further than on either side; it covers and partly envelopes the superficial perinæal vessels and nerves, also all the muscles in the anterior perinæal region. Separate this fascia from one side of the perinæum, and reflect it towards the opposite, its density and close connexion to the lateral

* See art. "Anus," in Todd's Cyclop. of Anat. and Phys.

boundaries of this region will then become obvious; a number of veins and nerves, and a quantity of fat also, will be observed; when the latter is dissected away, those muscles of the perinæum, which are attached to the penis and urethra, will appear, covered, however, by a fine but dense and semi-transparent aponeurosis; this may be called the *deep fascia* of the perinæum, although this term is usually applied to that aponeurosis which is placed still deeper in this region, and which is also called the triangular ligament of the urethra, or the interosseous membrane, or the septum perinæi, as it separates the anterior perinæum from the pelvis. The aponeurosis we are now alluding to might, perhaps, to avoid confusion, be named the *middle fascia* of the perinæum; though thin, it is strong, and essentially aponeurotic; it forms a close investment for the erector penis and accelerator urinæ muscles, and is folded round these, except their upper or attached surface; over the transversus perinæi it is very thin, and scarcely exists:* this fascia must be carefully raised, and the muscles will be exposed: these are six in number, three on each side, viz., the erector penis, transversalis perinæi, and accelerator urinæ. If the perinæum be divided by the transverse line drawn, as was before indicated, from one tuberosity of the ischium to the other, into an anterior and posterior part, we shall find that the anterior triangular space, or the *urethral* region, contains in the male subject the six muscles just named, also the crura penis and the corpus spongiosum urethræ, with their blood-vessels and nerves: the posterior triangular division, or the *anal region*, contains the lower extremity of the rectum, surrounded by the cutaneous and deep sphincters, also on each side of this intestine a considerable quantity of fat, filling up the space between the side of the rectum and the obturator internus muscle and fascia; this is the *ischio-rectal space*, a deep conical recess, the base towards the skin, the apex towards the pelvis, bounded externally by the ischium, which is lined by the obturator fascia; internally by the side of the rectum, covered by the levator ani and by the anal or ischio-rectal fascia, narrow above and closed by the last-named muscle and fascia, which form an oblique septum between the pelvis and this space; anteriorly by the transversus perinæi muscle, and posteriorly by the coccygæus: each of these recesses is lined on all sides, except inferiorly or towards the skin, by fascia, a view of which is obtained by dissecting out the contained adeps; there may then be observed near the apex, or the deepest part, a strong, tense, aponeurotic line; this is the inferior, folded, or convex surface of the pelvic fascia, which here sends off its inferior layer, and which immediately divides into two laminæ, an external and internal; the latter is named *anal* or *ischio-rectal fascia*, is thin and weak, descends upon the lower or outer surface of the levator ani to the sphincter,

* Both this and the superficial fascia resist collections of urine or of pus from coming to the surface; they also cause the tendency to infiltration of the urine forward into the scrotum and upwards on the abdomen, in cases of rupture of the urethra.

where it is lost in the surrounding cellular tissue; the former or external lamina is the *obturator fascia*: it is dense, strong, and glistening, descends obliquely outwards, and is inserted into the falciform process of the great sacro-sciatic ligament, and into the tuber and ramus of the ischium; it covers the obturator internus muscle, and encloses the pudic vessels and nerves, the hæmorrhoidal branches of which pierce it in their course towards the anus. The masses of adipose and cellular tissue, from two to three inches in depth, which fill these spaces, impart a certain degree of firmness and elasticity to the parietes of the rectum and to this part of the pelvis, and are retained and supported in their situation by their connexion to these fasciæ, as well as by the glutæi muscles which overhang them: in these spaces inflammation often occurs, and the consequent suppuration and abscess not unfrequently lead to the disease of fistula in ano. Next, examine the muscles in the anterior part of the perinæum; the erector or compressor penis is most external, and lies on the crus penis; the accelerator urinæ extends along the middle of the perinæum, attached to its fellow in the raphe, and covering the urethra; the tranversalis perinæi connects the posterior extremities of these muscles. To these three pair some writers add three others, namely, the pubio-urethral, or Wilson's muscles, the ischio-bulbosi or transversi perinæi alteri, and the compressores penis, or Houston's muscles. I shall allude to each of these afterwards, though I do not approve of this arrangement. Immediately in front of the rectum, in the middle line, and behind, but connected to the bulb of the urethra, is a small spot, of condensed cellular, tendinous, and muscular substance; into this many of the perinæal muscles are inserted; it is, therefore, called the *central point* of the perinæum, or the *common point of insertion* to the muscles of the perinæum.

Erector, or Compressor Penis, long and flat, narrow at each extremity, broader in the middle, *arises* tendinous and fleshy from the inner surface of the tuber ischii, and from the insertion of the great or inferior sacro-sciatic ligament, the fibres proceed forwards, upwards, and inwards, adhering to the edges of the rami of the pubis and ischium, and covering the crus penis. The fleshy fibres terminate in a tendinous expansion, which inclines forwards, upwards, and outwards, and is *inserted* into the fibrous membrane of the corpus cavernosum, or crus penis; some of the fleshy fibres are continued upwards and inwards, and are inserted into the inner side of the crus. *Use*, to draw down the penis; it is also supposed by some to contribute to the erection or distension of this organ by propelling the blood into it, and by the compression of the dorsal vein of the penis, as well as of the veins of the crus, against the bone, preventing the free return of this fluid through these vessels; others, on the contrary, contend that it does not compress, but rather dilates the corpus cavernosum, by separating the lower from the upper wall, and that it thereby facilitates its distension or erection; the course and attachment of the fibres appear to me to favour the former opinion in preference to the latter, although I

believe this muscle has little or no effect in producing this peculiar change in the erectile tissue of the organ: it is the most external of the muscles in this situation, it covers and adheres to the crus penis.

ACCELERATOR URINÆ, or EJACULATOR SEMINIS, is in the middle of the perinæum, extends from the front of the rectum to the back part of the scrotum, and is attached to its fellow along the mesial line; it *arises*, first, by tendinous fibres from the triangular or inter-osseous ligament, internal to the erector penis; secondly, by a thin tendon, which is common to the opposite muscle, and which lies above the urethra, between it and the pubis; thirdly, more anteriorly, by a tendinous expansion from the upper surface and outer side of the corpus cavernosum penis. The posterior and middle fibres descend inwards; the anterior fibres, which are longer, descend obliquely backwards and inwards; all the fibres are *inserted*, along with those of the opposite muscle, into the middle tendinous line or raphe of the perinæum, which extends from the common central point to the root of the scrotum. Or we may study this muscle according to the following description: *arising* with its fellow from their common tendinous raphe, which commences in the central spot, adheres to the bulb, and extends as far forwards as the angle which the bent or flaccid penis and urethra form with the pubis; from this line the fleshy fibres of the two muscles diverge like the barbs of a feather, the posterior pass upwards and outwards, are convex and strong, form a capsule for the bulb, and are inserted into the triangular ligament, also sometimes into the rami of the ischium and pubis, above the crura penis; the middle fibres, which are short, encircle the urethra, and end in a common tendon on its upper surface, which adheres to it, and to the angle of the crura penis; the anterior fibres are the longest, diverge like the legs of the letter Y, ascend outwards and forwards along each crus penis, and end in a thin but tough aponeurosis, which spreads upwards and inwards, and is continuous with the suspensory ligament and fascia of this organ. *Use*, to expel the last drops of urine and semen; the posterior and middle fibres are supposed to have an influence in distending or erecting the corpus spongiosum urethræ by propelling the blood into its cells; and the anterior are also thought to contribute to the same effect, by their insertion into the fascia of the penis compressing the dorsal vein. The posterior origin of this muscle is overlapped by the compressor penis, and by the perinæal vessels and nerves; some of its fibres extend in some cases outwards, to the rami of the ischium and pubis, and are attached to the bone: the origin of the middle fibres lies above the urethra, and that of the anterior is external and superior to the crus penis. The acceleratores urinæ muscles fill up the middle of the perinæum, cover the bulb, and encircle the urethra anterior to it. Separate these muscles from each other along the mesial line, and detach one of them from the corpus spongiosum urethra, then, by examining its deep surface, its origin, particularly that which lies above the urethra, and anterior to the bulb, will be more distinctly seen. The terminating aponeurosis of the anterior portions

occasionally carry along with them some muscular fibres to the dorsum of the penis, and from the attachment of the former to the suspensory ligament these fibres sometimes appear like distinct muscles, and hence, probably, Mr. Houston was led to describe a pair of muscles in this situation under the name of

Compressores Venæ Dorsalis Penis; according to his account (Dub. Hosp. Rep. vol. v.) "these *arise* from the rami of the pubes, above the crura and erectores penis; they ascend inwards and forwards, unite, and are *inserted* in a common tendon above the dorsal vein in the median line; they form a thin, musculo-tendinous stratum, about an inch long and three-quarters broad, separated from the penis by the dorsal vein, arteries, and nerves; the pudic arteries, in their course to the dorsum of the penis, separate them from Wilson's muscles, or the anterior portions of the levatores ani. *Use*, to contract and close the vein, and thus, by mechanically obstructing the current of the blood, induce turgescence and erection of the organ."

These muscles, however, which are well developed in the dog and in many other animals, do not, I believe, normally exist in man; although I have, in some instances of young and robust subjects, seen the fibres above described, yet I think they are often very indistinct, and inadequate to the office assigned; when present, I am disposed to regard them as only rudimental of the more perfect structure in other animals.

Transversalis Perinæi is thin and weak, often indistinct, and sometimes wanting; it *arises* from the inside of the tuberosity of the ischium, above the erector penis muscle; the fibres pass transversely inwards, but also a little forwards and downwards, and are *inserted* into the central point of the perinæum, behind the accelerator urinæ muscle. *Use*, to fix the central point, and support and raise the anus; it assists in defæcation, by pressing backwards the anus and the forepart of the rectum, which are drawn forwards and raised by the levatores ani muscles; it may also dilate the bulb. This muscle is covered by the sphincter ani, and by the superficial fascia; a small artery (tranversalis perinæi) runs along its anterior edge; it lies on, or rather beneath the levator ani, and nearly parallel, connected to it by cellular membrane, and in some cases intimately joined to it; the two transversi are sometimes continuous with each other across the median line, in front of the anus, so as to resemble a semicircle concave backwards, embracing and compressing the forepart of the rectum. In some subjects a second muscle may be observed taking a transverse course (the *tranversalis alter*, or *ischio-bulbosus*); this *arises* from the ramus of the ischium and pubis, proceeds obliquely forwards and inwards, and is *inserted* into the accelerator urinæ and side of the bulb; though shorter it is often stronger than the superficial transverse muscle; it lies deeper and higher, that is nearer the pubis, and is partially concealed in the posterior part of the triangular or deep fascia of the perinæum; though not unfrequently a distinct fasciculus, it generally appears to me to be only a portion of the levator ani. The

transversi perinæi muscles are very irregular in size in different persons, in some being found very distinct and strong, in others a few pale and scattered fibres only point out their course and situation; the dissector is frequently obliged to raise off a few fasciculi from the levatores ani muscles, to make even an appearance according with the description given in books. Between the three last described muscles on each side we may remark a triangular space, which is bounded externally by the crus penis and the erector penis muscle, internally by the urethra and accelerator urinæ; the base is posteriorly, and is formed by the transversalis perinæi muscle. This space contains a quantity of fat, also the perinæal artery, veins, and nerves, branches of the pudic vessels and nerves; into this space, near its base, on the left side of the perinæum, the operator must sink his knife in the lateral operation of lithotomy, in order to lay bare the groove in the staff. In this incision the transversalis muscle and artery of the perinæum must be divided. Next dissect off the erector penis from the crus penis, also the acceleratores urinæ muscles from the bulb and corpus spongiosum urethræ; detach the transverse muscle from its attachments, and remove the vessels and cellular membrane out of the triangular space just now described; then press the bulb of the urethra to one side, from the crus penis, and between these two bodies we may observe a strong ligamentous substance, the fibres passing in different directions; this is the *triangular ligament of the urethra*, or the *interosseous ligament*, or, according to some, *the deep fascia of the perinæum*. This is a strong aponeurosis, extended as a tense septum between the anterior part of the perinæum and the pelvis; of a triangular shape, its apex is thin, and lost in front of the pubic symphysis and subpubal ligament on the dorsal vessels of the penis; from this it inclines obliquely downwards and backwards, attached on each side to the rami of the pubis and ischium, above the crura penis; its base or posterior inferior margin, which is weak and undefined, is directed towards the rectum, and is connected mesially to the central point, and on either side is continued behind the transversus perinæi, joins the middle perinæal aponeurosis and the ischio-rectal fascia, and is lost on the lower surface of the levator ani muscle; it is covered on its perinæal aspect by the muscles, nerves, and vessels of the perinæum, and by the bulb of the urethra; the vessels of the latter are enclosed between its laminæ; its upper or pelvic surface is in contact with a venous plexus and with the anterior portion of the levator ani; about an inch below the pubic arch it is pierced by the urethra; this aperture corresponds to the angle between the bulb and the membranous portion of that tube, and from its margin are derived two laminæ or processes, one, anterior and inferior, is lost upon the bulb, which it serves to fix, support, and compress; the other, or the posterior lamina, is more extensive, is continued backwards into the pelvis, around the membranous part of the urethra, and a delicate venous plexus, or spongy erectile tissue, and then expands to enclose the prostate gland; it is, therefore, of a funnel form, the apex towards the perinæum, the

base is in the pelvis, superiorly it covers the upper surface of the prostate and neck of the bladder, and is beneath the pubic ligament and the dorsal veins of the penis, and joins the convex surface of the anterior ligaments of the bladder, or the anterior reflection of the pelvic fascia; laterally it forms a smooth, glistening capsule for the lobes of the prostate, and is attached to the convex edge of the lateral vesical ligaments or folds of the pelvic fascia; inferiorly it extends backwards between the rectum and bladder, covers the prostate, vasa deferentia, and vesiculæ seminales, and is connected between the latter to the convexity of the pelvic *cul de sac*, or recto-vesical fold of the peritonæum; this portion of the fascia is very distinct and strong, and has been described by Mr. Tyrrel as a distinct lamina of the pelvic aponeurosis, under the name of the *recto-vesical fascia*. The triangular or interosseous ligament is an important texture in this region; it forms a septum or boundary to the lower and anterior part of the pelvis; it sustains and fixes the canal of the urethra in its passage to the perinæum, and it supports and strengthens the bulb or the commencement of its corpus spongiosum; by its attachments to the neck of the bladder and to the prostate gland, and by its continuity with the pelvic fascia, it serves to connect those organs to the pubes, and to retain them in certain fixed relations to the surrounding parts; by its connexion, also, to the ischio-rectal fascia and levator ani muscle, it strengthens the inferior region of the pelvis posteriorly, and sustains this muscle and the rectum: as the pubic ligament intervenes superiorly between its two laminæ, so inferiorly these are separated by the arteries of the bulb and by two small glands, *Cowper's*, or the *anti-prostatic glands*; these may be next exposed by dividing a few fibres of the anterior layer of this ligament, and by a little dissection on each side of and a little below the bulb; these are two in number, each about the size of a small pea, situated at each side of and behind the bulb, below the membranous part of the urethra, between the layers of the triangular ligament, and closely connected to the artery of the bulb; they are covered anteriorly or inferiorly by the acceleratores urinæ muscles, and by the anterior layer of the triangular ligament; of a pale, reddish colour, and of a firm tissue, resembling that of the salivary glands; they have no distinct capsule, and their form is therefore variable; from each a small, distinct duct, about an inch in length, passes forwards, and opens obliquely into the lower and lateral part of the urethra, at a little distance anterior to the bulb. Dissect away all the cellular membrane at the side of the rectum, between it and the tuber ischii; you will thus expose the greater portion of the levator ani muscle; press the rectum to the opposite side, and you will then observe how this muscle posteriorly, and the triangular ligament anteriorly, close the inferior opening of the pelvis, and separate this cavity from the perinæum; detach the crus penis from the bone on one side, and above it separate the triangular ligament on one side also from the rami of the pubis and ischium, and draw it over towards the bulb of the urethra, which, together with the rectum, press or fasten

with a tenaculum, towards the opposite tuberosity of the ischium. In separating this ligament from the bone, the pudic artery and its terminating branches will be seen; we thus also expose the greater portion of the levator ani muscle on one side, and which we may next examine, although, to understand the anatomy of this muscle fully, it must be examined in two other aspects; the present dissection displays its inferior surface, the course of its fibres and their insertion or perinæal attachment; its upper or pelvic concave surface may be seen by raising the peritonæum and the intestines it contains out of the pelvis, and carefully dissecting the thin reflections of the pelvic fascia from its fibres; and lastly, when the lateral dissection of the pelvis has been made (which we shall direct presently), the origin of the muscle on one side, and its relations to the rectum and neck of the bladder, will be fully displayed, in the course of which dissection the reader can again refer to the following description.

Levator Ani, flat, thin and broad, or irregularly square, situated at the inferior and lateral part of the pelvis, broader above at its origin than below at its insertion; *arises* by three origins, the first is fleshy, from the posterior part of the symphisis pubis below the true ligaments of the bladder; the second is thin and tendinous from the obturator fascia, and from the ilium above the thyroid hole, or rather from the inferior surface of that angle of reflection of the pelvic and vesical fasciæ, from which both the anal and obturator laminæ descend external to this muscle; its origin from the ilium is through the medium of the pelvic fascia; the third is thick, tendinous, and fleshy from the inner surface of the ischium, and from its spinous process; the fibres descend obliquely inwards, by the side of the neck of the bladder and rectum; the anterior passing more backwards than the others, while the posterior are more transverse or horizontal; *inserted*, the anterior or pubic fibres into the central point of the perinæum, and into the forepart of the rectum, uniting with the fibres from the opposite side; these fibres descend along the side of the lower fundus of the bladder and of the prostate gland and membranous part of the urethra; the middle fibres are inserted into the side of the rectum, passing internal to the sphincters, and united to the outer surface of the longitudinal fibres of the intestine; the posterior fibres into the back part of the rectum, and into a tendinous raphe, extending from it to the os coccygis, in which raphe the muscles from opposite sides unite, also into the two last bones of the coccyx. *Use*, to raise and draw forward the rectum, particularly when this intestine has been protruded by the efforts of the abdominal muscles and diaphragm to expel its contents; it also assists in closing this intestine; it compresses the vesiculæ seminales and prostate gland, and assists powerfully in the evacuation of the fæces, urine, and semen; the anterior portion supports the perinæum by raising the common central point, and may also compress and close, like a sphincter, the membranous portion of the urethra; these muscles complete the inferior boundary of the pelvis and abdomen, and form a muscular floor to

these regions, not unlike the diaphragm above, but opposed to it in respiration, being muscles of expiration; they resemble a funnel, with two openings in it inferiorly, the concavity directed towards the pelvis, the convexity to the perinæum, through the anterior aperture the urethra passes, through the posterior the rectum. On the perinæal surface of this muscle are placed the muscles, the triangular ligament, the anal fascia, and the adipose substance in the ischio-rectal space, of which we have already spoken, and which separates it from the obturator fascia and muscle; its pelvic surface is related to the bladder, prostate, and rectum, but is separated from these and from the peritonæum by the pelvic and vesical fasciæ above, and by a thin lamina from the latter, which may be named *rectal fascia*, below. As the diaphragm owes much of its physical strength to its serous investments, so the fasciculi of the levatores ani (many of which are weak and separated) are supported and connected by the aponeurotic sheath in which these muscles are enclosed on either side; this sheath is formed on its superior or pelvic aspect by the pelvic, vesical, and rectal fasciæ (but which cannot be seen in the present stage of the dissection), and on the inferior or perinæal aspect by the anal or ischio-rectal aponeurosis; the sheath of one side is directly continuous with that of the opposite around the rectum posteriorly, and anteriorly through the intervention of the recto-vesical fascia, by which again this entire structure is attached to the triangular ligament of the urethra, and thereby maintained in such a state of tension as to afford resistance and strength to the inferior region of the perinæum and to the parietes of the rectum.

At the anterior edge of each levator ani muscle fleshy fibres may be observed to surround the membranous part of the urethra very closely. These fibres, particularly at their insertion, will in general be found so united to the levatores ani, that they may be considered as portions of these muscles; they have, however, been described differently by different anatomists, no doubt in consequence of the different appearances they present in different subjects, and from the different mode in which the dissection has been conducted. Mr. Wilson describes them as follows:

Compressores, or Levatores Urethræ; each *arises* by a narrow tendon from the inside of the symphysis pubis, about one-eighth of an inch above the lower edge of the arch, and at nearly the same distance beneath the anterior ligaments of the bladder, to which, and to the tendon of the opposite muscle, it is connected by loose cellular membrane; the tendons, at first round, become flat as they descend, are parallel and in contact; they soon end in fleshy fasciculi, which separate and enclose the membranous part of the urethra, and, folding beneath it, are again united, and are *inserted* into a narrow tendinous line, which is lost in the common central point of the perinæum, and in the posterior layer of the triangular ligament between the prostate and the rectum. *Use*, to compress, contract, close, and elevate the membranous portion of the urethra: these fibres encircle the narrowest

part of the urethra, that portion which is just behind the bulb, and may, by their contraction during life, form such an impediment to the passage of an instrument into the bladder as may lead the surgeon to suspect the presence of a stricture, when in reality no alteration of structure exists. The origin of these muscles is occasionally distinguished from the levatores ani by some small veins which pass from the side of the neck of the bladder to join the trunk of the dorsal veins of the penis, but their insertion is confounded with these muscles in perinæo behind the bulb.

To these perpendicular muscles Mr. Guthrie has added a pair of *transverse compressors, arising* narrow and tendinous from the rami of the ischium, they pass inwards and a little upwards, expand into a fan-like form, enclose the urethra, and are *inserted* into a common tendinous raphe on its upper and lower surface, extending from the prostate to the bulb, and connected to both. Mr. G. considers these

*Fig. 52.**

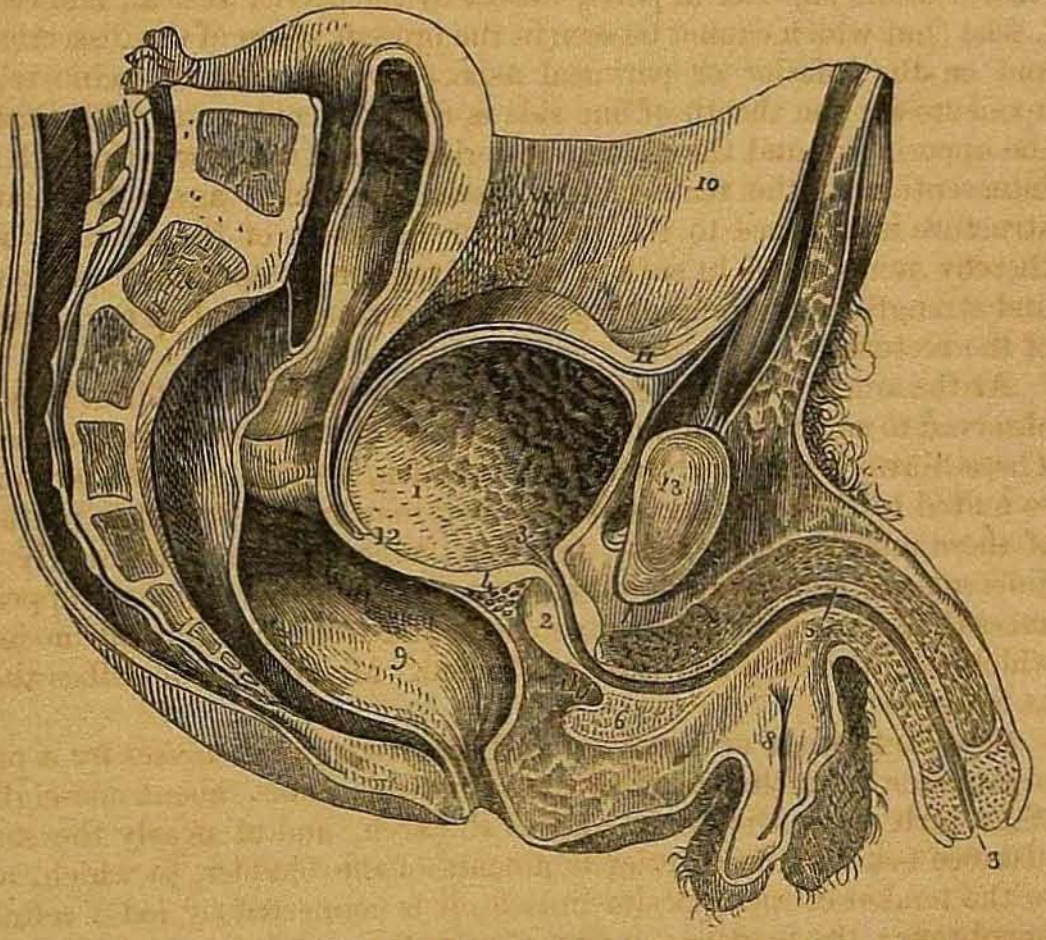


* An antero-posterior section of the pelvis of a male, exhibiting the viscera *in situ*. 1. The bladder. 2. The prostate. 3. 3. The urethra laid open through its whole extent. 4. The vesicula seminalis laid open. 6. The bulb of the corpus spongiosum. 5. The corpus spongiosum seen both above and below the urethra. 7. The corpus cavernosum penis. 8. The right side of the scrotum, from which the testicle has been removed. 9. The rectum. 10. The peritonæum lining the abdominal muscles. 11. Its reflection on the upper surface of the bladder. 12. Its reflection from the posterior surface of the bladder on the rectum. 13. The section of the symphisis pubis. 14. A line marking the situation of the triangular ligament.

as totally distinct from Wilson's muscles, which, according to him, descend only to the upper surface of the insertion of the transverse, and do not encircle the urethra, as Wilson and others have described. All this muscular structure is, in the adult, intermingled with a spongy, elastic, erectile tissue, and a fine, soft, adipose substance, not unlike that of the tongue, except for the preponderance of veins; the exact course and termination or attachment of the fibres is indistinct, and appears very variable in different individuals. I consider that these perpendicular and transverse fibres, as well as the transversus perinæi alter, may all be regarded as portions of the levatores ani muscles, which close the pelvis inferiorly, and form a floor extending on each side from the pubis round to the coccyx; the fibres of these thin and broad muscles are not always in close and parallel contact, but occasionally some cross others with more or less obliquity, forming imperfect but separate planes; some fasciculi are separated by the passage of blood-vessels and by aponeurotic septa from the adjacent fasciæ; these, by careful dissection, may be still further isolated, and made to appear as distinct muscles: in the child the structure is more simple and the urethral fibres more distinctly connected with the levatores ani muscles.

Let the student next replace the triangular ligament, &c., and then reconsider the several parts before him in reference to the operation of lithotomy: he has already examined the triangular space between the erector penis and accelerator urinæ muscles, into which the knife of the operator is to sink in order to reach the groove in the staff; this space having been fully opened, the staff can be plainly felt or seen passing above the bulb through the membranous part of the urethra into the bladder: behind and below the bulb is the rectum; and close to the rami of the pubis and ischium are the internal pudic vessels covered by the obturator fascia; the large artery from the pudic, called the deep transverse artery, or the artery of the bulb, may also be observed passing in the substance of the triangular ligament, about an inch below the symphisis pubis. Hence, then, in order to lay bare the staff without injury to the more important parts which surround it, we should endeavour to open the urethra as near to the base of the triangular ligament as possible, as we shall thus be most likely to avoid the artery of the bulb. Suppose the knife of the operator to be lodged in the groove of the staff, and then to be pushed along it into the bladder, the student will perceive that at that moment the posterior layer of the triangular ligament, the anterior fibres of the levator ani, the compressores urethræ, and the left lateral lobe of the prostate gland, must be divided, and from this view he may also learn that the rectum will be protected from injury if the staff be well raised into the arch of the pubes, its groove turned a little to the left side, and the wrist of the operator depressed, so as to elevate the point of the knife, and thus direct it into the neck of the bladder. He may next learn in what direction the knife can be withdrawn with safety and effect, and what parts require to be divided; it is to be withdrawn slowly and steadily, in a direction backwards and outwards, nearly parallel to

the line of the cutaneous incision, the edge so lateralized as to avoid cutting the rectum posteriorly, or the pudic artery externally. In this part of the operation the middle fibres of the levator ani must be divided, also the adipose substance on its perinæal surface. The student may next withdraw the staff from the bladder, and pass it again and again along the urethra into that cavity; he will soon perceive how apt the point of the instrument is to descend into the sinus of the bulb, and the necessity of depressing the handle of the staff, in order to raise the point into the membranous part of the urethra; at the same time he should observe that the latter is about an inch below the arch of the pubes, and that, therefore, the point of the instrument is not to be too much elevated, otherwise it may lacerate the upper part of the urethra, and injure some large veins that may be found in this situation. The student may now also examine what occupies the space between the urethra and the pubes; immediately above that canal is the upper portion of the triangular ligament, attached to the crura penis; behind and above this are one or two large veins from the dorsum of the penis; these enter the pelvis along the upper surface of the prostate gland; above these is a smooth dense ligament, the *pubic ligament*, which is attached to the lower edge of the symphysis pubis, and rounds off the angle between the opposite rami.

Posterior to the levator ani, and overlapped by the glutæus maximus, is the following small muscle:

Coccygeus, triangular, thin and flat, at the inferior and posterior part of the pelvis, behind and above the levator ani, and in front of the sacro-sciatic ligaments, *arises* narrow from the inner surface of the spine of the ischium and adjoining ligaments, the fibres expand along the inner or lesser sacro-sciatic ligament, and are *inserted*, fleshy and tendinous, into the extremity of the sacrum and side of the coccyx. *Use*, to support and raise the os coccygis in defæcation, and to assist in closing the inferior and posterior part of the pelvis; this muscle is between the levator ani and the glutæus maximus; is composed of aponeurotic and fleshy fibres; it is more distinctly seen within the pelvis, as it is covered posteriorly by the sciatic ligaments and glutæus maximus; its posterior margin reaches the lower edge of the pyriformis, while its anterior is continuous with the levator ani, and is only distinguished from it by difference in structure; its upper surface is concave, and in contact with the pouch of the rectum; its lower convex surface is related to the glutæus maximus muscle and to the sacro-sciatic ligaments.

Next, let the student divide the central point of the perinæum, separate the rectum from the bulb, and draw the former a little downwards from the bladder and prostate gland: he will thus expose the inferior or posterior surface of the neck of the bladder, the flat posterior surface of the prostate gland, also the vesiculæ seminales, the terminations of the vasa deferentia, and the commencement of the urethra; but the most important part to direct the attention to is a small triangular space or portion of the bladder, just above and behind the prostate gland,

which is bounded on either side by the vasa deferentia and vesiculæ seminales, posteriorly by the *cul de sac* of the peritonæum, and anteriorly by the prostate gland, which forms the apex of this triangle; all these are covered by a strong aponeurosis, the posterior layer of the triangular ligament, or the recto-vesical fascia of Tyrrel; within this space, the bladder, when distended, is in contact with the rectum, and from the cavity of the latter the former organ may be perforated during life without injuring any important part; this space is about three inches and a half or four inches from the anus, and is selected by some surgeons as the best situation for tapping the bladder in case of retention of urine, when a catheter cannot be passed through the urethra. The student may now proceed to examine the pelvic viscera.

## SECTION VII.

### DISSECTION OF THE PELVIS.

The *pelvis* is the inferior portion of the trunk, continuous with and bounded above by the abdomen, with which it communicates so freely that some of the viscera of each may mutually occupy either situation; bounded on either side and in front by the ossa innominata, behind by the two last lumbar vertebræ, the sacrum, and coccyx, and closed below by the various tissues already described in the perinæum: it is divided into the upper or false, and the lower or true pelvis; the former cannot be separated from the abdomen, as it forms an essential portion of it, but the latter is distinguished from both by a well-marked line, formed posteriorly by the promontory of the sacrum, on either side by the ilio-pectineal ridge, and anteriorly by the cristæ and symphysis of the pubes. The anatomy of the pelvis, therefore, implies that of the *true pelvis*, which cavity is bounded behind by the sacrum and coccyx, in front and on either side by the pubis and ischium, and a small portion of the ilium; the sacrum is partially lined or covered by the pyriform muscles and sciatic plexus of nerves, the pubes by the pelvic fascia, and the sides by the obturator and pelvic fasciæ, the levatores ani, and internal obturator muscles. For the purpose of examining the viscera in this region, make the following dissection: separate the left crus penis, also the left border of the triangular ligament, from the rami of the ischium and pubis (if not already done), and detach the levator ani muscle of the left side from its pelvic attachments; with the hand separate the cellular and aponeurotic bands, which lie superior to this muscle; then divide the symphysis pubis, or saw the left os pubis about a quarter of an inch external to the symphysis; divide the left ilio-sacral articulation, cut through the psoas muscle and iliac vessels, and then remove the os

innominatum and lower extremity of the left side; the pelvic viscera will remain in the concavity of the sacrum and of the os innominatum. These viscera will be rendered more distinct by a little preparation; first, moderately inflate the bladder through the ureter, a ligature having been tied around the penis, the rectum also may be moderately distended with curled hair or a sponge, and attached to the spine by a ligature. The *pelvic portion* of the *peritonæum* should be first attended to. This membrane may be now seen to descend along the sides and forepart of the rectum to within about four inches of the anus, whence it is reflected on the lower and back part of the bladder, a little above the base of the prostate gland; the line of this reflection is, in the recumbent position of the subject, opposite the lower margin of the third piece of the sacrum; in the erect posture it will be found on a level with the junction of the sacrum and coccyx; it is reflected on the bladder between the middle of the vesiculæ seminales; it then ascends on the back part and sides of this organ to its superior fundus, whence it is continued to the abdominal muscles. Below the line of its reflection, or below the *cul de sac*, we may again take notice of the small triangular space on the inferior fundus of the bladder, before alluded to, as the situation in which that viscus can be punctured from the rectum, in case of retention of urine. The reflections of the peritonæum, from each side of the rectum to the back part of the bladder, are called the posterior ligaments, and the folds which this membrane forms, one on each side between the bladder and the iliac fossa, are named the lateral ligaments of the bladder; these shall be more particularly noticed presently. The *pelvic fascia* may be considered as a continuation of the iliac; it descends behind the iliac vessels, from the brim of the pelvis, to which it adheres, lines the parietes of the cavity as low down as the upper edge, or the origin of the levator ani muscle, and divides into two laminæ, between which this muscle is enclosed, the external is named the obturator, the internal the vesical fascia.

The *obturator fascia*, or lateral pelvic aponeurosis, descends between the obturator internus and levator ani, adhering closely to the former, and sends off the ischio-rectal or anal fascia, which covers the perinæal aspect of the levator ani muscle; the obturator fascia is inserted inferiorly into the projecting border, or falx-like process of the great sciatic ligament, into the tuber ischii, and into the rami of the ischium and pubis, where it is continuous with the triangular ligament of the urethra, which ligament thus appears to be the continuation of the obturator fascia, from one side of the pelvis to the other; it is also connected posteriorly to the overhanging border of the glutæus maximus, and to the coccygeus muscles: its external surface is in contact above with the obturator internus muscle, which separates it from the obturator ligament or membrane and from the bone, inferiorly with the great pudic vessels and nerves, which it encloses in a sort of sheath, and which are thereby protected from injury in the lateral operation of lithotomy; its internal surface is in contact above with the

levator ani muscle, but separated from it below by the anal fascia, and by the adipose mass which fills the ischio-rectal space, of which latter it forms the outer wall; the obturator fascia is better seen in the dissection of the perinæum, where it has been already noticed (page 308).

The *vesical fascia*, or superior pelvic aponeurosis, covers and adheres to the internal surface of the levator ani, lying between it and the peritonæum; in order to see it, the latter must be removed together with the loose connecting cellular tissue, which readily admits of being torn from it; it may also be exposed on its perinæal aspect, by dividing the levator ani muscle and its investing fasciæ, also the triangular ligament of the urethra; this fascia descends, anteriorly, to the lower edge of the symphysis pubis, and laterally to a level with a line carried from this point round to the spine of the ischium; from the pubes it is reflected on the upper surface of the prostate gland, and on the neck of the bladder, forming the anterior true ligaments of this organ: laterally it is reflected from the pelvis on the side of the prostate, and on the lower part of the side of the bladder, just above the outer edge of each vesicula seminalis, and thus forms the true lateral ligaments of the bladder; posteriorly it is thin and cellular, and lost on the fore-part of the sacrum, and on the nerves and vessels passing into and out of the pelvis. As this fascia is reflected upwards on either side to from the true lateral vesical ligaments, it encloses the vesical venous plexus, and sends off from its inferior or convex surface two processes or laminæ; one passes inwards and a little downwards, beneath the vesiculæ and the bladder, in front of the rectum, and joins a similar process from the other side; this may be named (according to Tyrrell) *recto-vesical fascia*, or, if this latter be considered as derived from the posterior layer of the triangular ligament of the urethra (see p. 312), then this process may be considered as a mere connecting lamina between it and the vesical fasciæ of each side; the other process descends more directly on the upper or pelvic surface of the levator ani to the lower part of the rectum, on which it expands, and meets posteriorly the similar process from the other side, so as to invest it laterally and behind; this process may be named the *rectal fascia*, and is not to be confounded with the anal or ischio-rectal, which covers the opposite or inferior surface of the levator ani; the rectal fascia on either side and behind, together with the recto-vesical in front, form a complete aponeurotic investment for the lower portion of the rectum immediately above the insertions of the levatores ani muscles. The vesical fascia, therefore, on each side, may be described as dividing at the outer border of the vesicula, where it encloses a venous plexus, into three processes or laminæ: a superior, the true lateral vesical ligament; a middle, the recto-vesical fascia; and an inferior, the rectal fascia: at its anterior reflections it is short and very strong, and presents the appearance of two flat tendons, with an intervening depression, passing in an arched manner from the pubes to the neck of the bladder, and continuous with the muscular fibres of the latter; its long lateral reflection often presents the appearance of a strong tendinous

arch extending from the pubis, beneath the canal for the obturator vessels, as far back as the spine of the ischium.

The vesical fascia forms a pouch on each side of the bladder, which assists in closing the pelvis; it also fixes the pelvic viscera, supports the peritonæum, and resists the pressure of the abdominal muscles and diaphragm, and thus prevents perinæal herniæ; it separates the perinæal from the pelvic or subperitoneal cellular membrane, and limits the progress of inflammation, or infiltration from the former to the latter; its reflection on the prostate and neck of the bladder is superior to the line of the lateral incision in lithotomy through these parts, and therefore the pelvic cellular tissue is uninjured. This fascia is perforated by several blood-vessels, anteriorly the small vesical and prostatic, posteriorly the sciatic and pudic; there are also often small depressions and deficiencies in it filled with fat. At the anterior border of the great sciatic notch, it forms an arched boundary to the opening for the escape of the great glutæal vessels and nerves; when sciatic hernia occurs, it is through this opening and behind this arch. Divide the pelvic fascia on one side, in the course of its lateral reflection, and the levator ani muscle will be exposed, particularly its origin, to the account of which the student may refer (page 313); the rectum, ureter, and vas deferens, also come into view, and deserve particular attention; these should be all carefully dissected, but disturbed as little as possible from their natural relations. The course of the ureter has been already described; the vas deferens will be noticed hereafter with the generative organs; but now remark the curved course of the rectum, its dilatation above the anus, the connexion of the peritonæum to its upper and middle thirds; and its lower third, below and wholly unattached to this membrane; this portion is curved so as to be convex towards the prostate, concave towards the coccyx, and as the anal end of the intestine inclines backwards, it leaves between its forepart and the urethra a triangular space (*recto-bulbar*), bounded above and before by the membranous portion and bulb of the urethra, behind by the rectum between the prostate and the anus; the integuments, together with the central point of the perinæum and the muscles inserted therein, form its base below; this space is traversed laterally by the knife in lithotomy, and if the convexity of the rectum, or its dilatation, be greater than usual, it is in danger of being wounded; in the child, this lower curve or anterior convexity of the rectum is not developed, as the intestine is almost straight, or a little concave forwards. In the adult or old the dilatation of the rectum above the sphincters is often very considerable, particularly in front; to it the prostate gland, vesiculæ seminales, and "bas fond" of the bladder, are connected by cellular tissue, in which a number of very large and tortuous veins may be observed. Next study the connexions of the urinary bladder.

*Vesica Urinaria* is a musculo-membranous sac, the temporary receptacle for the urine, which constantly trickles into it from the ureters;

it is also the chief agent in the expulsion of this fluid from the system by the urethra, being assisted by the abdominal muscles and the diaphragm; situated in the median line, and, to a certain extent, a fixed viscus, its exact position and relations, as well as shape, must vary according as it is contracted or enlarged; the latter also varies with age, and, in some measure, with sex. In the adult, in its contracted state, it is deeply sunk in the anterior and inferior part of the pelvis, behind and below the pubes, and is then of a flattened triangular form, the base towards the rectum, the apex behind the lower edge of the symphysis; when moderately enlarged it becomes of an ovoid form, the larger end resting on the rectum, the smaller and anterior being towards the recti abdominis muscles, between the pubes and the peritonæum; when fully or over-distended the superior or abdominal end rises still higher in the abdomen, and enlarges more and more, so that the larger end of the oval is then above and the smaller end below in the pelvis. In the adult female, especially if she have borne children, the bladder has greater general capacity than in the male, is flattened before and behind as if by the pressure of the uterus and the pubes, and the transverse diameter is longer. In the infant it is pyriform, the large round end, or fundus, above in the hypogastric region of the abdomen, the small tapering neck below the pubis: this fact accounts for the term "fundus" being applied to the "summit" of the organ, which is not only inaccurate as to language, but is really incorrect, as applied to the adult, for the base or fundus is then in the pelvis: the long axis of the bladder is a line directed obliquely downwards and backwards through its cavity from one extremity to the other; its obliquity is increased in proportion as the organ is distended and raised out of the pelvis; it will then correspond to a line drawn from the coccyx to midway between the umbilicus and the pubes. When the trunk is slightly inclined forwards, the cervix is the most depending part; but in the erect, and still more so in the horizontal posture, the "bas fond" is on a plane inferior to the urethral opening, at least in the adult; in the child, however, the bladder, being pyriform with the large end above, the "bas fond" is not developed, and the orifice is the most depending part. The bladder is connected to the parietes and to the viscera of the pelvis by folds of the peritonæum, and by the reflections of the pelvic fascia. The former are termed false ligaments, and are five in number, viz., two posterior, two lateral, and one superior; the latter are reflections of the pelvic fascia, and are four in number, two anterior and two lateral. The *false ligaments* are, first, the two *posterior*, one on each side, leading from the front of the rectum to the back part of the bladder, semilunar, concave forwards and upwards; in each is contained the ureter posteriorly, and the obliterated hypogastric artery anteriorly; between these ligaments the recto-vesical *cul de sac* of the peritonæum descends; one or two semilunar folds usually exist on the posterior surface of the bladder, if in a state of contraction; these disappear, however, when it expands, and

are therefore designed to admit of its more easy distension. The two *lateral* extend from its sides to the iliac fossæ; each contains in its duplicature the vas deferens in the male, and the round ligament of the womb in the female. The *superior ligament* extends from the

*Fig. 53.**

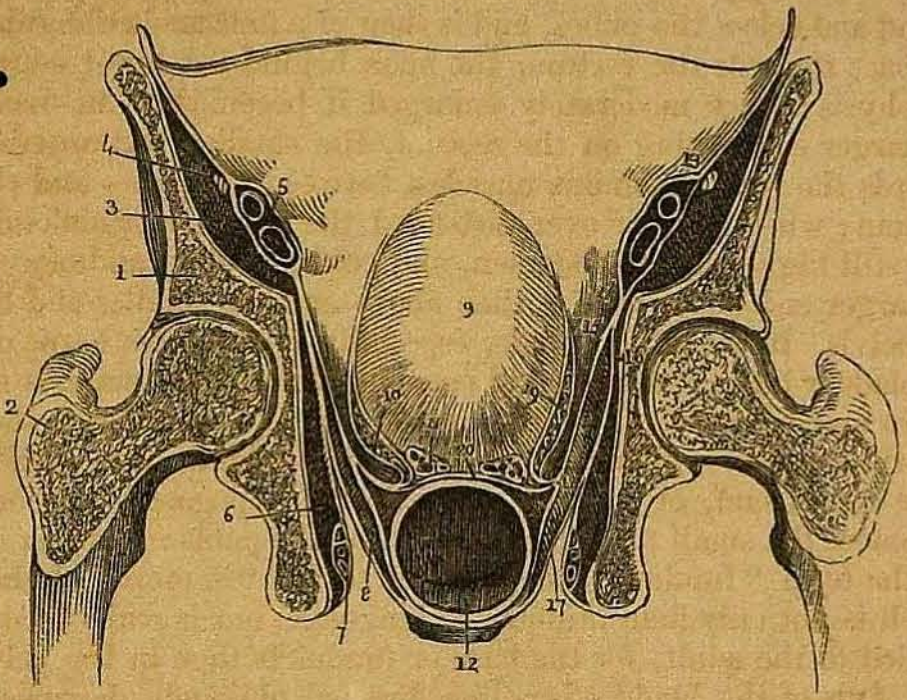


summit of the bladder to the recti muscles, and is partially reflected over the remains of the urachus and umbilical vessels. Detach the peritonæum from the right iliac fossa, and gently draw the bladder and rectum from the pelvis, we shall then observe that the neck and sides of the former are retained in their situation by the reflections of

* A posterior view of a transverse section of the pelvis, shewing the arrangement of the different layers of fasciæ in the pelvis. 1. Section of the os innominatum. 2. Section of the upper extremity of the femur. 3. The iliacus internus and psoas muscles. 4. The divided extremity of the anterior crural nerve, external to the sheath of the vessels. 5. The external iliac artery and vein. 6. The obturator internus muscle. 7. The internal pudic vessels and nerve. 8. The levator ani muscle. 9. The bladder. 10. The vesical plexus of veins. 11. The vesicula seminalis of one side. 12. The rectum. 13. The iliac fascia, covering the iliac and psoas muscles, and separating into two layers external to the vessels, so as to form a sheath for them. 14. These two layers, reuniting beneath the vessels to form the pelvic fascia, which, having descended into the pelvis, divides into, 15, the vesical fascia; and, 16, the obturator fascia, descending on the obturator internus muscle to the tuber ischii, and forming a sheath for the internal pudic vessels and nerve. 17. The anal or ischio-rectal fascia, given off by the obturator, and investing the inferior surface of the levator ani. 18. The vesical fascia, splitting into three laminæ. 19. Its ascending lamina, forming one of the lateral ligaments of the bladder. 20. Its middle lamina, the recto-vesical fascia of Tyrrell, passing beneath the vesiculæ seminales and between the bladder and rectum. 21. Its inferior lamina, the rectal fascia, surrounding the rectum, and meeting the fascia of the opposite side in the mesial line.

the pelvic fascia from the parietes of the pelvis upon this viscus; these are the *true ligaments* of the bladder.

The *anterior*, two in number, *arise* from the lower margin of the pubis by the side of the symphysis, pass backwards and upwards on the upper surface of the prostate gland, and expand on the anterior part of the bladder, with the muscular fibres of which they become partly continuous; their inferior or convex surface is united to the posterior layer of the triangular ligament; a depression exists between them, along which the dorsal veins of the penis pass from beneath the arch of the pubes to the side of the bladder in their course to the internal iliac veins; the fascia, however, is not deficient between these ligaments, but is continued from one to the other, so as to line this depression and cover the veins. The *true lateral ligaments* are one on each side; each is continuous with the anterior, and is formed by the reflection of the pelvic fascia from the inner surface of the levator ani to the side of the prostate gland and of the bladder, and encloses the vesical venous plexus.

The superior anterior extremity is named the *superior fundus;* the posterior, which presses against the rectum, the *inferior fundus*, or "bas fond;" the intervening portion, the *body;* and that part which is connected to the pubes, and is above the rectum, the *cervix;* the latter is surrounded by the prostate gland, but little, however, of the latter being above it; the cervix is somewhat conical; in the adult it lies nearly horizontal, below and behind the pubes; in the child it is more vertical or oblique. There is no exact distinction, however, between these several compartments, and a more accurate knowledge of the organ may be obtained by examining the several aspects or regions it presents when moderately distended, which are six in number, and on each of which some important object may be noticed. 1st, The *superior region* is in contact posteriorly with the convolutions of the small intestines, and anteriorly with the recti muscles; to it are attached the urachus and obliterated umbilical arteries; posterior to which, only, it is covered by the peritonæum; if much distended, this region is sometimes found to incline to the left side. 2nd and 3rd, The *lateral regions* are contiguous to the sides of the pelvis, to the vesical fascia, and to the levatores ani muscles; descending obliquely backwards along this region is the vas deferens, crossing over the umbilical artery above, and the ureter below, passing internal to both, or nearer to the mesial line; the peritonæum adheres to so much of each lateral region as is posterior to the vas deferens, while that portion anterior to it is deficient of serous covering. 4th, The *anterior region* also looks a little downwards; it is behind the recti muscles, the pubes, the pubic ligament, and the triangular ligament of the urethra; all this region wants the peritonæal covering; towards its inferior part we observe the anterior ligaments of the bladder, between these the dorsal veins of the penis, and below these the neck of the bladder surrounded by the prostate gland. 5th. The *posterior region* is contigu-

ous to the rectum in the male, to the uterus in the female, and in either sex occasionally to the convolutions of the small intestines: all this region is covered by peritonæum. 6th. The *inferior region*, in the female, lies on the ureters and on the vagina; in the male, on the vesiculæ seminales, the intervening *cul de sac* of peritonæum, the rectum, and the prostate gland; the superior and posterior part of this region is covered by the peritonæum; but anterior to the line of the reflection of this membrane from the bladder to the rectum, is the triangular portion of this region, in which the peritonæum is deficient, and which has been already attended to, as the situation in which the operation of tapping the bladder from the rectum may be performed. In the contracted state of the organ, the peritonæum descends almost to the prostate gland, and nearly covers all this space; but in the distended state not only is the latter much enlarged, but the peritonæum is raised out of it posteriorly, so as to allow the bladder and rectum to come in contact. It is composed of five tunics or laminæ, three of which are essential or proper, serous, muscular, and mucous; these are connected by two laminæ of cellular tissue. The *serous* is but a partial coat, covering those portions only which come into contact with other moveable viscera, namely, the posterior region, the back part of each side, and of the upper and lower fundus; all the anterior region, the cervix, the forepart of the sides and fundus, are, therefore, uncovered by peritonæum; when distended, there is more of it in proportion covered by this membrane than when it is contracted; it is dense and strong, and can be easily detached from the muscular coat, to which it is connected by the first or *external cellular tunic;* this lamina, in some situations, is compact and elastic; in others, as in front, it is loose and abundant, to allow the bladder to rise out of the pelvis; inferiorly it contains several veins, partially envelopes the vesiculæ seminales, and is continued to the forepart of the rectum; it contains but little adipose substance; blood-vessels and nerves ramify and divide in it in their course to the other textures; it serves to connect the serous to the muscular coat, and to support and bind together the fibres of the latter. The *muscular coat* consists of fasciculi, arranged in such different directions as to admit of partial separation into two or three laminæ, longitudinal, circular, and reticular; they are very variable as to strength and colour, but in these respects they surpass those of other hollow viscera, except the heart and œsophagus; the first or longitudinal are the strongest and most numerous, proceed from around the cervix, and expand over the entire surface; those on the forepart are connected superiorly to the urachus, and inferiorly to the anterior ligaments, and through these, as by shining tendons, to the pubes; hence some have described this lamina as a distinct muscle, "detrusor urinæ," but incorrectly; some pass deeper, and are inserted into the cellular tissue about the prostate, and some still deeper into the fibro-muscular tissue of the cervix, whereby they are enabled to expand the sphincter during their contraction, and so allow the escape of the urine; laterally, these fibres are inserted into the prostate and

its investing fascia; and, posteriorly, they are weak and scattered above, but below and between the ureters they form a strong, broad, and flat band; several fibres are inserted into the trigone, into and around the ureters; on the latter some even ascend in a retrograde course; no fibres pass over the vesiculæ seminales as over the prostate, but between these a distinct lamina descends to the base of the prostate, into and beneath which the fibres are inserted into the submucous tissue; one fasciculus can be traced mesially beneath the uvula as far as the verumontanum, under which it is inserted by a delicate tendon; the effect of these fibres must be to depress the uvula, also to depress and retract the verumontanum, and thereby protect the latter from the irritation of the urine, and at the same time open the orifice of the urethra freely for the passage of this fluid: in the female these longitudinal fibres are inserted anteriorly and laterally into the cellulo-vascular and glandular tissue around the cervix, and posteriorly into a more dense tissue, connecting the urethra to the vagina; the longitudinal fasciculi are frequently crossed by transverse and arched bands, particularly in front, where also they often decussate in the median line, and then pursue a different course; this lamina may, by careful dissection, be raised in some places to some extent, particularly before and behind and below, but not uniformly throughout. The next order of fibres is circular; these are pale and scattered, particularly above, but as they approach the cervix they become more close and distinct, and have been considered by some as the "sphincter vesicæ," but there is no distinction between these and those above them, which are plainly designed to contract the organ; this term, therefore, is probably incorrectly applied. The circular or transverse fibres are very distinct posteriorly between the two ureters, and a strong semilunar band, concave backwards, forms the base of the trigone in front of the pouch or "bas fond," which is generally well developed in the adult and aged. This band can be better seen when the bladder is opened: it is impossible to raise these circular fibres as a distinct plane, as so many deviate from this direction and join deeper fibres in a tortuous or irregular course. The third set of muscular fibres are best seen from the internal surface; they project through the mucous membrane as distinct fasciculi, large and separate, and most irregularly arranged, so as to present a reticulated or honeycomb appearance; they are often very large, and, though paler, are not unlike some of the carneæ columnæ of the heart; they take various directions, divide, join again, subdivide, and unite with some of the other planes; when hypertrophied, these fibres often project considerably into the cavity, causing proportioned depressions or pouches of the membrane between them. This condition is named the columnar bladder, and the pouches, which often become dilated, like offsets with narrow, constricted mouths, are true herniæ of the mucous coat. This condition is named the sacculated bladder. In these sacs calculi are sometimes lodged, and one of them may undergo such gradual enlargement and lateral elongation as to become engaged in femoral or inguinal

hernia. The neck of the bladder presents a peculiar structure; there is no exact limit to this part, hence the term is differently applied by different writers: some include as cervix all that portion in front of the recto-vesical reflection of peritonæum; others consider it so much only as is surrounded by the prostate gland; but most regard this as the first division of the urethra. There is, therefore, no exact limit or external mark to define this part, although it is one so generally alluded to. We consider as the neck that contracted, conical portion of the viscus, longer below and on the sides than above, which is embraced inferiorly and laterally by the base of the prostate gland, and laterally and above by the peculiar contractile structure which fulfils the office of a sphincter; this part contains internally and below, the slight elevation called the uvula or "luette," which lies over the middle lobe of the prostate gland; the contractile tissue is muscular, also fibrous and elastic, as well as vascular and nervous; it surrounds three-fourths of the orifice; the muscular fibres are red and close, are attached to the fibrous basis of the trigone on each side of the uvula, behind which they do not pass; they are not continuous with the circular plane, but the longitudinal fibres are partly inserted into this semicircular muscle, in the same way as the levatores intermingle with the sphincter ani; it is partly elastic, but essentially muscular; bounds the urethral opening laterally and above, but not below: the slight projection of the uvula in the latter situation, and the elasticity and tonic contraction common to all sphincters, preserve the opening in a closed state, and the urine is thus retained in the bladder, the muscular coat of which is in a passive and relaxed state; when distension excites the usual feeling, the general muscular coat contracts towards the pubis and cervix, and the longitudinal fibres draw out from the axis of the opening the relaxed sphincter which encompasses three-fourths of it, while the long middle band will depress the uvula and retract the seminal caruncle, and thereby free the passage into the urethra. At the anterior part of the inferior region there is a compact layer of white, dense, fibrous substance, into which the muscular, particularly the longitudinal, fibres of the bladder are inserted, but which itself does not appear to be very muscular, except near the cervix; this structure will be found to correspond with a particular region, to be noticed presently, in the interior of the bladder, called the trigone, or velum. Beneath the muscular is the fourth, or the *deep cellular coat;* it invests the whole organ, is very elastic, and seldom contains any adipose substance; it supports and strengthens the mucous lining, and contains the nutrient vessels and nerves. Open the bladder by a perpendicular incision through its anterior part, and the fifth, or *mucous coat*, will be observed, pale, and thrown into many folds, chiefly transverse, particularly if the bladder had been empty, for this membrane has no contractile power; through it the muscular fibres project, presenting a reticulated appearance, and very frequently the mucous membrane forms pouches, or small sacs, between these: infe-

Fig. 54.*

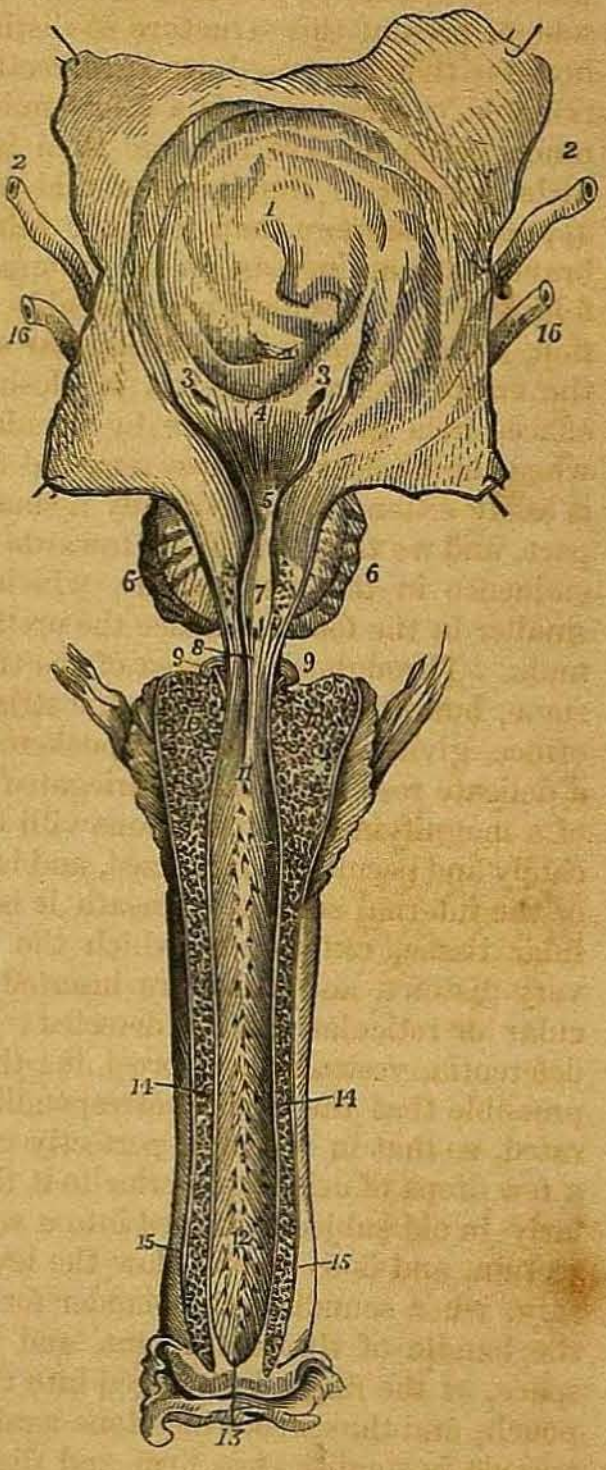


riorly is seen the orifice of the urethra, somewhat of a crescentic figure, the uvula projecting into it from below; posterior to this the membrane presents a smooth and dense appearance throughout a small triangular space called the *velum* or *trigone;* at the posterior angles of which are the orifices of the ureters; the line extending between these forms the base of this triangle, is somewhat semilunar, and contains strong muscular fibres; the sides are defined by lines drawn from each ureter to the uvula from an inch to an inch and a half in length; beneath the membrane covering these, pale muscular fibres may in general be found; these have been named by Mr. Bell the *muscles of the ureters*, who describes each as *arising* from the vesical extremity of the ureter, and thence descending obliquely forwards and inwards, to be *inserted* by a tendon common to its fellow into the uvula. The *use* which he assigns to them is, to restrain the termination of the ureters, and preserve the obliquity of the passage of these tubes through the coats of the bladder while it is being contracted; for, says

* The urinary bladder and canal of the urethra laid open. 1. The mucous coat of the bladder thrown into folds. 2. 2. The ureters. 3. 3. Their orifices at the posterior angles of the trigone. 4. The base of the trigone. 5. The uvula. 6. 6. The prostate gland. 7. The prostatic portion of the urethra, the figure is placed on the verumontanum. 8. The membranous portion of the urethra. 9. 9. The antiprostatic glands, or glands of Cowper. 10. 10. The bulb of the urethra. 11. The spongy portion of the urethra, the figure is placed on the sinus of the bulb. 12. The fossa navicularis. 13. The orifice of the urethra. 14. 14. The corpus spongiosum urethræ. 15. The corpora cavernosa penis. 16. 16. The vasa deferentia.

he, without this provision, the urine would be sent retrograde into the ureters, instead of forward into the urethra. These lines, however, seldom present this structure so distinctly as has been described, and how far their supposed use is correctly ascribed to them is very questionable.* The *uvula* is a small eminence at the apex of the trigone, much better marked in some than in others; nearly opposite, but a little anterior to the third or middle lobe of the prostate gland, it appears little more than a slight fulness or prominence of the membrane, with an increase in the submucous tissue, which contains some follicles; it is vascular, and probably possesses some special organization, which endows it with peculiar sensibility and associates it with the entire organ; it assists in closing the urethral opening, but is effaced in a great measure by opening the cervix from the urethra when the bladder has been removed from the body, as the membrane is easily extended; but if only a small opening be made in the upper part, and we then look down towards the urethra, it appears as a small eminence in the median line, which it thus assists to close: it is smaller in the female; hence the urethral opening is larger than in the male. Throughout the area of the trigone the membrane is free from rugæ, but often marked with fine striæ, which converge to the urethral orifice, giving to the latter a puckered appearance. It usually presents a delicate rose tint, being variegated with fine vessels; with the aid of a magnifying lens numerous villi can be detected; it appears delicately and peculiarly organized, and is, no doubt, the most sensible part of the internal surface; beneath it is a dense substratum of fibro-cellular tissue, exterior to which the longitudinal muscular fibres are very distinct, and many are inserted into it, but very few of the circular or reticular can be detected; it is also supported by the vasa deferentia, vesiculæ, and prostate; this portion is so firm and incompressible that the cavity corresponding to it cannot be wholly obliterated, so that in the most perfectly contracted state it will still retain a few drops of urine; posterior to it the bladder is frequently, particularly in old subjects, dilated into a sort of pouch, which rests upon the rectum, and is so much below the level of the trigone that it is necessary, when sounding the bladder for the detection of a stone, to raise the handle of the instrument, and thus depress the point into this space, or the finger introduced into the rectum may raise forward this pouch, and thus strike the stone against the sound. In the female the trigone is smaller, less firm and distinct, but broader in proportion, than in the male, and the uvula is less developed.

The vesical arteries are variable as to origin, number, and size; they arise from the internal iliac, pudic, and obturator; the veins form a remarkable plexus around the cervix, which extends along the sides of the inferior fundus and vesiculæ seminales, and opens into the internal iliac, or some of its branches; the nerves are derived both from ganglionic and spinal filaments of the hypogastric plexus; ac-

* See art. "Bladder," Todd's Encyclop. of Anat. and Phys.

cordingly the muscular power is partly involuntary and partly under the influence of the will.

This organ is by no means essential to the urinary secretion, and is absent in many animals; it is merely intended as a reservoir for the urine, and to act in its expulsion, in which it is the chief agent, for when its muscular coat is in a state of paralysis the most violent action of the abdominal muscles and diaphragm is unable to empty it of its contents.

The bladder is occasionally found in a *diseased* state; inflammation of it (cystitis) may be general or confined to one particular part; the portion which is most frequently so affected is that near the neck, and commonly arises from the presence of a rough stone: from the naturally pale appearance of the mucous membrane in the dead body any crowding of vessels containing arterial blood which takes place in inflammation, makes this state of parts easy of detection, and this is the case in chronic inflammation or catarrh of the bladder: if the inflammation be violent, the muscular coat may become engaged, and abscesses and ulcers are not unfrequently the consequence; they sometimes proceed so far as to destroy a portion of the bladder, and form communications between it and the neighbouring viscera; with the rectum in the male, and vagina in the female; they have also been known to open into the cavity of the abdomen, producing peritonitis and death from extravasation of urine; abscesses about the neck of the bladder are generally found as a consequence of the operation of lithotomy or of fatal retention of urine, or diseased prostate gland. The uvula, like other similar portions of mucous texture, is subject to infiltration and increase of size in acute inflammatory affections, as also to chronic enlargement, and closely simulates disease of the middle lobe of the prostate gland. Calculi are not uncommonly formed in the bladder, their formation is confined to no particular period of life; they are found in very young children and in persons of middle and advanced age; they are less frequent in females, as the size of the urethra in that sex allows them to be discharged before they become large, probably also the tendency to their formation is not so strong. The stones which are found in the bladder are either originally formed in the kidneys, and pass through the ureters into the bladder, or they are at first formed in the bladder itself. Calculi lie either loosely in the cavity, or are confined to some fixed situation from particular circumstances; when they are of a small size they are sometimes lodged in pouches, formed by the protrusion of the mucous coat between the muscular fasciculi. Urinary calculi have sometimes a smooth, uniform surface, but more frequently they are granulated and rough.

The urethra is the next division of the urinary organs to be examined; as this canal, however, in the male, is the common passage for the urine and semen, and a part both of the urinary and generative organs, we shall postpone the description of it until we have considered the latter.

# SECTION VIII.

## DISSECTION OF THE ORGANS OF GENERATION IN THE MALE.

These are the testicles and their appendices, the vesiculæ seminales, the prostate and anti-prostatic glands (the latter have been already examined), the penis, and the urethra. The testes secrete the seminal fluid, the vasa deferentia conduct this to the vesiculæ seminales, whence it is conveyed, together with the secretion of these organs, by the ejaculatory ducts, into the urethra; the secretions from the prostate and antiprostatic glands are added to it, but equally belong to this canal as a common passage for the urine, as well as semen; finally, the urethra is enclosed in a spongy erectile tissue, to which is added the analogous structure of the two crura penis, whereby it is adapted for the final expulsion of the seminal fluid. We shall describe these organs in the following order: 1st, the testes with their coverings; 2nd, the vasa deferentia; 3rd, the vesiculæ seminales; 4th, the prostate gland; 5th, the penis; and 6th, the urethra.

1st. The *Testes.*—These two glands are, during the greater part of uterine life, contained in the abdomen beneath each kidney; some time, however, previous to birth, they descend into that situation which they are found to occupy in the adult, and are surrounded by several tunics, viz., the scrotum, dartos, superficial fascia, tunica communis, vaginalis, albuginea, and vasculosa; the three first are common to both, the others are proper to each testis.

The *Scrotum* is a loose process of integument continued from the inner side of each thigh, and from the perinæum and penis; it is generally of a dark brown colour, thinly covered with oblique hairs, the white bulbs of which project upon the surface; it usually presents numerous wrinkles, and is so thin that the subcutaneous veins and sebaceous follicles can be seen through it; these latter secrete the peculiar perspirable matter of this region; the prominent hard ridge or raphe is continued from the perinæum along its middle line as far as the penis. In the old and enfeebled, or under the influence of warmth, it is soft, flaccid, and elongated; but in the robust, or when exposed to cold, it becomes rugous and closely contracted around the testes, and deeply indented between them; certain mental and nervous emotions also induce similar changes, which most probably depend upon the action of the subjacent tissue, the dartos, rather than upon the skin itself.

The *Dartos* is the peculiar cellular tissue immediately subjacent to the skin; it usually presents a reddish appearance; a number of small vessels are distributed through it; its texture is very loose, and is readily distended in emphysema, or in anasarca; it never contains any fat; it is somewhat more dense in the mesial line than at either side, is connected to the rami of the pubes and ischium, and to the raphe in the middle, thence it ascends a short way between the testes to the

urethra, and thus assists the superficial fascia in forming the *septum scroti*, which divides this pouch into two lateral portions, of which the left is generally the longer; some describe the dartos as double, one for each side; the dartos manifests during life a degree of contractility above that which cellular tissue enjoys in any other situation; it possesses the power of corrugating the skin, and moving the testes in a sort of vermicular or peristaltic manner, distinct from the upward motion of these glands produced by the cremaster muscles; anteriorly and laterally it ends abruptly in the cellular and adipose tissue of each femoral and inguinal region; in the middle it is continued round the penis, and can be sometimes traced even to the prepuce; posteriorly it extends near to the anus, and often derives a few muscular fibres from its sphincter: it is composed of thin areolar tissue, traversed by nerves and vessels, and intermingled with fine, soft, reddish filaments, which are interlaced in an irregular manner; some fibres are transverse, but the most are vertical; these resemble the involuntary muscular fibre in being unstriped, and in the effect of acetic acid bringing into view the peculiar corpuscles they contain, and which distinguish them from the white and yellow fibrous elements of the areolar tissue: the dartoid then appears to be a peculiar tissue, intermediate between cellular and muscular: a somewhat analogous texture most probably pervades certain other parts, viz., the vagina, the nipple, the coats of some excretory ducts and blood-vessels; the dartos exists in the scrotum before the descent of the testes, and cannot therefore be derived from the expansion of the gubernaculum testis, as some have supposed.

Beneath the dartos is the *superficial fascia* of the scrotum, continued from that of the abdomen around each spermatic cord, testicle, and epididymis, thin, loose, and reticular, it becomes continuous with the fascia of the perinæum; as it envelopes the cord and testis on each side, it assists the dartos in forming the *septum scroti*, and retaining each testicle at its own side; it is very distinct above towards each inguinal ring, also posteriorly where it enters the perinæum, but in the intermediate space it is a mere cellular connexion between the dartos and the next covering of the testis. Some anatomists, therefore, include this tissue in their account of the dartos, and do not consider it as a separate lamina of the scrotum.

The *tunica communis*, or *erythroides*, or *musculosa*, is a compound tissue; it commences in the inguinal channel, is composed essentially of the cremaster muscle, very variable in strength and colour, consisting superiorly of two or three fasciculi, which descend on the outer and forepart of the cord, expand and separate on the testis in curved or arched lines, concave upwards, and inserted partly into the tunica vaginalis, and partly by re-ascending fibres into the cord and pubis (see page 195); the fasciculi are covered and bound together by a fascia derived from the deep aponeurosis of the abdominal muscles and from the pillars of the external ring (intercolumnar or spermatic fascia); internally they are also connected by a fine membrane derived from

the edges of the internal ring (the infundibuliform fascia from the transversalis), and from the cellular tissue in the canal; the two former components of the tunica communis expand all round the testis, but the latter being closely attached to the vessels of the cord adheres to its upper and back part and to the epididymis, and does not, therefore, properly cover the gland: this tunic is the chief means of suspension of the testis, while the cremaster also draws it upwards and outwards, supports and compresses its vascular texture, and urges its secretion through the vas deferens: in old hernia and hydrocele it sometimes acquires prodigious strength and thickness; the influence of these diseases upon this structure, however, is very variable.

The *tunica vaginalis*, or *serosa*, was originally, that is, in fœtal life, a process of the peritonæum, having been prolonged in front of and around the cord and testis, as the latter was descending from the abdomen to the scrotum; at this age the tunica vaginalis freely communicated with the cavity of the peritonæum by a canal which led along the forepart of the cord from the abdomen to the scrotum: this canal, however, previous to birth, was closed by the adhesive process, and ever afterwards the cavity of the tunica vaginalis is distinct from that of the peritonæum.* The tunica vaginalis, therefore, is a serous membrane, a shut sac of an oval form, suspending and partly enclosing the testicle, and also reflected over its anterior part and sides, and larger than the gland, as it also encloses a portion of the epididymis and of the cord; that portion of it which suspends the gland, and which lines the scrotum, may be named the tunica vaginalis *scroti*, or parietal layer, while the reflected portion, which covers the sides and forepart of the testicle, is the tunica vaginalis *testis*, or visceral layer. This membrane is so loosely connected to the scrotum that it can be detached from it with little force; it is thence reflected on the sides and forepart of the epididymis and testis; it also ascends a short distance on the forepart of the cord, higher upon its inner side, and separated from the epididymis by the vas deferens and the spermatic vessels; the posterior part of the epididymis is altogether uncovered by it: as it is continued from the epididymis to the testicle it passes in between these organs on their outer side, so as to form a sort of pouch or *cul de sac* between them. Both the testicle and epididymis are in reality behind this serous membrane, and nothing is contained within its cavity except the serous fluid which lubricates its opposed surfaces, and which facilitates that gliding motion which the testicle undergoes in the scrotum; hence in hydrocele, or dropsy of this sac, the testis is almost always at the upper, inner, and back part of the tumour. When the anterior part of the tunica vaginalis is divided, we see its internal surface smooth and polished; shining through its reflected layer which covers the testis, we can discern the next, or the fibrous tunic of the gland, to which it adheres very intimately,

* When this canal is not thus closed, a hernia usually occurs, which is named "congenital inguinal hernia." In most animals it communicates with the general peritonæum at all ages.

forming with it a true fibro-serous membrane like the pericardium or the dura mater: the tunica vaginalis serves to insulate the testis from adjacent parts, and to facilitate those gliding motions which enable it to elude injury or pressure.

*Tunica albuginea* is a dense fibrous membrane, of a bluish white colour; the proper capsule of the gland, adheres to it, preserves its form, and sends several processes or septa into it, which will be seen when it has been divided; it has no connexion to the epididymis; the reflected layer of the tunica vaginalis is intimately united to it; through it the blood-vessels of the vascular coat can be distinctly seen; having invested the whole gland, it is inflected into it posteriorly in the form of a vertical plate or partition, composed of two laminæ, one from either side, enclosing between them the vessels, nerves, and ducts; this is the *corpus Highmorianum* or *mediastinum testis;* from its anterior or visceral border numerous bands radiate forwards, inwards, and outwards, and adhere to similar processes from the inner surface of this coat; these are the *septa* or *desipimenta testis*, which divide the organ into so many compartments, conduct the vessels to and fro, preserve the form of each, and protect the glandular contents from compression; in the mediastinal process the blood-vessels are most distinct posteriorly, the seminal ducts anteriorly.

*Tunica vasculosa*, so named by Cooper, is an extremely delicate membrane, and in immediate contact with the glandular tissue, composed of minute but tortuous ramifications of the spermatic vessels, united by a fine cellular web; it lines the albuginea, and is so thin in some places as scarcely to deserve the name of a distinct membrane; it not only envelopes the surface, but also sends in delicate membranous processes along each of the septa, which convey the nutrient vessels to the lobules of the gland.

*Fig. 55.**

Each *testicle* is of an oval form, flattened on each side, also a little on the back part beneath the epididymis; it is suspended rather obliquely, the superior extremity being directed forwards and outwards, the inferior backwards and inwards; the left is a little lower than the right; hence, when the thighs are crossed, these glands do not approximate so closely, thereby they escape compression; bent like an arch, along the

* A section of the testicle. 1. The cavity of the tunica vaginalis; the external layer is the tunica vaginalis scroti, and the internal, which covers the testicle, is the tunica vaginalis testis. 2. The tunica albuginea. 3. The tunica vasculosa, or pia mater testis. 4. The corpus Highmorianum, or mediastinum testis, shewing the rete testis between its laminæ and the fibrous septa which connect it to the internal surface of the tunica albuginea. 5. 5. The convolutions of the tubuli seminiferi, terminating in the tubuli recti. 6. The epididymis.

posterior surface and external aspect of each, is the *epididymis*, long and narrow, large above (globus major), narrow in the middle (body), and again enlarged below (globus minor), attached to the testis above by vessels, and in the rest of its extent by the reflected layer of the tunica vaginalis, closely on the internal, but very loosely on the external or femoral side; from its inferior extremity the vas deferens proceeds, and thence ascends along its internal side. Divide the tunica albuginea anteriorly, and we observe the testicle to be composed of a soft, greyish, or yellowish pulpy substance, which, when opened out a little and floated in water, is found to consist of numerous fine, tortuous shreds or vessels of delicate texture, loosely connected to each other; some are of considerable length, and with a little care may be drawn out of the gland to the extent of two or three feet, presenting at first a knotted or beaded appearance, owing to the coils or convolutions; they are placed in packets or fasciculi, which are separated from each other by fibrous bands or septa, derived from the tunica albuginea, and which may now be seen to pass in considerable number through the gland towards the back part to join the *corpus Highmorianum*, which is broader above than below, and perforated in the former situation by the excretory ducts. These packets or bundles of tubes are the *lobules* of the testis, between three and four hundred in number; each is of a flattened, conical form, the base towards the surface, the apex posteriorly towards the mediastinum, enclosed in two membranous capsules, one from the tunica albuginea, the other from the tunica vasculosa, and composed either of one or of a mass of *convoluted tubuli seminiferi*, with minute blood-vessels; some tubes appear larger than others; their average diameter is the $\frac{1}{150}$ part of an inch, and occasionally they receive injection from mercury, but seldom admit any fine-coloured fluid; in each lobule these tubes commence or terminate either in anastomosing loops or in free cæcal ends; their convolutions also appear to communicate; but the tubuli in one lobule do not directly inosculate with those in another, hence mercurial injections are often but partially successful, some of the lobules only being filled; the tubes are less convoluted posteriorly, where several coalesce, and they all terminate in about twenty larger and less convoluted vessels, which proceed in parallel lines towards the back part of the gland; these are the *tubuli recti;* they enter the mediastinum, and if one lamina of this process be raised off, they will be seen entangled with each other, and with the vessels and nerves of the gland; this latter structure is named *Rete Testis*, is placed near the posterior part of the gland, between the laminæ of the mediastinum; from the upper part of it about eight or ten tortuous vessels ascend obliquely backwards, pierce the tunica albuginea, and arrive at the head of the epididymis; here they increase in size, and become coiled or convoluted; these are the *vasa efferentia*, or *coni vasculosi:* they form the head or globus major of the epididymis, and unite into one small duct (the vas deferens), which is twisted and coiled over and over again in a most extraordinary and peculiar manner. The body and globus minor are

solely composed of this convoluted vessel, which by care may be unravelled to a great extent; some coni vasculosi, or coiled seminal ducts, continue from the head through the body of the epididymis, and end in the vas deferens; the convolutions of this latter, of which the epididymis thus principally consists, are connected to each other by fine cellular tissue, and by the reflected tunica vaginalis; it has no fibrous capsule like the testis; from its lower extremity the *vas deferens* at length escapes, and, increasing in size and density, this duct bends upwards along the inner side of the epididymis; a little above the head of the latter it becomes a part of the spermatic cord, and is connected to the spermatic vessels and cremaster muscle behind, and distinct from both; with these it continues its course obliquely upwards and outwards along the inguinal channel, and through the internal abdominal ring; it here separates from the spermatic vessels, the latter ascending towards the spine, and passes backwards, inwards, and downwards, enclosed in the lateral fold of peritonæum, which conducts it to the bladder, along the side and inferior fundus of which it runs internal to the vesicula seminalis, and converging to its fellow: at the base of the prostate gland each vas deferens joins obliquely the duct of the corresponding vesicula, the union of which forms the *ductus ejaculatorius communis*, which runs through the prostate obliquely forwards and inwards, and opens into the prostatic portion of the urethra on the side of the verumontanum. While the vas deferens is contained in the spermatic cord, it lies posterior to the spermatic arteries and veins, and to the cremaster muscle; as it passes through the internal ring it hooks round the outer side of the epigastric artery, being separated from it by the spermatic artery alone; it next passes over the psoas and iliac muscles, the external iliac artery and vein; it then bends over the obliterated hypogastric artery and descends internal to it; and in the same manner it next crosses over the ureter, so as to lie at first anterior to that tube, or between it and the bladder, and then to descend along its internal side; it then runs between the bladder and rectum, near to its fellow, and internal to the vesicula seminalis, as far as the prostate gland, which it perforates in the direction before mentioned. This vessel has a peculiar, hard, wiry feel, like whipcord; its calibre is very small; its coats are two in number, an internal mucous, and an external very thick, firm, and white, like fibro-cartilage; the mucous surface is pale, rough, and alveolar, but very thin; the external coat is most probably fibrous, the fibres being principally circular; their true character is not ascertained in man, but in some animals the fibres are longitudinal and circular, and apparently muscular. Between the vesiculæ each vas deferens is flattened, enlarged, and often convoluted; when it enters the prostate it again contracts, and its firm external tunic ceases. In some a second duct, *vasculum aberrans*, will be found to leave the testis or the epididymis, and to run for some distance parallel to the vas deferens, which in some cases it will join, while in others it will be found to end in a *cul de sac*.

The *spermatic cord* extends from the epididymis to the internal ab-

dominal ring; it consists of the vas deferens, spermatic artery, veins, nerves, and lymphatics; this fasciculus of vessels is covered by loose cellular membrane, and by the cremaster muscle: beneath the latter and the fascia which supports it, the vessels of the cord will be found joined together by a fine membrane, named the *tunica vaginalis of the cord;* this is the remains of that portion of peritonæum which in the fœtus accompanied the spermatic vessels to the scrotum, and which after birth lost its serous characters, and became converted into condensed cellular membrane; this covering is strengthened by the prolongation of the fascia transversalis which is continued from the internal abdominal ring along the spermatic vessels. The *spermatic artery* arises from the abdominal aorta below the renal artery, and not unfrequently from the latter; it descends along the psoas muscle, passes through the internal abdominal ring on the outer side of the epigastric artery; it then enters the spermatic cord, is conducted to the back part of the testicle, and divides into several branches which enter the rete testis; these subdivide minutely as they proceed into the substance of the testicle, in which they twine around the tubuli seminiferi and the spermatic veins; one or two small arteries from the epigastric are distributed to the cremaster. The *veins*, when they leave the rete testis, twine around the arteries, and then ascend in the spermatic cord; a little above the testicle these vessels become very tortuous, and form a plexus, which is named Corpus Pampiniforme; the spermatic veins then accompany the spermatic artery through the inguinal canal and along the psoas muscle towards the spine: the right spermatic vein generally ends in the inferior cava near the entrance of the right renal vein; the left frequently ends in the left renal vein. The nerves of the testicle are derived chiefly from the spermatic plexus, which is formed by the union of branches from the lumbar ganglions of the sympathetic, with filaments from the splanchnic nerves and from the renal plexus; the cremaster muscle is also supplied by branches from the lumbar plexus of spinal nerves, hence this muscle is, to a certain extent, voluntary.

The *vesiculæ seminales* are two membranous sacs of variable size, situated on the inferior surface of the bladder, behind and above the prostate gland, on the outer side of the vasa deferentia, and anterior to the rectum, converging before, diverging behind, connected to the bladder by filamentous tissue, surrounded by venous plexus, and forming the sides of the triangular space, which is completed by the prostate gland, and by the recto-vesical fold of peritonæum; each is of an oval figure, about two inches long and half an inch broad; the superior and posterior extremity is large and round, and in contact with the ureter; the anterior is narrow, connected to the prostate gland, and ends in a small duct which joins the vas deferens; the union of these forming the *common seminal* or *ejaculatory duct*, which is about three quarters of an inch long, and passes obliquely forwards and inwards through the prostate gland, between its middle and lateral lobes, and opens into the urethra by the side of the anterior extremity of the

verumontanum. Although the vesiculæ look like a congeries of cells, yet by dissection they may be unravelled, so as to appear as one continued tube convoluted or coiled very much, the different coils communicating with each other; these organs are covered by a dense fascia, which is continued from that covering the prostate gland. Each vesicula consists of two tunics, viz., mucous membrane internally, and peculiar grey substance externally, somewhat similar to, but softer than the outer coat of the vas deferens. The vas deferens communicates very freely with the corresponding vesicula; hence air or fluid injected into the vas deferens will often distend the vesicula seminalis of the same side before it escapes into the urethra by the common ejaculatory duct. These organs are generally believed to contribute some additional secretion to the seminal fluid, rather than to serve as reservoirs for the latter; their exact use, however, is not well known; they are wanting in many animals. The common seminal or ejaculatory ducts are thin, the external coat of the vesiculæ and of the vasa deferentia cease, and these canals appear to be formed of little more than a fine mucous membrane; their calibre is larger and more dilatable than those of the vesiculæ or testis.

The *prostate gland* is situated at the anterior and inferior part of the pelvis, behind the triangular ligament, and in front of the rectum, to which it is connected by cellular membrane; it surrounds the neck of the bladder and about an inch and a quarter of the urethra; is attached and nearly fixed in its position by the anterior ligaments of the bladder to the lower edge of the symphysis pubis, from which it is about three-fourths of an inch distant, also by the posterior lamina of the triangular ligament, which encloses the membranous part of the urethra, and expands around this gland; it is also surrounded by several veins. The prostate is somewhat chesnut or heart-shaped, or triangular; the base is posterior, and connected to the vesiculæ seminales; the apex is anterior, and extends to within a short distance of the triangular ligament; in the erect posture its long axis is nearly horizontal, sloping a little downwards and forwards, but in the recumbent it is the reverse, the base being on a lower level than the apex: only a small portion of it lies superior to the neck of the bladder and urethra; this part is convex, and is covered by the dorsal veins of the penis, and by the anterior ligaments of the bladder; the inferior or posterior surface is almost flat, a slight groove is generally observable on it, extending along the mesial line; this surface is attached to the forepart of the rectum, and may be felt distinctly either in the living or in the dead subject by the finger introduced into the intestine about two inches and a half above the anus; the sides of the gland are smooth, very round, and covered by a strong fascia, by several veins, and by the levatores ani muscles; the relation of the urethra to the prostate varies, in general it is one-third nearer to its upper than its lower surface; in some the gland is absent above, and the urethra may be said to groove it only; in others it forms a cylinder around the canal, wider in the centre than at the ends; and in some rare

cases it has been found thicker above the urethra, being separated from the rectum only by a thin lamina. In the base or posterior end is a notch for the entrance of the common ejaculatory ducts; this notch, together with the groove on the posterior surface, and the passage of the urethra above this, have caused it to be described as consisting of two lateral portions, called the *right and left lateral lobes;* these are connected to each other posteriorly by a small transverse process called the *middle lobe;* the latter may be seen by detaching the vesiculæ and vas deferentia from the bladder, and leaving them suspended by their common ducts, the middle lobe of the prostate will then be seen to pass from one lateral lobe to the other, and to be closely connected to the mucous membrane of the bladder, and above the ducts: the bilobed appearance of this gland is more distinct in animals than in man.

The prostate has a firm, resisting feel, a greyish colour, and a very compact structure; these characters, however, chiefly depend on the strong fascia which invests it, and which forms its capsule: the capsule has been already described as being partly derived from the posterior layer of the triangular ligament, which expands on the sides and inferior surface of the gland, and partly from the reflection of the pelvic fascia from the pubes, called the anterior ligaments of the bladder. Next continue the incision, which was made in the forepart of the bladder, through the upper part of the prostate, so as to lay open the urethra; we shall perceive how this gland surrounds the canal, also the greater thickness of its lateral portions. The prostate gland consists of several follicles or acini closely connected to each other, and covered externally by the capsule, and internally by the mucous membrane; a reddish, filamentous tissue also pervades it, which appears of a fleshy nature, and continuous with the muscular fibres of the bladder; these follicles open by several small ducts, ten or twelve on the lower surface of the urethra, in two lateral depressions, called prostatic sinuses, on either side of the verumontanum; some small ducts also open on the upper surface of the canal; a white, brownish, viscid fluid can be squeezed from these small openings; the contraction of the bladder and of its sphincter, with that of the levatores ani muscles, no doubt express this fluid from the gland to lubricate the urethral canal. The prostate is absent in the female, and small and tender in the male, previous to puberty.

The *Penis* is situated in front, and connected to the symphysis pubis; is divided into its root or roots, body, and extremity or glans; the two latter are covered by the integuments and partly by superficial fascia; the skin, thin and loose, is continued from the abdomen and scrotum around this organ, and extends some way beyond it in the form of a loose sheath, the *prepuce*, from the extremity of which it is inflected as far as the corona glandis, where it becomes very thin; is thence continued over the glans to the orifice of the urethra, and is continuous with its lining membrane; inferior to this opening it forms a triangular fold, the frænum preputii; the sides of the prepuce are

connected together by a very loose reticular tissue, and this fold is expanded and obliterated when drawn back, or when the penis becomes distended; the inner side of the prepuce is like mucous membrane, and of more delicate texture than the external, and that portion of it which is continued over the glans is still more delicate than either. Beneath the skin, around the corona glandis, are a number of small sebaceous glands, glandulæ odoriferæ, or Tysoni; the subcutaneous tissue, both of the prepuce and penis, is very loose, is continuous with and similar to the dartos; it is never the seat of adipose deposit, but is liable to serous infiltration; the orifice of the prepuce is sometimes, particularly in young persons, so contracted that the skin cannot be retracted so as to allow the escape or protrusion of the glans; this is termed "phymosis," and, if in this condition the skin be forcibly drawn back over the base of the glans, it sometimes cannot be returned, but forms a tense constriction or strangulation round the latter; this is termed "paraphymosis." The superficial fascia which covers the penis is continued from that of the abdomen, and extends around the penis as far as the corona glandis; it is thick and strong posteriorly, where it is reflected from the linea alba on the penis, so as to form the superficial suspensory ligament of the latter; it often contains some yellow, elastic tissue; anteriorly it is loose and delicate.

The *crura*, or *corpora cavernosa penis*, are two long, semi-cylindrical bodies, composed of a strong, elastic, tendinous, and fibrous substance, forming a sort of tube, filled with a soft cellular or *erectile tissue*, through which a large artery and many small tortuous veins, with free cellular inosculations, run from one end to the other. Each crus commences narrow in front of the tuber ischii, and adheres most intimately to the rami of the ischium and pubis, as far forwards as the symphysis; anterior to this the two crura become inseparably united, and continue so as far as the corona glandis, forming the body of the penis; here they end in one obtuse point, over which the glans penis, which is the expanded extremity of the corpus spongiosum urethræ, is folded, but with which it has little or no vascular communication: the crura are attached to the symphysis by the *true suspensory ligament*, which is very strong, of a triangular figure, yellow, and elastic; it arises from the symphysis, and is inserted into each crus; it consists of two laminæ, between which the dorsal vessels and nerves of the penis pass. The crura are separated from each other by an imperfect tendinous septum, composed of parallel fibres, with such intervals between them that the cavity of one crus communicates with and can be injected from that of the other; this septum is named *pectiniforme;* it is more perfect behind, but so deficient in front that the two crura may be regarded as one; a number of fibrous cords (*trabeculæ*) also cross the interior of each; these chiefly arise from the inferior surface, and thence radiate in different directions, and are inserted into the inside of each sheath; both these and the septum must impart considerable strength to the organ, and limit its distension. The crura penis are somewhat conical, the apex of each being attached to the

ischium and pubis, the base supporting the glans; they are round externally, flattened towards each other; a wide and deep groove exists between them inferiorly, which contains the urethra and its corpus spongiosum, and a more superficial one superiorly, in which the dorsal vessels and nerves of the penis run. The erection of the penis during life is caused by a greater quantity of blood than usually circulates through this organ being propelled by an increased action of the arteries into the small vessels of the corpora cavernosa penis, induced by a peculiar excitement of the nervous energy. Anatomists are not agreed as to the exact structure of the corpora cavernosa, or as to the proximate cause of their erection during life, or how the blood is circumstanced during that condition: some consider that the arteries pour their blood into the cells of the cellular tissue which surrounds them, so as to cause their distension, and that from these the blood is slowly and gradually absorbed by the veins; others conceive that the arteries directly communicate with the veins, and that these latter vessels are tortuous and coiled to such a degree, their coils communicating by lateral openings, as to form the plexuses which serve to retard the course and delay the return of the blood, and so cause the distension and consequent erection of the whole organ. The contraction of the dartos, and of the special muscles alluded to (at page 310), have been also supposed to contribute to this condition. The penis is supplied with blood from the terminal branches of the pudic artery; opposite the ramus of the ischium arises the artery of the bulb, enclosed in the triangular ligament; it ramifies in the corpus spongiosum urethra as far as the glans; the pudic then ends in the arteriœ dorsalis penis and cavernosa; the dorsal passes between the crura and the arch of the pubis, and between the laminæ of the suspensory ligament; it then runs tortuously forwards near the median line, ends in several preputial branches, and in some deeper ones, which form a free circular inosculation around the corona glandis, and also communicate with branches in the glans and corpus spongiosum urethræ. The arteria cavernosa enters the crus near its origin, and proceeds tortuously through it, near the septum, giving off numerous small branches in its course; these are entwined among the ramifications of the venous plexus, with which they communicate freely. Muller has described small vessels, "arteriæ helecinæ," as arising from this artery, and projecting in tufts from each side of it into the venous cells: this opinion has not been confirmed by subsequent observation. The veins of the penis are large and numerous, and supplied with valves; they are deep and superficial, the former accompany the branches and the trunk of the pudic artery, and join the internal iliac; the superficial commence in the prepuce, pass backwards, receiving branches from its sides and inferior surface, and form the two dorsal veins of the penis; these pass beneath the arch of the pubis through fibrous canals connected to the sub-pubic ligament: these canals, like the sinuses of the dura mater, serve to keep the veins open and free from pressure; they open into the prostatic and vesical plexuses. The nerves of the penis

are derived from the sympathetic and pudic branches of the spinal. Each of these strong fibrous cylinders is filled with an areolar or cellulo-vascular tissue, which is strengthened by the trabeculæ, and which itself is chiefly composed of an interlacement of veins: the cells communicate freely with each other and with the veins. There appears to be in erectile tissue a gradation of structure between true veins and venous plexus; thus at first we find the veins communicating, as it were, by lateral perforations; these become more numerous, distinct vessels disappear, and a mass of communicating cells alone can be detected; these cells appear formed of the prolonged lining membrane of the veins; the interstices of this plexus are filled with a peculiar fibrous texture, of a reddish appearance, and bearing some resemblance to muscular tissue.

The *Urethra* is a membranous canal, about nine inches long, extending from the neck of the bladder to the extremity of the penis, formed of mucous membrane, covered by an elastic coat; the former is continuous posteriorly with that of the bladder, anteriorly with the thin integument of the glans, and in different situations with the lining membrane of the ducts that open on its surface, namely, the prostatic, ejaculatory, Cowper's, and numerous lacunæ. The elastic coat differs in strength in different situations, and is covered at first by the prostate gland; this portion of the canal is called the *prostatic portion* of the urethra; next by the compressores urethræ muscles, the triangular ligament, and a peculiar reddish, spongy, or erectile tissue, which contains several small blood-vessels, chiefly veins; this is called the *membranous portion;* it is separated from the subpubic ligament by some considerable veins, and from the rectum by the small triangular space, recto-bulbar, already described. The remainder of the canal is covered by a cellulo-vascular substance of a dark red or purple colour, named corpus spongiosum urethræ, which commences in the bulb, and ends in the glans penis; this portion is named the *spongy portion.* The course or direction of the urethra should be first attended to; from the neck of the bladder it passes downwards and forwards; having arrived opposite the symphysis pubis, it describes a very slight curve, concave upwards; it then rises on a higher level than the bulb in front of the pubes, and enters the groove on the lower surface of the corpora cavernosa penis; the remainder of its course depends on the state of the penis; if the latter be collapsed, it forms a marked curve, concave downwards, but this can be changed into nearly a straight line by elongating the penis, and during the erection of the organ it becomes concave upwards, so that in this condition of the penis the whole canal forms but one curve in that direction, but in the collapsed state it forms two curves, somewhat like the letter S, with the posterior curve less sharp or acute. The first, or the prostatic portion, is within the pelvis, about an inch and quarter or an inch and a half in length; in the erect position of the body its direction is downwards and forwards, is nearer to the upper than to the lower surface of the gland. The membranous portion is about half or three-quarters of an inch long,

and is the narrowest part of the canal except the anterior orifice; it is described in general as being concave towards the pubes: it is, however, but very slightly so; it is nearly horizontal, about three quarters of an inch below the symphysis pubes; it is surrounded by an elastic and erectile tissue, also by the deep lamina of the triangular ligament, and by the compressores urethræ muscles. The spongy portion commences in the bulb in front of the triangular ligament, extends to the extremity of the canal, and ends in the glans penis. The *corpus spongiosum urethræ* consists of a fine erectile tissue, through which an artery from each side (a branch from the internal pudic) extends; these vessels send off numerous branches, which pour their blood into the surrounding venous cells; the bulb and the glans are expansions of this texture, the former on the inferior, the latter on the superior part and sides; it is invested by a fine but strong and semi-transparent aponeurosis, very different from that which covers the corpora cavernosa; it surrounds the urethra, but is thicker inferiorly and laterally than superiorly. The *bulb* occupies the space between the crura penis, is opposite the arch of the pubis, in front of the rectum and below the level of the membranous portion of the urethra, and about an inch distant from the anus; it terminates gradually in front, in the corpus spongiosum; it is embraced by the acceleratores urinæ muscles, and immediately covered and supported by the anterior or inferior lamina of the triangular ligament; on each side, and rather posteriorly, are the glands of Cowper, between the laminæ of the triangular ligament, and immediately beneath the arteries of the bulb; the bulb is very small in the child. The *glans* is the anterior conical enlargement of the penis, of the same structure as the bulb, only more dense; its base projects beyond the crura superiorly and laterally, and forms the corona glandis, and is cut off obliquely, so that its upper surface is twice as long as its lower; the prepuce is connected to it inferiorly by the frænum. There is no direct communication between the corpus spongiosum urethræ and the corpora cavernosa penis; the one can, therefore, be distended with air or injection without the other, or both may be injected with different coloured fluids. In order to inject the crura penis, make a small opening in each crus near its attachment to the ischium, insert a pipe into one of these, and force warm water through it; this will soon escape through the opening in the opposite crus, carrying along with it the blood which was contained in the cells; then secure with a ligature the opposite crus, and inject some coloured fluid. To prepare the corpus spongiosum urethræ, make a small opening in the substance of the bulb; next open the dorsal vein of the penis; in it secure a small pipe; water injected through this will escape at the opening in the bulb; when all the blood shall have been thus washed out, the latter opening may be secured, and some coloured fluid injected along the dorsal vein; if, however, a fine injection be forced from the pudic, or from the internal iliac artery, it will occasionally succeed in distending the corpora cavernosa penis and the corpus spongiosum urethræ at one and the same time. The student may

now detach the crura penis and the neck of the bladder from the pubes, and remove these organs, together with the urethra, from the subject; continue an incision from the anterior part of the bladder through the upper part of the prostate gland, and of the urethra to its extremity; the mucous lining of the urethra will be thus exposed; the difference in the diameter and other peculiarities in different parts of it may now also be observed. 1st. The prostatic portion is somewhat contracted at either extremity, and dilated in the centre, particularly on the lower surface, and at either side of the middle line. These enlargements are called the *prostatic sinuses;* they are separated from each other by a prominent fold of the lining membrane, extending from the uvula of the bladder, along the mesial line of the urethra, as far as the bulb. This fold is named *verumontanum*, or caput gallinaginis: in the centre of it is a very large lacuna (*sinus pocularis*), the orifice of which is directed forwards; on either side of this pouch, and in general external to it, is the opening of the common ejaculatory duct, external to which, and in the prostatic sinus on each side, are the several small orifices of the ducts of the prostate gland. In the closed state of the urethra, the uvula and verumontanum are pressed against the upper part of the canal, and the whole ring is closed by the sphincter vesicæ, but when the bladder contracts, this ring is expanded by the longitudinal fibres, and the verumontanum is depressed by some of the posterior fibres which are inserted beneath it; the prostatic portion of the urethra is then considerably dilated. The opening of the sinus pocularis, usually not larger than a pin's head, is sometimes much more so, and may admit and obstruct a bougie or catheter in its course to the bladder 2nd. The membranous portion is shorter, and of a smaller calibre, than the prostatic; it is cylindrical; its anterior extremity is the narrowest portion of the canal. 3rd. The spongy portion of the urethra is much dilated at first, particularly inferiorly (*sinus of the bulb*); anterior to this the small ducts of the anti-prostatic glands open. The canal contracts a little beyond the bulb, and continues of nearly the same diameter until it arrives opposite the scrotum; it is there slightly contracted for a short distance: about an inch posterior to the external orifice of the urethra the canal is dilated in the transverse direction; this dilatation is called the *fossa navicularis.* Lastly, the orifice of the urethra is contracted into a narrow vertical slit. Several small lacunæ open on the surface of the mucous membrane of the urethra, between the bulb and the anterior extremity; they are said by some to be most numerous on the upper surface; they are very variable in number and size; the orifices of these, in a healthy condition of the membrane, are very small; they are all directed forwards. If bristles be introduced into some of these ducts, they will be found in many cases to extend backwards for near an inch in the submucous tissue: these lacunæ secrete a thin mucous fluid, which is expelled by the urine in its passage along the urethra. In chronic diseases of the urethra, these ducts not unfrequently become so much enlarged as to admit the end of a small

bougie, and so lead to the formation of a false passage: the largest lacunæ are on the upper surface of the urethra; one in particular, near the fossa navicularis, is named the *lacuna magna.** This membrane is very extensible as well as dilatable, hence neither its length nor its diameter can be accurately stated; it presents many longitudinal folds which admit of distension; through it appear irregular longitudinal fibres, probably elastic, but by some supposed to be muscular: there is no regular arrangement of circular fibres. The epidermic character of this membrane is most distinct in its anterior portion. If the urethra be distended with spirit, and the crura penis and corpus spongiosum carefully dissected off, a beautiful preparation of this semi-transparent canal may be obtained.

The testicle is the seat of many *morbid* appearances, both in its tunics and in its substance; hydrocele is very common; this is a dropsy in the serous cavity of the tunica vaginalis; this latter membrane may be inflamed, and the adhesive process may obliterate its cavity. The tunica albuginea is sometimes the seat of a firm fungus, which protrudes through the other coverings to the surface. The testicle and epididymis may be the seat of acute inflammation or orchitis, as in hernia humoralis, the effect of gonorrhœa, also of chronic inflammation, with indolent enlargement, or sarcocele. The testis is also the frequent seat of strumous inflammation and suppuration, of fungoid disease in which there is great enlargement, total change of structure, and conversion into cerebriform matter; of true scirrhus and cancer, of hydatid tumours, &c.: these glands are also sometimes atrophied. The spermatic cord is sometimes the seat of encysted hydrocele, of varicocele, particularly on the left side, as also of different tumours.

The prostate gland is seldom found *diseased*, except in old men; it is rarely inflamed; an abscess, however, has been met with (unaccompanied by any thickening) in its substance, arising from common inflammation. *Scirrhus.*—The most common disease of the prostate gland is scirrhus; the gland in its natural state is known to be about the size of a chesnut, but when affected with scirrhus, it is often enlarged to the size of the fist. The common appearances observed in scirrhus in other parts of the body can be plainly seen in this

* During the dissection of the pelvic viscera, perinæum, &c., the student should frequently practise the introduction of a catheter into the bladder, which is to be done in the following manner: the subject lying on its back with the legs drawn up, the penis should be held by placing the thumb and index-finger on each side of the corona glandis, by which means the orifice of the urethra will not be compressed; the penis is then to be drawn upwards, and the catheter, being previously oiled, is next to be introduced in a line with the linea alba into the urethra, directly downwards as far as the bulb; the concavity of the instrument being towards the abdomen. The catheter having reached the bulb, its handle is to be depressed by bringing it forwards between the thighs, and in proportion as this is done the point is elevated, and the catheter glides into the bladder; in this latter part of the operation, the penis must be allowed to sink down, for if it be kept extended on the instrument the membranous part of the urethra will be drawn towards the pubes, by which means the introduction of the instrument will be rendered difficult.

gland; when cut into, it appears to consist of a very solid, whitish, or brown substance, with membranous septa running through it in various directions. According to the degree of enlargement that takes place, the urine is passed from the bladder, or the catheter can be introduced to draw it off, with greater or less difficulty. *Calculi* have been found lodged in the ducts of the prostate gland; they are usually small granules of a dark colour, and give it a mottled appearance when cut into.

The vesiculæ seminales are seldom found *diseased;* in case of scrofulous disease of the testicle they have been found similarly affected and filled with cheesy fluid. The urethra is the frequent seat of inflammation, which, when recent, produces suppuration without ulceration, and, if long continued, causes a thickening of the submucous tissue, and thus renders the canal narrow and irregular, and so commences the foundation of stricture. Chancres have been found in it even so far back as the membranous portion, and at the orifice (generally at the lower side) they are by no means uncommon; a chancre in this situation being, according to M. Ricord, the real cause of the peculiar characters of gonorrhœa virulenta. The coverings of the penis are the frequent seat of ulceration, also those of the glans penis; the latter in old persons are very often attacked with warty, cancerous ulceration.

# CHAPTER VII.

## DISSECTION OF THE FEMALE ORGANS OF GENERATION.

THE generative organs in the female are more distinct from the urinary than in the male; they may be divided into the external and internal: the *external parts* are the mons veneris, vulva, labia, clitoris, nymphæ, vagina, and perinæum.

The *mons veneris* is an eminence placed on the upper and anterior part of the pubes; it consists of a quantity of adipose substance beneath the integuments, which in the adult are covered with hair. The *vulva* is the fissure, or common urino-sexual opening between the labia, extending from the mons veneris to within an inch of the anus. The anterior *perinæum* is the small space in front of the anus. The posterior *perinæum* is between the anus and the os coccygis. The *labia externa* or *majora* are the prominent folds of integument which extend from the mons veneris, one on each side of the vulva, thicker before than behind, and are united inferiorly in a crescentic edge, called the commissure or fourchette, between which and the vagina is a small depression, called fossa navicularis; the labia are composed of fat and loose areolar tissue, with numerous sebaceous glands and hair bulbs, vessels, and nerves; beneath the skin and mucous surface is a dartoid texture like that in the scrotum; they are liable to serous infiltration; during parturition they are unfolded, and admit of the expansion of the vulva; in the infant they are less developed than the following. The *nymphæ*, or labia minora, descend one on each side of the vagina, from the prepuce of the clitoris, and are gradually lost about the centre of the vulva, on the sides of the vaginal opening; they are folds of mucous membrane enclosing an erectile tissue, and are covered by a fine epithelium, and have numerous and distinct sebaceous follicles; they are narrow behind, broad before, and bifurcate at the clitoris; the lower division joins the glans clitoridis, the upper unites with that from the opposite in a hood-like fold, called the prepuce of the clitoris; variable as to size; in some very small, in others very large and prominent, and in some nations hypertrophied and elongated to an extreme degree; in the infant they are more developed in proportion than the labia, and usually project beyond them. The *clitoris* is in the median line, about half an inch below the superior angle or commissure of the labia: it is a small red projection immediately beneath the symphysis pubis and above the vagina; attached by two crura to the rami of the ischii and pubes; these unite and form the body of the clitoris, opposite the symphysis, to which it is connected

by a suspensory ligament; it then passes forwards, like a ridge, between the labia from their anterior commissure to its extremity, a little curved, convex upwards, concave downwards and backwards, and terminates in a round, red swelling or tubercle, which, from a resemblance to the glans penis, is named glans clitoridis, and is covered by the thin, loose fold of the integument or mucous membrane, called the prepuce, derived from the upper division of the nymphæ. The crura clitoridis are composed internally of a spongy cellular texture, not very unlike the corpora cavernosa, or the corpus spongiosum urethræ in the male; each crus is invested with an erector or compressor muscle analogous to the erector penis; the urethra is received in the angle between the two crura, and, passing forwards beneath the body, ends behind the glans; the whole organ is erectile, being composed of spongy, erectile tissue enclosed in a fibrous sheath: like the nymphæ, it is large in the infant; in the adult its size is variable; in some it is hypertrophied and elongated to the extent of one, and even two inches.

About half an inch below and a little behind the clitoris, between the nymphæ, and immediately above the projecting edge of the vaginal opening, is the round orifice of the *meatus urinarius;* this opening always appears closed, is surrounded by a projecting fold of mucous membrane, on the sides of which are orifices of small mucous glands analogous to Cowper's glands in the male, although probably the true analogues to these bodies are those two organs to which attention has been recently directed by M. Huguier, in a memoir read before the Academy of Medicine of Paris, and which are named the *vulvo-vaginal glands.* These were first described by G. Bartholinus, and have been noticed by the older writers, but no mention is made of them by modern authors. These glands are seated one at each side of and a little behind the vaginal orifice, in size and appearance like an apricot-stone covered with its epidermis; their excretory ducts, about half an inch long, open near the margin of the hymen at the base of the lateral and posterior caruncles, by which they are usually concealed: like the other parts of the generative apparatus, these become much developed at puberty; they pour out a copious supply of clear, transparent mucus, which M. H. states can, under peculiar excitement, be ejected by the involuntary contraction of the surrounding muscles. These glands and their ducts are very variable as to size, and, like the clitoris and adjacent surface, possess peculiar sensibility; their atrophy and hypertrophy bear a proportion to the condition of the ovaries; hence attention to their condition may assist in the diagnosis of disease: during pregnancy they are diminished, and in old age are atrophied; they are occasionally absent; in structure, and in situation, also in pouring forth their secretion on the common urino-sexual surface, they have some analogy to Cowper's, or the anti-prostatic glands. Immediately behind and a little below, but partly surrounding this opening, and from this descending on each side of the vagina, is an elevation of the latter by an erectile tissue, somewhat

analogous to the bulb or spongy portion in the male. The meatus is about an inch and a half in length, leads backwards and upwards in the upper wall of the vagina, to which it adheres almost inseparably, is slightly curved beneath the symphysis pubis, to which, as also to the crura of the clitoris, it is attached by the triangular ligament and pelvic fascia, or rather by the anterior ligaments of the bladder; between its upper surface and the latter is a venous plexus; this canal is composed of mucous membrane continued from the bladder, surrounded by an elastic, erectile, and muscular tissue; this membrane is of a deep red colour, and presents longitudinal plicæ, which account for its great dilatability; longitudinal veins appear through it, and several lacunæ open upon it; its elastic and erectile tissue retains it in a closed state; the longitudinal fibres of the bladder can be traced through the cervix into the latter, and probably assist in the expansion of this canal when contracting the reservoir; it perforates the triangular ligament of the urethra in the same manner as the membranous portion does in the male, to which division of the canal in the latter the female urethra is somewhat analogous. The compressores urethræ muscles, both vertical and transverse, are similarly arranged; the vesical opening has no encircling prostate gland; the anterior orifice is a little constricted by a surrounding fibrous band, which resists dilatation as in the male, but it has not the same form.

The orifice of the *vagina* is directly below that of the urethra, is somewhat oval, with a projecting and rather corrugated margin; in the virgin it is partially closed in front by a crescentic fold of membrane, termed the *hymen;* concave forwards, only leaving the anterior superior part of the orifice free; very variable, however, it is sometimes circular, with an opening in the centre; its loose edge is usually fringed; it is sometimes only rudimental, and on the other hand it is sometimes complete, and is then called imperforate hymen, a condition attended with danger, as it confines the menstrual secretion: it is a fold of mucous membrane enclosing some small vessels. After laceration the margin presents an irregular series of reddish, fringe-like processes, named the *carunculæ myrtiformes;* these are variable in number and size. The course and connexions of the vagina will be better seen when the pelvis shall have been divided for the purpose of examining the internal organs of generation. Dissect off the integuments and fascia from the perinæum and labia, and the following muscles may be observed: the *sphincter ani*, *levatores ani*, *coccygæi*, and *transversales perinæi*, are similar to the muscles of the same name in the male; the middle fibres of the levatores ani are expanded on the sides of the vagina: the *erectores clitoridis* are analogous to the compressores penis; and the *sphincter vaginæ* corresponds to the acceleratores urinæ; it extends from the clitoris superiorly around each side of the vagina to the central point of the perinæum in front of the anus; it may be described as double, each *arising* in common from this point, then, passing forwards as a flat band on the side of the vagina, is *inserted* by a tendinous expansion partly into the side of the clitoris and partly into its upper

surface and suspensory ligament, in conjunction with that from the other side; it contracts the orifice of the vagina, which is the narrowest part of the canal.

*Fig. 56.**

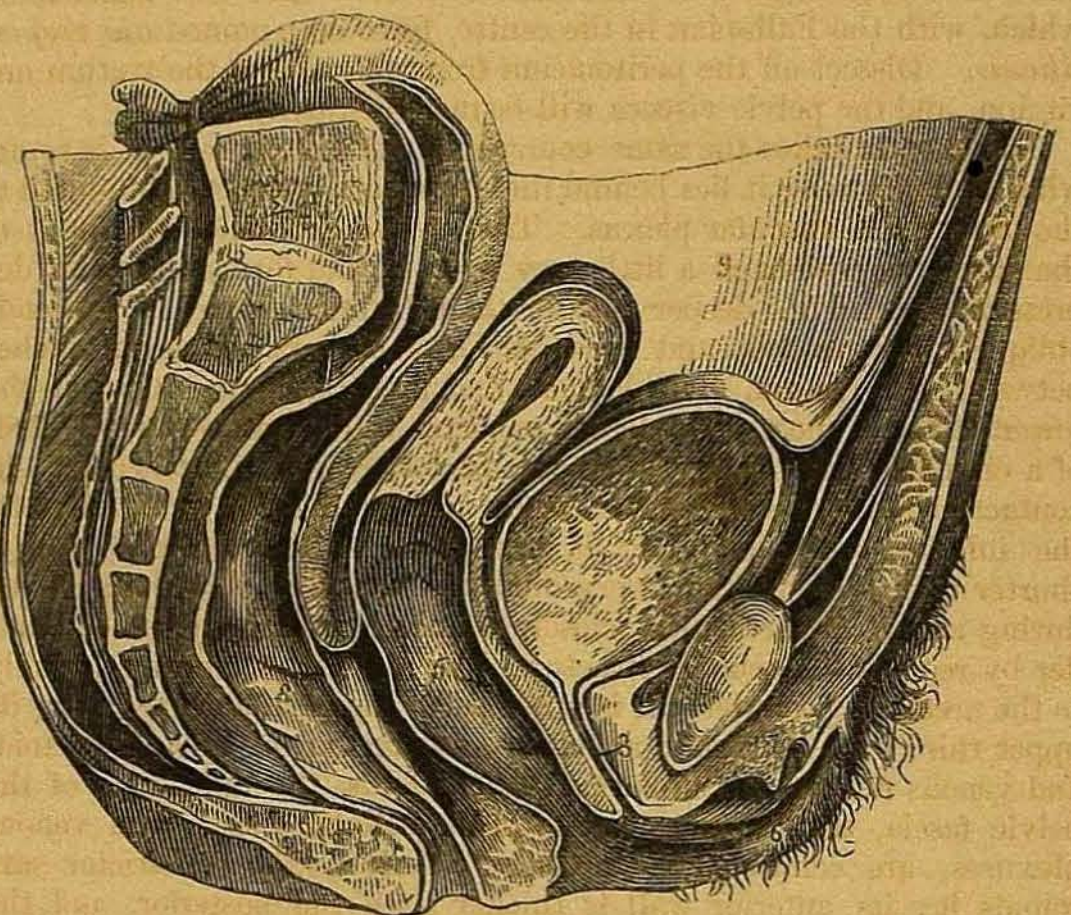

Make the lateral section of the pelvis in the same manner as was directed in the dissection of the male pelvis (page 318). The peritonæum may be first examined; this will be seen to descend along the forepart of the rectum to within three or four inches of the anus; is thence reflected forwards on the posterior part of the vagina, the superior third of which it covers; ascends on the posterior surface and sides of the uterus; continues round the superior fundus of this organ to its anterior part, on which it descends as low as the cervix only, and has, therefore, no connexion to the vagina in front; it is thence reflected to the bladder, and continued over this organ, as in the male, to the abdominal muscles; thus, in the female pelvis, the peritonæum forms one *cul de sac*, which is deep, between the rectum and vagina, and another between the uterus and bladder, which is shallow. From each side of the uterus a broad fold of peritonæum is ex-

* An antero-posterior section of the pelvis of a female, giving a lateral view of the viscera *in situ*. 1. The symphysis pubis. 2. The urinary bladder. 3. The urethra. 4. The uterus. 5. The vagina. 6. The labia pudendi. 7. The clitoris. 8. The rectum. 9. The periætonum reflected over the bladder, uterus, and rectum.

tended transversely towards each iliac fossa; these are the *broad ligaments* of the uterus; enclosed superiorly between the laminæ of each are the *Fallopian tube* in the centre, *the round ligament* of the uterus in front, and the *ovarium* with its ligament and vessels behind; the ovary and round ligament raise the membrane into two lesser folds, which, with the Fallopian in the centre, have been named *alæ vespertilionis.* Dissect off the peritonæum from one side of the rectum and vagina, and the pelvic viscera will be more distinctly seen.

The *rectum* takes the same course as in the male, only it is somewhat more curved; it lies behind the uterus and vagina, and united to the latter by a vascular plexus. The *vagina* surrounds the neck of the uterus, is prolonged a little way upon it, and forms a circular depression around it, deeper behind than before; thence it descends obliquely downwards and forwards for about six or seven inches between the rectum, the bladder, and urethra, in the axis of the lower orifice of the pelvis, slightly concave before and convex behind, of a circular form, the anterior and posterior walls flattened and in contact; the uterine end is the largest part, and often much dilated; the inferior orifice or vulva is the smallest; the anterior wall is shorter than the posterior; very dilatable and very elastic, as is seen during and after parturition, closely connected anteriorly to the bladder by reddish filamentous structure, like the dartos, and inseparably to the urethra; posteriorly it is attached to the peritonæum during its upper third; the remainder adheres to the rectum by a loose, dartoid, and venous tissue; the broad peritonæal folds, the reflections of the pelvic fascia, the levatores ani muscles, cellular tissue, and venous plexuses, are connected to its sides; inferiorly the constrictor surrounds it; its anterior wall is thicker than the posterior, and the urethral portion is the most so; lined by a vascular mucous membrane, which is transversely rugose. These rugæ are very distinct in the infant, they are not like the ordinary plicæ of mucous membranes, to admit of distension, but firm ridges like those on the palate behind the anterior teeth; they are seen on the upper and lower surfaces, but chiefly on the former, and near the vulva. In the median line, on each surface, is a more prominent ridge or raphe, extending nearly the whole length; these lines are called the columns of the vagina. This membrane is covered with a distinct epithelium of the squamous or cuticular kind; it extends into the uterus, but there becomes of a different nature; it is furnished with numerous follicles and papillæ, especially near the vulva; the mucous membrane is covered by a dense fibrous tissue and by numerous vessels, particularly veins, which form a retiform plexus, or a spongy erectile body, which is covered by a fibrous and dartoid tissue above, and by the sphincter vaginæ muscle below; there is an increase of this spongy tissue at either side of the orifice, between it and the crura of the clitoris. Between the bladder and the vagina the *ureter* may be observed, connected to the upper and lateral part of the latter; its course is longer and more curved in the female pelvis than in the male; its vesical extremity

corresponds to the cervix uteri; its entrance into the bladder is nearer the uvula than in the male, and the trigone is of greater transverse, but of less antero-posterior extent. The peculiarities of the female bladder have been already noticed.

The *Uterus* is situated in the pelvis, between the bladder and rectum, connected to both by peritonæum, and fixed thereby in its situation, as also by its broad and round ligaments, and by the vagina; it enjoys, however, a certain degree of mobility; it occupies the median line, but often inclines to one side, especially the left, and is more or less in contact with the convolutions of the small intestines. The uterus is of a flattened pyriform or triangular shape; the larger end or fundus is superior and anterior; the smaller end or cervix inferior and posterior; the intermediate portion is named the body, and is separated from the neck by a constricted line; the vagina surrounds the cervix uteri, and ascends higher posteriorly than anteriorly; about three inches long, one inch thick, and two broad at its fundus, this and the body equal two inches in length and the cervix one; at the lower extremity of the cervix is a small transverse slit, the *os uteri* or *os tincæ;* the long axis of the uterus leads obliquely backwards and downwards in the same line as that of the upper orifice of the pelvis, and forms an angle, concave forwards, with the axis of the vagina, which leads obliquely forwards and downwards in the line of that of the lower orifice. The anterior surface is flattened, and covered by the peritonæum in its upper three-fourths; the lower fourth is connected to the inferior surface of the bladder by cellular tissue: the posterior surface is more convex, and is entirely covered by peritonæum: the sides are slightly concave, and give attachment to the broad, round, and ovarian ligaments, and to the Fallopian tubes. The *broad ligaments* are the two peritonæal folds which extend to the iliac fossæ, and form with this organ a transverse septum in the pelvis, between the bladder and rectum. The *round ligament* arises on each side anterior and inferior to the Fallopian tube, ascends obliquely outwards in the anterior fold of the broad ligament, passes through the internal ring into the inguinal or spermatic canal, accompanied by a close sheath of peritonæum (canal of Nuck), escapes through the external ring, and is lost in the cellular tissue of the mons and labium externum; is composed of muscular and fibrous tissue derived from the uterus, together with small, tortuous arteries, a venous plexus and filaments from the spermatic nervous plexus; these ligaments retain the uterus in the median line, and, when it becomes enlarged, support it anteriorly, and draw it towards the abdominal muscles; the veins in these cords are not unfrequently in a varicose state; the arteries maintain a communication between those of the uterus and the groin. The *ovarian ligament* is a round, fibro-muscular cord, from an inch and a half to two inches long, arising from the upper and lateral angle of the uterus, below and behind the Fallopian tube, and inserted into the inner end of the ovary. The *Fallopian* tubes extend from the upper angles of the uterus towards each side of the pelvis. The *supe-*

*rior end* or *fundus* is convex, and directed upwards and forwards; it is behind the bladder, and below the level of the pubes. The *lower end*, or *cervix*, presents the os uteri or tincæ at its termination, looks backwards and downwards, is embraced by and projects into the vagina. The *os* is small and circular, and the lips or borders smooth, in the virgin, but in those who have borne children it becomes larger and more transverse, and the edges slightly fissured or wrinkled; it presents two lips, one is anterior or superior, and thicker than the other, which is posterior or inferior, and longer. The parietes of the uterus are nearly a quarter of an inch thick; its cavity, therefore, is very small, the surfaces nearly in contact, mucus only interposed; the area in the body and fundus is somewhat triangular, the base above. The cervical portion is cylindrical and flattened, communicates with the vagina by the os uteri or tincæ, or *ostium externum*, above which the canal through the cervix is narrowed, and leads into the body of the uterus by a very constricted opening, the *ostium internum*. The triangular cavity in the uterus then commences; the apex is in this opening, the base in the fundus, each angle of which is depressed into a funnel-shaped recess, in the bottom of each of which is the very minute orifice of the Fallopian tube. The uterus, being the organ for the gestation of the embryo during the long period between its conception and the completion of its maturity, and also the principal agent in its final expulsion from the body of the parent, possesses very peculiar organization, and is endowed with peculiar and interesting powers. It is composed of three different tissues or tunics, a serous, a fibrous or fibro-muscular, and a mucous; it is furnished with nerves and vessels, which are small in the quiescent state of the organ, but which become wonderfully developed during uterine gestation; it possesses very little of the areolar, and none of the adipose tissue, except the thin, connecting lamina between its peritonæal and muscular tunics. The first or *serous coat* invests the fundus and body, all the posterior, and the three upper fourths of the anterior surface; on each side of the anterior *cul de sac*, between the uterus and bladder, it forms a semi-lunar fold, named *vesico-uterine ligaments*, and in like manner its reflection from the vagina to the rectum presents, on either side of the posterior *cul de sac*, a semi-lunar fold, named *recto-uterine ligaments;* it adheres closely to the fundus and surfaces, but loosely to the sides, and, as the organ enlarges, the lateral duplicatures or broad ligaments unfold and expand, and thus materially contribute to a corresponding extension of the serous investment. This coat answers the same *uses* as on other hollow viscera; when the womb is distended, it supports and strengthens its other tissues, it insulates it from surrounding parts, and mutually facilitates its motions and those of the adjacent organs. The *mucous membrane* is in general pale, though sometimes very dark; it is smooth, and furnished with an epithelium, which is columnar and ciliated. In the cervix it presents longitudinal median lines or columns, from which

pass off, at nearly right angles, smaller transverse rugæ, like branches of a tree. This appearance, named arbor vitæ uterina, is more perfect in the virgin state: in this region of the uterus in particular are many mucous follicles, the closure and distension of which give rise to a vesicular, and sometimes even a morbid appearance (ovula of Naboth); the membrane is smoother and more vascular in the body than in the cervix; this difference has been well observed in those who have died during the menstrual period; under ordinary circumstances this membrane is very fine and delicate, and so difficult of demonstration that some have even (but erroneously) denied its existence; it is continuous inferiorly with that of the vagina, and superiorly it extends through the Fallopian tubes and their fimbriated extremities, where it is continuous with the peritonæum on each side, thus presenting the single example of continuity between a mucous and serous membrane.

The *middle* or *muscular coat* is very thick and firm, and resists the knife like cartilage; composed of strong, greyish fibres, closely interwoven and traversed by numerous vessels. The true nature of this structure could not be known if our observations were confined to the unimpregnated human uterus; examination, however, of this organ, when pregnant, aided by the microscope, corroborated by chemical analysis, and elucidated by comparative anatomy, have revealed its true character to be muscular tissue; this, in the quiescent state of the organ, is condensed, and, as it were, atrophied, but, when impregnated, the parietes become wonderfully vascular, the fibres softened and unravelled, the sensibility and nervous energy proportionably exalted, and the muscular structure is then developed in an eminent degree; the muscular fasciculi become evident, and are expanded into extended laminæ, whose fibres interlace in the same manner as those of the involuntary system, or of organic life in general; like the fibres of the latter, also, they want the transverse striæ. Around the cervix they are in circular laminæ, some fibres interlacing or crossing others; on the body and fundus the fasciculi are large, and flat bands disposed in a superficial and deep lamina; the superficial are longitudinal or vertical on the front and back part, and oblique on the sides and fundus, and at the angles of the latter are continued on the Fallopian tubes and on the round and ovarian ligaments; the deep layer consists of two series of conical fibres, the apices around the Fallopian tubes, the bases intermingling on the body of the uterus. This tunic of the uterus is truly interesting from the very curious changes it can undergo; thus through the greater portion, and often through the entire period of life, it remains inactive, and condensed into a thick, close, and almost solid, whitish, homogeneous mass, without a single feature in common with contractile tissue; with this contrast its plainly muscular appearance in the gravid uterus, when its fibres admit of a passive extension and elongation to an almost unlimited extent, while at the same time they present all the characters of highly developed muscle, except the manifestation of the contractile

power, which it refrains from exercising with any vigour until the period of parturition, at which hour it displays this power with extraordinary energy and with wonderful intensity and force. During pregnancy the vascular system also of the uterine parietes is equally developed; the *uterine arteries*, which are derived from the internal iliac, and the *spermatic* from the aorta, become enlarged, elongated, and tortuous. The *uterine veins* are still more remarkable; they form large channels (uterine sinuses), like the larger venæ cavæ hepaticæ, through the uterine walls, and appear formed only of the lining membrane which adheres to the surrounding fibrous tissue; these veins form plexuses at each side of the uterus, and open into the internal iliac, the renal, and the cava. The *nerves* of the uterus proceed from the hypogastric plexus, which consists of filaments from the sacral and lumbar and pelvic ganglions of the sympathetic; these nerves accompany the uterine arteries; others are derived from the renal plexus, and accompany the spermatic arteries; all these nerves are small in the unimpregnated organ, and difficult to follow, but, like the muscular and vascular tissues, they also become enlarged during pregnancy into a great system of nerves, whereby not only are its functions regulated, but a sympathy is also maintained with the entire system. These nerves have been described by Hunter and Tiedemann, and more recently and ably by Lee (Phil. Trans., 1842). The latter has described several nervous ganglia and plexuses in and about this organ, viz., the hypogastric ganglia, which are near the ureters on each side of the cervix, and which receive nerves from the hypogastric plexus, and supply the rectum, bladder, vagina, and uterus, with filaments which form minor ganglions, each named from their situation; the branches of the uterus ascend, and, meeting some from the spermatic plexus, form a large ganglion (spermatic), which supplies the fundus; the filaments from these several ganglia form a sort of nervous net-work over the entire organ. (*See* Nervous System). The more minute examination of the muscular, vascular, nervous, and mucous tissue in this organ, and of the changes which each undergoes in the several stages of pregnancy, are of great interest; this study belongs, however, to that of the anatomy of the gravid uterus, which does not properly come within the limits of the present work. In the embryo, and previous to the third month, the uterus is found developed as bifid or bicornate, a condition which is permanent in many animals; about the fourth month the two cornua have united to form a single cavity: the two funnel-like depressions in the superior angles, in which are the internal orifices of the Fallopian tubes, correspond with this original conformation. An imperfect septum may coexist with this bifid form, of which the two median lines, or raphes, in the vagina, may be regarded as rudiments. In the fœtus, at birth, the uterus is situated in the abdomen, and is very small; the cervix is longer in proportion than the body or fundus: as the pelvis is developed it gradually subsides into it, but undergoes little change or increase until

near puberty, when it rapidly attains its full dimensions and proper form; in old age it becomes atrophied, and is often inclined to one side, or turned backwards towards the rectum; a well-marked constriction then separates the neck and body, the latter becomes thin and softened, the former very dense, and the lips of the os are nearly effaced.

The *Fallopian tubes* or *oviducts* are two in number, one on each side, from four to five inches in length; they extend from the upper angles of the uterus to near the sides of the superior opening of the pelvis, at first straight upwards and outwards, then tortuously downwards and backwards, and a little inwards, loose and floating, supported by the broad ligaments, in the upper border of which they are enclosed behind the round and before and above the ovary and its ligament; its uterine half is small, but the external portion is nearly the size of a goose-quill; its calibre is very contracted throughout, and is like that of the vas deferens, to which this duct is also analogous in its firm, cord-like feel; it opens internally into the upper angle of the womb by a minute foramen, almost capillary (ostium uterinum); externally by a much larger opening into the peritonæal cavity (ostium abdominale); this extremity, named *corpus fimbriatum*, is expanded in a trumpet form; is soft, and irregularly fringed, or, as it were, lacerated; from this appearance, and from the manner in which it is supposed to seize the ovary during conception, the term *morsus diaboli* has been applied to it. The fringes surround the opening by one or two rows or borders; it partly overhangs the ovary, and is connected to it either by one of the fringes, or by a fibrous band, which serves to conduct the tube to that body. This conformation can be well seen when the tube is removed and floated in water; like the uterus, these are composed of three tunics: the external or serous, derived from the broad ligaments, is loose and easily detached; the middle or fibrous, or fibro-muscular, consists of two planes of fibres, external or longitudinal, and internal or circular; they are continuous with those of the uterus, and most probably of the same muscular character: the internal or mucous coat is continuous with that of the uterus internally, and with the peritonæum externally; it is soft and reddish, and thrown into longitudinal plicæ designed to admit of dilatation; its epithelium is columnar and ciliated; the external fimbriæ are chiefly composed of the mucous and serous tissues; the former is soft and vascular, the latter very thin; the fibrous coat is wanting, or nearly so; this extremity of the tube is dilatable, and much larger than the uterine portion. The Fallopian ducts are essential to reproduction; they transmit the fecundating principle of the male to the ovary, which they embrace, and then conduct the fecundated ovum into the uterus. The *ovaria*, or female testes, are two small oval bodies, white or pale red, flattened before and behind, one at each side, enclosed in the posterior fold of the ligament, behind the Fallopian tube, connected to the uterus by the broad ligament and by a round, fibrous cord, its proper ligament, which is about two inches long, is enclosed between the laminæ

of the broad ligament, and is attached to the inner end of the ovary and to the upper part of the side of the uterus, a little below its superior angle: to its outer extremity, also one of the fringed processes of the morsus diaboli, or a fibrous band, is attached; it is free before, behind, and above: it is composed of a cellulo-vascular tissue enclosed in three tunics, a serous, a fibrous, and a vascular; the serous invests the greater portion of it, and adheres most intimately to the fibrous coat, which is white, strong, and sclerotic; the vascular not only covers it, but is continued into it internally, and assists in forming its areolar tissue. In the cells of this vascular structure, or stroma, a number of small vesicles are developed (Graafian vesicles); these are very variable in number and size; from six to ten or twelve, fully formed, are usually observed, but the microscope reveals numerous minute ovisacs throughout the parenchyma. This structure is most distinct if examined shortly after parturition, the ovary being then swollen, soft, spongy, and vascular, and the vesicles enlarged. The Graafian vesicles are small, transparent cysts, varying in size from a pin's head to a small pea, containing a transparent, yellowish fluid, and adhering to the stroma; each has two coats, an external or vascular, and an internal (the ovi-capsule), lined with epithelium; in each vesicle there is usually only one ovum at first in its centre, but as it is matured it approaches the inner surface of the internal coat, and becomes surrounded by a granular covering. An *ovum* is a spherical body, of uniform size, about $\frac{1}{120}$ of an inch in diameter, with a thick but transparent coat, which surrounds the yolk; within the latter is the germinal vesicle of Purkinjie, and within this again is the germinal spot of Wagner. (For further information on this subject, and on the changes that follow impregnation, see Muller's Physiol., transl. by Baly; also Carpenter's Human Phys., p. 684). On one or both ovaries we commonly observe an appearance known under the name of *corpora lutea*. A corpus luteum is considered to be the remains of a vesicle ruptured in consequence of impregnation; it is usually a small, yellowish, brownish mass, of a spongy tissue, traversed by white bands, and containing a small cavity which had been occupied by the ovum; it is lined by a puckered membrane, the remains of the ovisac; if recent, the opening from this sac, through the capsule of the ovary, whereby the ovum escaped, is distinct; when this is closed a small cicatrix exists in its situation.

As the ovaries contain the ova, they are essential to reproduction. In the fœtus they are large in proportion, and, like the testes, occupy the lumbar regions, and gradually descend into the pelvis. During pregnancy they are carried up into the abdomen along with the uterus, to the sides of which they are closely applied: shortly after parturition they are situated in the iliac fossæ, and are not unfrequently retained there by adhesions during the rest of life.

The mammary glands have been already examined (page 74).

The female organs of generation are the seat of many *morbid*

changes. Not to notice the various ulcerations to which the *external parts* are liable, we occasionally find here also polypi, adipose, and sarcomatous tumours in the labia, enlargement of the clitoris, &c.

The uterus may be found inflamed (matritis); this most frequently occurs soon after parturition; the adjacent peritonæum is then also generally affected: the uterus itself exhibits the same appearances as other inflamed parts; the inflammation is found to creep along the Fallopian tubes and ovaries. It often advances to suppuration, and pus is generally found in the large veins of the womb. In puerperal peritonitis, it has been remarked, that the extravasated fluid and coagulable lymph are found in a greater proportion to the degree of inflammation, and the lymph softer and more coloured, than in common peritonitis. *Polypi* are very frequently found in the uterus; they may grow at any period of life, but they are rarely met with in the young. By a polypus is meant a diseased mass, which adheres to the cavity of the uterus by a sort of a neck or narrower portion. Polypus is of two different kinds; the most common is hard, and consists of a substance divided by thick membranous septa. This sort of polypus varies much in its size, some not being larger than a walnut, and others exceeding in bulk a child's head. Another sort of polypus forms in the uterus, which consists of an irregular bloody substance, with tattered processes hanging from it; when cut into, it appears to be a spongy mass, containing large cells. The most common part to which polypi adhere is the fundus uteri, and sometimes they are found attached to the os tincæ. Hard, fibrous tumours also not unfrequently exist in the parietes of the uterus. One of the most frequent affections of this organ is a granulated state of the os tincæ, giving rise to leucorrhœa. The os, and the parts about it, are covered with minute red elevations, like the surface of a raspberry, and the interstices are covered with a fluid resembling pus, but which is really serum. The uterus is also the seat of cancer, which usually commences near the os tincæ. It is likewise often subject to partial displacement, viz., prolapsus, inversio, and retroversio.

The investing membrane, or the substance of the *ovary*, are very rarely found inflamed, except when they are included in general peritonitis. When the inflammation proceeds from the uterus, or from the cæcum (perityphlitis), as occasionally happens, it sometimes goes on to the formation of pus in the ovary. The most common disease in the ovary is dropsy; the whole substance of the ovarium is sometimes converted into a capsule containing fluid, the natural structure has disappeared, and it is found converted into cells, communicating with one another by considerable openings, and very much enlarged. The ovaria are sometimes converted into a series of cysts, which have no communication with each other: these cysts have been confounded with hydatids, to which they bear some resemblance; they are, however, very different; they have much firmer and less pulpy coats than hydatids; they contain a different kind of fluid, and they are diffe-

rently connected among themselves. Hydatids either lie unconnected, or one large one encloses a number of small ones; while ovarian cysts adhere to each other by broad surfaces, and do not enclose each other. The ovaria are sometimes found converted into cysts, holding large masses of fat, hair, and some teeth ; these substances appear to be generated by the internal membrane of the cyst; the hairs are most of them loose in the fatty substance, but many of them adhere to the inside of the capsule; the teeth, which are not always perfect, are sometimes attached to the cyst, and at others to an irregular mass of bone.

*Fig.* 57.*

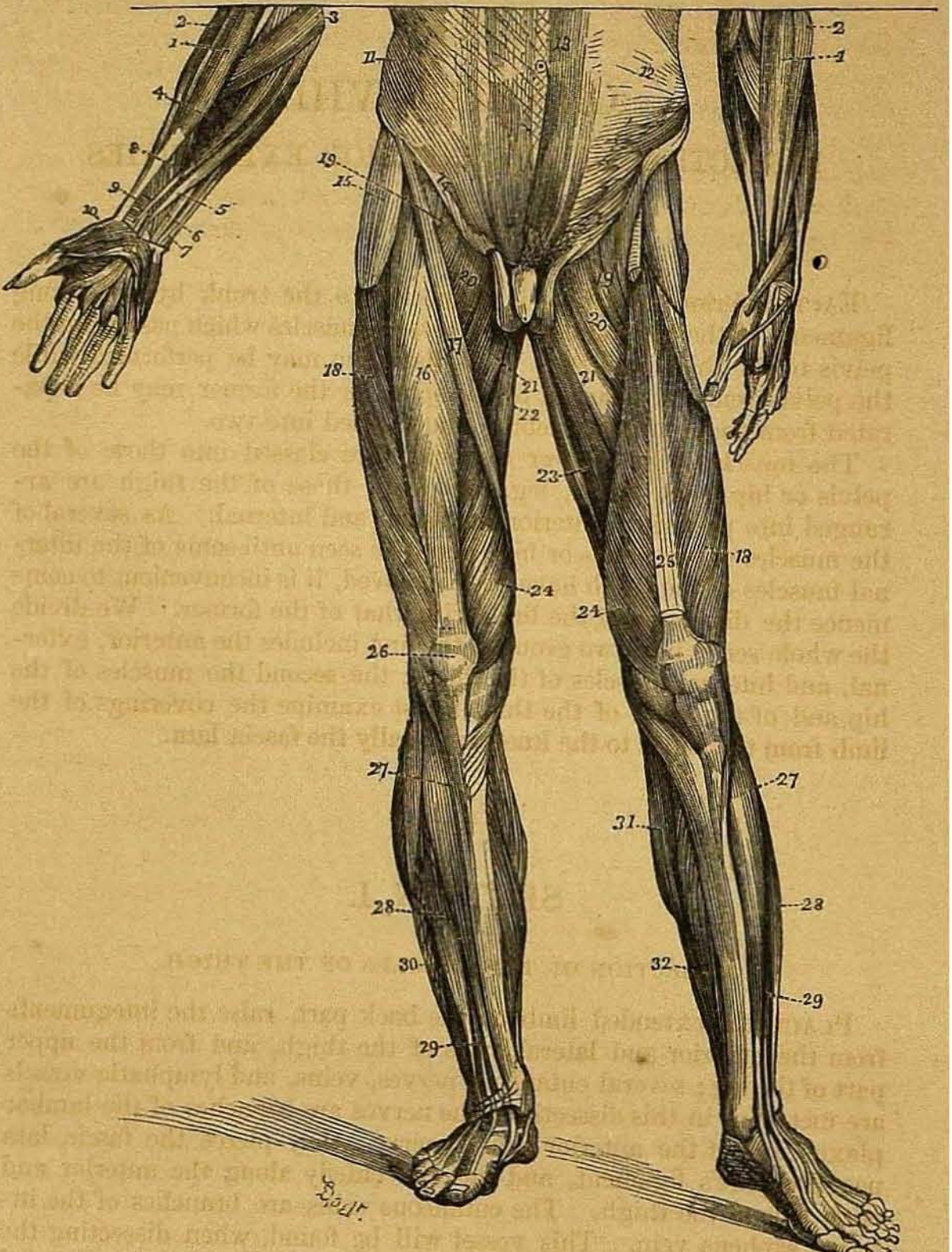


* The muscles of the anterior aspect of the trunk and extremities; on the right side the superficial layer is seen, and on the left side the deeper layer. 1. 1. Supinator radii longus. 2. 2. Extensor carpi radialis longus. 3. Pronator radii teres. 4. Flexor carpi radialis. 5. Palmaris longus. 6. Flexor digitorum sublimis. 7. Flexor carpi ulnaris. 8. Portion of flexor digitorum sublimis. 9. Pronator quadratus. 10. Abductor pollicis. 11. Portion of obliquus externus abdominis. 12. Portion of obliquus internus. 13. Rectus abdominis. 14. Inferior border of external oblique forming the crural arch. 15. Tensor vaginæ

# CHAPTER VIII.

## DISSECTION OF THE INFERIOR EXTREMITIES.

EACH inferior extremity is connected to the trunk by the strong ligaments of the hip joint, and by several muscles which pass from the pelvis to the thigh and leg. This dissection may be performed while the pelvis remains attached to the spine, or the former may be separated from the lumbar vertebræ, and divided into two.

The muscles of the lower extremity are classed into those of the pelvis or hip joint, thigh, leg, and foot; those of the thigh are arranged into posterior, anterior, external, and internal. As several of the muscles of the pelvis or hip cannot be seen until some of the internal muscles of the thigh have been removed, it is inconvenient to commence the dissection of the limb with that of the former. We divide the whole series into two groups; the first includes the anterior, external, and internal muscles of the thigh; the second the muscles of the hip and of the back of the thigh: first examine the coverings of the limb from the pelvis to the knee, especially the fascia lata.

## SECTION I.

### DISSECTION OF THE MUSCLES OF THE THIGH.

PLACE the extended limb on the back part, raise the integuments from the anterior and lateral parts of the thigh, and from the upper part of the leg; several cutaneous nerves, veins, and lymphatic vessels are met with in this dissection; the nerves are branches of the lumbar plexus and of the anterior crural nerve; they pierce the fascia lata near Poupart's ligament, and descend chiefly along the anterior and outer side of the thigh. The cutaneous veins are branches of the internal saphena vein. This vessel will be found, when dissecting the leg and foot, to commence at the inner side of the latter, and to ascend

femoris. 16. Rectus femoris. 17. Sartorius. 18. 18. Vastus externus. 19. 19. Femoral portion of the psoas magnus and iliacus internus muscles. 20. 20. Pectinæus muscle. 21. 21. Adductor longus. 22. Gracilis. 23. Part of the adductor magnus. 24. 24. Vastus internus. 25. Cruræus. 26. The patella. 27. 27. Tibialis anticus. 28. 28. Extensor digitorum communis. 29. 29. Extensor pollicis proprius. 30. Peronæi muscles. 31. Internal portion of gastrocnemius. 32. Solæus.

along the internal part of the leg and knee to the inner and forepart of the thigh, along which it continues its course to the groin; about an inch and a half or two inches below Poupart's ligament it pierces the fascia lata, and joins the femoral vein. In this course it receives several cutaneous branches, and, in general, just before it ends in the femoral, it is joined by one or two large veins from the outer and forepart of the thigh, and by some smaller branches from the abdominal parietes; some cutaneous branches from the anterior crural and lumbar nerves accompany this vein in its course along the thigh. Beneath the integuments the thigh is invested by the superficial fascia, which is prolonged around it from the parietes of the abdomen. In the groin this fascia is thick and laminated, and closely connected to the fascia lata, particularly to its cribriform portion; but inferiorly and posteriorly it is thin and loose, as ordinary sub-cutaneous cellular tissue. This fascia may be easily detached from the fascia lata, except in the groin; in attempting to raise it in this region we expose the superficial inguinal glands, some of which lie between its laminæ; they are eight or ten in number; five or six of them are placed parallel to Poupart's ligament, some above, others below it; two or three are situated lower down in the groin than these, near the termination of the saphena vein. These last glands lie on the fascia lata; they are larger than the former, and are parallel to the saphena vein. Through these conglobate glands the superficial absorbents of the lower extremities pass, also those from the external parts of generation. Beneath the fascia lata, close to, and generally internal to the femoral vessels, are the deep-seated inguinal glands; small, only three or four in number; they transmit the deep-seated absorbents of the limb. The integuments and superficial fascia having been removed, the *fascia lata*, or *crural*, or *femoral aponeurosis*, may be next examined. This aponeurosis surrounds the thigh; it is very strong and tendinous externally, but so thin and weak internally that without caution it may be removed along with the integuments; it is attached superiorly and externally to the crest of the ilium; posteriorly to the sacrum and coccyx: on the glutæus maximus it is weak and thin, but at the anterior border of this muscle it becomes very strong, receiving an addition of fibres both from the tendon of that muscle and from the tensor vaginæ femoris; anteriorly it is attached to Poupart's ligament, and internally to the rami of the ischium and pubis; as it extends down the thigh it confines the different muscles in their situation, so as to preserve the figure of the limb; several processes also pass inwards to form septa and sheaths for some muscles, and to bind others in their place: to many of these processes the muscles adhere, so that when in action they serve to make the fascia more tense and resisting; this is especially the case with the glutæus maximus and the tensor vaginæ: these processes also serve to increase the surface of origin or attachment of several muscles. Along the posterior part of the thigh it is connected to the whole length of the linea aspera, also to the insertion of the glutæus maximus, and to the origin of the short head of the

biceps; inferiorly it adheres to the condyles of the femur, surrounds the knee-joint, and receives an addition of fibres from the different tendons in this region; a bursa separates it from the patella; below the knee it is continued over the heads of the tibia and fibula into the fascia of the leg. Numerous foramina are observable in the fascia lata, particularly at the upper and anterior part of the thigh; they transmit cutaneous nerves and vessels: the most remarkable of these holes is that for the saphena vein; it is situated on the anterior and inner aspect of the thigh, about an inch and a half or two inches below Poupart's ligament, and may be most distinctly seen by dividing the vein below, and raising it towards the abdomen. This opening is semilunar, the concavity directed upwards; from its apparently sharp edge the fascia is reflected backwards, and is lost on the sheath of the femoral vessels. That part of the fascia which is internal to this opening is named the pubic portion of the fascia lata; it covers the pectinæus muscle, adheres to the spine and linea innominata of the pubis, extends behind the femoral vessels, and divides into two laminæ; one is continuous with the fascia iliaca, in front of the psoas and iliac tendon; the other passes deeper and behind this tendon to join the ilio-femoral capsule; that part of the fascia lata external to the saphenic opening is called the iliac portion; it covers the sartorius, tensor vaginæ, rectus, and iliacus internus muscles, and is continued obliquely in front of the femoral vessels, in the form of a *crescentic* or *falciform process*, the concavity of which is directed downwards and inwards; the convexity is towards the ilium, and attached to Poupart's ligament; the lower cornu of this crescentic process is continuous with the outer cornu of the saphenic opening, and the upper cornu extends in front of the femoral vessels to their inner side, and is inserted along with the third insertion of Poupart's ligament, or Gimbernaut's ligament, into the linea innominata, or ileo pectinæa. Between the margin of the falciform process and the pubic part of the fascia lata is a thin membrane, perforated by numerous vessels; this is termed the *cribriform fascia;* it is connected on either side to the iliac and pubic portions of the fascia lata, and may be regarded either as a thin lamina of the fascia lata connecting these two lateral portions, or as a deep layer of the superficial fascia; it extends from the saphena vein to Poupart's ligament, in front of the sheath of the femoral vessels; it adheres to the anterior part of this sheath, or to the fascia transversalis; when this cribriform fascia is removed the falciform process is made more distinct. (*See* Description of Crural Hernia, page 214.) The fascia lata, in some situations, particularly along the outer side of the limb, is seen to consist of two laminæ of fibres; the external take a circular, the internal a longitudinal direction; these two laminæ are very distinctly separated at the upper and outer part of the thigh by the insertion of the tensor vaginæ femoris; the deep layer, which in this situation is very strong, is attached to the capsular ligament of the hip joint, and to the external head of the rectus muscle; of its intermuscular septa two are very strong, external and internal;

the *external* extends from the great trochanter to the external condyle, attached to the linea aspera; the vastus externus adheres to it in front, the short head of the biceps behind; it is pierced above by the external circumflex, and below by the external articular vessels. The *internal* intermuscular septum arises from the anterior intertrochanteric line, and is inserted into the inner condyle, adheres to the linea aspera between the vastus internus and the adductor tendons. These two great septa separate the muscles on the front from those on the inner and back part of the thigh; between the two latter regions again a weaker septum is interposed, so that there are three principal muscular compartments, one for the posterior, another for the internal, and a third for the anterior muscles; and the two latter compartments are subdivided into sheaths for the separate muscles, as will be seen in the course of their dissection. Raise the fascia lata from the anterior and lateral parts of the thigh; several muscles will come into view, the femoral vessels also in the groin will be partially exposed; they are still somewhat concealed by a quantity of adipose substance, by a few deep-seated lymphatic glands, and by their anterior sheath or the fascia transversalis; when the former are removed, and the latter opened, we always find the vein internal to the artery, and about an inch and a half from the spine of the pubis: immediately external to the vein is the artery resting on the psoas, and about a quarter of an inch external to the artery is the anterior and crural nerve, imbedded between the psoas and iliacus, and covered by the fascia iliaca; it does not, therefore, lie in the sheath of the vessels: internal to the vein, between it and the inner wall of the sheath, is the femoral ring. Clean the several muscles which now partially appear on the forepart of the thigh: external to the vessels the sartorius and tensor vaginæ are first seen; internal to the vessels are the pectinæus, gracilis, and the three adductors; and immediately covering the anterior and lateral parts of the femur are the rectus, cruræus, vastus internus, and externus.

## SECTION II.

### MUSCLES ON THE FOREPART AND SIDES OF THE THIGH.

THESE are eleven in number.

1. TENSOR VAGINÆ FEMORIS, at the upper and outer part of the thigh, narrow above, broad and thin below, *arises* tendinous and fleshy from the external part of the anterior superior spinous process and crest of the ilium; it forms a fleshy belly, which descends obliquely backwards, and is *inserted*, broad and thin, into a duplicature of the fascia lata on the outside of the thigh, about three or four inches below the great trochanter. *Use*, to make tense the fascia, and compress the vastus externus; to rotate the thigh inwards; also to assist

in flexing and abducting it. The origin of this muscle is between the sartorius and glutæus medius; between these muscles it descends, covered by the fascia lata; its insertion is anterior to that of the glutæus maximus muscle.

2. Sartorius, or the tailor's muscle, is the longest muscle in the body, thin and flat like a riband, broader in the middle than at the extremities, situated obliquely along the anterior and inner side of the thigh, *arises* by short, tendinous fibres from the anterior superior spine of the ilium, and from the notch below that process, it soon becomes broad and fleshy, extends obliquely across the thigh to its inner side, and, descending perpendicularly to the knee, passes behind the condyle of the femur; it then turns forwards and outwards towards the inner side of the upper end of the tibia, into which it is *inserted* below the tubercle by a long, flat tendon, the anterior edge of which is attached to the fascia lata covering the knee-joint, and the posterior edge sends off an aponeurosis to the fascia of the leg. *Use*, to flex the leg upon the thigh, also the latter on the pelvis; to adduct the thigh and leg obliquely, so as to cross the lower extremities, or to place one foot on the opposite knee; when the thigh and leg are extended, it assists in raising and advancing forwards the whole limb, also in turning the knee outwards; in standing it also supports the pelvis, and prevents it bending backwards on the thigh; it may then also flex the body, and rotate it to the opposite side. This muscle through its whole extent is covered only by the fasoia lata and the integuments;

*Fig.* 58.*

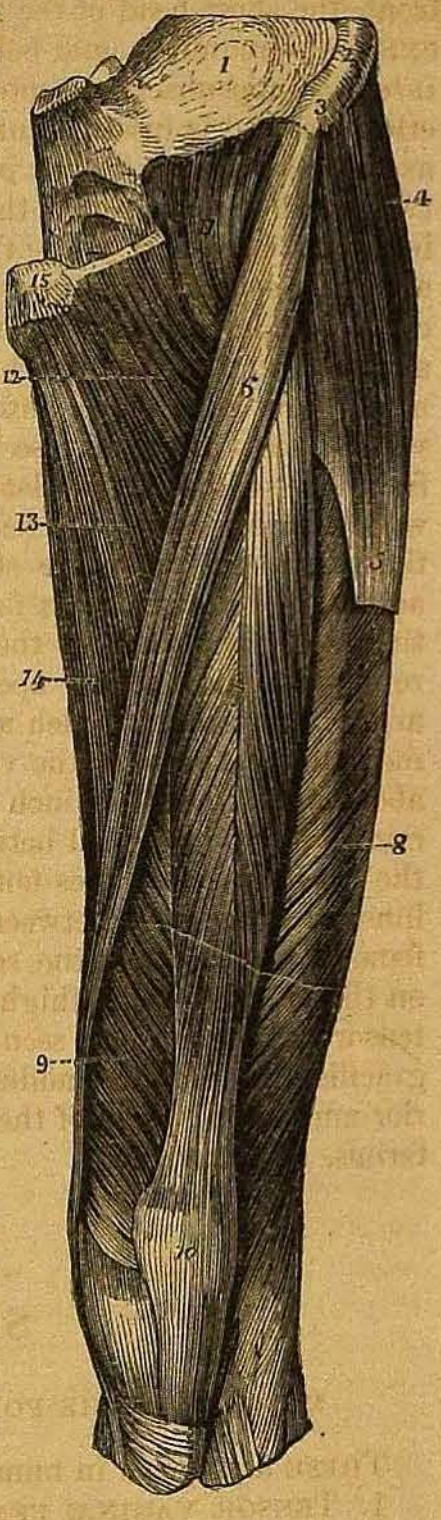


* The muscles on the forepart and sides of the thigh. 1. The internal iliac fossa. 2. The crest of the ilium. 3. The anterior-superior spine of the ilium. 4. The anterior portion of the glutæus medius. 5. The tensor vaginæ femoris muscle, cut off just below its insertion into the fascia lata. 6. The sartorius. 7. The rectus femoris. 8. The vastus externus. 9. The vastus internus. 10. The patella. 11. The inferior portion of the internal iliac and psoas muscles. 12. The pectinæus muscle. 13. The adductor longus. 14. Part of the adductor magnus. 15. The pubis.

its superior extremity lies between the tensor vaginæ and the iliacus internus muscles; its inferior extremity expands into a strong aponeurosis, which covers and adheres to the tendons of the semi-tendinosus and gracilis muscles, anterior and superficial to both of which it is inserted, a bursa being usually interposed; in its course along the thigh it first passes over the psoas, iliacus, and rectus muscles; next over the vastus internus and adductor muscles, saphenous nerve, and the femoral vessels; is separated from the latter by a strong aponeurosis; inferiorly it passes over the internal lateral ligament of the knee, between the tendons of the adductor magnus and the gracilis. The superior third of this muscle extends in an oblique direction from the ilium downwards and inwards, forms the external boundary of the inguinal region, lies to the outer side of the femoral vessels, and serves as a guide to the operator when exposing them; the middle third is more vertical in its course, and is about two inches broad, and completely covers the femoral vessels, also a part of the adductor and vastus internus muscles; the lower third is in a groove between the gracilis and vastus internus; near the knee the saphenous nerve is anterior, and the vein behind it.

3. Rectus Femoris, long and flat, rather round and thick in the centre, placed vertically on the forepart of the thigh, *arises* by two tendons, one straight, short, strong, anterior, and internal, from the anterior inferior spinous process of the ilium, the other longer, broader, and more curved, from the superior and external border of the acetabulum, and from the capsular ligament; these tendons soon uniting form a strong, fleshy belly, which descends almost vertically, with a slight inclination inwards. This muscle has a peculiar penniform appearance; it is also tendinous anteriorly in the upper half, so that the sartorius can glide over it, and tendinous posteriorly in the lower half, whereby it can move on the surface of the cruræus; ends in a flat tendon, is *inserted* along with the vasti and cruræus into the upper edge of the patella; a few fibres pass anterior to this bone, and are continued into the ligamentum patellæ, which descends obliquely outwards to the tubercle of the tibia. *Use*, to extend the leg on the thigh, and flex the thigh on the pelvis; it supports the pelvis in a state of equilibrium, but can also bend it forwards on the thigh, and it strengthens the capsular ligament of the hip joint; its action is facilitated by the patella, which changes the direction of its force, by increasing the angle of insertion, and this is still further secured by the tendon and ligamentum patellæ being inserted into the anterior surface of the bone, and not into its posterior rough margin: the rectus tendon and the ligamentum patellæ form an angle concave outwards; the tendency, therefore, of this muscle, is to prevent the patella being pushed inwards by any external force; this circumstance, however, favours dislocation of this bone, which always occurs in a direction outwards; in some persons, in whom the knees incline too much inwards, this angle is very obtuse, and dislocation therefore more likely to occur. The anterior tendinous origin of this muscle is

covered by the sartorious, tensor vaginæ, and iliacus internus muscles; the posterior by the glutæus medius and minimus muscles; the remainder of the muscle is only covered by the integuments and fascia; superiorly this muscle lies on the capsular ligament of the hip joint and the external circumflex vessels; in the rest of its course, on the cruræus and vasti muscles, to which it is united below, so that these four are really one muscle, a *quadriceps extensor cruris*. Beneath the rectus we find this large mass of muscular substance covering the front and sides of the femur; it may be divided superiorly into three portions, but inferiorly these are inseparably united; the external portion is named vastus externus, the internal vastus internus, and the middle cruræus.

4. VASTUS EXTERNUS, much larger than the other portions, and larger above than below, *arises* tendinous and fleshy from the root and anterior part of the great trochanter, anterior to the tendon of the glutæus maximus, from the outer edge of the linea aspera, its whole length, and from the oblique ridge which leads to the external condyle, anterior to the short head of the biceps; from all the external surface of the bone, and from the fascia lata, and its external septum; the fibres descend obliquely forwards, the superior are very long, the inferior are shorter and more transverse, *inserted* into the external surface of the tendon of the rectus, also into the side of the patella, and by an aponeurosis, which adheres to the synovial membrane of the knee-joint, into the head of the tibia. *Use*, to extend the knee, also to rotate the leg outwards; this muscle is partly concealed by the rectus; its external surface is tendinous above and fleshy below, its internal is fleshy above and tendinous below; covered by the fascia lata and its tensor, and by the tendon of the glutæus maximus.

5. VASTUS INTERNUS, smaller and shorter than the last, narrow above, but broad below; *arises* on the anterior part of the femur, from the inter-trochanteric line; from the inner edge of the linea aspera, its whole length, also from the inner side of the femur, the fibres desend obliquely forwards, and are *inserted* into the inner edge of the tendon of the rectus, also into the patella, and by an aponeurosis, which covers the inner side of the synovial membrane of the knee, into the head of the tibia. *Use*, to extend the knee and turn the leg a little inwards. The vestus internus is partly concealed by the rectus and sartorius, its origin lies anterior to the insertion of the psoas, pectinæus, and adductor muscles, and overlaps the cruræus, so as to be in contact with the vastus externus; its internal surface is tendinous above and fleshy below; an aponeurosis from the two vasti covers the patella and its ligament, also the sides of the joint; this aponeurosis is inserted into the head of the tibia, it serves to support the patella in its situation, and to protect the sides of the articulation like a capsular ligament; a small bursa is situated over the patella, between this aponeurosis and the skin; the insertion of the vastus externus into the patella overlaps that of the vastus internus, and

both overlap the cruræus, from which the vastus externus can be more easily separated above, but the vastus internus below.

6. Cruræus, shorter than either of the vasti, between which it lies, larger and more tendinous below than above, *arises* fleshy from the anterior and external part of the femur, commencing at the inter-trochanteric line, and extending along three-fourths of the bone, as far outwards as the linea aspera; it does not adhere to the inner side of the femur, there being a portion of the latter, nearly an inch in breath and extending almost the whole length of the bone, to which no muscular fibre adheres; the cruræus descends close to the femur to its inferior third, the fibres then incline forwards, become tendinous posteriorly, and are separated from the bone by a large bursa, and by a considerable quantity of fat; *inserted* into the upper and anterior edge of the patella, also into the synovial membrane of the knee behind the vasti, particularly the external, to which it is here intimately united. *Use*, to assist the vasti and the rectus in extending the leg. This muscle is covered by the rectus and the vasti, from the latter it can only be separated superiorly by tearing a few muscular fibres, and tracing some large nerves and vessels that pass between them. The large bursa, which is situated behind the lower part of this muscle, is attached to and frequently communicates with the synovial membrane of the joint. A few muscular fibres are generally attached to this membrane, and have been described as a distinct muscle, the Sub-cruræus or Capsular; this *arises* from the anterior surface of the femur, about its inferior fourth, passes forwards and downwards, and is *inserted* into the synovial membrane. *Use*, to raise the synovial membrane in extension of the leg, so as to prevent its being contused by the patella.

7. Gracilis, flat, long, and thin, broad and fleshy above, round and tendinous below, situated at the inner side of the thigh, immediately beneath the integuments and fascia; *arises* by a broad, thin, short tendon from the lower half of the symphysis, and from the inner edge of the descending ramus of the pubis; it soon becomes fleshy, and descends vertically, one edge directed forwards, the other backwards, and its surfaces looking one inwards, the other outwards; about the inferior fifth of the thigh it ends in a round tendon which passes behind the inner condyle, and then turns forward along with the tendon of the sartorius, behind and beneath which it lies; *inserted* into the superior part of the internal surface of the tibia, uniting in a common aponeurosis with the sartorius and semi-tendinosus, but superficial to the latter. *Use*, to adduct the leg and thigh, to bend the knee, and turn the leg and foot inwards. The origin of the gracilis is between the triceps and the crus penis; its whole course is superficial, except near the knee, where it is covered by the sartorius; its insertion is inferior to that of the sartorius, and superior to that of the semi-tendinosus; the saphena vein and nerve are situated between its tendon and that of the sartorius at the inner side of the knee, but these are separated from each other by a fascia, which attaches these

tendons together, the vein lying superficial: from the tendon of the gracilis an aponeurosis is sent off to the fascia of the leg.

8. PECTINÆUS, flat, triangular, broad above, situated at the superior, anterior, and internal part of the thigh; *arises* fleshy from the linea innominata and the concave surface below it on the horizontal ramus of the pubis, between the spine of that bone and the ilio-pectinæal eminence; it forms a flat, fleshy belly, which descends obliquely outwards and backwards, and, becoming narrower and a little twisted, is *inserted* by a flat tendon into the rough ridge which leads from the lesser trochanter to the linea aspera. *Use*, to adduct and flex the thigh, also, to rotate it outwards; it may also serve to strengthen the capsular ligament of the hip joint internally, and in adduction of the limb to draw the capsule inwards from between the neck of the femur and the acetabulum. It lies between the psoas magnus and the adductor longus; the latter overlaps it, covered superiorly by the fascia lata, and inferiorly by the femoral vessels, the fascia intervening; it covers the obturator nerve and vessels, the external obturator muscle, and the adductor brevis; it also adheres to the capsular ligament of the hip joint.

TRICEPS ADDUCTOR FEMORIS consists of three portions, which pass in distinct laminæ from the pelvis to the thigh.

9. ADDUCTOR LONGUS, flat and triangular, base below, is situated at the upper and internal part of the thigh, superficial to the other adductors and to the pectinæus; it *arises* by a short, small, but strong tendon from the anterior surface of the pubis, between its spine and the symphysis; this ends in a broad, fleshy belly, which descends obliquely backwards and outwards, and is *inserted* by a broad, thin tendon into the middle third of the linea aspera, between the adductor magnus and the vastus internus, to both of which it is closely united. The origin of this muscle lies between the pectinæus and the gracilis, and above the adductor brevis; its insertion is behind the vastus internus, and in front of the profunda artery, and adductor magnus; is covered by the integuments and fascia superiorly, and by the sartorius and femoral vessels inferiorly; and there forms the posterior wall of that remarkable fibrous tube which encloses the femoral vein and artery in the middle of the thigh: it lies anterior to the two following muscles; its tendon is perforated by vessels.

10. ADDUCTOR BREVIS, thick and fleshy, short, flat, and triangular, is situated posterior to the adductor longus and pectinæus, and internal to the psoas; *arises* flat and tendinous from the anterior inferior surface of the pubis, between the gracilis muscle, the symphysis pubis, and the thyroid hole; it soon ends in a fleshy belly, which passes outwards, backwards, and a little downwards, *inserted* by tendinous slips into the superior third of the internal root of the linea aspera, extending for about three inches below the lesser trochanter; its origin is external to the gracilis, and internal to the obturator externus, and concealed by the adductor longus and pectinæus; as it descends it is covered by these muscles, except a small portion near

its insertion, which appears between them; this portion is posterior to the femoral and profunda vessels; its insertion is anterior to that of the adductor magnus; in its tendon one or two large openings frequently exist for the passage of some of the perforating arteries.

11. ADDUCTOR MAGNUS, the longest and largest of the adductors, very thick internally, triangular, the base attached to the femur, the apex to the pelvis; composed of thick and separate fasciculi like the glutæus maximus; *arises* chiefly fleshy from the anterior surface of the descending ramus of the pubis, external to the gracilis, also from the ramus of the ischium, and tendinous from the external border of the tuberosity of the latter; the fibres pass outwards with different degrees of obliquity; those which arise from the pubis ascend obliquely outwards, those from the ramus of the ischium pass outwards and downwards, and those from the tuber ischii more directly downwards; *inserted* fleshy into the rough ridge which leads from the great trochanter to the linea aspera, tendinous and fleshy into the linea aspera, and by a long round tendon into the internal condyle of the femur, immediately above the inner tendon of the gastrocnemius. This muscle forms a septum between the inner and back part of the thigh; its superior edge has a twisted appearance, is nearly parallel to the quadratus femoris; several branches of the internal circumflex vessels pass between these, and in rotation of the leg inwards the lesser trochanter also projects between them; the middle portion, which is inserted into the linea aspera, is internal to the insertion of the glutæus maximus, and to the origin of the short head of the biceps. This part of the muscle is perforated by several branches of the perforating arteries; at the lower part of the linea aspera it appears to separate into two portions, one of which is inserted into this line, between the vastus internus and the short head of the biceps; the other is continued into the long tendon, which is inserted into the inner condyle; the femoral vessels pass between these into the popliteal space. The adductor magnus is covered internally by the gracilis, and anteriorly by the long and short adductors, pectinæus, part of the sartorius, and the femoral vessels; posterior to it are the sciatic nerve and the hamstring muscles; the tendinous insertion of the lower part of this muscle is intimately connected to the vastus internus. About the inferior fourth of the thigh there is a large oblique opening, bounded by these two muscles and by the adductor longus, through which the femoral vessels pass into the popliteal space. This muscle, particularly its origin, should also be examined on its posterior aspect, where it is covered by the three hamstrings, the sciatic nerve, and a large quantity of cellular and adipose tissue; in this aspect its division into two is more distinct; the superior or external portion passes more transversely outwards, consists of distinct fasciculi, the aponeurotic insertions of which are united with the other adductors, forming arched and incompressible openings for the passage of the femoral vessels, and for three or four perforating branches of the profunda artery; the internal portion principally arises from the tuber ischii, descends

nearly vertical, and ends in the tendon which is inserted into the inner condyle. *Use*, the three adductors, in addition to adducting the limb, can rotate it outwards ; they also serve to steady and support the pelvis on the thigh; the long and short adductors can also flex the thigh on the pelvis, and the adductor magnus can extend it when it has been flexed.

In dissecting the preceding muscles we observe the following vessels and nerves :

The *Femoral Artery* passes from under Poupart's ligament, about midway between the symphysis pubis and the spine of the ilium, descends obliquely inwards and backwards, and about the lower part of the middle third of the thigh perforates the adductor magnus, enters the popliteal space, and then receives the name of popliteal artery. In the upper third of the thigh, or in the inguinal region, it is covered only by the skin, superficial fascia, some lymphatic glands, and the fascia lata ; in the middle third of the thigh it receives the additional covering of the sartorius, and beneath this of a very strong tendinous aponeurosis, which passes from the tendons of the adductor longus and magnus over the artery and vein, and joins the tendon of the vastus internus. In this part of the thigh it is thus enclosed in a perfect tendinous sheath, consisting anteriorly of the aponeurosis just mentioned, posteriorly and internally of the tendons of the adductor longus and magnus, and externally of the vastus internus : at the lower end of this sheath it passes into the ham, through a large oval opening, which is bounded superiorly by the adductor longus and magnus, externally by the vastus internus, internally by the adductor magnus, and inferiorly by the united tendons of the adductor magnus and vastus internus. The femoral artery in this course first passes over a few fibres of the psoas, next over the pectinæus and adductor brevis, the adductor longus, and a small portion of the magnus : immediately below Poupart's ligament gives off, 1st, some cutaneous branches ; 2nd, small arteries to the inguinal glands ; 3rd, about two inches below Poupart's ligament, a very large branch, the profunda ; 4th, several muscular branches to the sartorius and vastus internus ; and 5th, just before it enters the ham, the anastomotica magna, which is distributed to the muscles and integuments at the inner side of the knee. The *profunda* is the largest branch of the femoral ; it descends behind that vessel and to its inner side, and gives several branches to the muscles of the thigh, namely, the external and internal circumflex, and the three or four perforating arteries. (*See* Anatomy of the Vascular System.) The *femoral* vein takes the same course as the artery ; in the groin it always lies to its internal or pubic side, but as it descends it becomes posterior to it. In dissecting the muscles on the forepart of the thigh, numerous branches of the *anterior crural nerve* are met with. This nerve in the groin is separated into several branches ; many of these become cutaneous, others pass to the muscles on the forepart of the thigh, and two or three accompany the femoral artery ; one of these, the *nervus saphenus*, enters its tendinous sheath, and, descending along the forepart of the artery, as far as the

*Fig.* 59.*

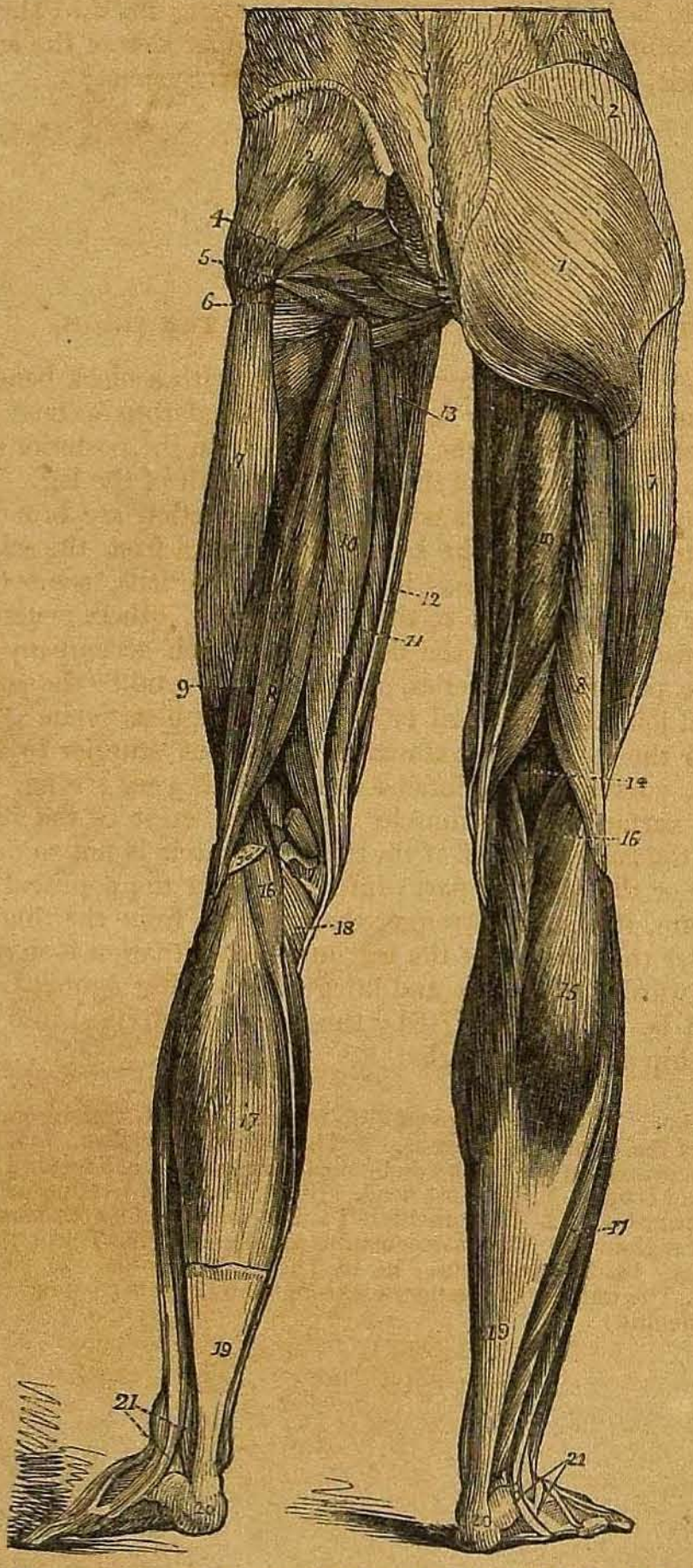


* The muscles on the posterior aspect of the thigh and leg; part of the superficial layer has been removed on the left side. 1. The glutæus maximus. 2. 2.

opening in the tendon of the triceps, then leaves that vessel, descends between the tendons of the sartorius and gracilis muscles to the inner side of the knee, becomes cutaneous, and, attaching itself to the saphena vein, accompanies this vessel along the inner side of the leg to the internal ankle. (*See* Anatomy of the Nervous System.)

---

## SECTION III.

### DISSECTION OF THE POSTERIOR PART OF THE THIGH.

Place the detached extremity on its forepart, with a block beneath the hip joint, so as to flex the latter slightly, and thus extend the muscles in this region. Raise the integuments from the posterior surface of the limb, from the crest of the ilium to the calf of the leg. The cutaneous nerves which are met with in this dissection are branches from the lumbar nerves, from the sacral plexus, and from the sciatic nerve. The cutaneous veins pass in different directions, some turn round the inner side of the limb to the saphena vein, others penetrate between the muscles, and join the deep veins which accompany the muscular or the perforating arteries, and others descend to the popliteal space, and join the popliteal or the lesser saphena vein. The fascia lata over the glutæus maximus is weak, but anterior to that muscle, that is, covering the glutæus medius, it is very strong, and adheres to the surface of this muscle, and to the crest of the ilium above it. On the posterior part of the thigh the fascia is not so dense as on the outer or the anterior part; inferiorly, over the popliteal region, or the ham, it is much stronger than above; from the thigh it is continued over the muscles of the leg, in which situation it may be examined afterwards: the fascia and integuments being removed, the muscles should be cleanly dissected; these may be divided into the muscles of the hip and of the thigh.

The glutæus medius. 3. Part of the pyriformis muscle. 4. The superior gemellus. 5. Portion of the obturator internus. 6. The inferior gemellus. 7. 7. The vastus externus, covered on the right side by the fascia lata. 8. 8. The long head of the biceps flexor cruris. 9. Its short head. 10. 10. The semi-tendinosus. 11. The semi-membranosus. 12. The gracilis. 13. Part of the adductor magnus. 14. The popliteal region. 15. The gastrocnemius muscle. 16. 16. The plantaris. 17. 17. The solæus. 18. The popliteus. 19. 19. The tendo Achillis. 20. 20. The os calcis. 21. 21. The tendons of the peroneus longus and brevis passing behind the external malleolus.

# SECTION IV.

## DISSECTION OF THE MUSCLES OF THE HIP.

THESE are nine in number, viz., the three glutæi, the pyriformis, the gemini, the two obturator, and the quadratus femoris.

*Fig.* 60.*

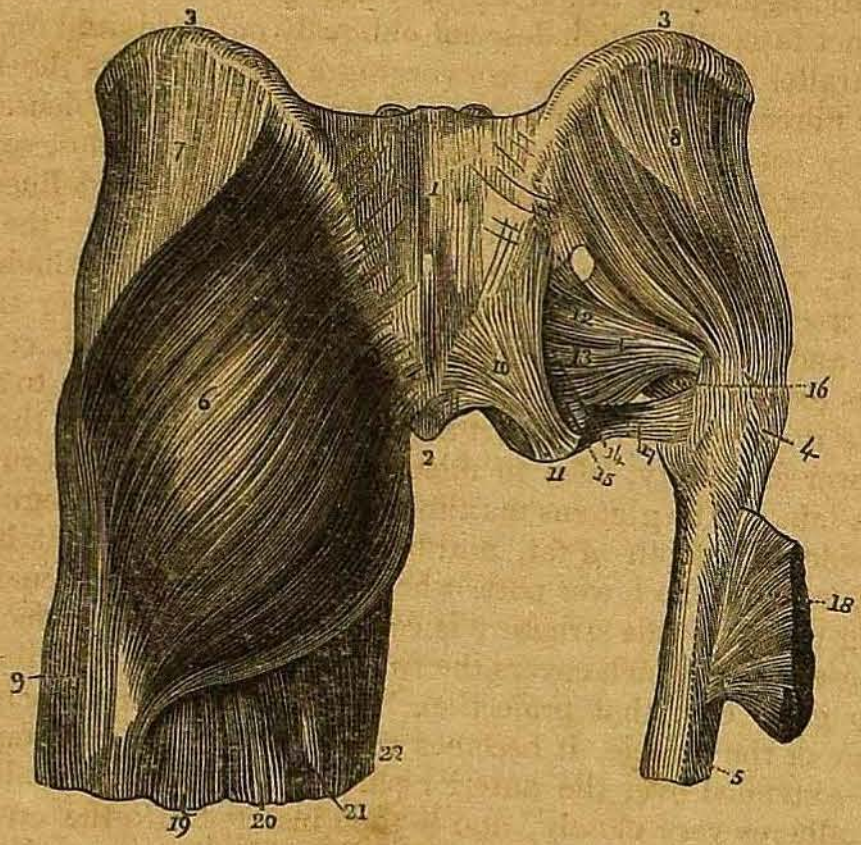


1. GLUTÆUS MAXIMUS covers the greater part of the pelvis, also the upper part of the thigh; it is somewhat square, one edge being the origin and attached to the sacrum, the opposite edge or the insertion to the femur, and to the fascia lata, the other edges are directed one upwards and forwards, the other downwards and backwards. The inferior edge is thick and round, and covered by a great quantity of fat; this forms the *fold of the nates.* It is difficult to clean the sur-

* The muscles of the hip. 1. The posterior surface of the sacrum covered by a dense aponeurosis. 2. The os coccygis. 3. 3. The crest of the ilium. 4. The external surface of the great trochanter. 5. The linea aspera of the femur. 6. The glutæus maximus muscle. 7. A portion of the glutæus medius covered by the fascia lata. 8. The same muscle on the opposite side exposed. 9. The vastus externus muscle covered by the fascia lata. 10. The great sacro-sciatic ligament. 11. The tuberosity of the ischium. 12. The pyriformis muscle. 13. The superior gemellus. 14. A portion of the obturator internus. 15. The inferior gemellus. 16. The tendon of the obturator externus. 17. The quadratus femoris. 18. The tendon of the glutæus maximus thrown down to shew its insertion. 19. The biceps femoris muscle. 20. The semi-tendinosus. 21. The semi-membranosus. 22. The gracilis muscle.

face of the glutæus maximus, its fasciculi are so coarse and rough; this may be facilitated by dissecting parallel to the fibres, that is, in a line drawn from the sacrum towards the great trochanter. This muscle *arises* by fleshy and short aponeurotic fibres from the posterior fifth of the crest of the ilium, from the rough surface between the crest and the superior semicircular ridge on this bone, from the posterior sacro-iliac ligaments and lumbar fascia, from the tubercles on the posterior surface of the sacrum, the side of the coccyx, and from the great sciatic ligaments, which last it covers; the fibres are collected into distinct fasciculi, which descend obliquely outwards and forwards, nearly parallel to each other, converging a little towards the thigh: the lower fibres are the longest, they all form a strong and dense mass, particularly below, and end in a flat and thick tendon, whose external surface is rough and coarse, but the internal smooth, and lined by a bursa which separates it from and allows it to glide over the great trochanter; this tendon is *inserted* into a rough ridge, which leads from the trochanter to the linea aspera, also into the upper third of that line, and by a tendinous expansion into the fascia lata, covering the vastus externus muscle. *Use*, to extend the thigh, also to abduct and rotate it outwards, to support and extend the pelvis and the trunk on the lower extremity, also to make tense the fascia lumborum and the fascia lata. The glutæus maximus is covered by the integuments, by a considerable depth of fat, and by a thin fascia; the fat is most abundant towards the lower part, where it forms an elastic cushion in the sitting posture; this structure is continuous with a very loose cellulo-adipose tissue, which covers the tuber ischii, and which allows the muscle to glide over that projection. As the fascia approaches the upper edge of the muscle, it becomes more strong and adherent, and is thence extended over the anterior part of the glutæus medius, to which it adheres very closely, and is then inserted into the crest and anterior spine of the ilium. The glutæus maximus covers the tuber ischii and all the muscles on the posterior part of the pelvis, except the anterior portion of the glutæus medius, which is covered by the fascia just now mentioned; its insertion into the linea aspera is above the short head of the biceps, and between the vastus externus and adductor magnus; a very large bursa lines its tendon, and is expanded over the trochanter and a portion of the vastus externus; it is very thin, it usually contains much synovial fluid, and it is frequently intersected by tendinous bands: a smaller bursa is often situated below it, between the tendons of the glutæus maximus and vastus externus.

Divide this muscle by a perpendicular incision, and separate the edges. Several muscles, vessels, &c., may be noticed, having the following relation to each other: commencing above, we see the glutæus medius muscle, beneath this the pyriformis, and between these the glutæal vessels and the superior glutæal nerve; below the pyriform muscle the great sciatic and some smaller nerves, also the sciatic and pudic vessels, all escaping from the pelvis by the lower part of the sciatic notch. Next in order are the gemini muscles surrounding the

tendon of the obturator internus; below these is the quadratus femoris, parallel to the superior fibres of the adductor magnus; the great sciatic ligament, the tuber ischii, and the superior attachment of the hamstring muscles, are all seen in this dissection, also several small arteries and veins, and a considerable quantity of loose, watery, cellular tissue, which surrounds the sciatic nerve in its course through the depression between the trochanter and tuber ischii.

2. GLUTÆUS MEDIUS, triangular, flat, thinner than the last described muscle, is exposed by dividing the glutæus maximus and dissecting off the strong fascia, which extends from its anterior edge to the crest of the ilium; *arises* by fleshy and aponeurotic fibres from the deep surface of this fascia, from the three anterior fourths of the outer edge of the crest of the ilium, from the superior semicircular line or ridge which leads from the anterior spinous process of the ilium to the upper part of the sciatic notch, and from the surface of the ilium, above and below that ridge. The fibres descend in different directions; the middle perpendicularly, the anterior, which are very short, and the posterior, which are long, obliquely; they all converge into a strong and broad tendon, which is *inserted* into the upper and outer part of the great trochanter, and is attached anteriorly to the tendon of the glutæus minimus. *Use*, to abduct the thigh; its posterior fibres can extend and rotate it outwards, its anterior fibres can flex and rotate it inwards; it also serves to maintain the pelvis in equilibrio on the femur, as when standing on one leg. This muscle is covered in part by the glutæus maximus; the anterior and larger portion is covered only by the integuments, the fascia lata, and its tensor; it lies on the glutæus minimus, its posterior edge is parallel to the pyriform muscle, and separated from it by the gutæal vessels and nerves; the anterior edge is nearly parallel to and behind the tensor vaginæ muscle, is united to it above, but separated from it below by a quantity of fat, and by several branches of the external circumflex vessels and nerves.

3. GLUTÆUS MINIMUS is exposed by detaching from its origin the glutæus medius; small, semicircular, more tendinous than the last, it *arises* from the inferior semicircular ridge on the dorsum of the ilium, and from the rough surface between it and the edge of the acetabulum; the fibres converge as they descend, and end in a strong, round, twisted tendon, which is *inserted* into the upper and anterior part of the great trochanter, first passing over a small bursa. *Use*, similar to the last; it also strengthens the ilio-femoral articulation, and as it adheres to the capsular ligament it can draw this out of the joint in abduction of the thigh. This muscle is covered by the glutæus medius, and a little overlapped by the tendon of the pyriformis; it covers the capsular ligament and the external tendon of the rectus. The six glutæi muscles are most powerful agents in maintaining the body in the erect posture, by resisting the tendency which its weight has to bend it forwards, hence these muscles are developed in man to a degree superior to any other animal.

4. PYRIFORMIS is of a flattened, triangular form, the base at the

sacrum within the pelvis, the apex at the trochanter; situated partly within the pelvis, partly behind the hip joint, nearly parallel to the posterior border of the glutæus minimus; it *arises* within the pelvis by three tendinous and fleshy fasciculi, from the anterior or concave surface of the second, third, and fourth divisions of the sacrum; it also receives a few fibres from the anterior surface of the great sciatic ligament, and from the upper and back part of the ilium; the fibres form a thick, fleshy belly, which, passing through the great sciatic notch, descends obliquely outwards and a little forwards, and is *inserted* by a round tendon into the upper part of the digital fossa, at the root of the great trochanter above the tendons of the gemini and obturator muscles, to which it is connected. *Use*, to abduct the thigh, to extend and rotate it outwards; it can also act on the capsular ligament in the same manner as the glutæus minimus. Within the pelvis this muscle lies on the sacrum, and is covered by the hypogastric vessels, the sciatic plexus of nerves, and the rectum; the sciatic nerve often perforates it near its lower margin; on the dorsum of the pelvis it is covered by the glutæus maximus, and is parallel to but not covered by the glutæus medius; it adheres to the capsular ligament, and is superior to the gemini, from which it is separated by the sciatic nerves and vessels; it divides the sciatic notch into two parts, through the superior, pass the glutæal vessels and nerves, through the inferior the sciatic and pudic vessels, the sciatic nerve, and several smaller branches of the sacral plexus of nerves. To expose the following five small rotator muscles of the hip joint, draw to either side the great sciatic nerve, and remove the surrounding loose cellular tissue.

5, 6. GEMELLI, two small muscles inferior to the last, behind the ilio-femoral articulation, and between the ischium and the trochanter; the SUPERIOR small, sometimes absent, *arises* narrow and fleshy from the spine of the ischium: the fibres pass outwards above the tendon of the obturator internus, and are *inserted* with it into the upper part of the digital fossa of the great trochanter. INFERIOR *arises* also fleshy, from the upper part of the tuber ischii, and from the great sciatic ligament, the fibres run parallel to the former, and are also *inserted* into the digital fossa. *Use*, to rotate the thigh outwards, also to abduct it, to strengthen the capsular ligament, and to confine the obturator tendon in its situation. These muscles are concealed by the glutæus maximus and the sciatic nerve; are placed between the pyriformis and quadratus femoris muscles: they form a sort of sheath around the tendon of the obturator internus, and adhere to its edges, and appear as portions of this muscle added to it as it escapes from the pelvis: the inferior is the larger of the two; the superior is inserted between the pyriformis and the obturator internus, and the inferior between the tendons of the obturator internus and externus: they both adhere to the capsular ligament.

7. OBTURATOR INTERNUS is situated partly within the pelvis and partly behind the ilio-femoral articulation; somewhat triangular, the

base within the pelvis, the apex at the great trochanter, *arises* by aponeurotic and fleshy fibres within the pelvis from the superior or pelvic surface of the obturator or thyroid ligament, and from all the circumference of the foramen of that name, except at the upper part, where the obturator nerve and vessels pass through; beneath these a ligamentous arch is extended, and from this some fibres of this muscle proceed; it also arises from the pubis internally, from the ischium inferiorly, and from the thin but strong fascia of the same name which covers it, and separates it from the levator ani muscle; the fibres descend obliquely outwards and backwards, converging towards the lesser sciatic notch, which is between the spine and the tuberosity of the ischium; the fibres here end in a flat tendon, which, turning outwards, winds round the cartilaginous pully-like surface which the ischium presents; a loose bursa, and one, in general containing a quantity of synovia, is interposed between it and the bone; the tendon now runs outwards on the dorsum of the pelvis, between the gemini, and is *inserted* into the digital fossa of the great trochanter. *Use*, to abduct and rotate the thigh outwards; it may also act on the capsular ligament. This muscle within the pelvis is covered by the peritonæum, the pelvic fascia, levator ani muscle, and by a strong aponeurosis, the obturator fascia, which serves to give origin to some fibres both of this and of the levator ani muscles, between which it is interposed; it is the external layer of the pelvic fascia, adheres superiorly to the ilium and pubis, and inserted inferiorly into the great sciatic ligament, into the tuberosity and ramus of the ischium, also into the ramus of the pubis, and is continuous with the triangular ligament of the urethra; it is closely connected to this muscle; inferiorly the internal pudic nerve and vessels partly intervene, and are partly enclosed in the tissue itself (pages 308, 319). As the obturator tendon is passing through the sciatic notch, its deep surface is divided into four or five distinct tendons, which are lined by the synovial membrane, and connected to each other like so many plaits or folds; the pudic vessels lie external to the tendon in this situation; the continuation of the tendon to its insertion has the same relations as the gemini muscles.

8. Quadratus Femoris, *arises* by fleshy and aponeurotic fibres from the external surface of the tuber ischii, anterior to the tendon of the semi-membranosus; the fibres pass transversly outwards, and are *inserted* tendinous and fleshy into the inferior and posterior part of the great trochanter, and into the posterior inter-trochanteric line. *Use*, to adduct and rotate the thigh outwards: this muscle is covered by the glutæus maximus and sciatic nerve; its origin is also concealed by the hamstrings; it is parallel to and between the gemini and the adductor magnus; its lower border is overlapped by the latter; it covers the obturator externus, the lesser trochanter, and the insertion of the psoas and iliacus. Divide this muscle, and a little dissection will expose the following, particularly if the gracilis, adductor, and pectinæus muscles have been previously removed.

9. Obturator Externus, situated at the superior, posterior, and internal part of the thigh, somewhat triangular or pyramidal, the base towards the pubis, the apex at the trochanter; *arises* fleshy from the inferior surface of the thyroid or obturator ligament, and from the surrounding surface of the pubis and ischium, the fibres descend obliquely outwards and backwards behind the neck of the femur, in a sort of notch or grooved pulley between the tuber ischii and the edge of the acetabulum; here they end in a strong tendon, which ascends a little behind the neck of the femur, then runs directly outwards along the inferior gemellus, and, adhering to the capsular ligament, is *inserted* into the lower part of the digital fossa. *Use*, to adduct the thigh, and to rotate it outwards; it also supports and strengthens the inferior and posterior part of the ilio-femoral articulation, particularly in abduction of the thigh. This muscle is placed in a very deep situation, being covered anteriorly and inferiorly, by the adductor brevis and pectinæus, also by the obturator nerve and vessels, internally by the adductor muscles, externally by the joint, and posteriorly by the quadratus femoris and glutæus maximus.

The several small muscles just described, in addition to their individual actions, effect the common purpose of strengthening the ilio-femoral articulation. The capsular ligament of this joint is covered anteriorly by the rectus, psoas, and iliacus; internally by the pectinæus and obturator externus; externally by the tendon of the rectus, the glutæus minimus and medius; posteriorly by the pyriform, gemini, obturator tendons, quadratus femoris, and glutæus maximus; and inferiorly by the tendon of the obturator externus. Many of these muscles, like the small capsular muscles of the shoulder joint, guard against dislocation in the different motions of the limb, and also serve to protect the capsular ligament by drawing it out of the angle which is formed between the acetabulum and the neck of the femur in the rotatory motions of the thigh; in the extended state of the limb, they chiefly act as rotators outwards, but in its flexed state they are abductors; when standing on one leg, which thus becomes fixed, they can rotate the pelvis and the trunk to the opposite side.

In dissecting the foregoing muscles, several vessels and nerves must have been remarked; the former are derived from the hypogastric or internal iliac vessels; the latter from the sacral plexus of nerves; the arteries are the glutæal, sciatic, and pudic. The *glutæal* artery escapes through the upper part of the sciatic notch, above the pyriform muscle, and immediately divides into several branches; these are distributed to the three glutæi muscles. The *sciatic artery* passes out of the pelvis through the lower part of the great sciatic notch, below the pyriformis; its principal branches descend between the tuber ischii and the great trochanter, and are lost in the surrounding muscles. The *pudic artery* escapes from the pelvis along with the last described vessel; it soon, however, re-enters the cavity through the lesser sciatic notch, and pursues its course forwards and inwards towards the perinæum and pubis, lying at first on the internal surface

of the obturator internus, and afterwards on the rami of the ischium and pubis; its branches are distributed to the external organs of generation, and to the muscles in the perinæum. (*See* Anatomy of the Vascular System). Each of these arteries has its corresponding vein, which takes a similar course, and terminates in the internal iliac vein. The nerves which are found in this situation are the superior and inferior glutæal, the posterior cutaneous, the pudic, the great and lesser sciatic; these are all branches of the sacral plexus, except the *superior glutæal nerve*, which is a branch of the lumbo-sacral, it accompanies the glutæal artery, and is distributed principally to the glutæus medius and minimus muscles. The *inferior glutæal nerve* escapes below the pyriform muscle, and is distributed principally to the glutæus maximus. The *inferior* or *lesser sciatic nerve* accompanies the last through the sciatic notch, descends obliquely inwards round the tuber ischii, and is distributed to the surrounding muscles and integuments. The *posterior cutaneous nerve* also passes through the lower part of the great sciatic notch, descends beneath the glutæus maximus, and then, becoming cutaneous, divides into several long branches, which may be traced along the posterior surface of the thigh, even to the leg, where in general they will be found to communicate with the posterior cutaneous nerves of that region. The *pudic nerves* take the same course as the pudic artery, and terminate in corresponding branches. The *great sciatic* or *posterior crural nerve* is the largest nerve in the body; it passes out of the pelvis below, but often through the pyriform muscle; descends behind the hip joint in the fossa between the trochanter and tuber ischii, covered by the glutæus maximus, and passing over the gemini, obturator, and quadratus muscles; its course along the back of the thigh, and its branches, shall be considered after the dissection of the following muscles.

## SECTION V.

### DISSECTION OF THE MUSCLES ON THE BACK PART OF THE THIGH.

THE fascia in this situation has been already noticed; the muscles are only three in number, and are commonly called hamstrings; the semi-tendinosus and semi-membranosus form the inner, the biceps the outer hamstring.

BICEPS FLEXOR CRURIS consists of a long and short head: the LONG HEAD *arises* from the outer and back part of the tuber ischii and rather above it, in common with the semi-tendinosus; this descends obliquely outwards, and soon ends in a thick fleshy belly; about the inferior third of the thigh it joins, at an acute angle, the SHORT HEAD, which *arises* fleshy from the linea aspera, between the

vastus externus and the adductors, commencing below the insertion of the glutæus maximus, and continuing to within two inches of the external condyle; here the muscle ends in a strong tendon, which descends at first behind the knee, then turns forwards and outwards towards the head of the fibula, into which it is *inserted;* the tendon is here divided in general by the external lateral ligament into two fasciculi, the superficial of which, in addition to its attachment to the head of the fibula, is also inserted into the fascia of the leg; and the deep fasciculus, which is also inserted into the fibula, sends some fibres to the head of the tibia. *Use*, to flex the knee-joint, also, by its long head, to extend the thigh and rotate the whole limb outwards; the long head can also fix the pelvis, prevent it and the trunk from bending forwards on the head of the femur, raise the body when bent, and maintain the erect posture. The superior fifth of this muscle is concealed by the glutæus maximus, the remainder is covered by the integuments and fascia, and descends between the vastus externus and semi-tendinosus, forming the outer hamstring; the long head passes over the semi-membranosus, the sciatic nerve, and the triceps muscles; it also conceals the short head: inferiorly the biceps passes over the external articular vessels and the external head of the gastrocnemius muscle.

2. SEMI-TENDINOSUS, large, flat, and fleshy above, round and tendinous below, *arises* by fleshy fibres from the tuberosity of the ischium in common with the long head of the biceps, also from the inner or anterior edge of the tendon of the latter for about three inches; it descends obliquely inwards, and about four inches above the knee it ends in a long round tendon, which, passing behind the head of the tibia, is then reflected forwards between the tendon of the semi-membranosus and the internal head of the gastrocnemius, and is *inserted* into the anterior angle of the tibia below its tubercle, inferior and posterior to the tendons of the gracilis and sartorius, to which it is connected: from the convex edge of the tendon an aponeurosis is given off, which joins the fascia of the leg. *Use*, to flex the knee and rotate the leg inwards, to extend the thigh, to support the pelvis, and prevent the trunk bending forwards This muscle is covered superiorly by the glutæus maximus; the rest of its course is superficial; a transverse aponeurotic line usually intersects it about its centre.

3. SEMI-MEMBRANOSUS, beneath the semi-tendinosus, flat and aponeurotic superiorly, thick and fleshy in the middle, round and tendinous below; *arises* by a flat tendon from the upper and outer part of the tuber ischii; this descends obliquely inwards, ends in a fleshy belly, which retains the muscular structure lower down than either of the former muscles; a little above the knee it ends in a round tendon, which passes behind the internal condyle, and divides into three processes, one of which passes outwards, another downwards, and a third forwards; the first is a broad aponeurosis, which ascends obliquely outwards, beneath the heads of the gastrocnemius muscle, over the back part of the knee-joint, and is *inserted* into the external

condyle of the femur; this aponeurosis has been termed the *posterior ligament* of the knee-joint, or the *ligament of Winslow;* the second is a strong and broad fascia, which descends over the popliteus muscle, and is inserted into the posterior part of the heads of the tibia and fibula, and is also continuous with the deep fascia of the leg; the third process appears the continuation of the tendon, turns forwards beneath the internal lateral ligament, round the head of the tibia, into which it is *inserted.* *Use,* to extend the thigh on the pelvis, and to support the latter on the thigh, to flex the knee and to rotate the leg inwards; it also strengthens the back part of the knee, and can draw the synovial membrane out of the angle of the joint. This muscle, at its origin, lies external to the other hamstrings; covered at first by the semi-tendinosus, biceps, and glutæus maximus, inferiorly it is superficial; above it passes over the quadratus femoris and adductor magnus muscles; below it overlaps the popliteal vessels, and the internal head of the gastrocnemius, from which last it is separated by a bursa: the sciatic nerve is on its outer, the gracilis on its inner side.

The arteries which are met with in the dissection of these muscles are branches of the sciatic, circumflex, perforating, and articular; the numerous ramifications of these vessels are distributed to the hamstring and adductor muscles, and are accompanied by their corresponding veins: the principal nerve in this situation is the *great sciatic;* from the back part of the hip joint, this large nerve descends along the back of the thigh to the upper part of the popliteal space, where it divides into the peronæal and posterior tibial nerves; in this course it is covered at first by the glutæus maximus, afterwards by the biceps and semi-tendinosus, and inferiorly by the integuments and fascia; having passed over the quadratus femoris and the other small muscles at the back of the hip joint, it next lies on the adductor magnus, and inferiorly on a quantity of adipose substance. The sciatic nerve gives off several cutaneous and muscular filaments, in addition to its two terminating branches, the peronæal and the posterior tibial; the *peronæal nerve* takes the course of the biceps tendon towards the head of the fibula, where it divides into several branches which are distributed to the integuments and muscles on the outer and forepart of the leg, as will be described in the dissection of that region. The *posterior tibial nerve* accompanies the popliteal vessels through the space of that name, which space the student should next examine.

The *popliteal space* is situated behind the knee-joint, extending upwards for about one-fourth of the thigh, and downwards for about one-sixth of the leg; it is somewhat oval, is bounded internally by the inner hamstring, and the internal head of the gastrocnemius; externally by the biceps, external head of the gastrocnemius, and plantaris; it is covered by the integuments and by a strong fascia, which, derived from the fascia lata, is strengthened by adhering to the condyles of the femur, and to the adjoining tendons; this fascia serves to approximate the sides of this region, and thus to give to it a consider-

able depth. The popliteal space is bounded before by the flat surface of the femur, by the back part of the joint covered by the ligament of Winslow, by the head of the tibia, and by the popliteus muscle and its fascia. In this region are contained the terminating branches of the sciatic nerve, the popliteal artery and vein, with their branches, also some lymphatic glands and much adipose substance. The nerves are superficial and external to the vessels, that is, nearer to the biceps; the vessels are close to the bone, and near to the semi-membranosus muscle, the vein being superficial, and a little to the outer side of the artery; two or three lymphatic glands are connected to the latter; and a quantity of fat, which is of a peculiar soft consistence, intervenes between the nerve and vessels. The course of the peronæal nerve has been already noticed. The *posterior tibial nerve* descends nearly vertically between the hamstring muscles and the heads of the gastrocnemius, and then runs beneath the solæus, and over the poplitæus; above it lies to the outer side of, and at some distance from, the artery, but below it is in close contact with it, and to its tibial or inner side; it then accompanies the posterior tibial vessels down the leg, and along the inner side of the heel, to the sole of the foot, in which course it shall be examined afterwards. In the ham this nerve sends off muscular branches, also the *posterior* or *external saphenus nerve*, which accompanies the posterior saphena vein along the back of the leg, towards the outer ankle, behind which it passes to the external and superior part of the foot, where it is distributed: this nerve is by some called "communicans tibialis." The *popliteal artery* descends obliquely outwards through this space, and at the lower edge of the poplitæus muscle divides into the anterior and posterior tibial arteries; in this course it sends off many muscular and five articular branches; the latter supply the ends of the bones and the synovial membrane of the knee-joint. The *popliteal vein* accompanies the artery, lying superficial and somewhat external to it; it receives branches which correspond to those of the artery, and it is joined inferiorly by the lesser or posterior saphena vein. Next proceed to the dissection of the leg.

## SECTION VI.

### DISSECTION OF THE LEG.

REMOVE the integuments of the leg and foot; on the plantar surface of the latter they are always remarkably hard and thick, even in the fœtus, particularly beneath the heel and the first and last joints of the toes: in these situations, also, the subcutaneous fat has a peculiar granulated structure, being intersected by tendinous bands, which pass from the skin to the plantar fascia. Beneath the integuments of the leg we find two cutaneous veins, the internal and external saphena;

the *internal saphena* is large and regular, and has numerous branches; it commences by small veins from the upper surface of the toes, and from the dorsum of the foot; these run towards the inner malleolus, and unite in one large vessel, which ascends along the inner side of the leg, receiving in its course numerous branches from the integuments; it then passes behind the inner condyle of the femur, and, ascending along the inner and anterior part of the thigh, terminates in the femoral vein about an inch and a half below Poupart's ligament. On the thigh this vein is accompanied by small nerves, which are derived from the lumbar plexus and from the anterior crural; along the leg the saphenus nerve, a branch of the anterior crural, is attached to it, and winds round it. The *posterior* or *external saphena vein* commences behind the external ankle from the junction of several small veins from the integuments of the heel and the sole of the foot; it ascends along the surface of the gastrocnemius muscle, accompanied by the communicans tibialis nerve. At the ham this vein in general joins the popliteal vein, but sometimes it here turns inwards and joins the internal saphena vein, with which it always communicates in its course along the leg. Several cutaneous nerves are distributed to the leg, namely, the internal saphenus from the anterior crural, the posterior saphenus or communicans tibialis from the posterior tibial, and several cutaneous branches from the peronæal and anterior tibial nerves, which perforate the fascia of the leg on its outer and anterior part, and are distributed to the integuments of the leg and foot.

The *fascia* of the leg is derived partly from the fascia lata of the thigh; it also receives additional fibres from the tendons around the knee joint, namely, the rectus and vasti anteriorly; the vastus externus and biceps externally; the sartorius, gracilis, and inner hamstring internally; it adheres to the head of the tibia and fibula, to the spine of the tibia, near its whole length, to the annular ligaments of the ankle joint, and to the malleoli; it can scarcely be said to exist on the anterior surface of the tibia, which is only covered by the skin and periosteum: it is stronger superiorly than inferiorly. Near the ankle it again increases in strength from its connexion to the malleoli and to the annular ligaments; these are three in number, anterior, internal, and external. The *anterior annular ligament* is a little above the joint; it is somewhat square, and stronger externally than internally; in the latter situation it is attached to the malleolar process of the tibia and to the os naviculare; in the former to the external malleolus, and to the upper part of the os calcis; it consists of two layers, which, by separating and re-uniting, form three rings or sheaths for the tibialis anticus and the two extensor tendons; the anterior tibial vessels and nerves also pass beneath it. The *internal* is broader than the anterior; it is attached to the internal malleolus and to the os calcis, forms a sort of arch over the groove or canal in which the three flexor tendons and the plantar nerves and vessels run. The *external*, short and narrow, is attached to the end of the external malleolus and to the os calcis; it binds down the peronæal tendons. The fascia of

the leg is thin posteriorly; near the heel it is indistinct: on either side it is connected to the sheaths of the tendons that pass round the malleoli; and on each side of the tendo Achillis it sends in a lamina to join the fascia which covers the deep muscles of the leg, and which will be noticed presently: it serves to confine the muscles in their situation, and to give origin to many of their fibres, to which, therefore, it adheres above, but not below; this last effect is further accomplished by intermuscular bands or septa, which pass in from the fascia, between the extensor and peronæi muscles, attached to the tibia, fibula, and interosseous ligament. From the anterior annular ligament a thin fascia is extended over the dorsum of the foot; that covering the sole of the foot, *the plantar fascia*, is remarkably strong; it *arises* from the extremity of the os calcis, narrow, but thick and strong; passes forwards, expands, and divides into three parts, which lie on different planes, and which, by sending in two processes, serve to separate the plantar muscles into three orders, the internal, middle, and external; the lateral portions are attached to the sides of the tarsus and metatarsus; the internal portion is the weakest: the middle division is the strongest, and on a plane inferior to the internal. As this middle portion expands beneath the plantar muscles, it is strengthened by transverse fibres, and near the base of the toes it divides into five fasciculi; these diverge, and opposite the head of each metatarsal bone subdivide into two fasciculi, which pass along the sides of the metatarso-phalangal articulations, and are *inserted* into the lateral ligaments of these joints, and into the sheaths of the flexor tendons; between these fasciculi the tendons pass, also the digital vessels and nerves of each toe. The plantar fascia possesses the same strength as ligamentous structure. *Use*, it serves to retain the arched form of the foot, and to protect the plantar muscles, vessels, and nerves, from pressure; it also gives attachment to several muscular fibres. The skin and areolar tissue are directly connected to the fascia of the leg and foot, so that no distinct superficial fascia exists between them. The muscles of the leg may be divided into anterior, external, and posterior.

## SECTION VII.

### DISSECTION OF THE MUSCLES ON THE ANTERIOR AND EXTERNAL PART OF THE LEG.

THE muscles on the forepart of the leg are four in number, viz., the tibialis anticus, extensor pollicis, extensor communis, and peronæus tertius. The muscles on the outer side of the leg are the peronæus longus and brevis. Almost all these muscles are connected to each other superiorly, so that they cannot be perfectly separated from

each other; they all adhere to and partly arise from the fascia of the leg; therefore, when exposed, they present a rough surface superiorly.

1. Tibialis Anticus, on the outer side of and next the tibia, somewhat triangular, large and fleshy above, tendinous below, *arises* tendinous and fleshy from the outer part of the two superior thirds of the tibia, from the head of the fibula, from the inner half of the interosseous ligament, from the fascia of the leg, and from the intermuscular septa. The fibres descend obliquely inwards, end in a strong and flat tendon which crosses from the outer to the forepart of the tibia, runs through a distinct ring in the annular ligament, near the internal malleolus, passes forwards and inwards above the astragalus and naviculare, increases in breadth, and is *inserted* into the inner side of the great or internal cuneiform bone, also by a tendinous slip into the base of the first metatarsal bone, or that of the great toe. *Use*, to flex the ankle, to adduct the foot, and to raise its inner edge from the ground; to turn the toes inwards, also to support the leg when standing, and prevent it bending backwards. This muscle is superficial through its whole length; the tendon, at its insertion, is partly concealed by the abductor and flexor pollicis brevis; superiorly it is external to the tibia, inferiorly it is anterior to it: the extensor communis and extensor pollicis, the anterior tibial vessels and nerve are to its outer or fibular side; a small

*Fig.* 61.*

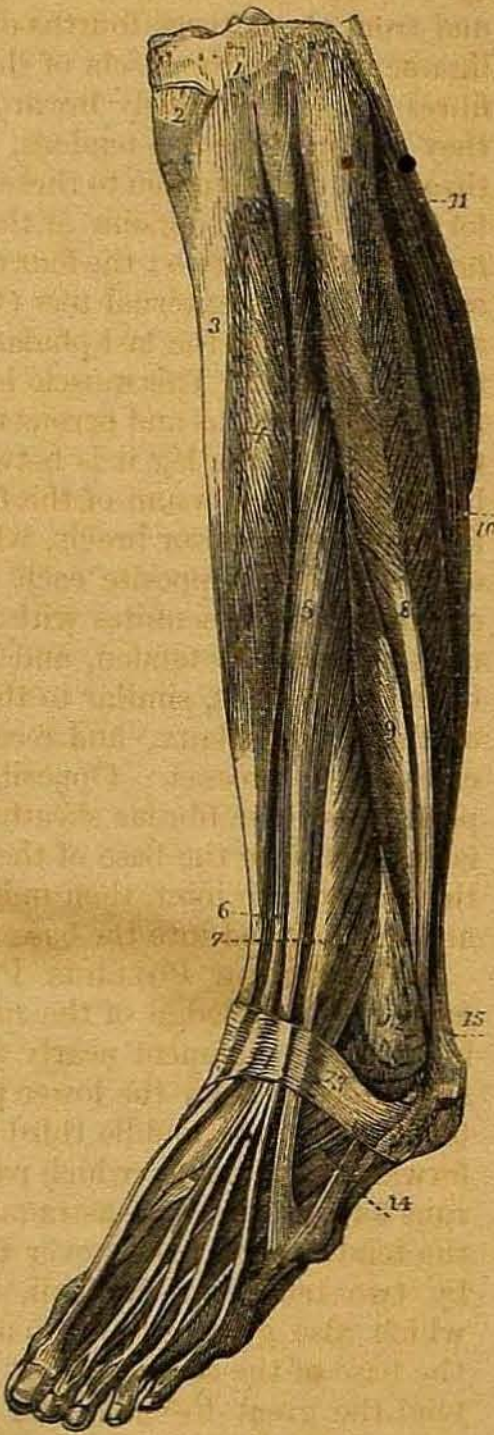


* The muscles of the anterior and external part of the leg. 1. The superior extremity of the tibia. 2. A portion of the ligamentum patellæ. 3. The subcutaneous surface of the tibia. 4. The tibialis anticus muscle. 5. The extensor digitorum longus. 6. The extensor pollicis proprius. 7. The peronæus tertius. 8. The peronæus longus. 9. The peronæus brevis. 10. A portion of the solæus muscle. 11. Edge of the gastrocnemius muscle. 12. The external malleolus. 13. The anterior annular ligament of the tarsus. 14. The extensor digitorum brevis. 15. The tendo Achillis.

bursa separates its tendon from the upper part of the internal cuneiform bone; another bursa in general surrounds it as it is passing over the synovial membrane of the ankle joint.

2. Extensor Digitorum Longus *arises* tendinous and fleshy from the external part of the head of the tibia, from the head of the fibula, and from about three-fourths of this bone, from part of the interosseous ligament, from the fascia of the leg, and its intermuscular septa; the fibres descend obliquely inwards; a little below the middle of the leg they end in three flat tendons, which pass under the annular ligament through a ring common to these and to the peronæus tertius, and extend forwards over the dorsum of the foot, the internal of the three tendons here divides into two: the four tendons now extend along the dorsum of each of the four external toes (the great toe does not receive any), and are *inserted* into the last phalanx of each. *Use*, to extend the toes and flex the ankle. This muscle is superficial; superiorly, it lies between the tibialis anticus and peronæus longus, and is connected to both. In the middle of the leg it is between the extensor pollicis and peronæus brevis; on the dorsum of the foot its tendons cross at an acute angle those of the extensor brevis, which separate the former from the bones of the tarsus. Opposite each of the four metatarso-phalangal joints one of its tendons unites with the inner border of the corresponding deep or accessory tendon, and both expand into the dorsal aponeurosis of the toe. This, similar to that upon the fingers, covers the dorsum of the first phalanx, and receives additional fibres from the lumbricales and interossæi. Opposite the joints between the first and second phalanges these fibrous sheaths divide into three fasciculi; the middle is inserted into the base of the second phalanx, the lateral pass over the sides of the joint, then unite on the dorsum of the second phalanx, and are inserted into the base of the last.

3. Extensor Pollicis Proprius *arises* tendinous and fleshy from the inner edge of the middle third of the fibula, and from the interosseous ligament nearly as low down as the ankle; a few fibres also proceed from the lower part of the tibia; its origin seldom extends above the middle third of the leg; the fibres descend obliquely forwards to a tendon which passes beneath the annular ligament, then runs forwards over the astragalus, navicular, and cuneiforme internum; the tendon next passes over the first metatarsal bone, and is *inserted* by two tendinous fasciculi, one into the base of the first phalanx, which also gives off an expansion on either side, and the other into the base of the second or last phalanx of the great toe. *Use*, to extend the great toe and flex the ankle; it may also adduct the foot, and rotate it inwards, and both this and the former muscle may, from the obliquity of their course, turn the toes outwards, and slightly raise the inner border of the foot. The upper and middle portions of this muscle are overlapped and concealed by the tibialis anticus and extensor communis, between which muscles it is situated; its tendon is superficial; the anterior tibial nerve and vessels separate it from the tibialis anticus above, and from the extensor communis

below; it lies on the fibula and interosseous ligament above; inferiorly it crosses over the tibial vessels, the synovial membrane of the ankle joint, and bones of the tarsus; on the foot it crosses superficially the extensor brevis, and is on the inner side of the dorsal artery of the foot.

4. PERONÆUS TERTIUS, or anticus, appears to be a portion of the extensor communis, and in some cases cannot be separated from it; it *arises* from the anterior surface of the lower half of the fibula; the fibres pass forwards to a tendon which descends, along with that of the extensor communis, beneath the annular ligament; it then passes forwards and outwards, and is *inserted* broad and thin into the base of the fifth metatarsal bone, and it frequently sends a band of fibres to join the fourth tendon of the extensor communis. *Use*, to extend the little toe, to flex the ankle, to abduct the foot and raise its outer edge. This muscle is sometimes wanting, an additional tendon from the extensor communis will then supply its place; it is superficial; on the foot it conceals the extensor brevis, which may be next examined.

EXTENSOR DIGITORUM BREVIS, is the only muscle situated on the upper surface of the foot; it *arises* tendinous and fleshy from the upper and anterior part of the os calcis, in front of the groove for the peronæus longus, also from the cuboid bone, the astragalus, and the annular ligament; it forms a flat, fleshy belly, which passes forwards and inwards, divides into four fasciculi, which soon end in four tendons, of which the two internal are the strongest; the little toe does not receive any; these tendons are *inserted* thus: the first or most internal into the base of the first phalanx of the great toe, passing beneath its long extensor at an acute angle, and crosses the dorsal artery of the foot as it is about to sink between the first and second metatarsal bones; the three other tendons join the outer edge of the corresponding tendons of the extensor digitorum longus, and assist in forming the aponeurosis which covers the dorsum of each toe. *Use*, to extend the toes and rotate the anterior part of the foot outwards. This muscle is partly concealed by the tendons of the long extensor and peronæus tertius; it projects, however, behind and between them; the tendons cross the metatarsal bones and the interossei muscles, beneath and in a different direction to the long extensor tendons, and as their obliquity is contrary to that of the latter, the combined action of both is to extend the toes directly: as the extensor tendons run in a more direct manner from the wrist joint to their insertion, there is no obliquity to correct, therefore there is no analogous muscle to this on the dorsum of the hand.

The muscles on the outer part of the leg are the two peronæi.

1. PERONÆUS LONGUS, *arises* tendinous and fleshy around the head of the fibula, and from the adjacent surface of the tibia, from the upper half of the external angle of the fibula, from the fascia and intermuscular septa, the fibres descend obliquely backwards and outwards, end in a strong, flat tendon, which passes behind the external malleolus, through a grove in the lower end of the fibula, in which it is bound down by a strong aponeurosis, lined by a synovial mem-

brane; it then passes forwards, downwards, and inwards, through a similar groove in the os calcis and cuboid, in each of which it is secured by a synovial membrane, and a very strong fibrous sheath; in the cuboid groove it is much thickened, and generally has a sesamoid bone or cartilage developed in it; it next passes across the sole of the foot, above the plantar muscles, obliquely inwards and forwards, towards the metatarsal bone of the great toe, into the outer side of which, and of the adjacent sesamoid bone, it is *inserted;* also, into the internal cuneiform, and into the base of the second metatarsal bone. *Use*, to extend the ankle joint, turn the foot outwards, and raise its outer edge, also to press the great toe against the ground as in walking; in the leg this muscle is superficial, and is situated between the extensor communis anteriorly and the solæus and flexor pollicis posteriorly, separated from both by aponeurotic septa; in the sole of the foot it is above all the muscles there, and cannot be seen until these are removed.

2. Peronæus Brevis, *arises* fleshy from the outer and back part of the lower half of the fibula, and from the intermuscular septa; the fibres descend obliquely, end in a tendon which passes behind the external malleolus in the same groove as the peronæus longus; it then passes forwards through a distinct groove in the os calcis, above the peronæus longus, and is *inserted* into the base of the metatarsal bone of the little toe, and into the os cuboides. *Use*, similar to the last. This muscle *arises* between the extensor longus and peronæus longus, and descends between the peronæus tertius and the flexor pollicis longus, and partly concealed by the peronæus longus; it continues fleshy lower down than it, and projects on either side of its tendon; it is separated from the peronæus tertius by the external malleolus; in the groove in the latter it is beneath the long peronæal tendon, that is, nearer to the bone, but on the os calcis it is superior to it; an aponeurosis sometimes unites its insertion to that of the extensor tendon of the little toe. When the fibula is fractured near its malleolus, these two muscles, by raising the outer edge of the foot and turning its sole outwards, frequently dislocate the foot outwards, or the ankle, that is the astragalus, inwards: in a sprain or twisting of the ankle, these two tendons sometimes burst their sheath, are displaced, and lie in front of the malleolus, their action is then somewhat changed, and they become flexors of the ankle as well as abductors of the foot.

In the dissection of the foregoing muscles we meet with the anterior tibial vessels and their branches; also the peronæal nerve and its divisions. The *anterior tibial artery* is a branch of the popliteal; it passes forwards between the solæus and popliteus, perforates the interosseous space, surrounded by some fibres of the tibialis posticus; it then descends obliquely inwards and forwards as far as the cleft between the first and second metatarsal bones; in its course down the leg it is placed at first between the tibialis anticus and extensor communis, in the middle of the leg between the former and the extensor

pollicis, and inferiorly between the tendon of the latter and that of the extensor communis; above it lies on the interosseous membrane, below it passes over the tibia, the synovial membrane of the ankle joint, the astragalus, navicular, and cuneiform bones, and beneath the annular ligament and the internal tendon of the extensor digitorum brevis; in the leg the anterior tibial artery sends off, first, the recurrent branch, which ascends on the outer and forepart of the head of the tibia, and meets the external articular arteries; second, in its course along the leg, several muscular branches; third, near the ankle, the two malleolar branches, of these, the external is the larger, and inosculates with a small artery (the anterior peroneal) which perforates the interosseous ligament about two inches above the ankle joint; on the tarsus, the anterior tibial artery, or, now called, dorsal artery of the foot, sends off the tarsal and metatarsal branches, which pass obliquely outwards, and supply the interossei muscles, the bones and joints of the tarsus and metatarsus; between the two first metatarsal bones the anterior tibial divides into the superior and inferior branch; the former supplies the integuments of the great toe; the latter passes deep towards the sole of the foot, and joins the external plantar artery; the anterior tibial artery is accompanied by two veins, which end in the popliteal vein. The *peronæal nerve* winds around the head of the fibula, perforates the peronæus longus, and divides into several branches; some of these supply the peronæal muscles, others the integuments on the outer and fore part of the leg and foot; and the continuation of the peronæal nerve passes obliquely forwards and downwards, accompanies the anterior tibial artery, lying in general superficial, and to its fibular side.

## SECTION VIII.

### DISSECTION OF THE MUSCLES ON THE BACK OF THE LEG.

These muscles are seven in number, and may be divided into a superficial and a deep layer; the former consists of three, the gastrocnemius, solæus, and plantaris; the latter of four, the tibialis posticus, flexor pollicis longus, flexor digitorum communis, and popliteus. The cutaneous nerves and veins, and the fascia, have been already noticed.

1. Gastrocnemius, large and thick, tendinous below, fleshy and aponeurotic above, and divided into two heads; both are somewhat oval, convex behind, flat before; the internal longer and larger than the external; *arises* from a digital depression on the upper and back part of the internal condyle of the femur, and fleshy from the oblique ridge above it, behind the insertion of the adductor magnus, and on a plane posterior to the external head, which is not so long or so large,

and which *arises* in the same manner above the external condyle from a pit above the groove for the popliteus tendon. The fibres of each descend converging, and form two fleshy bellies, which unite a little below the knee in a middle tendinous line, and form the calf of the leg; the inner head constituting the larger portion. About the middle of the limb the muscle ends in a broad and flat tendon, which gradually unites with that of the solæus underneath, and both form the strong tendon called *tendo Achillis*, which is *inserted* into the lower and back part of the os calcis. *Use*, to extend the ankle joint, and thus, by raising the heel from the ground, to lift the weight of the whole body, and throw it forwards on the toes, as in progression; to flex the knee joint, also to secure this articulation against displacement, by preventing the condyles of the femur slipping backwards off those of the tibia. This great muscle is superficial, a small portion of its internal head is overlapped by the semi-membranosus; its deep surface is more aponeurotic than its superficial; the lower angle of the popliteal space separates its two heads; in this angle the popliteal vessels, posterior tibial nerve, and plantaris muscle, are contained; a bursa is placed between each head and the condyle of the femur, which it covers; a sesamoid bone or tubercle often exists in each, particularly the outer; these support the condyles like strong capsules: the external head conceals the tendon of the popliteus; the internal covers the deep processes of the semi-membranosus tendon and an intervening bursa, also the insertion of the popliteus: the gastrocnemius covers the greater part of the solæus, therefore to examine the latter detach the heads of the former from the condyles, and separate it from the solæus to within two or three inches of the heel, or cut the muscle transversely about the centre, and raise the upper portion, whereby its structure will be seen. The plantaris muscle is now also exposed.

2. Plantaris *arises* fleshy from the back part of the femur, above the external condyle, and from the posterior ligament of the knee; it is connected to the external head of the gastrocnemius, forms a small, pyramidal, fleshy belly, which descends obliquely inwards, crosses the popliteal vessels, and ends in a flat tendon (the longest in the body), which descends between the gastrocnemius and solæus. When the tendons of these muscles are about to unite, that of the plantaris becomes superficial, and descends along the inner side of the tendo Achillis to the heel, and is *inserted* into the posterior part of the os calcis, a little anterior to the tendo Achillis; it has also some connexion to the plantar fascia and subcutaneous tissue. *Use*, to extend the foot, and turn it inwards, also to make tense the fascia, and to flex the knee; its origin is partly concealed by the external head of the gastrocnemius; its tendon also is at first covered by this muscle, but inferiorly it is superficial. This muscle is sometimes wanting; it may probably be considered as rudimentary rather than essential; the tendon is often found so long and loose, and even coiled, that we can scarcely suppose the muscle had been accustomed to act, at least with any force. In most animals it is better developed in proportion than in man; in the quadrumana it acts as a tensor of the plantar fascia,

and in quadrupeds it answers to the perforated flexor of the toes; but in man the great muscles of the calf preponderate over all other animals, their superior development being obviously in relation to the erect position he is destined to enjoy. In some instances the plantaris tendon is short and tense; in such the muscle may rupture it, an accident which has been noticed by surgical writers.

3. SOLÆUS, of an oval and flattened figure, consists superiorly of two heads, which are not so distinct from each other as those of the gastrocnemius; the external is longer and larger than the internal, and *arises* from the back part of the head and from the superior third of the fibula, behind the peronæus longus: the internal *arises* from the middle third of the tibia, commencing below the oblique insertion of the popliteus; the two heads are connected by a strong tendinous arch, beneath which pass the posterior tibial nerve and vessels; all the fibres descend and form a large oval belly, which continues fleshy lower than the gastrocnemius. A tendon is formed first on its superficial surface, and is gradually united to that of the gastrocnemius to form the tendo Achillis. This strong tendon is broad and thin above, narrow and depressed in the middle, and round and thick below; it is composed of strong vertical fibres, which descend behind the os calcis, over a bursa, covering a cartilaginous impression on that bone, and is *inserted* into a rough surface below that. Occasionally a small bursa is also found between it and the skin. This muscle is almost entirely concealed by the gastrocnemius; a little below the middle of the leg, however, it projects on each side of the tendon of the latter, and forms the lower calf; it covers the deep-seated muscles, vessels, and nerves. *Use*, to assist the gastrocnemius in extending the ankle, but it cannot exert any influence on the knee-joint as that muscle does. When standing, the solæus supports the leg, and resists the tendency of the body to fall forwards, while the gastrocnemii strengthen the back part of the knee joint, press the condyles forwards, and resist their tendency to rotate backwards and upwards in the superficial tibial cavities; they can also flex the knee when the anterior extensors permit, but, as they are very close to the fulcrum, their action in this respect is feeble, whereas the combined actions of these two muscles, which may be considered as one powerful triceps or quadriceps extensor pedis, and which is the largest muscle in the body, are most powerful; they are the principal agents not only in maintaining the erect posture, but also in all locomotive exertions, such as walking, running, dancing, leaping, &c.; they are peculiarly and very favourably circumstanced for the exercise of power; the lever, whereby they act, is of the second order, the toes being the fulcrum at one end; the weight, which is the body, rests upon the astragalus in the ankle joint in the middle; and the power, which is at the other hand, is represented by the insertion of the tendo Achillis into a rough projection on the lower part of the os calcis, and which insertion is perpendicular to the lever. A violent action of these powerful muscles occasionally ruptures the tendo Achillis, or tears off a fragment of the os calcis.

Detach the solæus from its origin, and the strong, deep fascia of the

leg is exposed; this fascia is partly derived from the semi-membranosus and popliteus, and partly from the more superficial fascia of the leg; it adheres to the tibia and fibula, to the solæus, and to the deep muscles: inferiorly it is strong, and connected to the sheaths of the tendons that pass behind the malleoli, and to the lateral annular ligaments of the ankle; raise it, and clean the four following muscles: popliteus, two long flexors of the toes, and the tibialis posticus; the first is confined to the region of the knee, or ham, but the other three extend along the leg into the foot, and are all reflected or bent round the inner ankle, vertical in the leg, horizontal in the foot.

*Fig. 62.**

4. Popliteus, situated obliquely at the upper and back part of the leg, bound down by a strong fascia, behind the knee, above the other muscles in this region, flat and triangular; *arises* by a round and very strong tendon from a depression on the external surface of the outer condyle, below the origin of the outer head of the gastrocnemius and of the external lateral ligament; descends obliquely inwards and backwards, above the head of the fibula, and along the external semilunar cartilage, to which it is connected by the synovial membrane of the knee, and by a few tendinous fibres; becomes broad and fleshy, and is *inserted* into a flat, triangular surface, which occupies the superior fifth of the posterior surface of the tibia. *Use*, to bend the knee, and, when bent, to twist the foot and toes inwards; it may also assist, when the limb is extended, in rotating the knee outwards: it supports the external semilunar cartilage, and moves it slightly, so as to adapt its situation to the external condyle of the femur in the rotatory motions of the joint; the popliteus is covered by the two heads of the gastrocnemius, the plantaris, the external lateral ligament, and the popliteal nerve and vessels; it is superior to the inner head of the solæus, and passes

* The deep layer of muscles on the back of the leg. 1. The lower extremity of the femur. 2. The internal condyle. 3. The external condyle of the same bone. 4. The tendon of the semi-membranosus muscle. 5. The ligamentum posticum of Winslow. 6. The external lateral ligament of the knee-joint. 7. The popliteus muscle. 8. The flexor digitorum longus. 9. A portion of the tibialis posticus. 10. The flexor pollicis longus. 11. The head of the fibula. 12. The peronæus longus. 13. The tendon of the peronæus brevis passing to its insertion into the posterior extremity of the fifth metatarsal bone. 14. The os calcis. 15. The tendon of the tibialis posticus proceeding to its insertion into the inferior tubero-

over the tibio-fibular articulation and the back part of the tibia; it is nearly parallel to the upper part of the plantaris; the tendon is nearly surrounded by the synovial membrane of the knee, but is external to its cavity; it also adheres to the membrane of the tibio-peronæal joint, and sometimes the *cul de sac*, which attends it from the former articulation, communicates with the latter so as to constitute one synovial membrane to these two articulations, as is normally the case in many animals.

5. Flexor Digitorum Perforans, longus or communis, broader in the centre than at either end; *arises* fleshy from the posterior flat surface of the tibia, commencing below the popliteus, and extending to within two or three inches of the ankle, also from the fascia and intermuscular septa. The fibres descend obliquely inwards to a tendon which passes behind the internal malleolus, in a groove in the tibia lubricated by a bursa, and in which it is confined, along with the tendon of the tibialis posticus, by the internal annular ligament, separated, however, from that tendon by a ligamentous septum; each tendon also has a distinct synovial sac; it then turns forwards and a little outwards into the sole of the foot, still confined in a bony groove, first in the astragalus, and then in the os calcis: in the sole of the foot it lies beneath the tendon of the flexor pollicis, and is connected to it by a tendinous slip. About the centre of this region it expands and receives the insertion of the accessory muscle; it then divides into four tendons, which pass to the four outer toes, and opposite the first phalanx each tendon enters a strong fibrous sheath, which is lined by synovial membrane. This sheath continues as far as the extremity of the second phalanx, and contains also the corresponding tendon of the flexor digitorum brevis. Opposite the base of the second phalanx each of the last-named tendons is slit for the transmission of the long flexor tendon, which continues to run forwards to be *inserted* into the base of the last phalanx of each of the four lesser toes. *Use*, to flex all the phalanges of the toes, also the metatarsus; to extend the ankle, and to steady the leg on the foot as when standing; the accessory muscle assists it in flexing the toes, and, by correcting its obliquity, diminishes its tendency to invert the foot when extending the ankle joint. This muscle is the most internal in this layer; in the leg it is covered by the superficial muscles, the deep fascia, and the tibial vessels; it overlaps the tibialis posticus, and is on the inner or tibial side of the flexor pollicis. A little above the inner ankle the tendon of the tibialis posticus crosses above that of the flexor communis, that is, nearer to the tibia. In the sole of the foot its direction is horizontal; it is there superior to the flexor brevis and abductor pollicis, inferior to the transversalis pedis and peronæus longus tendon. The lumbricales muscles arise from the tibial or inner sides of its tendons.

sity of the navicular bone and internal cuneiform bone. 16. The tendon of the flexor digitorum longus. 17. The tendon of the flexor pollicis longus. 18. The tendon of the peronæus longus, traversing obliquely the sole of the foot to its insertion into the base of the metatarsal bone of the great toe, &c.

6. Tibialis Posticus, larger above than below, *arises* from the posterior and internal part of the fibula, from the upper part of the tibia, from almost the entire length of the interosseous ligament, and from intermuscular septa. The fibres descend and end in a strong tendon, which passes, along with that of the last muscle, behind the internal ankle, crosses above that tendon, and then proceeds obliquely forwards and inwards, and is *inserted* into a tuberosity on the inferior and internal part of the os naviculare, and into the internal cuneiform bone; it also sends some fibres to the cuboid and to the second and third metatarsal bones. A small bony or cartilaginous tubercle is often found in this tendon, near to its insertion, beneath the head of the astragalus; it also glides over a small bursa in this situation. *Use*, to extend the ankle and to raise the inner edge of the foot from the ground. The upper end of this muscle is notched by the anterior tibial vessels; a few of its fibres accompany these vessels through the interosseous space, and are attached to the anterior surface of the ligament. In its course down the leg it is covered by the solæus, and overlapped by the flexor communis and flexor pollicis; it covers the tibia, fibula, and interosseous ligament, winds round the deltoid or internal lateral ligament, passes beneath the head of the astragalus, and supports that strong fibro-cartilage, which extends from the os calcis to the os naviculare, beneath the head of the astragalus, which elastic substance supports a great portion of the weight of the body in standing, and in progression.

7. Flexor Pollicis Longus is the most superficial and external in this plane; *arises* from the two inferior thirds of the fibula, from the fascia covering the tibialis posticus, from intermuscular septa, and, inferiorly, from a small portion of the interosseous membrane; the fleshy fibres descend obliquely inwards to a tendon which passes behind the internal malleolus through a groove, first in the tibia and next in the astragalus. Entering the sole of the foot, this tendon crosses above the flexor communis, and is connected to it by a strong tendinous slip; it then proceeds forwards and inwards, between the two portions of the flexor pollicis brevis, enters a strong tendinous sheath between the sesamoid bones, and is *inserted* into the base of the last phalanx of the great toe. *Use*, to flex this toe, to extend the ankle and adduct the foot, but in a much less degree than the common flexor. It lies to the fibular side of the tibialis posticus, between it and the peronæi muscles. The peronæal vessels are enclosed between its fibular and its internal aponeurotic origin. As it passes behind the internal ankle it is about half an inch behind the tendons of the tibialis posticus and the flexor communis, and is separated from these by the posterior tibial nerve and vessels.

# SECTION IX.

## DISSECTION OF THE MUSCLES OF THE FOOT.

THERE is but one muscle on the dorsum or on the upper surface of the foot, the extensor digitorum brevis, which has been already examined, as being an appendix to or continuation of the long extensors of the toes, which arise from the bones of the leg; the dorsal or superior interossei muscles do not properly belong to this region, and may be examined with the inferior set. The integuments and fascia in the sole of the foot have been already noticed. The muscles here are very numerous: they may be divided into four laminæ; these are tolerably distinct about the middle of this region, but at either side this arrangement is rather artificial; the two intermuscular processes of the plantar fascia also divide these laminæ into three compartments, an internal, a middle, and an external. The muscles of the first, or superficial layer, are the abductor pollicis, flexor digitorum brevis, and abductor minimi digiti: in the second layer are the long flexor tendons, the accessory muscle, and the lumbricales. The third layer consists of the flexor pollicis brevis, adductor pollicis, transversalis pedis, and flexor minimi digiti. In the fourth layer are the interossei muscles, and the tendon of the peronæus longus.

*Fig.* 63.*

ABDUCTOR POLLICIS *arises* tendinous and fleshy from the lower and inner part of the os calcis, from the internal annular ligament, the plantar aponeurosis, and internal intermuscular septum; the fibres pass forwards and inwards, and are *inserted* tendinous into the internal sesamoid bone, and into the internal side of the base of the first phalanx of the great toe. *Use*, to separate the great toe from the others; it can also flex it. This muscle is by some writers called the adductor pollicis, its action being then referred to the mesial line of the body; it is the most internal of the plantar mus-

* The first or superficial, and part of the second layer of muscles in the sole of the foot, the plantar fascia having been removed. 1. The inferior surface of the os calcis. 2. The abductor pollicis. 3. The flexor digitorum brevis perforatus. 4. The abductor minimi digiti. 5. The tendon of the flexor pollicis longus. 6. 6. 6. 6. The lumbricales. 7. One of the tendons of the flexor digitorum longus passing through the slit in the corresponding tendon of the flexor digitorum brevis.

cles, and is superficial; the fascia covering it is very thin; the long tendons and plantar vessels and nerves pass between its heads or origins from the internal malleolar region into the sole of the foot; a septum from the plantar fascia alone separates its outer border from the following muscle.

Flexor Digitorum Brevis Perforatus, short, thick, and narrow behind; *arises* from the inferior and rather from the internal part of the os calcis, from the internal annular ligament, the plantar aponeurosis, and intermuscular septa; it forms a fleshy mass, which, passing forwards, divides about the middle of the foot into four delicate muscles, which soon end in tendons; these accompany the flexor longus communis into the tendinous and synovial sheaths, beneath the phalanges of the four outer toes: each tendon is slit opposite the base of the second phalanx, and, having transmitted the long flexor tendon, is then folded out on the inferior surface of the second phalanx, and again bifurcates close to the bone, and is *inserted* into its lateral borders, above the long flexor tendon, having been previously beneath it. *Use*, to assist the long flexor, to strengthen the plantar fascia, and to preserve the arch of the foot. This muscle is immediately above the strong central portion of the plantar fascia, from which a considerable portion of it arises, therefore it always presents a rough surface when dissected; it is beneath the plantar vessels and nerves, the long flexor tendons, the accessory muscles, and the lumbricales; it is joined to the abductor pollicis posteriorly, but anteriorly is separated from it by the tendon of the flexor pollicis longus; the fourth, or the external of its tendons, or that for the little toe, is sometimes wanting. This muscle is analogous to the flexor sublimis of the fingers, but much smaller, and wants the vertical portion.

Abductor Minimi Digiti is situated along the outer edge of the foot, *arises* tendinous and fleshy from the outer side of the os calcis, and from a strong ligament which extends from this to the fifth metatarsal bone, also from the bone of the latter, from the plantar fascia, and its external intermuscular septum; *inserted* tendinous into the outer side of the base of the first phalanx of the little toe, and into the adjoining surface of the metatarsal bone. *Use*, to separate the little toe from the others, and to flex it. This muscle is also superficial; the fascia covering it is very strong; it is the most external of the muscles in this region.

Detach this first layer of muscles from their posterior attachments, and throw them forwards towards the toes; the tendons of the flexor pollicis and communis are now exposed, also the accessory muscle and the lumbricales; all these constitute the second layer of the plantar muscles, and which is partially concealed by the first.

The tendon of the flexor longus digitorum communis is seen passing from the inner side of the os calcis to the middle of the plantar region, where it divides into its four tendons, which have been already described as entering the sheaths on the inferior surface of the four outer toes, passing through the slits in the tendons of the flexor brevis,

and then inserted into the last phalanx of each toe. The tendon of the flexor pollicis longus is now also seen passing above the former, to which it is united by a tendinous fasciculus, and then proceeding forwards to its insertion to the base of the great toe.

*Fig.* 64.*

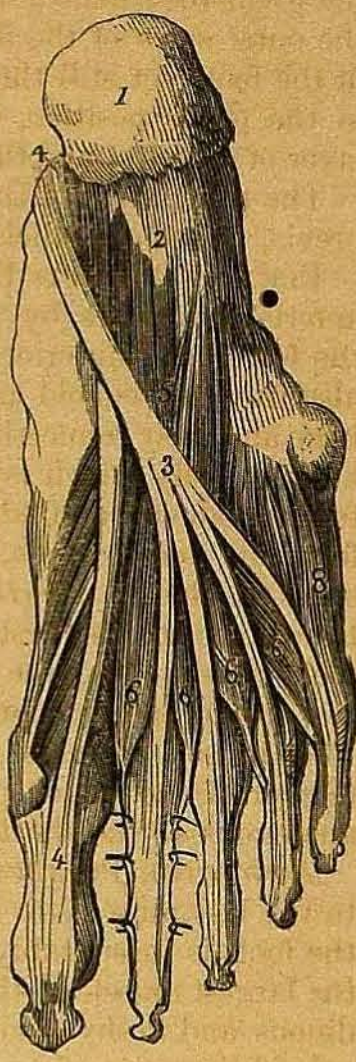


MUSCULUS ACCESSORIUS, or flexor digitorum accessorius, square, flat, and fleshy; *arises* bifurcated, fleshy and tendinous from the inferior and lateral borders of the os calcis, forms a flat and somewhat square, fleshy belly, which, proceeding forwards, is *inserted* into the upper and outer part of the tendon of the flexor digitorum longus, just before it divides; an expansion from the flexor pollicis longus also joins it, and extends to the flexor communis. *Use*, to assist the long flexor, and to counteract its obliquity by pulling it directly towards the heel. This muscle lies above the flexor digitorum brevis and the plantar vessels and nerves, and beneath the os calcis and calceo-cuboid ligaments. There is no analogous muscle to this in the hand, as there the flexor tendons pass directly over the centre of the carpus.

LUMBRICALES are four small muscles which *arise* tendinous and fleshy from the angles between the tendons of the flexor digitorum longus; there is none for the great toe: the first or the internal one is the largest. These four muscles proceed forwards along the internal edge of the long flexor tendons; each ends in a thin aponeurosis, which is *inserted* into the internal side of the first phalanx of the four lesser toes, and joins the tendinous expansion of the extensor tendons on the dorsum of the toes. *Use*, to adduct and to assist in flexing the four toes; they may also extend their second and last phalanges. These muscles are covered in the sole of the foot by the superficial layer, but emerge from beneath this and the plantar fascia in the interstices between the sheaths of the flexor tendons; their tendinous insertions are superficial, and are best seen on the dorsum of the toes. They are analogous to the four lumbricales in the hand, which also arise from the deep or perforating flexors, and run along the radial side of each tendon, or that next the

* The second and part of third layer of muscles in the sole of the foot. 1. The inferior surface of the os calcis. 2. A portion of the inferior calcaneo cuboid ligament. 3. The tendon of the flexor digitorum longus dividing into its four portions. 4.4. The tendon of the flexor pollicis longus. 5. The musculus accessorius. 6.6.6.6. The lumbricales muscles. 7. A portion of the flexor pollicis-brevis. 8. Part of the flexor brevis minimi digiti.

thumb, so in the foot they run along that side which corresponds to the great toe; hence, although they are described as running along the outer sides of the flexor tendons in the hand, and along the inner in the foot, yet still they are perfectly analogous, supposing the hand in the prone position, or the foot in the supine. Detach this second layer of muscles, and throw it also forwards towards the toes.

The third layer of the plantar muscles consists of the flexor pollicis brevis, adductor pollicis, transversalis pedis, and flexor minimi digiti.

FLEXOR POLLICIS BREVIS, narrow posteriorly, broad and notched anteriorly; *arises* by a strong tendon from the lower and anterior part of the os calcis, also from the cuboid and external cuneiform bone and their connecting ligaments; it forms a fleshy belly which is inseparably connected to the abductor and adductor pollicis; passes forwards and inwards, and divides into two short tendons; *inserted* into the sesamoid bones beneath the first phalanx of the great toe. *Use*, to flex the first joint of the great toe, also to approximate this toe to the others. This muscle forms a sort of sheath for the tendon of the flexor pollicis longus, and is analogous to the short flexor of the thumb.

*Fig.* 65.*

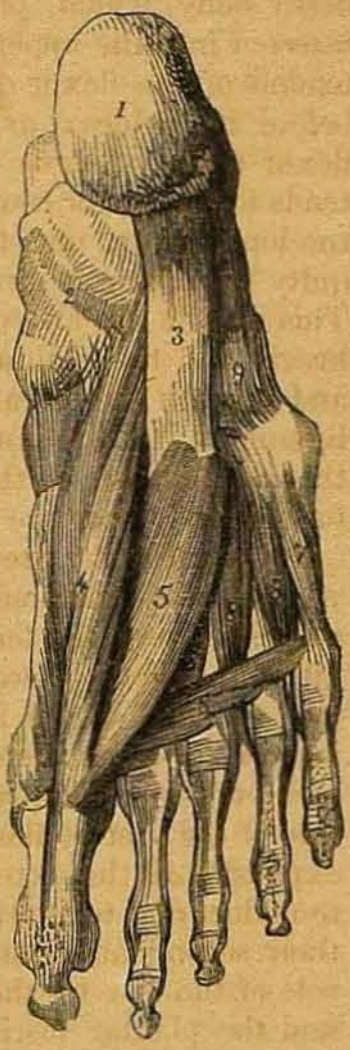


ADDUCTOR POLLICIS is situated external to the last muscle, or more in the centre of the foot, is inseparably attached to it, and is the largest muscle in this plane; it arises tendinous and fleshy from the strong calcaneo-cuboid ligament, from the sheath of the peronæus longus, and from the base of the second, third, and fourth metatarsal bones; passes forwards and inwards, *inserted* along with the external portion of the last muscle into the external sesamoid bone. *Use*, to draw the great toe outwards towards the others, also to flex it, so as to bring it beneath them. By some this muscle is named the abductor pollicis, its action being then referred to the mesial line.

TRANSVERSALIS PEDIS *arises* by distinct, fleshy slips from the anterior extremities of the four external metatarsal bones. The fibres pass inwards and forwards, converging to the external sesamoid bone of the great toe, into which they are *inserted* along with the last de-

* The third and part of the fourth layer of muscles of the sole of the foot. 1. The inferior surface of the os calcis. 2. The inferior calcaneo-scaphoid ligament. 3. The inferior calcaneo-cuboid ligament. 4. The flexor pollicis brevis. 5. The adductor pollicis. 6. The transversalis pedis. 7. The flexor brevis minimi digiti. 8. 8. 8. The inferior interossei muscles. 9. The tendon of the peronæus longus, in its sheath, passing obliquely across the sole of the foot.

scribed muscle. *Use*, to approximate the toes, and to contract the transverse arch of the foot. There is no analogous muscle in the hand, except the anterior transverse fibres of the adductor pollicis. Behind this muscle, and nearly parallel to it, the strong calcaneo-cuboid ligament is observed; also the tendon of the tibialis posticus dividing into several slips, which are inserted into the adjacent bones and ligaments.

FLEXOR BREVIS MINIMI DIGITI *arises* tendinous and fleshy from the cuboid and fifth metatarsal bone, and from the sheath of the peronæus longus tendon; it passes forwards and outwards, and is *inserted* into the inner side of the base of the first phalanx of the little toe. *Use*, to flex and adduct this toe. This muscle is connected to the abductor minimi digiti; it fills up the concavity of the fifth metatarsal bone. Detach these four muscles in this layer from the tarsus, and the fourth layer will come into view, namely, the tendon of the peronæus longus and interossei muscles; the former crosses the foot obliquely forwards and inwards from a deep groove in the cuboid, beneath the cuneiform and metatarsal bones, to be *inserted* into the internal cuneiform and into the base of the first and second metatarsal bones; in this course this strong round tendon is enclosed in a tendinous sheath, which is lined by synovial membrane, and is attached to the several projections of the adjoining bones. *Use*, to serve as a strong, transverse ligament in strengthening the tarsus and metatarsus in that direction. This course and connexion of the tendon explain the action of the peronæus longus muscle, namely, to extend the ankle joint, to elevate the external side of the foot, to depress its internal side, and to turn the point of the foot outwards.

INTEROSSEI MUSCLES are seven in number; three are seen in the sole of the foot, and four on the dorsum; they fill up the interstices between the metatarsal bones: the three inferior are named *interossei interni*, or *inferiores*, and lie rather beneath or in the concavity of these bones than between them, the interosseous space being very narrow; they *arise* tendinous and fleshy from between the metatarsal bones of the four external toes, and are *inserted* tendinous into the inner side of the extensor tendon and of the base of the first phalanx of the three lesser toes. *Use*, they are all adductors of the toes, like the palmar interossei, that is, supposing the axis of the foot to be in the line of the second toe, and not, as in the hand, through the third or middle finger; they each arise from one metacarpal bone only, from its lower surface, and from the lower part of its inner side, that which looks towards the axis of the foot, and are inserted each into the inner side of the same toe; none of them are attached to the first and second toes, but the adductor pollicis might be considered as belonging to this group. The *first* is between the second and third metatarsal bones, *arises* chiefly from the inner side of the third, and is *inserted* into the inner side of the first phalanx of the same or the middle toe; this is the *adductor medii digiti;* the *second* is between the third and fourth metatarsal bones, *arises* chiefly from the inner side of the fourth, is *inserted* into the inner side of the first phalanx of the same toe, and is the *adductor quarti digiti;* the *third* is between the fourth

and fifth metatarsal bones, *arises* from the fifth, and is *inserted* into the inner side of the little toe, and is the *adductor minimi digiti:* these three muscles might rather be called sub-interroseous muscles; they are so connected together as to appear at first as one fleshy mass, they are covered by an aponeurosis from the plantar, which separates them from the subjacent tendons and vessels.

The *interossei externi* or *superiores* are four in number, are larger than the last, and are seen on the dorsum or convex surface of the foot; like those on the hand, they are bicipital muscles, communicating branches between the dorsal and plantar vessels passing between their heads. *Use*, they are all abductors, that is, expand the toes, or separate them from the axis of the foot; the first or great toe is unaffected by them, it however has its proper abductor in the sole of the foot; the same may be said of the little or the fifth toe; the second toe or axis has one inserted into either side, which, if both act together will fix it, or they may alternately move it to either side; the third and fourth are inserted into the outer sides of the third and fourth toes, and are therefore abductors of both; all these tendons likewise join the expansion of the extensor tendons. The *first* is between the first and second metatarsal bones, and may be named the *internus digiti secundi;* it *arises* from the internal side of the second metatarsal bone, and by a distinct fasciculus from the outer side of the first; these two origins are separated by the deep branch of the anterior tibial artery, or the communicating branch between the dorsalis pedis and the external plantar; the fibres end in a tendon which is *inserted* into the inner side of the base of the first phalanx of the second toe; it also joins the corresponding extensor tendon. *Use*, to approximate the second to the great toe. The *second or externus digiti secundi* is placed between the second and third metatarsal bones; *arises* from their opposite surfaces, but chiefly from that of the former; the fibres end in a tendon which is *inserted* into the outer side of the first phalanx of the second toe. *Use*, to separate the second from the great toe. The *third or abductor digiti medii* is placed between the third and fourth metatarsal bones, and *arises* from their opposite surfaces, but chiefly from that of the third; the fibres end in a tendon which is *inserted* into the outer side of the phalanx of the third toe. *Use*, to separate the third toe from the second. The *fourth or abductor digiti quarti* is situated between the fourth and fifth metatarsal bones; it *arises* from their opposite surfaces, and is *inserted* into the outer side of the first phalanx of the fourth toe from the three internal. All these muscles are covered by the long and short extensor tendons, and by a strong aponeurosis, which binds them down between the bones, and presses them towards the plantar surface; they conceal the inferior interossei, and are separated from them by a fine fascia derived from the plantar. Both sets of interossei muscles serve to strengthen the metatarsus, and to press the metatarsal bones together; they also serve to flex the first joint of the four outer toes, but may assist in extending their last phalanges; these muscles

can exert no influence on the great toe; there is only one muscle between the two first metatarsal bones; between the others there are two, therefore there are four superior or dorsal interossei muscles, but three inferior; the latter are situated more in the concavity of each metatarsal bone than between these bones; the superior are stronger, and more tendinous than the inferior; and are only partially covered by the long and short extensor tendons.

In dissecting the muscles on the back of the leg, and those in the sole of the foot, we meet the posterior tibial vessels and nerve, and their principal branches. The posterior *tibial artery* is the larger branch of the popliteal; it descends obliquely inwards beneath the deep fascia and the superficial muscles, and over the tibialis posticus and flexor communis, to the fossa between the heel and inner ankle, it here ends in the two plantar arteries: in this course it gives off many muscular branches, also the *peronæal artery;* the latter arises from the tibial, about an inch below the poplitæus; it descends obliquely outwards along the back part of the fibula beneath the flexor pollicis longus; behind and a little above the outer ankle, it divides into the anterior and posterior peronæal arteries; the former perforates the interosseous space and joins the external malleolar artery; the latter descends between the external ankle and the heel, and is distributed to the ligaments and adipose substance in that region.

The two plantar branches of the posterior tibial artery are distributed to the muscles and integuments of the foot and toes; the *internal plantar* is the smaller of the two, it supplies the muscles along the inner side of the tarsus: the *external plantar*, the large branch, runs across the foot obliquely outwards, towards the fifth metatarsal bone, between the first and second layers of plantar muscles; from the little toe it next runs obliquely forwards and inwards, towards the first metatarsal bone, above the second layer of the plantar muscles, and between the first and second metatarsal bones it joins the deep branch of the anterior tibial artery, and thus forms the great plantar arch of arteries, from the convexity of which proceed the digital arteries, to supply the toes. (*See* Anatomy of the Vascular System.) The posterior tibial artery and its several branches are accompanied by corresponding veins, all of which end in the popliteal vein. The *posterior tibial nerve* is the principal branch of the sciatic, it accompanies the posterior tibial artery, at first lying to its tibial, afterwards to its fibular side; in this course it sends off several small branches to the deep and superficial muscles of the leg, and between the heel and ankle it divides into the two plantar nerves, which take the course of the corresponding arteries. In this internal malleolar region, when the integuments, fascia, and internal annular ligaments are removed, we find the three tendons and the posterior tibial nerves and vessels to have the following relation to each other: the tibialis posticus and flexor communis tendons are bound close to the ankle; about half an inch behind these is the posterior tibial artery, accompanied by two veins; the nerve is a little nearer to the heel; and the tendon of the flexor pollicis lies about half an inch nearer to the latter.

# INDEX.


Page.

ABDOMEN . . . . 226
deep muscles of . . 290
dissection of . . 184
vessels and nerves of . 280
Abdominal aorta . 282. 419
aponeurosis, anterior . 188
fascia, deep . . 185
fascia, superficial . 184
lymphatic glands . 449
muscles . . . 186
regions . . . 226
ring, external . . 191
ring, internal . . 205
viscera, dissection of . 226
walls, nerves in the . 214
Abducentes nerves, . 527. 533
Abductor indicis muscle . 180
minimi digiti muscle . 178
minimi digiti pedis . 397
oculi . . . 628
pollicis muscle . . 177
pollicis longus muscle 174
pollicis pedis . . 396
Aberration, chromatic . 664
from parallax . . 663
from sphericity . . 663
Absorbent system . . 446
Accelerator urinæ muscle . 309
Accessorii musculi (dorsal) 143
Accessorius muscle . . 398
Accessorius nervus . 528. 546
Acervulus . . . 486
Acetabulum . . . 766
Achilles, tendon of . . 391
Acini of Malpighi . . 269

Page.

Acromial thoracic artery . 415
Acromion process . . 786
Adipose tissue . . . 598
tissue, medullary . 599
Adductor brevis muscle . 369
longus muscle . . 369
magnus muscle . . 370
minimi digiti muscle . 178
oculi muscle . . 627
pollicis muscle . . 178
pollicis pedis . . 399
Alæ vespertilionis . . 351
Alar, cartilages of nose . 601
ligaments . . 849
Albugineal membrane of the eye . . . 629
Alimentary canal . . 238
Alveolar process . . 739
Ammonis cornu . . 485
Amphiarthrosis . . 800
Ampullæ of the mammary gland . . . 76
of semicircular canals . 681
Amygdala, or tonsil . . 52
Anal fascia . . . 307. 319
Anal region . . . 307
Anastomotica magna artery of thigh . . 426
Anastomotica artery of arm 417
Anconæus muscle . . 173
Andersch, ganglion of . 543
Angular processes of frontal bone . . . 720
Ankle, external . . 780
internal . . . 778

| | Page. |
|---|---|
| Ankle-joint . . . . | 856 |
| joint, dislocation of . | 859 |
| Annular ligament of ankle, anterior . . . . | 384 |
| ligament of ankle, external . . . . | 384 |
| ligament of ankle, internal . . . . | 384 |
| ligaments of the wrist . | 162 |
| protuberance . . | 491 |
| Annulus ovalis . . . | 111 |
| Anterior auris muscle . | 5 |
| mediastinum . . | 86 |
| Anticubital fossa . . | 162 |
| Antihelix . . . . | 666 |
| Antiprostatic glands . . | 312 |
| Antitragus . . . | 667 |
| Antitragicus muscle . . | 668 |
| Antrum highmorianum . | 738 |
| pylori . . . | 240 |
| Anus . . . . . | 305 |
| Aorta . . . . . | 405 |
| abdominal . . . 282. | 419 |
| arch of . . 120. | 406 |
| ascending . . . | 407 |
| descending . . | 407 |
| great sinus of . . | 120 |
| opening of . . | 118 |
| thoracic . . 91. | 418 |
| transverse . . | 407 |
| Aortic sinuses . . . | 407 |
| Aponeurosis, abdominal, anterior . . . . | 188 |
| brachial . . . | 149 |
| cervical . . . | 135 |
| dorsal . . . | 141 |
| epicranial . . . | 2 |
| of the fascia lata . | 185 |
| femoral . . . | 362 |
| lumbar . . . | 135 |
| pharyngeal . . | 46 |
| temporal . . . | 17 |
| Apparatus, lachrymal . | 622 |
| ligamentosus . . | 806 |
| Appendices epiploicæ . 236. | 258 |
| Appendix, auricular, left . | 116 |
| auricular, right . . | 110 |

| | Page. |
|---|---|
| Appendix to the ileum . | 248 |
| vermiformis . . | 249 |
| Aqua Cotunnii . . | 683 |
| Aqua Morgagni . . | 659 |
| Aqueduct of the cochlea . | 683 |
| of Fallopius . . | 726 |
| of Sylvius . . | 488 |
| of the vestibule . . | 680 |
| Aqueous humour . . . | 658 |
| humour, membrane of 647. | 658 |
| Arachnoid canal . . | 466 |
| membrane, cranial . | 464 |
| membrane, pathology of the . . . | 522 |
| membrane, spinal . | 505 |
| Arantii corpora . 114. | 119 |
| Arbor vitæ cerebelli . . | 499 |
| Arbor vitæ uterina . . | 354 |
| Arch of the aorta . . | 120 |
| femoral or crural 192. | 222 |
| palmar superficial . | 417 |
| palmar deep . . | 418 |
| superciliary . . | 719 |
| Arches of the palate . 49, | 50 |
| of pubis . . . | 765 |
| Arciform fibres . . | 502 |
| Areola . . . . . | 75 |
| Areolar tissue . . . | 597 |
| Arm, dissection of . . | 149 |
| muscles of . . . | 155 |
| Arterial tendinous zone 114. | 118 |
| Arteriosus ductus . . | 116 |
| ARTERIES,—general anatomy | 403 |
| structure of . . | 405 |
| acromial thoracic . | 415 |
| anastomotica of arm . | 417 |
| anastomotica magna of thigh . . . | 426 |
| angular . . . | 409 |
| aorta . . . | 405 |
| aorta, abdominal 282. | 419 |
| aorta, thoracic . . | 418 |
| articular of knee . | 426 |
| auricular, anterior . | 410 |
| auricular, posterior . | 410 |
| axillary . . 84. | 415 |

Page.

ARTERIES—*continued.*

azygos, articular . 426
basilar . . 414. 520
brachial . . 159. 416
bronchial . . . 418
buccal . . . 411
callosa . . . 413
capsular . . . 421
carotid, common right 39. 408
carotid, common left 39. 408
carotid, external 39. 408
carotid, internal 411. 520
carpi radialis, dorsal . 418
carpi ulnaris, dorsal . 417
caudal . . . 421
centralis retinæ . . 412
cerebellar, inferior . 520
cerebellar, superior 414. 520
cerebral, anterior 413. 520
cerebral, inferior . 414
cerebral, middle . 413. 520
cerebral, posterior 414. 520
cervicalis, ascendens . 415
cervicalis, profunda . 415
cervicalis, superficialis 415
ciliary, long . . 412
ciliary, posterior . 412
circumflex, anterior . 416
circumflex, external . 425
circumflex ilii, deep 213. 424
circumflex ilii, superficial 425
circumflex, internal . 425
circumflex, posterior . 416
cæliac axis . . 419
colica dextra . 280. 420
colica media . 280. 420
colica sinistra . 281. 421
comes nervi phrenici . 415
communicans cerebri, anterior . 413. 520
communicans cerebri, posterior . 412. 520
coronary . . 121, 122
coronary, left . . 408
coronary, right . . 408
coronary of lips, inferior 409

Page.

ARTERIES—*continued.*

coronary of lips, superior 409
coronary, orifices of . 119
corporis bulbosi . 423
corporis cavernosi . 423
cystic . . 280. 420
dental, inferior . . 411
dental, superior . . 411
digital, of the foot . 427
digital, of the hand . 417
dorsalis carpi radialis . 418
dorsalis carpi ulnaris . 417
dorsalis linguæ . . 409
dorsalis penis . . 423
dorsalis pollicis manus 418
epigastric, internal 209. 213. 424
epigastric, superficial . 425
ethmoidal . . . 412
external carotid . 39. 408
facial . . 21. 409
femoral . . 371. 424
frontal . . . 412
gastric . . 280. 419
gastro-duodenalis 280. 420
gastro-epiploica dextra 280. 420
gastro-epiploica sinistra 280. 420
glandular . . . 409
glutæal . . . 423
hæmorrhoidal, external 423
hæmorrhoidal, middle 423
hæmorrhoidal, superior 281. 421
helecine . . . 341
hepatic . 270. 280. 420
hyoidean, inferior . 409
hyoidean, superior . 409
hypogastric . . 422
ileo-colic . . 280. 420
iliac, common . 282. 421
iliac, external . 282. 424
iliac, internal . 282. 422
ilio-lumbar . . 422
infraorbital . . 411
inguinal . . . 425

Page.
ARTERIES—*continued*.
innominata . . 408
intercostal . . . 419
intercostal, anterior . 415
intercostal, superior . 415
internal carotid 39. 411. 520
internal maxillary 22. 410
interosseal . . 417
interosseal, anterior . 417
interosseal, posterior . 417
labial, inferior . . 409
lachrymal . . 412
laryngeal . . . 409
lateralis nasi . . 409
lingual . . . 409
lumbar . . 282. 421
malleolar . . . 426
mammary, internal . . 415
masseteric . . . 411
maxillary, external . 409
maxillary, internal 22. 410
mediastinal . . 415
meningea media . 410
mesenteric, inferior 280. 421
mesenteric, superior 280. 420
metatarsal . . 426
muscular . . . 409
nasal . . 411, 412
obturator . . . 423
occipital . . . 409
œsophageal . . 418
ophthalmic . 412. 636
palatine, inferior . 409
palatine, superior . 411
palmaris profunda . 418
palmaris superficialis . 417
palpebral . . . 412
pancreatic . . . 280
pancreatico-duodenalis
280. 420
perforating of thigh . 425
pericardiac . . 415
perinæal . . . 423
perinæal, transverse . 423
peroneal . . . 427
peroneal, anterior . 427
peroneal, posterior . 427

Page.
ARTERIES—*continued*.
pharyngeal ascending . 410
phrenic . . 282. 419
plantar, external . 427
plantar, internal . 427
pollicis magna . . 418
pollicis pedis . . 426
popliteal . . . 426
profunda femoris . 425
profunda, inferior . 417
profunda, superior . 416
pterygoid . . . 411
pudic, internal . . 423
pudic, superficial . 425
pulmonary . . 115
pulmonary, orifice of . 114
pyloric, inferior . . 420
pyloric, superior 280. 420
radial . . 182. 418
radialis indicis . . 418
radial, recurrent . 418
ranine . . 409
renal . . 282. 421
sacral, lateral . . 422
sacral, middle . 282. 421
scapular, posterior . 415
sciatic . . . 423
sigmoid . . 281. 421
spermatic . . 282. 421
spinal, anterior . 414. 520
spinal, posterior . 414. 520
splenic . . 280. 420
stylo-mastoid . . 410
subclavian . 39. 413
sublingual . . 409
submental . . 409
subscapular . . 416
superficialis volæ . 418
supraorbital . . 412
suprascapular . . 415
tarsal . . . 426
temporal . . 22. 410
temporal, anterior . 410
temporal, deep . . 411
temporal, middle . 410
temporal, posterior . 410
thoracica-acromialis . 415

Page.
ARTERIES—*continued.*
thoracic, long . 416
thoracic, superior . 416
thyroid axis . . 414
thyroid, inferior . . 415
thyroid, superior . 409
tibial, anterior . 389. 426
tibial, posterior . . 427
tibial, recurrent . 426
tonsillitic . . 409
transversalis colli . 415
transversalis faciei 21. 410
transversalis humeri . 415
transversalis perinæi . 423
ulnar . 182. 417
ulnar, recurrent anterior 417
ulnar, recurrent posterior . . . 417
umbilical . . 422. 443
uterine . . . 423
vaginal . . . 423
vasa brevia . . 420
vertebral . . 414. 519
vesical . . . 423
vidian . . . 411
Arthrodia . . . 799
Arthrology . . . 799
Articular arteries (knee) . 426
ARTICULATIONS . . 799
ankle . . . 856
atlanto-axoid . . 808
carpal . . . 831
carpo-metacarpal . 834
costo-clavicular . 816
costo-vertebral . 813
femoro-tibial . . 845
humero-cubital . . 824
humero-scapular . 821
ilio-femoral . . 839
of the larynx . . 61
metacarpo-phalangeal 835
metatarso-phalangeal 864
occipito-atlantal . 805
occipito-axoid . . 806
pelvic . . . 837
phalangeal of the foot 864
phalangeal of hand . 835

Page.
ARTICULATIONS—*continued.*
radio-carpal . . 829
radio-ulnar . . 826
sacro-iliac . . 837
sacro-coccygean . 837
sacro-vertebral . . 836
scapulo-clavicular . 819
sterno-clavicular . 816
tarsal . . . 860
tarso-metatarsal . . 863
temporo-maxillary . 801
tibio-fibular, inferior . 855
tibio-fibular, superior . 855
vertebral, common . 809
Arytenoid cartilages . 59
Arytenoideus muscle . 64
Ascendens colli nerve . 15
Astragalus . . . 781
Atlanto-axoid articulation . 808
Atlas . . . . 703
Atrabiliary body . . 288
Attollens aurem muscle . 4
Attrahens aurem muscle . 5
Auditory nerve 528. 543. 685
process, external . 723
Aureum punctum . . 656
Auricle, or external ear . 666
of the heart, left . 116
of the heart, right . 110
muscular fibres of . 126
Auriculæ transversus muscle 668
Auricular appendix, left . 116
appendix, right . . 110
arteries, anterior . 410
artery, posterior . 410
Auricularis magnus nerve . 549
muscle . . . 173
Auricular nerve . 538. 544
nerves, posterior . 542
Auricular veins . . 430
Auriculo-ventricular opening, left . . . 117
Auriculo-ventricular opening, right . . 112
Axilla, dissection of . . 83
lymphatic vesssels and glands of . 84. 448

| | Page. |
|---|---|
| Axillary artery . . 84. | 415 |
| nerves . . . | 553 |
| vein . . 83. | 436 |
| Axis . . . . . | 704 |
| cæliac . . 280. | 419 |
| of cochlea . . . | 681 |
| thyroid . . . | 414 |
| Azygos-articular artery . | 426 |
| process of sphenoid bone | 729 |
| uvulæ muscle . . | 52 |
| vein, major . 91. 282. | 434 |
| vein, minor . . | 434 |
| vein, superior . . | 435 |
| Back, muscles of . . . | 134 |
| Base of the brain . . | 477 |
| Basement membrane . . | 267 |
| Basilar artery . . 414. | 520 |
| plexus . . . | 544 |
| process of occipital bone | 714 |
| sinus . . . . | 464 |
| Basilic vein . 150. 161. | 436 |
| Basi-vertebral veins . . | 505 |
| Beaumont's observations on digestion . . 244. | 246 |
| Bell's muscles of the ureters . . . | 328 |
| Bertin, spongy bones of . | 729 |
| Biceps muscle . . . | 150 |
| flexor cruris muscle . | 380 |
| Bichat, canal of . . | 466 |
| Bladder, gall . . . | 272 |
| urinary . . . | 321 |
| coats of . . . | 325 |
| ligaments of, false . | 322 |
| ligaments of, true . | 324 |
| regions of . . . | 324 |
| pathology of the . | 330 |
| Body, pineal . . . | 486 |
| pituitary . . . | 479 |
| Bones, chemical composition | 693 |
| development . . | 697 |
| general observations on | 688 |
| number of . . . | 689 |
| physical properties . | 693 |
| structure of . . | 695 |
| astragalus . . | 781 |

| | Page. |
|---|---|
| Bones—*continued.* | |
| atlas . . . | 703 |
| auditory . . . | 676 |
| axis . . . | 704 |
| calcis . . . | 782 |
| carpal . . . | 793 |
| clavicle . . . | 785 |
| coccyx . . . | 712 |
| costæ . . . | 755 |
| cranial . . . | 712 |
| cuboid . . . | 783 |
| cuneiform of carpus . | 794 |
| cuneiform (tarsi) internal . . . | 783 |
| cuneiform (tarsi) middle . . . | 783 |
| cuneiform (tarsi) external . . . | 783 |
| ethmoid . . . | 726 |
| facial . . . | 736 |
| femur . . . | 772 |
| fibula . . . | 779 |
| frontal . . . | 718 |
| humerus . . . | 789 |
| hyoides . . 57. | 798 |
| ilium . . . | 762 |
| incus . . . | 677 |
| innominatum . . | 765 |
| irregular . . . | 695 |
| ischium . . . | 764 |
| lachrymal . . | 741 |
| lenticular of ear . | 677 |
| long . . . . | 694 |
| lunar . . . | 794 |
| magnum . . . | 795 |
| malar . . . | 737 |
| malleus . . . | 677 |
| maxillary, inferior . | 742 |
| maxillary, superior . | 737 |
| metacarpal . . | 795 |
| metatarsal . . | 784 |
| nasal . . . | 741 |
| navicular of carpus . | 794 |
| navicular of tarsus . | 783 |
| occipital . . . | 713 |
| orbicular of ear . . | 677 |
| palate . . . | 739 |

Page.

BONES—*continued.*
parietal . . . 716
patella . . . 776
pelvic . . . 761
phalanges manus . 797
phalanges pedis . 784
pisiform . . . 795
planum of ethmoid . 728
pubis . . . 764
pyramidal of carpus . 794
radius . . . 792
ribs . . . . 755
sacrum . . . 709
scaphoid of carpus . 794
scaphoid of tarsus . 783
scapula . . . 786
semilunar . . . 794
sesamoid . . 785. 797
sphenoid . . . 729
spongy . . . 727
spongy of sphenoid bone 729
stapes . . . 677
sternum . . . 753
tarsal . . . 780
temporal . . . 722
tibia . . . . 776
trapezium . . . 795
trapezoid . . . 795
triquetra . . . 717
turbinated, inferior . 741
turbinated, middle . 720
turbinated, superior . 728
turbinated, of the sphenoid . . . 729
ulna . . . . 791
unciform . . . 795
unguis . . . 741
vertebræ . . . 699
vertebræ, cervical . 702
vertebræ, dorsal . 701
vertebræ, lumbar . 701
vomer . . . 742
Wormian . . . 717
Bowman's researches on the kidney . . . 285
Brachialis anticus muscle . 157
Brachial aponeurosis . . 149

Page.

Brachial artery . 159. 416
nerve . . . 555
plexus . 42. 84. 551. 159
Brain, . . . . 455
convolutions of . . 474
dissection of, from below . . . 513
membranes of . . 455
motions of . . 468
pathology of the . 522
structure of . 472. 513
vessels of . . 519
Broad ligaments of the uterus 351
Bronchial arteries . . 418
glands . . 99. 450
tubes . . . 102
Bruit musculaire . . 131
Brun, glands of . . 256
Buccal artery . . 411
nerve . . . 538
Buccinator muscle . . 11
Bulb, artery of . . 423
of the corpus spongiosum . . . 343
of olfactory nerve . 524
Burn's ligament . . 216
Bursa, carpal . . . 163

Cæcum . . . . 249
structure of . . 258
Calamus scriptorius . . 498
Calcaneum . . . 782
Calyces of the kidney . 286
Calyciform papillæ . . 609
Camper's fascia . . 185
Canal, alimentary . . 238
of Bichat . . . 466
of Fontana . . 651
godroné . . . 662
Haversian . . . 696
inguinal . . . 206
lachrymal . . . 623
of Nuck . . . 352
of Petit . . . 662
semicircular . . 681
spermatic . . . 206
Canine fossa . . . 737

Page.
Canine teeth . . . . 745
Canthi, palpebral . . 616
Capillary system . . 404
Capsule of Glisson . . 267
of aqueous humour 647
supra-renal . . 288
Capsular arteries . . 421
ligament of the jaw . 803
veins . . . 439
Caput gallinaginis . . 344
coli . . . 249
Cardia . . . . 240
Cardiac ganglion . . 580
muscles, actions of . 130
nerves, . . 123. 545
nerve, inferior . 579, 580
nerve, middle or great 578, 579
nerve, superior . 578, 579
plexus . . . 123
plexus, anterior . 580
plexus, great . . 580
plexus, posterior . 580
veins . . 122, 123
Carneæ columnæ . 112. 117
Carotid arteries, right and left, common . 39. 408
artery, external 39. 408
artery, internal 39. 411. 520
plexus, internal . 577
Carpal bones, dislocations of 834
bursa . . . 163
Carpo-metacarpal articulations . . . 834
Carpus, bones of . . 793
Cartilage . . 690. 800
chemical composition . 693
development . . 692
structure of . . 691
arytenoid . . 59
costal . . . 758
cricoid . . . 59
cuneiform . . 61
interarticular . . 800
interarticular of the clavicle . . 818
interarticular of the jaw 803

Page.
Cartilage, interarticular scapulo-clavicular . 819
interarticular of the wrist . . . 828
of the nose . . 600
palpebral . . 619
semilunar . . 851
tarsal . . . 619
thyroid . . . 58
xiphoid . . . 754
Caruncula lachrymalis 617. 620
Carunculæ myrtiformes . 349
Casserian ganglion . . 527
Cauda equina . . . 507
Caudal artery . . . 421
Cava vena, inferior . . 438
superior . . . 433
Cavernous plexus . . 577
sinus . . . 463
Cells, ethmoid . . 728
mastoid . . . 675
Cellular tissue . . . 597
Centrum ovale magnum . 480
ovale minus . . 480
Cephalic vein . 149. 161. 435
Cerebellum . . . 492
function of . . 518
Cerebellar artery, inferior 414. 520
artery, superior . 414. 520
Cerebral artery, anterior 413. 520
artery, communicating anterior . . 413
artery, communicating posterior . . 412
artery, middle . 413. 520
artery, posterior 414. 520
granulations . . 462
nerves, dissection of . 530
nerves, origins of . 523
Cerebro-spinal axis . . 456
Cerebrum, dissection of . 473
inferior surface of . 477
lobes of . . . 477
Cerumen . . . 670
Ceruminous glands . 594. 670
Cervical aponeurosis . 135

Page.
Cervical artery, ascending . 415
artery, superficialis . 415
artery, profunda . 415
fascia, deep . . 27
fascia, superficial . 27
ganglions . . . 576
ganglion, inferior 41. 578
ganglion, middle 41. 578
ganglion, superior 41. 576
glands . . . 448
nerves, spinal . 41. 548
plexus . . 41. 549
plexus posterior . . 551
Cervicalis ascendens muscle 143
descendens muscle . 143
Cervico-facial nerve . . 542
thoracic septum . 28
Chamber of the eye, anterior 658
of the eye, posterior . 658
Check ligaments . . 807
Cheeks . . . . 42
Chiasma . . . . 524
Chordæ tendineæ . 113. 117
vocales . . . 62
Chorion . . . . 592
Choroid coat of the eye . 647
membrane . . . 485
plexus . . . 483
plexus of the fourth ventricle . 469. 496
plexus of lateral ventricles 470
plexus of the third ventricle . . . 486
Chromatic aberration . 664
Cilia . . . . 618
Ciliary artery, long . . 412
artery, posterior . 412
disk . . . 652. 661
ligament . . . 650
nerves . . 533, 534
processes . . . 651
Circle of Willis 414. 519, 520
Circular sinus . . . 464
Circulation, adult . 110. 403
fœtal . . . 440
Circumflex artery, anterior 416
artery, external . . 425

Page.
Circumflex artery, internal . 425
artery, posterior . 416
ilii artery, deep . 213. 424
ilii artery, superficial . 425
nerve . . . 554
Clavicle, . . . . 785
dislocations of . . 820
Clinoid processes of sphenoid 730
Clitoris . . . . 347
Cochlea . . . . 681
Cochlear nerve . . . 685
Coccygeal ganglion . 575. 584
Coccyx . . . . 712
Cœliac axis . . 280. 419
plexus . . 92. 281
Colic artery, left . 281. 421
artery, middle . 280. 420
artery, right . 280. 420
omentum . . . 236
Colles's fascia . . . 194
Colon . . . . 251
structure of . . 258
Colouring matter of skin . 591
Columella . . . 672
Column, vertebral . . 706
Columnæ carneæ . 112. 117
vaginæ . . . 351
Commissure, cerebro-cerebellar . . . 499
of the cerebellum, great 491
of the cerebrum, anterior 489
of the cerebrum, posterior 489
of the cerebrum, great inferior . . . 485
of the cerebrum, great superior . . 481
intercerebral . . 499
optic . . . 524
soft . . . . 488
spinal, anterior . . 508
spinal, posterior . . 508
superior longitudinal . 475
Communicans noni nerve . 550
peronei nerve . . 571
tibialis nerve . 383. 573
Communicating nerve, lumbar . . . 567

Page.

Complexus muscle . . 144
Compressor nasi muscle . 8
penis muscle . . 308
urethræ muscle . . 314
urethræ transversus . 315
venæ dorsalis penis muscle . . . 310
Conarium . . . 486
Concha . . . . 668
Conglobate glands . . 447
Coni vasculosi . . . 335
Conjoined tendons . . 195
Conjunctiva . . . 620
structure of . . 621
Conoid ligament . . 820
Constrictor iridis . . 654
isthmi faucium muscle 52
pharyngis inferior muscle 46
pharyngis medius muscle 47
pharyngis superior muscle 48
Conus arteriosus . . 114
Converging fibres . . 514
Convolution, hem-like . 474
Coraco-brachialis muscle . 155
clavicular fascia . . 820
clavicular ligament . 80
Cord, spermatic . . 336
spermatic, tunica vaginalis of . . . 206
Corda tympani nerve 536. 541. 676
Cordæ Willisii . . . 462
Cordiform tendon of diaphragm . . . 294
Cornea . . . . 645
elastic . . . 647
Cornicula Santorini . . 60
Cornu Ammonis . . 485
Cornua of the vestibule . 680
of the lateral ventricles 482
Corona ciliaris . . . 661
Corona glandis . . . 343
Coronal suture . . . 732
Coronary arteries, orifices of 119
arteries . 121, 122. 408
arteries of lips . . 409
Coronary ligament of the liver . . . 264

Page.

Coronary ligament of the knee 851
plexuses . . 123. 580
sinus . . . 112
valve . . . 112
vein . . . . 122
Coronoid process of lower jaw-bone . . 743
process of ulna . . 791
Corpora albicantia . . 480
Arantii . . 114. 119
cavernosa penis . . 340
mammillaria . . 480
olivaria . . 501. 516
Pacchioni . . . 462
pisiformia . . . 480
pyramidalia . 501. 515
quadrigemina . . 490
restiformia . . 502. 515
striata . . . 482
Corpus callosum . . 481
cavernosum . . 340
cavernosum, artery of 423
dentatum . . . 499
denticulatum . . 485
fimbriatum . 356. 485
geniculatum externum 487
geniculatum internum 487
Highmorianum . . 334
luteum . . . 357
pampiniforme . . 337
psalloides . . . 484
rhomboideum . . 499
spongiosum urethræ . 343
striatum . . . 482
Corpuscles of Malphigi . 285
of Pacini . . . 557
Corrugator supercilii muscle 8
Costæ . . . . 755
Costal cartilages . . 758
Costo-clavicular articulation 816
clavicular fascia . . 820
coracoid ligament . 80
sternal ligaments . 816
transverse ligaments . 815
Cotunnii aqua . . . 683
Cotunnius, nerve of . . 536
Cotyloid cavity . . . 766

| | Page. |
|---|---|
| Cotyloid ligament | 842 |
| Cowper's glands | 312 |
| Cranial sinuses | 461 |
| Cranium | 712 |
| Cremaster muscle | 195 |
| Cribriform fascia | 217. 363 |
| plate of ethmoid bone | 726 |
| Cricoid cartilage | 59 |
| Crico-arytenoideus lateralis muscle | 64 |
| arytenoideus posticus muscle | 64 |
| thyroid ligament | 62 |
| thyroideus muscle | 63 |
| Crista galli | 727 |
| Crura cerebelli | 500 |
| cerebri | 480. 489. 516 |
| of diaphragm | 294 |
| penis | 340 |
| Cruræus muscle | 368 |
| Crural arch | 192. 222 |
| hernia | 214 |
| nerve, anterior | 563 |
| nerve, posterior | 570 |
| ring | 223 |
| septum | 212. 219 |
| Crusta petrosa | 747 |
| Crystalline humour, or lens | 658 |
| Cuboid bone | 783 |
| Cuneiform bone of carpus | 794 |
| bones of tarsus | 783 |
| cartilages | 61 |
| Cupola | 682 |
| Cutaneous nerve of arm, external | 555 |
| nerve of arm, internal | 554 |
| nerve of arm, lesser | 555 |
| nerves of back, inferior | 559 |
| nerves of back, superior | 559 |
| nerves of the leg, external | 571 |
| nerves of the leg, internal | 565 |
| nerves of the leg, posterior | 573 |
| nerve of thigh, posterior | 569 |
| Cuticle | 589 |

| | Page. |
|---|---|
| Cutis vera | 592 |
| Cystic artery | 280. 420 |
| duct | 272 |
| Dartos | 331 |
| Decussating fasciculi | 501 |
| Deglutition, stages of | 53 |
| Deltoid ligament of the ankle | 857 |
| ligament of the scapula | 820 |
| muscle | 150 |
| nerve | 554 |
| Demours, membrane of | 646 |
| Dental artery, inferior | 411 |
| arteries, superior | 411 |
| nerves, anterior | 537 |
| nerve, inferior | 538 |
| nerves, posterior | 537 |
| nerves, superior | 537 |
| pulp | 748 |
| Dentine | 747 |
| Depressor anguli oris muscle | 10 |
| labii inferioris muscle | 10 |
| labii superioris alæque nasi muscle | 10 |
| oculi muscle | 628 |
| Dermis | 592 |
| Descendens colli nerve | 547 |
| Descendens noni nerve | 410. 547 |
| Desipimenta testis | 334 |
| Detrusor urinæ | 325 |
| Diaphragm | 290 |
| openings in | 295 |
| Diarthrosis | 799 |
| Diastole | 130 |
| Digastricus muscle | 33 |
| Digastric nerve | 542 |
| region | 34 |
| Digestive organs | 238 |
| Digital arteries of the foot | 427 |
| arteries of the hand | 417 |
| cavity | 482 |
| nerves of fingers | 556 |
| nerves of toes | 574 |
| Dimensions of pelvis (Meckel) | 771 |
| Diploe | 695 |
| Diploic veins | 430 |

Page.
Disk, ciliary . . 652. 661
Dislocations of the ankle . 859
of carpal bones . . 834
of the clavicle . . 820
of elbow-joint . . 827
of fibula, head of . 855
of the hip-joint . . 843
of the humerus . . 823
of inferior radio ulnar joint . . . 829
of the knee-joint . 854
of lower jaw . 21. 804
of the metacarpal bones from the carpus . 834
of the patella . . 853
of the phalanges of the foot . . . 864
of the ribs . . 816
of semilunar cartilages 854
of the tarsal bones . 863
of thumb . . 835
of the vertebræ . . 813
of the wrist . . 831
Diverging fibres . . 514
Diverticulum ilei . . 248
Dorsal aponeurosis . . 141
nerves . . . 558
nerve, first . . 560
nerves of the foot . 571
Dorsalis carpi radialis artery 418
carpi ulnaris artery . 417
carpi ulnaris nerve . 557
linguæ artery . . 409
pollicis manus artery . 418
Dorso-lumbar nerve . . 560
Duct, cystic . . . 272
hepatic . . . 271
lachrymal . 617. 623
lymphatic, right . 454
nasal . . . 624
of the pancreas . . 279
of parotid gland . 14
of the prostate . . 339
of submaxillary gland 35
thoracic . 91. 283. 452
of Wharton . . 35
Ductus arteriosus . 116. 443

Page.
Ductus choledochus communis . . 271
ejaculatorius communis 336, 337
venosus . . . 442
Duodenum . . . 246
structure of . . 254
Dura mater, artery of, middle 410
mater, cranial . . . 457
mater, pathology of the 521
mater, spinal . . 504

Ear, anatomy of . . 665
external . . . 666
internal . . . 679
middle . . . 670
muscles of . . 4, 5
external, muscles of . 668
Eighth pair of nerves 40. 528 543
Ejaculator seminis muscle . 309
Ejaculatory duct . . 336
Elastic cornea . . . 647
Elbow-joint . . . 824
dislocations of . . 827
Eminence, ilio-pectinæal . 763
jugular . . . 715
Eminentia pyramidalis . 681
Emulgent veins . . 439
Enamel . . . . 746
Enarthrosis . . . 799
Encephalon . . . 456
Endocarde . . . 121
Endolymph . . . 684
Epicranial aponeurosis . 2
Epidermis . . . 589
Epididymis . . . 335
Epigastric artery, deep or internal . 209. 213. 424
artery, superficial . 425
region . . . 226
Epiglottic gland . . 61
Epiglottis . . . 60
Epithelium . . 260. 591
Erectile tissue . . . 340
Erector clitoridis muscle . 349
penis muscle . . 308
Ethmoid bone . . . 726

Page.
Ethmoid cells . . . 728
Ethmoidal artery . . 412
suture . . . 732
Eustachian tube . 49. 675
valve . . 111. 442
Excito-motor function . 510
Expiration . . . 299
External carotid artery
15. 21. 39. 408
jugular vein . . 15. 26
Extensor carpi radialis brevis muscle . . 172
carpi radialis longus muscle . . . 117
carpi ulnaris muscle . 172
digitorum brevis pedis 388
digitorum communis muscle . . . 172
digitorum longus pedis muscle . . . 387
indicis muscle . . 175
minimi digiti muscle . 173
ossis metacarpi pollicis muscle . . . 174
pollicis proprius pedis muscle . . 387
pollicis major muscle . 175
pollicis minor muscle . 174
primi internodii pollicis muscle . . . 174
secundi internodii pollicis muscle . . 175
Extremity, inferior, dissection of . . . 361
superior, dissection of . 148
Eye . . . . . 640
brows . . . 616
chambers of . . 642
coats of . . . 641
globe of . . . 640
humours of . . 641
lashes . . . 618
lids . . . . 616
motions of . 630. 633

Face, bones of . . 736
muscles of . . 6

Page.
Face, vessels and nerves of 21
Facial artery . . . 409
artery, transverse . 410
nerve . 527. 540. 686
vein . . 21. 430
Falciform ligament of liver . 263
process of fascia lata 217. 363
process of great sacro-sciatic ligament . 837
Fallopian tubes . . . 356
Fallopii hiatus . . . 726
Fallopius, aqueduct of . 726
ligament of . . 192
Falx cerebelli . . . 461
cerebri . . . 458
Fascia, abdominal, deep . 185
abdominal, superficial . 184
anal . . 307. 319
Camper's . . . 185
cervical, deep . . 27
cervical, superficial . 27
Colles's . . . 194
costo-clavicular . 820
costo-coracoid . 80. 820
cribriform . 217. 363
dentata . . . 485
of the forearm . . 162
iliaca . . . 220
infraspinous . . 148
infundibuliform . 205
intercolumnar . . 192
ischio-rectal . 307. 319
lata . . 216. 362
lata, aponeurosis of . 185
of the leg . . 384
lumbar . . 135. 198
obturator . . 308. 319
ocular . . . 628
palmar . . . 163
pelvic . . . 319
perinæal, deep . 307. 311
perinæal, middle . 307
perinæal, superficial . 306
plantar . . . 385
prevertebral . . 28
propria of femoral hernia . . 212. 219

| | Page. |
|---|---|
| Fascia, propria of inguinal hernia | 207 |
| rectal | 314. 320 |
| recto-vesical | 312. 320 |
| Scarpa's | 185 |
| semilunar | 156 |
| spermatic | 192. 332 |
| subpleural | 89 |
| subscapular | 149 |
| supraspinous | 148 |
| temporal | 17 |
| transversalis | 203 |
| triangular | 194 |
| vesical | 320 |
| Fat | 598 |
| Faucium isthmus | 42. 49 |
| Femoral aponeurosis | 362 |
| arch | 192 |
| artery | 371. 424 |
| hernia | 214 |
| hernia, coverings of | 224 |
| hernia, fascia propria of | 212. 219 |
| hernia, mode of descent of | 224 |
| ring | 223 |
| vein | 437 |
| vessels, sheath of, anterior | 205. 222 |
| vessels, sheath of, posterior | 221 |
| Femur | 772 |
| Fenestra cochleæ | 675 |
| ovalis | 674 |
| rotunda | 675 |
| vestibuli | 674 |
| Ferrein, tubes of | 285 |
| Fibro-cartilage | 690. 800 |
| interarticular of the clavicle | 818 |
| interarticular of the jaw | 803 |
| interarticular, scapulo-clavicular | 819 |
| interarticular of the wrist | 828 |
| intervertebral | 810 |
| of the nose | 600 |
| semilunar | 851 |
| Fibula | 779 |
| Filamentous tissue | 597 |
| Fimbriæ of Fallopian tubes | 356 |
| Fingers, bones of | 797 |
| Fissures, Glaserian | 723 |
| of the liver | 265 |
| purse-like, of cerebellum | 492 |
| of Sylvius | 478 |
| transverse, of cerebrum | 470 |
| Flexor brevis minimi digiti muscle | 178 |
| brevis minimi digiti pedis | 400 |
| carpi radialis muscle | 165 |
| carpi ulnaris muscle | 166 |
| digitorum brevis pedis | 397 |
| digitorum longus pedis | 394 |
| digitorum profundus perforans muscle | 168 |
| digitorum sublimis perforatus muscle | 166 |
| ossis metacarpi pollicis muscle | 177 |
| pollicis brevis muscle | 177 |
| pollicis longus muscle | 169 |
| pollicis pedis brevis | 399 |
| pollicis pedis longus | 395 |
| tendons, sheaths for | 167 |
| Flocculus | 494 |
| Flood's ligament | 822 |
| Fluid of Scarpa | 684 |
| Fluid, subarachnoid | 467 |
| subarachnoid, spinal | 506 |
| Fœtal circulation | 440 |
| Follicles, hair | 596 |
| of Lieberkühn | 256 |
| Meibomian | 594. 619 |
| Fontana, canal of | 651 |
| Fontanelle | 717 |
| Foot, bones of | 780 |
| dissection of | 396 |
| Foramen cæcum | 607. 609 |
| commune anterius | 485 |
| commune posterius | 488 |
| incisivum | 739 |
| lacerum orbitale | 731 |

| | Page. |
|---|---|
| Foramen magnum | 714 |
| obturator | 767 |
| ovale . . 111. | 442 |
| rotundum cochleæ | 675 |
| of Soemerring | 656 |
| thyroid | 767 |
| of Winslow | 236 |
| Foramina Thebesii | 112 |
| Forearm, dissection of | 160 |
| fascia of | 162 |
| Fornix | 484 |
| Fossa, anticubital | 162 |
| canine | 737 |
| innominata | 666 |
| myrtiform | 739 |
| navicular of ear | 666 |
| navicularis urethræ | 344 |
| ovalis | 111 |
| scaphoid of ear | 666 |
| Fovea elliptica | 681 |
| hemispherica | 680 |
| Fourchette | 347 |
| Frænum epiglottidis | 63 |
| linguæ | 43 |
| of the lips | 43 |
| præputii | 339 |
| Frontal artery | 412 |
| bone | 718 |
| nerve . . 22. | 533 |
| sinuses | 721 |
| vein | 430 |
| Function, excito-motor | 510 |
| Galen, veins of . . 470. | 485 |
| Galeni vena, heart | 123 |
| Gall-bladder | 272 |
| pathology of the | 277 |
| Ganglia, dissection of the | 574 |
| structure of | 585 |
| of Andersch | 543 |
| Arnold's | 539 |
| cardiac | 580 |
| carotid | 577 |
| Casserian | 527 |
| of cerebellum | 499 |
| of the cerebrum, anterior | 483 |
| Ganglia of the cerebrum, great posterior | 487 |
| of the cerebrum, superior | 483 |
| cervical | 576 |
| cervical, inferior 41. | 578 |
| cervical, middle . 41. | 578 |
| cervical, superior 41. | 576 |
| coccygæal . 575. | 584 |
| impar . . 575. | 584 |
| jugular | 543 |
| lenticular | 534 |
| lumbar | 583 |
| Meckel's | 535 |
| naso-palatine | 536 |
| olivary | 501 |
| ophthalmic | 534 |
| otic | 539 |
| petrous | 543 |
| pneumogastric, inferior | 544 |
| pneumogastric, superior | 544 |
| of Ribes | 521 |
| sacral | 584 |
| semilunar, abdominis 91. 281. | 582 |
| spheno-palatine | 535 |
| submaxillary | 536 |
| thoracic | 581 |
| Gastric artery . . 280. | 419 |
| plexus | 582 |
| Gastro-colic, or great omentum | 234 |
| duodenalis artery 280. | 420 |
| epiploica dextra artery 280. | 420 |
| sinistra artery . 280. | 420 |
| hepatic, or lesser omentum | 234 |
| Gastrocnemius muscle | 390 |
| Gemellus muscle, inferior | 377 |
| muscle, superior | 377 |
| Generative organs, female | 347 |
| organs, female, pathology of the | 358 |
| organs, male | 331 |
| organs, male, pathology of the | 345 |

Page.

Genio-hyo-glossi muscles 37. 607
hyoideus muscle . 35
Genito-crural nerve . . 563
Germinal spot (Wagner) . 357
vesicle (Purkinjie) . 357
Gimbernaut's ligament . 193
Ginglymus . . . 799
Glands, arrangement of . 13
aggregate . . . 256
antiprostatic . . 312
axillary . . . 448
Brunner's . . . 256
ceruminous . 594. 670
cervical . . . 448
conglobate . . 447
conglomerate . . 13
of Cowper . . 312
duodenal . . . 256
epiglottic . . 61
gastric . . . 244
of Harder . . . 621
of Havers . . . 801
inguinal . . . 449
inguinal, deep-seated lymphatic . . 362
inguinal, superficial lymphatic . . 362
lachrymal . . 622
lingual . . . 609
lymphatic . . 447
lymphatic, abdominal 449
lymphatic, inguinal . 216
lymphatic thoracic . 449
mammary . . 74
Meibomian . 594. 619
odoriferous . . 595
parotid . . . 14
parotid, pathology of . 16
pelvic . . . 449
Peyer's . . . 256
pineal . . . 486
pituitary . . . 479
prostate . . . 338
salivary . . . 12
sebaceous . . . 594
solitary . . . 256
sublingual . . 36

Page.

Glands, submaxillary . 34
sudoriferous . . 594
thymus . . . 445
thyroid . . . 32
vulvo-vaginal . . 348
Glandulæ agminatæ . . 256
Brunneri . . . 256
odoriferæ . . . 340
Pacchioni . . . 462
Peyeri . . . 256
solitariæ, or sparsæ . 256
Tysoni . . . 340
Glans clitoridis . . 348
penis . . . 343
Glasserian fissure . . 723
Glenoid cavity of scapula . 788
cavity of temporal bone 723
ligament . . . 821
Glisson, capsule of . . 267
Globe of the eye, dissection of . . . . 640
Globus, epididymis major . 335
epididymis minor . 335
Glosso-epiglottic ligament . 60
pharyngeal nerve 40. 528. 543
Glottis, opening of the . 49. 67
Glutæal artery . . . 423
nerve, inferior . . 569
nerve, superior . . 567
Glutæus maximus muscle . 374
medius muscle . . 376
minimus muscle . 376
Gomphosis . . . 800
Graafian vesicles . . 357
Gracilis muscle . . 368
Gubernacula dentium . 749
Gums . . . . 42
Gustatory nerve . 40. 539
Guthrie's muscles . . 315

Habenæ of pineal body . 486
Hæmorrhoidal arteries, external . . . 423
arteries, middle . . 423
artery, superior . 281. 421
plexus . . . 583

| | Page. |
|---|---|
| Hairs | 596 |
| Hamular process of sphenoid bone | 731 |
| Hamulus laminæ spiralis | 682 |
| Hand, bones of | 793 |
| characters of | 175 |
| dissection of | 160 |
| muscles of | 175 |
| Harder, gland of | 621 |
| Harmonia | 800 |
| Haunch bone | 765 |
| Haversian canals | 696 |
| glands | 801 |
| Head, bones of | 712 |
| external parts of | 1 |
| Hearing, organ of | 665 |
| sense of | 665 |
| Heart | 107 |
| Heart's action, frequency of | 132 |
| Heart, auricle of, left | 116 |
| auricle of, right | 110 |
| cavities of | 110 |
| muscular tissue of | 124 |
| nerves of | 123 |
| pathology of the | 132 |
| position of | 108 |
| sounds of | 131 |
| surfaces of | 108 |
| tissues entering into the composition of | 120 |
| ventricle of, left | 117 |
| ventricle of, right | 112 |
| Helecine arteries | 341 |
| Helicis major muscle | 668 |
| minor muscle | 668 |
| Helicotrema | 683 |
| Helix | 666 |
| Hepatic artery | 270. 280. 420 |
| ducts | 271 |
| plexus | 582 |
| veins | 270. 439 |
| Hernia, congenital | 333 |
| femoral, or crural | 214 |
| femoral, coverings of | 224 |
| femoral, fascia propria of | 212. 219 |
| femoral, mode of descent of | 224 |

| | Page. |
|---|---|
| Hernia, inguinal direct | 209 |
| inguinal direct inferior | 210 |
| inguinal direct superior | 210 |
| inguinal oblique | 207 |
| umbilical | 190 |
| ventro-inguinal | 209 |
| Herophili torcular | 464 |
| Hey's ligament | 217 |
| Hiatus Fallopii | 726 |
| Highmore, antrum of | 738 |
| Hilton's muscle | 65 |
| Hilus of kidney | 284 |
| of spleen | 277 |
| Hip-joint | 839 |
| joint, dislocations of | 843 |
| muscles of | 374 |
| Hippocampus major | 485 |
| minor | 485 |
| Hirundinis nidus | 497 |
| Horner's muscle | 8 |
| Houston's muscles | 310 |
| Humerus, dislocation of | 823 |
| Humeri os | 789 |
| Humour, of the eye, aqueous | 658 |
| aqueous, capsule of | 647 |
| of the eye, crystalline | 658 |
| of the eye, vitreous | 661 |
| Hyaloid body | 661 |
| capsule or membrane | 661 |
| Hydrocephalus externus | 522 |
| internus | 522 |
| Hymen | 349 |
| Hyo-epiglottic ligament | 60 |
| glossal ligament | 606 |
| glossus muscle | 37. 607 |
| pharyngeus muscle | 47 |
| thyroid ligaments | 61 |
| Hyoid bone | 57. 798 |
| Hypochondriac regions | 226 |
| Hypogastric artery | 422 |
| plexus | 584 |
| region | 226 |
| Ileo-cæcal valve | 250 |
| colic artery | 280. 420 |
| colic valve | 250 |
| Ileum | 247 |

| | Page. |
|---|---|
| Ileum, diverticulum of | 248 |
| structure of | 254 |
| Iliac arteries, common | 421. 282 |
| artery, external | 424. 282 |
| artery, internal | 422. 282 |
| fascia | 220 |
| fossæ | 763 |
| regions | 226 |
| vein, common | 282. 438 |
| vein, external | 282. 437 |
| vein, internal | 282. 438 |
| Iliacus internus muscle | 303 |
| Ilio-femoral articulation | 839 |
| lumbar artery | 422 |
| pectinæal eminence | 763 |
| pectinæal line | 763 |
| scrotal nerve | 562 |
| Ilium | 762 |
| Incisor teeth | 745 |
| Incisuræ Santorini | 669 |
| Incus | 677 |
| Indicator muscle | 175 |
| Inferior extremities, dissection of | 361 |
| maxillary nerve | 537 |
| Infraclavicular nerves | 553 |
| Infraorbital nerve | 23. 537 |
| orbital artery | 411 |
| spinous fascia | 148 |
| spinous ligaments | 812 |
| spinatus muscle | 152 |
| trochleator nerve | 533 |
| Infundibula of the kidney | 287 |
| Infundibuliform fascia | 205 |
| Infundibulum | 479. 488 |
| Infundibulum cochleæ | 682 |
| of ethmoid bone | 728 |
| Infundibulum of right ventricle | 114 |
| Ingrassius, wing of | 730 |
| Inguinal arteries | 425 |
| canal | 206 |
| glands | 449 |
| hernia congenital | 333 |
| hernia direct | 209 |
| hernia, direct inferior | 210 |
| hernia, direct superior | 210 |
| Inguinal hernia, oblique | 207 |
| lymphatic glands | 216 |
| lymphatic glands, deep | 362 |
| lymphatic glands, superficial | 362 |
| pouches | 209. 212. 228 |
| region | 215. 227 |
| ring, external | 191 |
| ring, internal | 205 |
| Inguino-cutaneous nerves | 562 |
| Innominata artery | 408 |
| Innominatæ venæ | 98. 433 |
| Inspiration | 298 |
| Interarticular cartilage of the clavicle | 818 |
| fibro-cartilage of the jaw | 803 |
| fibro-cartilage of the wrist | 828 |
| Intercolumnar fascia | 192 |
| Intercostal arteries | 419 |
| artery, superior | 415 |
| muscles | 82 |
| nerves | 559 |
| veins | 435 |
| Intercosto-humeral nerves | 560 |
| Intercrural lamina | 480 |
| Intermaxillary ligament | 11. 802 |
| Intermuscular ligaments | 149 |
| Internal maxillary artery | 22. 410 |
| Interosseal artery | 417 |
| artery, anterior | 417 |
| artery, posterior | 417 |
| nerve of arm, anterior | 556 |
| nerve of arm, posterior | 558 |
| nerve of leg | 572 |
| Interossei muscles of the hand | 179 |
| pedis inferiores muscles | 400 |
| pedis superiores muscles | 401 |
| Interspinales muscles | 145 |
| Interspinous ligaments | 813 |
| Intertransversales muscles | 145 |
| Intertransverse ligaments | 813 |
| Intervertebral fibro-cartilages | 810 |

| | Page. |
|---|---|
| Intestinal canal . . | 240 |
| canal, pathology of the | 262 |
| coats of . . . | 253 |
| glands of . . | 256 |
| Iris . . . . . | 652 |
| Ischio-bulbosus muscle . | 310 |
| Ischio-rectal fascia . | 307. 319 |
| region . . . | 307 |
| Ischium . . . . | 764 |
| Island of Reil . . | 475. 479 |
| Isthmus faucium . . | 42 |
| Iter ad quartum ventriculum . . . | 488 |
| Itinera dentium . . | 749 |
| Ivory . . . . | 747 |
| | |
| Jacob's membrane . . | 656 |
| Jacobson's nerve . . | 543 |
| Jaw, lower . . . | 742 |
| lower, dislocations of | 21. 804 |
| lower, motions of | 20. 804 |
| Jejunum . . . . | 247 |
| structure of . . | 254 |
| Joints . . . . | 799 |
| ankle . . . | 856 |
| atlanto-axoid . . | 808 |
| carpal . . . | 831 |
| carpo-metacarpal . | 834 |
| costo-clavicular . | 816 |
| costo-vertebral . . | 813 |
| elbow . . . | 824 |
| femoro-tibial . . | 845 |
| hip . . . . | 839 |
| humero-cubital . . | 824 |
| humero-scapular . | 821 |
| ilio-femoral . . | 839 |
| jaw, lower . . . | 801 |
| knee . . . | 845 |
| metacarpo-phalangeal . | 835 |
| metatarso-phalangeal . | 864 |
| occipito-atlantal . . | 805 |
| occipito-axoid . . | 806 |
| pelvic . . . | 837 |
| phalangeal of the foot . | 864 |
| phalangeal of the hand | 835 |
| radio-carpal . . | 829 |
| radio-ulnar . . | 826 |

| | Page. |
|---|---|
| Joints, sacro-coccygean . | 837 |
| sacro-iliac . . | 837 |
| sacro-vertebral . . | 836 |
| scapulo-clavicular . | 819 |
| shoulder . . . | 821 |
| sterno-clavicular . | 816 |
| tarsal . . . | 860 |
| tarso-metatarsal . | 863 |
| tibio-fibular, inferior . | 855 |
| tibio-fibular, superior . | 855 |
| vertebral . . . | 809 |
| wrist . . . | 829 |
| Jugular eminence . . | 715 |
| ganglion . . . | 543 |
| vein, anterior . . | 432 |
| vein, external . | 15. 431 |
| vein, internal . | 40. 432 |
| | |
| Kidney . . . . | 283 |
| pathology of the . | 289 |
| Kiernan's researches on the liver . . . | 268 |
| Knee-joint . . . | 845 |
| | |
| Labia majora . . . | 347 |
| minora . . . | 347 |
| Labial artery . . . | 409 |
| Labyrinth . . . | 679 |
| membraneous . . | 683 |
| Lachrymal apparatus . | 622 |
| artery . . . | 412 |
| bone . . . | 741 |
| canals . . | 617. 623 |
| caruncle . . | 617. 620 |
| ducts . . | 617. 623 |
| gland . . . | 622 |
| nerve . . . | 532 |
| papilla . . . | 617 |
| puncta . . | 617. 623 |
| sac . . . . | 624 |
| Lacteals . . . . | 446 |
| Lacuna magna urethræ . | 345 |
| Lacus lachrymalis . . | 617 |
| Lambdoid suture . . | 732 |
| Lamina cornea . . . | 483 |
| cribrosa oculi . . | 644 |
| intercrural . . | 480 |

Page.
Lamina serosa retinæ . . 656
spiralis . . . 682
vasculosa retinæ . 657
Laryngeal artery . . 409
nerves . . . 68
nerve, inferior . 41. 545
nerve, recurrent . 545
nerve, superior . . 545
Larynx . . . . 57
articulations of . . 61
pathology of the . 70
ventricle of . . 68
Lateral sinuses . . . 463
Latissimus colli muscle . 26
dorsi muscle . . 138
Laxator tympani, major . 678
tympani, minor . . 679
Leg, dissection of . . 383
Lens, crystalline . . 658
Lenticular ganglion . . 534
Levator anguli oris muscle . 9
anguli scapulæ muscle 140
ani muscle . . . 313
glandulæ thyroideæ muscle . . . 32
labii inferioris muscle . 10
labii superioris alæque nasi muscle . . 9
menti muscle . . 10
oculi muscle . . 627
palati muscle . . 51
palpebræ superioris muscle . . . 625
Levatores costarum muscles. 82
urethræ muscles . 314
Lieberkühn, follicles of . 256
Lieutand, septum of . 113. 118
Ligaments . . . . 801
accessory, of the hip-joint . . . 841
accessory, of the shoulder . . . 822
acromio-clavicular, inferior . . . 819
acromio-clavicular, superior . . . 819
adipose . . . 849

Page
Ligaments—*continued.*
alar . . . . 849
annular, of ankle, anterior . . . 384
annular, of ankle, external . . . 384
annular, of ankle, internal . . . 384
annular, of the radius . 826
annular, of the wrist 162. 833
arcuatum, externum . 293
arcuatum, internum . 293
astragalo-scaphoid . 861
atlanto-axoid, anterior 809
atlanto-axoid, posterior 809
auricular . . . 668
of bladder, false . . 322
of bladder, true . . 324
Burn's . . . 216
calceo-astragaloid . 860
calceo-cuboid, inferior 862
calceo-cuboid, superior 862
calceo-scaphoid, inferior 861
calceo-scaphoid, superior . . . 862
capsular, atlanto-axoid 809
capsular, of the hip . 839
capsular, of the jaw . 803
capsular, occipito-atlantal . . . 805
capsular, of the rib . 813
capsular, of the shoulder 821
capsular, of the thumb 834
carpo-metacarpal, dorsal . . . 834
carpo-metacarpal, interosseous . . 834
carpo-metacarpal, palmar . . . 834
carpus, dorsal . . 831
carpus, interosseous . 831
carpus, palmar . . 831
check . . . 807
ciliary . . . 650
conoid . . . 820
coraco-acromial . 80. 820
coraco-clavicular 80. 820

Page.

LIGAMENTS—*continued.*
coraco-humeral . . 822
coracoid . . . . 821
coronary, of the knee . 851
coronary, of the liver . 264
costo-clavicular . . 817
costo-coracoid . 80. 820
costo-transverse, anterior . . . . 815
costo-transverse, middle . . . 815
costo-transverse, posterior . . . 815
costo-vertebral, anterior . . . 813
cotyloid . . . 842
crico-thyroid . . 62
crucial, anterior . 850
crucial, posterior . 851
cuneo-scaphoid . 863
deltoid of the ankle . 857
deltoid of the scapula . 820
denticulatum . . 506
falciform, of liver . 263
Fallopius' . . . 192
Gimbernaut's . . 193
glenoid . . . 821
glosso-epiglottic . . 60
Hey's . . . 217
hyo-epiglottic . . 60
hyo-glossal . . 606
hyo-thyroid . . 61
ilio-femoral . . 841
ilio-lumbar . . 836
infraspinous . . 812
interarticular, of the hip 842
interarticular, of the ribs . . . 814
interarticular, of shoulder 822
interclavicular . . 818
intermaxillary . 11. 802
intermuscular . . 149
interosseous astragalo-calcaneoid . . 860
interosseous, of the carpus 831
interosseous radio-ulnar 828
interosseous tibio-fibular 855

Page.

LIGAMENTS—*continued.*
interosseous tibio-fibular, inferior . . 856
interspinous . . 813
intertransverse . . 813
intervertebral . . 810
lateral, of the ankle . 857
lateral, of the elbow . 824
lateral, of the jaw . 802
lateral, of the knee . 847
lateral occipito-atlantal 806
lateral, of phalanges, foot . . . 864
lateral, of phalanges, hand . . . 835
lateral, of the wrist . 829
latum pulmonis . . 89
of the liver . . 263
lumbo-sacral . . 836
metacarpo-phalangeal . 835
metatarso-phalangeal . 864
moderator . . . 807
mucosum . . . 849
nuchæ . . 134. 812
oblique . . . 827
oblique, of the knee . 851
obturator . . . 839
occipito-atlantal, anterior 805
occipito-atlantal, posterior . . . 806
occipito-axoid, middle 806
odontoid . . . 807
of the ovary . 352. 356
palmar of the carpus . 831
patellæ . . . 846
phalangeal, of the foot 864
phalangeal, of the hand 835
plantar, of the tarsus . 862
posterior, of the elbow 825
posterior, of the wrist . 829
posticum, of Winslow . 846
Poupart's . . . 192
pterygo-maxillary . 11
pubic . . . 317
pubic, anterior . . 839
pubic, posterior . . 839
pubic, superior . . 839

Page.

LIGAMENTS—*continued.*
recto-coccygeal . . 305
recto-uterine . . 353
rhomboid . . . 817
sacciform . . . 828
sacro-coccygean, anterior . . . 837
sacro-coccygean, posterior . . . 837
sacro-iliac, anterior . 837
sacro-iliac, posterior . 837
sacro-sciatic, anterior . 838
sacro-sciatic, posterior 837
scapheo-cuboid . . 862
spino-glenoid . . 821
stellate . . . 813
sterno-clavicular, anterior . . . 817
sterno-clavicular, posterior . . . 817
sterno-costal, anterior . 816
sterno-costal, inferior . 816
sterno-costal, posterior 816
sterno-costal, superior . 816
stylo-maxillary . . 803
subflava . . . 812
subpubic . . . 839
supraspinous . . 812
suspensory, of the liver 263
suspensory, of the penis 340
tarsal . . . 860
of the tarsi, broad . 619
tarso-metatarsal . . 863
teres, of the hip . . 842
teres, of liver . . 263
thyro-arytenoid . . 62
thyro-epiglottic . . 61
thyro-hyoid . . 61
tibio-fibular, inferior anterior . . . 856
tibio-fibular, inferior posterior . . . 856
tibio-fibular, superior anterior . . . 855
tibio-fibular, superior posterior . . . 855
tibio-tarsal . . 858

Page.

LIGAMENTS—*continued.*
transverse, of the acetabulum . . . 842
transverse, of the atlas 808
transverse, of the knee 850
transverse, of the scapula 821
trapezoid . . . 820
triangular, of urethra . 311
uterus of the, broad . 351
uterus of the, round . 352
vertebral, anterior common . . . 809
vertebral, posterior common . . . 810
vesico-uterine . . 353
of Winslow . . 382
Linea alba . . . 189
ilio-pectinæa . . 763
Lineæ semilunares . . 190
transversæ . 191. 201
Lingual glands . . . 609
Lingual nerve . . . 41
papillæ . . . 609
plexus . . . 611
veins . . . 431
Linguales muscles . 38. 608
Lips . . . . 43
Liquor Cotunnii . . 683
Morgagni . . . 659
Scarpæ . . . 684
Liver . . . . 263
coats of . . . 267
ligaments of . . 263
lobes of . . . 265
pathology of the . 274
structure of the . . 268
Lobes of the cerebellum . 493
of the cerebellum, amygdaloid . . . 494
of the cerebellum, digastric . . . 494
of the cerebellum, flocculus . . . 494
of the cerebellum, gracilis . . . 494
of the cerebellum, inferior posterior . 494

Page.
Lobes of the cerebellum, median . . . . 495
of the cerebellum, median inferior . 493. 496
of the cerebellum, median superior . . 493
of the cerebellum, pneumogastric . . 494
of the cerebellum, semilunar . . . 494
of the cerebellum, superior anterior . 494
of the cerebellum, superior posterior . 494
of the cerebellum, tonsillitic . . 494
of the cerebrum . . 477
of the liver . . 265
Lobules of the testis . . 335
Lobulus auris . . . 668
caudatus . . . 265
quadratus . . . 265
Spigelii . . . 265
Locus niger . . 489. 516
perforatus . 480. 488
Longissimus dorsi muscle . 143
Longitudinal sinus, inferior 462
sinus, superior . . 461
Longus colli muscle . . 72
Lower jaw . . . 742
jaw, dislocation of 21. 804
jaw, motions of . 20. 804
Loweri tuberculum . . 111
Lumbar aponeurosis . . 135
arteries . . 282. 421
fascia . . 135. 198
ganglions of the sympathetic . . . 583
meso-colons . 235, 236
nerves . . . 561
plexus . . . 562
regions . . . 226
veins . . . 439
Lumbo-aortic plexus . . 584
sacral nerve . . 567
Lumbricales muscles . . 169
pedis . . . 398

Page.
Lunar bone . . . 794
Lungs . . . . 92
Lunula . . . . 595
Lymphatic glands and vessels . . . 446
abdominal . . 449
axillary . . . 448
brachial . . . 448
bronchial . . 450
cervical . . . 448
cranial . . . 453
head and face . . 448
inguinal . . . 449
intestinal . . 449. 451
lacteals . . . 451
liver . . . 451
lower extremity . 450
lumbar . . 449. 451
lungs . . . 450
mesenteric . 449. 451
pelvic . . . 449
spleen . . . 449
stomach . . . 449
upper extremity . 448
Lyra . . . 481. 484

Macula cribrosa . . 680
Malar bone . . . 737
nerves . . . 537
Malleolar arteries . . 426
Malleolus, external . . 780
internal . . . 778
Malleus . . . . 677
Malpighian corpuscles . 285
Mammary artery, internal . 415
gland . . . 75
Mammæ . . . . 74
pathology of the . . 77
Manubrium of sternum . 753
Masseter muscle . . 16
Masseteric arteries . . 411
nerves . . . 538
Mastoid cells . . 675. 723
process . . . 723
Matrix of the nail . . 595
Maxillary artery, external . 409
artery, internal . 22. 410

Page
Maxillary bone, inferior . 742
bone, superior . . 737
nerve, inferior . . 537
nerve, superior . . 535
vein, internal . . 431
Measurements, of the parts concerned in inguinal and femoral hernia 225. 226
Meatus auditorius, externus 669
auditorius, internus . 679
urinarius, female . 348
urinarius, male . . 342
Meatuses of the nares . 603
Meckel's ganglion . . 535
Median basilic vein . 161. 436
cephalic vein . 161. 436
nerve . . 183. 555
vein . . . 161. 436
Mediastinum, anterior . 86
middle . . . 90
posterior . . . 90
testis . . . 334
Medulla, of bones . . 695
oblongata . . 500
spinalis . . . 507
Meibomian glands . 594. 619
Membrana flaccida . . 673
Jacobi . . . 656
pupillaris . . . 654
Ruyschiana . 648, 649
tympani . . . 671
tympani, structure of . 673
Membrane, albugineal, of eye 629
of the aqueous humour 658
arachnoid, cranial . 464
arachnoid, spinal . 505
basement . . . 261
of brain . . . 455
choroid, of brain . . 485
choroid, of eye . . 647
of Demours . . 646
hyaloid . . . 661
interosseous, radio-ulnar 828
interosseous, tibio-fibular . . . 855
of the labyrinth . 683

Page.
Membrane, mucous . . 259
papillary, of skin . 593
pituitary . . . 603
Schneiderian . . 603
synovial . . . 800
Membraneous labyrinth . 683
portion of the urethra 342. 344
semicircular canals . 684
Meningea media, artery . 410
Mental nerve . . 23. 538
Mental process . . . 742
Mesenteric artery, inferior 280. 421
artery, superior . 280. 420
glands . . . 449
plexus, inferior . . 583
plexus, superior . 583
Mesentery . . . 236
Meso-cæcum . . . 237
Meso-cephale . . . 490
Meso-colons, lumbar 235, 236
Meso-colon, transverse . 235
Meso-rectum . . . 237
Metacarpal bones . . 795
Metacarpo-phalangeal articulations . . 833
Metatarsal arteries . . 426
Metatarsus, bones of . . 784
Middle mediastinum . . 90
Mitral valves . . . 117
Moderator ligaments . . 807
Modiolus . . . . 681
Molar teeth . . . 745
Mons Veneris . . . 347
Morgagni, liquor of . . 659
sinus of, pharyngeal . 48
sinuses of . . 114. 118
Morsus diaboli . . . 356
Motor tracts . . . 509
uvulæ muscle . . 52
Motores oculorum nerves 524. 531
Mouth, dissection of . . 42
Mucous membrane . . 259
MUSCLES of the Abdomen 186
abductor indicis . . 180
abductor minimi digiti 178

Page.
MUSCLES—*continued.*
abductor minimi digiti pedis . . . 397
abductor pollicis . 177
abductor pollicis longus 174
abductor pollicis pedis 396
abductor oculi . . 628
accelerator urinæ . 309
accessorii (dorsal) . 143
accessorius . . 398
adductor brevis . . 369
adductor longus . 369
adductor magnus . 370
adductor minimi digiti 178
adductor oculi . . 627
adductor pollicis . 178
adductor pollicis pedis 399
anconæus . . . 173
anterior, auris . . 5
antitragicus . . 668
aryteno-epiglottici . 65
arytenoideus . . 64
attollens aurem . 4
attrahens aurem . 5
auriculæ transversus . 668
auricularis . . 173
azygos uvulæ . . 52
of the back . . 134
Bell's, of the ureters . 328
biceps . . . 155
biceps flexor cruris . 380
brachialis anticus . 157
buccinator . . 11
caninus . . . 9
cardiac, actions of . 130
cervicalis ascendens . 143
cervicalis descendens . 143
circumflexus palati . 51
coccygeus . . . 317
complexus . . 144
compressores nasi . 8
compressores penis . 308
compressores urethræ . 314
compressores urethræ transversi . . 315
compressores venæ dorsalis penis . . 310

Page.
MUSCLES—*continued.*
constrictor iridis . 654
constrictor isthmi faucium . . . 52
constrictor pharyngis, inferior . . . 46
constrictor pharyngis medius . . . 47
constrictor pharyngis, superior . . 48
coraco-brachialis . 155
corrugator supercilii . 8
cremaster . . . 195
crico-arytenoideus lateralis . . . 64
crico-arytenoideus posticus . . . 64
crico-thyroideus . 63
cruræus . . . 368
deltoides . . . 150
depressor anguli oris . 10
depressor labii inferioris 10
depressor labii superioris alæque nasi . 10
depressor oculi . . 628
detrusor urinæ . . 325
diaphragm . . 290
digastricus . . 33
of the ear . . . 4, 5
ejaculator seminis . 309
erector clitoridis . 349
erector penis . . 308
extensor carpi radialis brevis . . 172
extensor carpi radialis longus . . . 171
extensor carpi ulnaris 172
extensor digitorum brevis pedis . . 388
extensor digitorum communis . . . 172
extensor digitorum longus pedis . . . 387
extensor indicis . . 175
extensor minimi digiti 173
extensor ossis metacarpi pollicis . . . 174

| | Page. |
|---|---|
| MUSCLES—*continued.* | |
| extensor pollicis major | 175 |
| extensor pollicis minor | 174 |
| extensor pollicis proprius pedis . . | 387 |
| extensor primi internodii pollicis . . | 174 |
| extensor secundi internodii pollicis . . | 175 |
| of the face . . | 6 |
| flexor brevis minimi digiti . . . | 178 |
| flexor brevis minimi digiti pedis . . | 400 |
| flexor carpi radialis . | 165 |
| flexor carpi ulnaris . | 166 |
| flexor digitorum accessorius . . . | 398 |
| flexor digitorum brevis pedis . . . | 397 |
| flexor digitorum longus pedis . . . | 394 |
| flexor digitorum profundus perforans . | 168 |
| flexor digitorum sublimis perforatus . | 166 |
| flexor ossis metacarpi pollicis . . . | 177 |
| flexor pollicis brevis . | 177 |
| flexor pollicis brevis pedis . . . | 399 |
| flexor pollicis longus . | 169 |
| flexor pollicis longus pedis . . . | 395 |
| gastrocnemius . . | 390 |
| gemellus inferior . | 377 |
| gemellus superior . | 377 |
| genio-hyo-glossi | 37. 607 |
| genio-hyoideus . . | 35 |
| glutæus maximus . | 374 |
| glutæus medius . . | 376 |
| glutæus minimus . | 376 |
| gracilis . . . | 368 |
| helicis major . . | 668 |
| helicis minor . . | 668 |
| of hip . . . | 374 |
| hyo-glossi . | 37. 607 |

| | Page. |
|---|---|
| MUSCLES—*continued.* | |
| hyo-pharyngeus . | 47 |
| iliacus internus . . | 303 |
| indicator . . . | 175 |
| infraspinatus . . | 152 |
| intercostales . . | 82 |
| interossei manus, posteriores . . . | 180 |
| interossei palmar . | 179 |
| interossei pedis inferiores . . . | 400 |
| interossei pedis superiores . . . | 401 |
| interspinales . . | 145 |
| intertransversales . | 145 |
| ischio-bulbosus . . | 310 |
| latissimus colli . . | 26 |
| latissimus dorsi . . | 138 |
| laxator tympani major . . . | 678 |
| laxator tympani minor | 679 |
| levator anguli oris . | 9 |
| levator anguli scapulæ | 140 |
| levator ani . . | 313 |
| levator glandulæ thyroideæ . . . | 32 |
| levator labii inferioris . | 10 |
| levator labii superioris alæque nasi . . | 9 |
| levator menti . . | 10 |
| levator oculi . . | 627 |
| levator palati . . | 51 |
| levator palpebræ superioris . . . | 625 |
| levator urethræ . . | 314 |
| levatores costarum . | 82 |
| linguales . . | 38. 608 |
| longissimus dorsi . | 143 |
| longus colli . . | 72 |
| lumbricales manus . | 169 |
| lumbricales pedis . | 398 |
| masseter . . . | 16 |
| motor uvulæ . . | 52 |
| multifidus spinæ . | 145 |
| mylo-hyoideus . . | 35 |
| obliquus abdominis externus . . . | 188 |

MUSCLES—*continued*. Page.
obliquus abdominis internus . . . 194
obliquus capitis, inferior . . . 146
obliquus capitis, superior . . . 146
obliquus oculi, inferior 632
obliquus oculi, superior . . . 632
obturator externus . 379
obturator internus . 377
occipito frontalis . 2
omo-hyoideus . . 31
opponens minimi digiti 178
opponens pollicis . 177
orbicularis oris . . 11
orbicularis palpebrarum 6. 618
palato-glossus . 52. 608
palato-pharyngeus . 52
palmaris brevis . . 164
palmaris longus . . 166
pectinæus . . . 369
pectoralis major . . 77
pectoralis minor . 79
peroneus brevis . . 389
peroneus longus . 388
peroneus tertius . 388
plantaris . . . 391
platysma myoides . 26
poplitæus . . . 393
pronator quadratus . 170
pronator radii teres . 165
psoas magnus . . 301
psoas parvus . . 300
pterygoideus externus 20
pterygoideus internus. 19
pyramidalis abdominis 202
pyramidalis nasi . 8
pyriformis . . 376
quadratus femoris . 378
quadratus lumborum . 300
quadratus menti . 10
quadriceps extensor cruris . . . 367
rectus abdominis . 200

MUSCLES—*continued*. Page.
rectus capitis anticus major . . . 72
rectus capitis anticus minor . . . 72
rectus capitis lateralis . 72
rectus capitis posticus major . . . 145
rectus capitis posticus minor . . . 146
rectus femoris . . 366
rectus oculi externus . 628
rectus oculi inferior . 628
rectus oculi internus . 627
rectus oculi superior . 627
retrahens aurem . 5
rhomboideus major . 140
rhomboideus minor . 139
risorius Santorini . 26
sacro-lumbalis . . 143
sartorius . . . 365
scalenus anticus . 72
scalenus medius . . 73
scalenus posticus . 73
semimembranosus . 381
semispinalis colli . 144
semispinalis dorsi . 144
semitendinosus . . 381
serratus magnus . 80
serratus posticus inferior . . . 140
serratus posticus superior . . . 140
solæus . . . 392
sphincter ani externus 305
sphincter ani internus 306
sphincter iridis . . 654
sphincter oculi . 6. 618
sphincter oris . . 11
sphincter vaginæ . 349
sphincter vesicæ . 326
spinalis colli . . 144
spinalis dorsi . . 143
splenius capitis . . 141
splenius colli . . 141
stapedius . . . 678
sterno-cleido-mastoideus 28

Page.

MUSCLES—*continued.*
sterno-costalis . . 82
sterno-hyoideus . . 31
sterno-thyroideus . 31
stylo-glossus . 38. 607
stylo-hyoideus . . 38
stylo-pharyngeus 38. 47
subclavius . . 80
subcruræus . . 368
subscapularis . . 153
superior auris . . 4
supinator radii brevis . 174
supinator radii longus 171
supraspinatus . . 151
supraspinous . . 145
suspensorius testis . 195
temporalis . . 16
tensor palati . . 51
tensor tarsi . . 8
tensor tympani . . 678
tensor vaginæ femoris 364
teres major . . 154
teres minor . . 152
thyro-arytenoideus . 63
thyro-epiglottic . 65
thyro-hyoideus . . 63
tibialis anticus . . 386
tibialis posticus . . 395
trachelo-mastoideus . 144
tragicus . . . 668
transversalis abdominis 196
transversalis colli . 143
transversalis pedis . 399
transversalis perinæi . 310
transversus auriculæ . 668
trapezius . . . 137
triangularis oris . . 10
triangularis sterni . 82
triceps adductor femoris . . . . 369
triceps extensor cubiti . 157
trochleator . . 632
tympani laxator major 678
tympani laxator minor 679
tympani tensor . . 678
vastus externus . . 367
vastus internus . . 367

Page.

MUSCLES—*continued.*
zygomaticus major . 9
zygomaticus minor . 9
Muscular artery . . 409
fibres of auricles of the heart . . . 126
fibres of ventricles of the heart . . 127
tissue of the heart . 124
Musculi papillares . 112. 117
pectinati . . 111
Musculo-cutaneous nerve of arm . . . 555
of leg . . . 571
of lumbar plexus inferior . . . 563
Musculo-cutaneous nerve of lumbar plexus, middle . . . 562
superior . . . 562
Musculo-spiral nerve . 183. 558
Mylo-hyoideus muscle . 35
Mylo-hyoid nerve . . 538
Myopia . . . . 664
Myrtiform fossa . . 739

Naboth, ovula of . . 354
Nails . . . . 595
Nares . . . . 602
Nares, posterior . . 49
Nasal artery . . 411, 412
bones . . . 741
cartilages, or fibro-cartilages . . . 600
duct . . . 624
fossæ . . . 602
lamella of ethmoid bone 727
nerve . . . 533
process of superior maxillary bone . . 737
spine . . . 719
Naso-palatine ganglion . 536
Naso-palatine nerve . . 536
Nates cerebri . . . 490
Navicular bone of carpus . 794
bone of tarsus . . 783
fossa . . . 666

Page.
Neck, deep muscles of . 71
dissection of . . 24
triangles of . . 29
vessels and nerves of . 39
NERVES of abdomen . . 280
abducentes . 527. 533
accessorius . 528. 546
anterior crural . . 563
anterior thoracic . 553
anterior tibial . . 572
ascendens colli . . 15
auditory . 528. 543. 685
auricular, or temporo-auricular . . 538
auricular . . . 544
auricular, posterior . 542
auricularis magnus . 549
axillary . . . 553
brachial . . 84. 555
buccal . . . 538
cardiac . . 123. 545
cardiac, great . 578, 579
cardiac, inferior . 579, 580
cardiac, middle . 578, 579
cardiac, superior . 578, 579
cerebral, dissection of . 530
cerebral, origins of . 523
cervical, spinal . 41. 548
cervico-facial . . 542
ciliary . . 533, 534
circumflex . . 554
cochlear . . . 685
communicans noni . 550
communicans peronæi 571
communicans tibialis 383. 573
communicating, lumbar 567
corda tympani 536. 541. 676
Cotunnii . . . 536
crural, anterior . . 563
crural, posterior . . 570
cutaneous, of arm, external . . . 555
cutaneous, of arm, internal . . . 554
cutaneous, of arm, internal, lesser . . 555

Page.
NERVES—*continued.*
cutaneous of back, inferior . . . 559
cutaneous of back, superior . . . 559
cutaneous, of the leg, external . . 571
cutaneous, of the leg, internal . . 565
cutaneous, of the leg, posterior . . 572
cutaneous, of thigh, anterior . . . 564
cutaneous of thigh, posterior . . . 562
deltoid . . . 554
dental, anterior . . 537
dental, inferior . . 538
dental, posterior . 537
descendens, colli . 547
descendens, noni 41. 547
digastric . . . 542
digital, of fingers . 556
digital, of toes . . 574
dorsal . . . 558
dorsal, first . . 560
dorsalis carpi ulnaris . 557
dorsalis pedis . . 571
dorso-lumbar . . 560
eighth pair 40. 528. 543
external respiratory . 552
facial . 527. 540. 686
fifth pair . . 525. 532
first pair . . 523. 530
fourth pair . 525. 532
frontal . . 22. 533
genito-crural . . 563
glosso-pharyngeal 40. 528. 543
glutæal, inferior . . 569
glutæal, superior . 567
gustatory . . 40. 539
of the heart . . 123
ilio-scrotal . . 562
inferior laryngeal . 545
inferior maxillary . 537
infraclavicular . . 553

Page.

NERVES—*continued.*
infraorbital . 23. 537
infratrochleator . . 533
inguino-cutaneous . 562
intercostal . . 559
intercosto-humeral . 560
internal cutaneous of arm . . . 554
internal cutaneous, of arm, lesser . . 555
internal respiratory . 550
interosseal, of arm, anterior . . . 556
interosseal, of arm, posterior . . . 558
interosseal, of leg . 572
Jacobson's . . . 543
lachrymal . . . 532
laryngeal, functions of 68
laryngeal, inferior 41. 545
laryngeal, superior . 545
lingual . 41. 528. 547
lumbar . . . 561
lumbo-sacral . . 567
malar . . . 537
masseteric . . . 538
maxillary, inferior . 537
maxillary, superior . 535
median . . 183. 555
mental . . 23. 538
molles . . . 577
motores oculorum 524. 531
musculo-cutaneous, of arm . . . 555
musculo-cutaneous, of leg . . . 571
musculo-cutaneous lumbar, inferior . . 563
musculo-cutaneous lumbar, middle . . 562
musculo-cutaneous lumbar, superior . . 562
musculo-spiral . 183. 558
mylo-hyoid . . 538
nasal . . . 533
naso-palatine . . 536
ninth pair . 41. 528. 547

Page.

NERVES—*continued.*
obturator . . . 566
obturator, accessory . 566
occipitalis, major . 551
occipitalis, minor . 549
œsophageal . . 546
olfactory . . 523. 530
ophthalmic . . 532
optic . 524. 530. 637
orbital . . . 537
orbital, functions of the 637
palatine . . . 535
palmar, deep . . 557
palmar, superficial . 557
par vagum . 528. 543
pathetici . . 525. 532
pelvic . . . 568
perforans Casserii . 555
perinæal . . . 569
peroneal . . 390. 571
petrosal, external . 541
petrosal, superficial . 539
petrosal, superior . 536
pharyngeal . . 545
phrenic . 42. 99. 550
plantar, external . 574
plantar, internal . 574
pneumogastric 40. 528. 544
poplitæal, external . 571
poplitæal, internal . 572
portio dura 15. 22. 527. 540. 686
portio mollis 528. 543. 685
posterior crural . . 570
posterior thoracic . 552
posterior tibial . . 573
pterygoid . . . 538
pudic . . . 569
pulmonary . . 546
radial . . 183. 558
recurrent laryngeal 41. 545
respiratory, external . 552
respiratory, of face . 542
respiratory, internal . 550
respiratory, of neck . 547
sacral . . . 567
saphenous, external . 573

Page.

NERVES—*continued.*
saphenous, long, or inferior . . . 565
saphenous, short, or superior . . . 564
sciatic, great . . 570
sciatic, lesser . . 569
second pair 524. 530. 637
seventh pair . 527. 540
sixth pair . . 527. 533
spheno-palatine . . 535
spinal accessory 40. 528. 546
spinal, dissection of . 548
spinal, origins of . 511
spinal, functions of . 512
splanchnic, great 91. 581
splanchnic, lesser 92. 581
stylo-hyoid . . 542
submastoid . . 542
suboccipital . . 548
suboccipital, anterior division . . . 548
suboccipital, posterior division . . . 550
subscapular . . 554
superficialis colli 15. 549
superficialis cordis 578, 579
superior laryngeal . 545
superior maxillary . 535
supraclavicular . 549. 552
supraorbital . . 533
suprascapular . . 553
supratrochleator . 533
sympathetic 41. 282. 574
tarsal . . . 571
temporal . . . 537
temporal, deep . . 537
temporo-auricular 15. 538
temporo-facial . . 542
third pair . . 524. 531
thoracic, anterior . 553
thoracic, posterior . 552
tibial, anterior . . 572
tibial, posterior . 402. 573
trifacial . . 525. 532
trigemini . . 525. 532
trochleatores . 525. 532

Page.

NERVES—*continued.*
tympanic . . 541. 543
ulnar . . 183. 556
vagus . . . 528. 544
vestibular . . . 685
Vidian . . . 536
of Wrisberg 150. 555. 560
Nervous system . . 455
Neurine, grey . . . 472
white . . . 472
Nidus hirundinis . . 497
Ninth pair of nerves 41. 528. 547
Nipple . . . . 75
Nodulus . . . . 496
Nose, anatomy of . . 599
cartilages of . . 600
Nuchæ ligamentum . . 134
Nuck's canal . . . 352
Nymphæ . . . . 347
Obliquus abdominis externus muscle . . 188
abdominis internus muscle . . . 194
capitis inferior muscle . 146
capitis superior muscle 146
oculi, inferior . . 632
oculi, superior . . 632
Obturator artery . . 423
fascia . . 308. 319
foramen . . . 767
muscle, externus . 379
muscle, internus . 377
nerve . . . 566
nerve, accessory . 566
Occipital artery . . 409
bone . . . 713
sinuses . . . 464
veins . . . 430
Occipitalis major nerve . 551
minor nerve . . 549
Occipito-atlantal articulation 805
Occipito-axoid articulation 806
Occipito-frontalis muscle . 2
Ocular fascia . . . 628
Oculo-palpebral space . 621
Odontoid ligaments . . 807
process . . . 704

| | Page. |
|---|---|
| Odoriferous glands | 595 |
| Œsophageal arteries | 418 |
| nerves | 546 |
| plexus | 91. 546 |
| Œsophagus | 56. 90. 104 |
| pathology of the | 56 |
| Olecranon | 791 |
| Olfactory bulb | 524 |
| lobes | 524 |
| nerves | 523. 530 |
| Olivary ganglion | 501 |
| process of sphenoid bone | 730 |
| tracts | 516 |
| Olive-shaped bodies | 501. 516 |
| Omentum, colic | 236 |
| great or gastro-colic | 234 |
| lesser or gastro-hepatic | 234 |
| pathology of the | 262 |
| sac of | 235 |
| splenic | 236 |
| Omo-hyoideus muscle | 31 |
| Ophthalmic artery | 412. 636 |
| ganglion | 534 |
| nerve | 532 |
| vein | 431. 636 |
| Opponens minimi digiti muscle | 178 |
| pollicis muscle | 177 |
| Optic commissure | 524 |
| lobes | 491 |
| nerves | 524. 530. 637 |
| thalami | 487 |
| tract | 524 |
| Optics | 662 |
| Orbicular bone | 677 |
| Orbicularis oris muscle | 11 |
| palpebrarum muscle | 6. 618 |
| Orbital muscles, actions of | 630. 633 |
| nerves | 537 |
| nerves, functions of the | 637 |
| plate of superior maxillary bone | 737 |
| plexus | 531 |
| processes of frontal bone | 721 |

| | Page. |
|---|---|
| Orbits | 613 |
| angles of | 615 |
| apex of | 614 |
| axes of | 615 |
| base of | 614 |
| dissection of | 531 |
| foramina in | 615 |
| walls of | 614 |
| Organ of hearing | 665 |
| of smell | 599 |
| of taste | 605 |
| of touch | 586 |
| of vision | 612 |
| Organs of sense | 586 |
| Orifice of the thorax, upper | 98 |
| Orifices of the thorax | 86 |
| Os hyoides | 57 |
| innominatum | 765 |
| planum | 728 |
| uteri, or os tincæ | 353 |
| Ossa Wormea or triquetra | 717 |
| Osseous system, anatomy of | 688 |
| tissue | 696 |
| Ossicula auditus | 676 |
| Ossification, process of | 697 |
| Ostium abdominale | 356 |
| externum | 353 |
| internum | 353 |
| uterinum | 356 |
| Otic ganglion | 539 |
| Otoconia | 684 |
| Otolithi | 684 |
| Ourlet, or hem-like convolution | 474 |
| Ovaria | 356 |
| Ovarian ligament | 352. 356 |
| veins | 439 |
| Oviducts of Fallopius | 356 |
| Ovula Graafiana | 357 |
| of Naboth | 354 |
| Ovum | 357 |
| Pacchionii glandulæ | 462 |
| Pacinian corpuscles | 557 |
| Palate bone | 739 |
| dissection of the | 50 |
| pillars or arches of | 49, 50 |

| | Page. |
|---|---|
| Palate, soft | 42. 50 |
| Palatine artery, inferior | 409 |
| artery, superior | 411 |
| nerves | 535 |
| Palato-glossus muscle | 52. 608 |
| pharyngeus muscle | 52 |
| Palmar fascia | 163 |
| nerve, deep | 557 |
| nerve, superficial | 557 |
| Palmaris brevis muscle | 164 |
| longus muscle | 166 |
| profunda artery | 418 |
| superficialis artery | 417 |
| Palpebræ | 616 |
| Palpebral arteries | 412 |
| canthi | 616 |
| cartilages | 619 |
| fissure | 616 |
| Pancreas | 279 |
| pathology of the | 279 |
| Pancreatic arteries | 280 |
| duct | 279 |
| Pancreatico-duodenalis artery | 280. 420 |
| Panniculus carnosus | 589 |
| Papillæ, button-shaped | 609 |
| calyciformes | 609 |
| circumvallate | 609 |
| conical | 610 |
| dental | 748 |
| filiform | 610 |
| of fingers | 593 |
| fungiformes | 610 |
| of the kidney | 286 |
| lachrymal | 617 |
| of the nail | 595 |
| of the tongue | 609 |
| Papillary membrane of skin | 593 |
| Par vagum nerve | 40. 528. 543 |
| Parallax, aberration from | 663 |
| Parietal bone | 716 |
| Parotid gland | 14 |
| Parotid gland, pathology of | 16 |
| Parotidean plexus | 15. 542 |
| region | 34 |
| Parotidis socia | 14 |
| Patella | 776 |

| | Page. |
|---|---|
| Patella, dislocations of | 853 |
| Pathetic nerves | 525. 532 |
| Pathology of the arachnoid membrane | 522 |
| of the bladder | 330 |
| of the brain | 522 |
| of the dura mater | 521 |
| of the gall-bladder | 277 |
| of the generative organs, female | 358 |
| of the generative organs, male | 345 |
| of the heart | 132 |
| of the intestinal tube | 262 |
| of the kidney | 289 |
| of the larynx | 70 |
| of the liver | 274 |
| of the lungs | 97 |
| of the mammary gland | 77 |
| of the œsophagus | 56 |
| of the omentum | 262 |
| of the palate | 55 |
| of the pancreas | 279 |
| of the parotid gland | 16 |
| of the pericardium | 107 |
| of the peritonæum | 262 |
| of the pharynx | 56 |
| of the pia mater | 522 |
| of the pleuræ | 97 |
| of the prostate gland | 345 |
| of the scalp | 4 |
| of the spleen | 278 |
| of the stomach | 262 |
| of the submaxillary gland | 35 |
| of the testicle | 345 |
| of the thyroid body | 33 |
| of the tongue | 44 |
| of the tonsil | 56 |
| of the trachea | 70 |
| of the urethra, male | 346 |
| of the uvula | 56 |
| Pectinæus muscle | 369 |
| Pectoralis major muscle | 77 |
| minor muscle | 79 |
| Peduncles of the cerebellum, inferior | 502 |

| | Page. |
|---|---|
| Peduncles of pineal body | 486 |
| Pelvic cavity, dissection of | 318 |
| fascia | 319 |
| glands | 449 |
| nerves | 568 |
| Pelvis, bones of | 761 |
| dimensions of | 771 |
| false | 769 |
| female | 770 |
| general observations | 767 |
| of the kidney | 287 |
| true | 769 |
| Penis | 339 |
| dorsal artery of | 423 |
| Perforans Casserii nerve | 555 |
| Perforated plate of brain, external | 479 |
| plate of brain, middle | 480 |
| Perforating arteries of thigh | 425 |
| Pericardium | 105 |
| pathology of the | 107 |
| perforations of fibrous layer of | 106 |
| Perilymph | 683 |
| Perinæal artery | 423 |
| artery, transverse | 423 |
| fascia, deep | 307. 311 |
| fascia, middle | 307 |
| fascia, superficial | 306 |
| Perinæum, male | 303 |
| Peritonæum | 229 |
| external surface of | 228 |
| pathology of the | 262 |
| Peroneal artery | 427 |
| artery, anterior | 427 |
| artery, posterior | 427 |
| nerve | 390. 571 |
| Peroneus brevis muscle | 389 |
| longus muscle | 388 |
| tertius muscle | 388 |
| Perspiration | 587 |
| Pes anserinus | 15. 22. 542 |
| hippocampi | 485 |
| Petit, canal of | 662 |
| Petrosal nerve, external | 541 |
| nerve, superficial | 539 |
| nerve, superior | 536 |
| Petrosal sinuses | 464 |
| Petrous ganglion | 543 |
| Peyer, glands of | 256 |
| Phalangeal articulations of the foot | 864 |
| articulations of the hand | 835 |
| Pharyngeal aponeurosis | 46 |
| artery, ascending | 410 |
| nerve | 545 |
| plexus | 543. 545 |
| Pharynx, dissection of | 45 |
| openings into | 49 |
| pathology of the | 56 |
| Phrenic arteries | 282. 419 |
| nerve | 42. 99. 550 |
| plexus | 582 |
| veins, inferior | 439 |
| Pia mater, cranial | 468 |
| mater, pathology of the | 522 |
| mater, spinal | 507 |
| Pigmentum nigrum | 649 |
| Pillars of the fornix | 484 |
| of the palate | 49, 50 |
| Pineal body | 486 |
| Pinna | 666 |
| Pisiform bodies | 480 |
| bone | 795 |
| Pituitary body | 479 |
| membrane | 603 |
| Plantar artery, external | 427 |
| artery, internal | 427 |
| fascia | 385 |
| nerve, external | 574 |
| nerve, internal | 574 |
| Plantaris muscle | 391 |
| Platysma myoides muscle | 26 |
| Pleura costalis | 87 |
| fibrous layer of | 89 |
| pulmonalis | 87 |
| Pleuræ | 87 |
| pathology of the | 97 |
| Plexus, basilar | 544 |
| brachial | 42. 84. 159. 551 |
| cardiac | 123 |
| cardiac, anterior | 580 |
| cardiac, great | 580 |
| cardiac, posterior | 580 |

| | Page. |
|---|---|
| Plexus, carotid, internal | 577 |
| cavernous | 577 |
| cervical, anterior | 41. 549 |
| cervical, posterior | 551 |
| choroid | 483 |
| choroid of the fourth ventricle | 496 |
| choroid of lateral ventricles | 470 |
| choroid of the third ventricle | 486 |
| cœliac | 92. 281 |
| coronary | 123. 580 |
| gastric | 582 |
| gulæ | 546 |
| hæmorrhoidal | 583 |
| hepatic | 582 |
| hypogastric | 584 |
| lingual | 611 |
| lumbar | 562 |
| lumbo-aortic | 584 |
| mesenteric, inferior | 583 |
| mesenteric, superior | 583 |
| œsophageal | 91. 546 |
| orbital | 531 |
| parotidæan | 15. 542 |
| pharyngeal | 543. 545 |
| phrenic | 582 |
| pulmonary, anterior | 546 |
| pulmonary, posterior | 546 |
| renal | 287. 583 |
| sacral | 568 |
| solar | 92. 281. 582 |
| spermatic | 583 |
| splenic | 583 |
| submaxillary | 536. 539 |
| suprarenal | 582 |
| tonsillitic | 544 |
| tympanic | 686 |
| vertebral | 579 |
| Plica semilunaris | 620 |
| Pneumogastric ganglion, inferior | 544 |
| ganglion, superior | 544 |
| lobe | 494 |
| nerve | 40. 528. 544 |
| Pomum Adami | 58 |

| | Page. |
|---|---|
| Pons Tarini | 480 |
| Varolii | 491 |
| Popliteal artery | 426 |
| nerve, external | 571 |
| nerve, internal | 572 |
| region | 382 |
| vein | 437 |
| Poplitæus muscle | 393 |
| Pores | 590 |
| Portal vein | 269. 281 |
| Portio dura nerve | 15. 22. 527. 540. 686 |
| mollis nerve | 528. 543. 685 |
| Porus opticus | 644. 655 |
| Posterior auris muscle | 5 |
| mediastinum | 90 |
| Pouches, inguinal | 209. 212 |
| Poupart's ligament | 192 |
| Prelumbo-thoracic vein | 434 |
| Prepuce | 339 |
| Presbyopia | 665 |
| Prevertebral fascia | 28 |
| Process, acromion | 786 |
| alveolar | 739 |
| auditory, external | 723 |
| azygos, of sphenoid bone | 729 |
| basilar | 714 |
| ciliary | 651 |
| clinoid, of sphenoid bone | 730 |
| coronoid, of lower jaw | 743 |
| coronoid, of ulna | 791 |
| hamular, of sphenoid bone | 731 |
| mastoid | 723 |
| nasal, of superior maxillary bone | 737 |
| odontoid | 704 |
| olecranon, of ulna | 791 |
| olivary, of sphenoid bone | 730 |
| orbital, of frontal bone | 721 |
| pterygoid | 731 |
| of Rau | 677 |
| styloid, of temporal bone | 724 |
| vaginal, of temporal bone | 724 |

Page.
Process, vermiform, inferior 493. 496
vermiform, superior 493. 495
zygomatic, of temporal bone . . . 722
Processus a cerebello ad testes . . 490. 499
Profunda artery, inferior . 417
artery, superior . . 416
femoris artery . . 425
Promontory . . . 675
of sacrum . . . 709
Pronator quadratus muscle 170
radii teres muscle . 165
Prostate gland . . . 338
gland, pathology of the 345
Prostatic sinuses . . 344
veins . . . 438
portion of the urethra 342. 344
Protuberance, cerebral . 491
occipital . . 713
Psalterium . . 481. 484
Psoas magnus muscle . 301
Psoas parvus muscle . . 300
Pterygoid arteries . . 411
nerves . . . 538
process . . . 731
Pterygoideus externus muscle . . . 20
internus muscle . 19
Pterygo-maxillary ligament 11
Pubic ligament . . 317
region . . . 226
symphysis . . 838
Pubis, bone of . . . 764
Pudic artery, internal . 423
arteries, superficial . 425
nerve . . . 569
Pulmonary artery . . 115
artery, orifice of . 114
nerves . . . 546
plexus, anterior . 546
plexus, posterior . 546
sinuses . . . 114
veins . . . 427
Puncta lachrymalia . 617. 623
Pupil . . . . 652

Page.
Pupillary membrane . 654
Pyloric artery, inferior . 420
artery, superior . . 420
valve . . . 243
Pylorus . . . . 240
Pyramid of the cerebellum . 496
of the medulla oblongata, anterior 501. 515
of the medulla oblongata, posterior 502. 515
(in the tympanum) . 675
of vertebral column . 708
Pyramidal bone of carpus . 794
Pyramidalis muscle . . 202
nasi muscle . . 8
Pyriformis muscle . . 376

Radial artery . . 182. 418
artery, recurrent . 418
nerve . . 183. 558
Radialis indicis artery . 418
Radio-ulnar articulations . 826
Radius . . . . 792
Rami of lower jaw . . 743
Ramus of ischium . . 764
Ramus of pubis . . 764
Ranine arteries . . 409
vein . . . 431
Raphe corporis callosi . 481
of the perinæum . 305
Rau, process of . . 677
Receptaculum chyli . 283. 452
Rectal fascia . . 314. 320
Recto-bulbar region . . 321
Recto-coccygeal ligament . 305
Recto-uterine ligaments . 353
Recto-vesical fascia . 312. 320
Rectum . . . . 252
structure of . . 258
Rectus abdominis muscle . 200
capitis anticus major muscle . . . 72
capitis anticus minor muscle . . 72
capitis lateralis muscle 72
capitis posticus major muscle . . . 145

| | Page. |
|---|---|
| Rectus capitis posticus minor muscle | 146 |
| femoris muscle | 366 |
| oculi, externus | 628 |
| oculi, inferior | 628 |
| oculi, internus | 627 |
| oculi, superior | 627 |
| Recurrent laryngeal nerve | 41 |
| Reflex power | 510 |
| Region, anal | 307 |
| digastric | 34 |
| inguinal | 215 |
| ischio-rectal | 307 |
| parotidæan | 34 |
| popliteal | 382 |
| recto-bulbar | 321 |
| subclavicular | 79 |
| sublingual | 36 |
| submaxillary | 34 |
| urethral | 307 |
| Regions of the abdomen | 226 |
| of the bladder | 324 |
| Reil, island of | 475. 479 |
| Renal arteries | 282. 421 |
| capsule | 288 |
| plexus | 287. 583 |
| veins | 439 |
| Respiration | 298 |
| Respiratory nerve, external | 552 |
| nerve, internal | 550 |
| tracts | 509 |
| Restiform bodies | 502. 515 |
| Rete testis | 335 |
| Retina | 655 |
| central artery of | 412 |
| Retinacula of the hip-joint | 841 |
| Retrahens aurem muscle | 5 |
| Rhomboid ligament | 817 |
| Rhomboideus major muscle | 140 |
| minor muscle | 139 |
| Ribs | 755 |
| articulations of | 813 |
| dislocations of | 816 |
| Ribes, ganglion of | 521 |
| Rima glottidis | 62. 67 |
| Ring, abdominal, external | 191 |
| abdominal, internal | 205 |
| Ring, femoral or crural | 223 |
| inguinal, external | 191 |
| inguinal, internal | 205 |
| Roots of the lungs | 93 |
| Rostrum of sphenoid bone | 729 |
| Rotula | 776 |
| Round ligament of the uterus | 352 |
| Ruysch, membrane of | 648. 649 |
| Sac, lachrymal | 624 |
| Sacciform ligament | 828 |
| Sacculus laryngis | 68 |
| vestibuli | 684 |
| Sacral artery, lateral | 422 |
| artery, middle | 282. 421 |
| ganglions | 584 |
| nerves | 567 |
| plexus | 568 |
| Sacro-lumbalis muscle | 143 |
| Sacro-sciatic ligament, great | 837 |
| ligament, lesser | 838 |
| Sacrum | 709 |
| Sagittal suture | 732 |
| Salivary glands | 12 |
| Salvatella vein | 161. 436 |
| Santorini cornicula | 60 |
| incisuræ | 669 |
| musculus risorius | 26 |
| Saphena vein | 216 |
| vein, external | 437. 384 |
| vein, internal | 437. 361 |
| Saphenic opening | 216. 363 |
| Saphenous nerve, external | 573 |
| long, or inferior | 565 |
| short or superior | 564 |
| Sartorius muscle | 365 |
| Scala tympani | 683 |
| vestibuli | 683 |
| Scalenus anticus muscle | 72 |
| medius muscle | 73 |
| posticus muscle | 73 |
| Scalp | 1 |
| Scalp, pathology of | 4 |
| Scaphoid bone of carpus | 794 |
| bone of tarsus | 783 |
| fossa | 666 |
| Scapula | 786 |

Page.
Scapular artery, posterior . 415
artery, superior . . 415
Scapulo-clavicular articulation . . . . 819
Scarpa, fascia of . . 185
fluid of . . . . 684
Schindylesis . . . . 800
Schneiderian membrane . 603
Sciatic artery . . . . 423
nerve, great . . 570
nerve, lesser . . 569
Sclerotic coat of the eye . 642
Scrobiculus cordis . . 226
Scrotum . . . . . 331
Sebaceous glands . . 594
Sella Turcica . . . . 729
Semicircular canals . . 681
canals, membraneous . 684
Semilunar bone . . . 794
cartilages . . . . 851
fascia . . . . 156
ganglion . 91. 281. 582
valves . . . . 114
Semimembranosus muscle . 381
Semispinalis colli muscle . 144
spinalis dorsi muscle . 144
Semitendinosus muscle . 381
Sense of hearing . . . 665
of sight . . . . 612
of smell . . . . 604
of tact . . . 587. 594
of taste . . . 605. 611
of touch . . . 586. 594
of vision . . . . 662
Sensitive tracts . . . 509
Septum auricularum . . 111
cervico-thoracic . . 28
crurale . . . 212. 219
of Lieutand . 113. 118
lucidum . . . . 481
pectiniforme . . 340
scroti . . . . 332
ventriculorum . 112. 117
Serratus magnus muscle . 80
posticus inferior muscle 140
posticus superior muscle 140
Sesamoid bones of foot . 785

Page.
Sesamoid bones of hand . 797
Sheath of the femoral vessels 205. 221
of flexor tendons . 167
of the rectus abdominis 200
Shoulder, dissection of . 148
joint . . . . 821
joint, dislocations of . 823
Sight, sense of . . 612. 662
Sigmoid artery . . 281. 421
cavities of ulna . . 791
flexure of colon . . 252
notch of lower jaw . 743
valves . . . . 114
Sinus, aortic, great . 120. 407
aortic, lesser . . 407
basilar . . . . 464
of the bulb . . 344
cavernous . . . . 463
circular . . . . 464
coronary . . . . 112
frontal . . . . 721
lateral . . . . 463
longitudinal, inferior . 462
longitudinal, superior . 461
of Morgagni 48. 114. 118
occipital . . . . 464
palpebral . . . . 620
petrosal, inferior . 464
petrosal, superior . 464
pocularis . . . . 344
of the porta . . 281
prostatic . . . . 344
sphenoid . . . . 729
straight . . . . 463
transverse . . . 464
uterine . . . . 355
of Valsalva . 114. 118
venosus, of the heart, left . . . . 116
venosus, of the heart, right . . . . 110
vertebral . . . . 505
Skeleton . . . . . 688
Skin, anatomy of . . 586
colouring matter of . 591
Skull . . . . . 712

| | Page. |
|---|---|
| Skull, base of | 735 |
| regions of | 733 |
| Smell, organ of | 599 |
| sense of | 604 |
| Socia parotidis | 14 |
| Soemerring, spot of | 656 |
| Soemerring's levator glandulæ | 32 |
| Solæus muscle | 392 |
| Solar plexus | 92. 281. 582 |
| Soft palate | 42. 50 |
| Sounds of the heart | 131 |
| Space, oculo-palpebral | 621 |
| subarachnoid | 465 |
| subarachnoid, spinal | 506 |
| Spermatic arteries | 282. 421 |
| canal | 206 |
| cord | 336 |
| fascia | 192. 332 |
| region | 227 |
| veins | 439 |
| Sphenoid bone | 729 |
| sinuses | 729 |
| Sphenoidal folds of dura mater | 461 |
| suture | 732 |
| Spheno-palatine ganglion | 535 |
| nerve | 535 |
| Spherical aberration | 663 |
| Sphincter ani, externus | 305 |
| ani, internus | 306 |
| iridis | 654 |
| oculi muscle | 6. 618 |
| oris muscle | 11 |
| vaginæ muscle | 349 |
| vesicæ muscle | 326 |
| Spigelian lobe of liver | 265 |
| Spigot | 496 |
| Spinal accessory nerve | 40. 528. 546 |
| arteries, anterior | 414 |
| arteries, posterior | 414 |
| bulb | 500 |
| commissure, anterior | 508 |
| commissure, posterior | 508 |
| cord | 507 |
| cord, arteries of, anterior | 520 |
| Spinal cord, arteries of, posterior | 520 |
| cord, grey neurine of | 510 |
| cord, structure of | 509 |
| nerves | 548 |
| nerves, cervical | 41. 548 |
| nerves, dorsal | 558 |
| nerves, functions of | 512 |
| nerves, lumbar | 561 |
| nerves, origins of | 511 |
| nerves, sacral | 567 |
| ventricle | 511 |
| Spinalis colli muscle | 144 |
| dorsi muscle | 143 |
| Splanchnic nerves | 91 |
| nerve, great | 581 |
| nerve, lesser | 581 |
| Spleen | 277 |
| pathology of the | 278 |
| Splenic artery | 280. 420 |
| omentum | 236 |
| plexus | 583 |
| Splenius capitis muscle | 141 |
| colli muscle | 141 |
| Spongy portion of the urethra | 342. 344 |
| Spot, germinal (Wagner) | 357 |
| Squamous suture | 733 |
| Stapedius muscle | 678 |
| Stapes | 677 |
| Stellate ligament | 813 |
| Steno's duct | 14 |
| Sterno-clavicular articulation | 816 |
| Sterno-cleido mastoideus muscle | 28 |
| Sterno-costal ligaments | 816 |
| Sterno-costalis muscle | 82 |
| Sterno-hyoideus muscle | 31 |
| Sterno-thyroideus muscle | 31 |
| Sternum | 753 |
| Stomach | 240 |
| coats of | 241 |
| pathology of | 262 |
| vessels and nerves of | 244 |
| Straight sinus | 463 |
| Stylo-glossus muscle | 38. 607 |

| | Page. |
|---|---|
| Stylo-hyoideus muscle | 38 |
| Stylo-hyoid nerve | 542 |
| Stylo-mastoid artery | 410 |
| Stylo-maxillary ligament | 803 |
| Stylo-pharyngeus muscle | 38. 47 |
| Styloid process of temporal bone | 724 |
| Subarachnoid fluid | 467 |
| fluid, spinal | 506 |
| space | 465 |
| space, spinal | 506 |
| Subclavian arteries | 39. 413 |
| vein | 40. 436 |
| Subclavicular region | 79 |
| Subclavius muscle | 80 |
| Sublingual artery | 409 |
| gland | 36 |
| region | 36 |
| Submastoid nerve | 542 |
| Submaxillary ganglion | 536 |
| gland | 34 |
| gland, pathology of | 35 |
| region | 34 |
| Submental artery | 409 |
| Suboccipital nerve | 548 |
| nerve, anterior division | 548 |
| nerve, posterior division | 550 |
| Subperitonæal cellular tissue | 219 |
| Subscapular artery | 416 |
| muscle | 153 |
| nerves | 554 |
| Succus intestinalis | 253 |
| Sudoriferous glands | 594 |
| Supercilia | 616 |
| Superciliary arch | 719 |
| Superficial fasciæ | 598 |
| Superficialis colli nerve | 15. 549 |
| cordis nerve | 578, 579 |
| volæ artery | 418 |
| Superior auris muscle | 4 |
| maxillary nerve | 535 |
| pyloric artery | 280 |
| vena cava | 98 |
| Supinator radii brevis muscle | 174 |
| radii longus muscle | 171 |

| | Page. |
|---|---|
| Supraclavicular nerves | 549. 552 |
| Supraorbital artery | 412 |
| nerve | 533 |
| Suprarenal capsule | 288 |
| plexus | 582 |
| Suprascapular artery | 415 |
| nerve | 553 |
| Supraspinatus muscle | 151 |
| Supraspinous fascia | 148 |
| ligament | 812 |
| muscles | 145 |
| Supratrochleator nerve | 533 |
| Suspensorius testis muscle | 195 |
| Suspensory ligament of the liver | 263 |
| ligament of the penis | 340 |
| Sutures | 732. 799 |
| coronal | 732 |
| ethmoidal | 732 |
| frontal | 732 |
| lambdoid | 732 |
| sagittal | 732 |
| sphenoidal | 732 |
| squamous | 733 |
| Swallow's nest | 497 |
| Sweat | 587 |
| Sweat glands | 594 |
| Sylvius, aqueduct of | 488 |
| fissure of | 478 |
| Sympathetic nerves | 41. 282. 574 |
| Symphysis | 800 |
| pubis | 765. 838 |
| Synarthrosis | 799 |
| Syndesmology | 799 |
| Synovial membrane | 800 |
| membrane of ankle-joint | 858 |
| membrane, atlanto-axoid | 808 |
| membranes, carpal | 833 |
| membranes, carpo-metacarpal | 834 |
| membrane, costo-vertebral | 814 |
| membrane, femoro-tibial | 847 |
| membrane, humero-cubital | 825 |

Page.
Synovial membrane, humero-scapular . . 822
membrane, ilio-femoral . . . . 841
membranes of the jaw 803
membrane, radio-carpal 830
membranes, scapulo-clavicular . . 819
membranes, sterno-clavicular . . . . 818
System, nervous . . 455
osseous . . . . 688
vascular . . . . 403
Systemic veins . . 428
Systole . . . . 130

Tact, sense of . 587. 594
Tænia hippocampi . . 485
semicircularis . . 483
Tapetum . . . . 650
Tarini pons . . . 480
Tarsal arteries . . . 426
cartilages . . . 619
nerves . . . 571
Tarsus, bones of . . 780
broad ligaments of . 619
Taste, organ of . . 605
sense of . . 605. 611
Tears . . . . . 623
Teeth . . . . . 744
development of . . 748
structure of . . 746
Temporal aponeurosis . 17
arteries, deep . . 411
artery . . 22. 410
artery, anterior . 410
artery, middle . . 410
artery, posterior . 410
bones . . . . 722
fascia . . . . 17
muscle . . . . 17
nerves . . . . 537
nerves, deep . . 537
ridge . . . . 720
vein . . . . 430
Temporo-auricular nerve 15. 538
Temporo-facial nerve . 542

Page.
Temporo-maxillary articulation . . 801
Temporo-maxillary vein . 431
Tendo Achillis . . . 391
oculi . . . 6. 618
palpebrarum . 6. 618
Tendon, cordiform, of diaphragm . . 294
Tendons, conjoined . . 195
Tensor palati muscle . 51
tarsi muscle . . 8
tympani muscle . . 678
vaginæ femoris muscle 364
Tentorium cerebelli . . 460
Teres major muscle . . 154
minor muscle . . 152
Testes . . . . 331
cerebri . . . 490
Testicle, pathology of the . 345
Thalami optici . . . 487
Thebesius, foramina of . 112
valve of . . . 112
Theca vertebralis . . 504
Thigh, muscles of . . 361
Thoracic aorta . 91. 418
artery, long . . 416
artery, superior . . 416
duct . 91. 283. 452
ganglions of the sympathetic . . 581
lymphatic glands . 449
nerves, anterior . 553
nerve, posterior . 552
Thorax, boundaries of . 86
dissection of . 74. 85
parts passing through base of . . . 105
parts passing through upper orifice of . 98
skeleton of . 753. 759
upper orifice of . . 98
Thumb, muscles of . . 177
Thymus body . . . 445
Thyro-arytenoid ligaments 62
Thyro-arytenoideus muscle 63
Thyro-epiglottic ligament 61
Thyro-epiglottic muscles . 65

| | Page. |
|---|---|
| Thyro-hyoid ligaments | 61 |
| Thyro-hyoideus muscle | 63 |
| Thyroid artery, inferior | 415 |
| artery, superior | 409 |
| axis | 414 |
| body | 32 |
| body, pathology of | 33 |
| cartilage | 58 |
| foramen | 767 |
| veins | 433 |
| Tibia | 776 |
| Tibia, dislocations of from the femur | 854 |
| Tibial artery, anterior | 389. 426 |
| artery, posterior | 427 |
| artery, recurrent | 426 |
| nerve, anterior | 572 |
| nerve, posterior | 402. 573 |
| Tibialis anticus muscle | 386 |
| posticus muscle | 395 |
| Tissue, adipose | 598 |
| adipose medullary | 599 |
| areolar | 597 |
| cellular | 597 |
| filamentous | 597 |
| osseous | 696 |
| Toes, bones of | 784 |
| Tongue | 43 |
| anatomy of | 605 |
| pathology of the | 44 |
| Tonsil, or amygdala | 52 |
| pathology of the | 56 |
| Tonsillitic artery | 409 |
| plexus | 544 |
| Torcular Herophili | 464 |
| Touch, organ of | 586 |
| sense of | 586. 594 |
| Trabeculæ | 340 |
| Trachea | 99 |
| pathology of the | 70 |
| structure of | 100 |
| Tracheal veins | 433 |
| Trachelo-mastoideus muscle | 144 |
| Tract, motor | 509 |
| olivary | 516 |
| respiratory | 509 |
| sensitive | 509 |

| | Page. |
|---|---|
| Tractus opticus | 524 |
| Tragicus muscle | 668 |
| Tragus | 666 |
| Transversalis abdominis muscle | 196 |
| colli artery | 415 |
| colli muscle | 143 |
| fascia | 203 |
| perinæi muscle | 310 |
| pedis muscle | 399 |
| Transverse facial artery | 21 |
| fissure of cerebrum | 470 |
| ligament of the atlas | 808 |
| meso-colon | 235 |
| sinus | 464 |
| Trapezium bone | 795 |
| Trapezius muscle | 137 |
| Trapezoid bone | 795 |
| ligament | 820 |
| Triangles of the neck | 29 |
| Triangular fascia | 194 |
| ligament of the urethra | 311 |
| Triangularis oris muscle | 10 |
| sterni muscle | 82 |
| Triceps adductor femoris muscle | 369 |
| Triceps extensor cubiti muscle | 157 |
| Tricuspid valves | 113 |
| Trifacial nerves | 525. 532 |
| Trigeminal nerves | 525. 532 |
| Trigone | 328 |
| Trochanters of femur | 774 |
| Trochleator muscle | 632 |
| Trochleatores nerves | 525. 532 |
| Tube of the cochlea | 681 |
| Eustachian | 675 |
| of Fallopius | 356 |
| Tuber cinereum | 479 |
| Tubercula quadrigemina | 490 |
| Tuberculum Loweri | 111 |
| Tubes of Ferrien | 285 |
| lactiferous | 75 |
| Tubuli recti | 335 |
| seminiferi | 335 |
| uriniferi | 285 |
| Tubulus centralis modioli | 682 |
| Tufts of Malpighi | 285 |

Page.

Tunica albuginea oculi . 627
albuginea testis . 334
communis . . 332
erythroides . . 332
sclerotica . . . 642
serosa Jacobi . . 656
vaginalis scroti . . 333
vaginalis of the spermatic cord . 206. 337
vaginalis oculi . . 629
vaginalis testis . . 333
vasculosa retinæ . 657
vasculosa testis . . 334
Turbinated bones . . 727
bones, inferior . . 741
bones of the sphenoid . 729
Tutamina oculi . . 613
Tympanic nerve . 541. 543
plexus . . . 686
Tympanum . . 670. 674
Tyrrell's fascia . . 312. 320
Tyson's glands . . . 340

Ulna . . . . . 791
Ulnar artery . . 182. 417
artery, recurrent anterior . . . 417
artery, recurrent posterior . . . 417
nerve . . 183. 556
Umbilical arteries . 422. 443
region . . . 226
vein . . . 442
Umbilicus . . . 190
Unciform bone . . . 795
Urachus . . 212. 323
Ureter . . . . 288
Urethra, female . . 348
male . . . 342
male, pathology of the 346
triangular ligament of 311
Urethral region . . 307
Uterine arteries . . 423
sinuses . . . 355
veins . . . 438
Uterus . . . . 352
Uvea . . . . 653

Page.

Uvula cerebelli . . 496
palati . . . 50
pathology of the . 56
vesicæ . . . 329

Vagina . . . 349. 351
Vaginal arteries . . 423
process of temporal bone 724
veins . . . 438
Vagus nerve . . 528. 544
Valley . . . . 492
Valsalva, sinuses of . 114. 118
Valve, coronary . . 112
of Eustachius . 111. 442
of foramen ovale . 443
ileo-cæcal . . . 250
ileo-colic . . . 250
mitral . . . 117
pyloric . . . 243
semilunar . . . 114
sigmoid . . . 114
of Thebesius . . 112
tricuspid . . . 113
of Vieussens . 490. 499
Valves of veins . . 429
Valvulæ conniventes . 255
Varolii pons . . . 491
Vas deferens . . . 336
efferens . . . 285
Vasa brevia . . 280. 420
efferentia testis . . 335
lactea . . . 451
lymphatica efferentia . 447
lymphatica inferentia 447
vorticosa . . . 648
Vascular system, anatomy of 403
Vasculum aberrans . . 336
Vastus externus muscle . 367
internus muscle . . 367
VEINS . . . . 427
structure of . . 429
auricular . . . 430
axillary . . 83. 436
azygos, major 91. 282. 434
azygos, minor . . 434
azygos, superior . 435
basilic . 150. 161. 436

Page.

VEINS—*continued.*
basi-vertebral . . 505
capsular . . . 439
cardiac . . . 122
cava, inferior . . 438
cava, superior . . 433
cavernosæ . . 438
cephalic . 149. 161. 435
cerebellar . . 463
cerebral . . . 462
coronary . . . 122
diploic . . . 430
dorsalis penis . . 438
emulgent . . . 439
facial . . 21. 430
femoral . . . 437
frontal . . . 430
Galeni . . 470. 485
Galeni (heart) . . 123
gastric . . . 245
hepatic . . 270. 439
iliac, common . 282. 438
iliac, external . 282. 437
iliac, internal . 282. 438
innominatæ . 98. 433
intercostal . . 435
jugular, anterior . 432
jugular, external
15. 26. 431
jugular, internal 40. 432
lingual . . . 431
maxillary, internal . 431
median . . 161. 436
median basilic . 161. 436
median cephalic 161. 436
mesenteric, inferior . 281
mesenteric, superior . 281
occipital . . . 430
ophthalmic . 431. 636
ovarian . . . 439
phrenic, inferior . 439
popliteal . . . 437
portal . . 269. 281
prelumbo-thoracic . 434
profunda femoris . 437
prostatic . . . 438
pulmonary . . 427

Page.

VEINS—*continued.*
ranine . . . 431
renal . . . 439
salvatella . . 161. 436
saphena, external 384. 437
saphena, internal
216. 361. 437
spermatic . . . 439
spinal . . . 505
splenic . . 269. 281
subclavian . 40. 436
superior cava . . 98
systemic . . . 428
temporal . . . 430
temporo-maxillary . 431
thyroid . . . 433
tracheal . . . 433
umbilical . . . 442
uterine . . . 438
vaginal . . . 438
vertebral . . . 433
vesical . . . 438
Velum interpositum . 470. 485
medullary, inferior . 495
medullary, superior
490. 495. 499
pendulum palati 42. 50
vesicæ . . . 328
Vena cava, inferior or ascending . 282. 438
cava, superior . 98. 433
Galeni (heart) . . 123
portæ . . 269. 281
Venæ comites . . . 429
Galeni . . . 485
vorticosæ . . . 648
Ventricles of the brain, fifth 481
of the brain, fourth . 497
of the brain, lateral . 482
of the brain, third . 488
of the heart, left . 117
of the heart, muscular fibres of . . 127
of the heart, right . 112
of the larynx . . 68
spinal . . . 511
of vestibule . . 684

| | Page. |
|---|---|
| Ventro-inguinal hernia . | 209 |
| Vermiform appendix . | 249 |
| process, inferior 493. | 496 |
| process, superior 493. | 495 |
| Vertebræ . . . . | 699 |
| cervical . . . . | 702 |
| common articulations of | 809 |
| dislocations of . . | 813 |
| dorsal . . . . | 701 |
| lumbar . . . . | 701 |
| Vertebral arteries . 414. | 519 |
| column . . . . | 706 |
| column, pyramids of . | 708 |
| sinuses . . . . | 505 |
| veins . . . . | 433 |
| Verumontanum . . | 344 |
| Vesica urinaria . . | 321 |
| Vesical arteries . . | 423 |
| fascia . . . . | 320 |
| veins . . . . | 438 |
| Vesicles, germinal (Purkinjie) . . . | 357 |
| Graafian . . . . | 357 |
| Vesico-uterine ligaments . | 353 |
| Vesiculæ seminales . . | 337 |
| Vestibular nerve . . | 685 |
| ventricle . . | 684 |
| Vestibule . . . . | 680 |
| Vibrissæ . . . . | 600 |

| | Page. |
|---|---|
| Vidian artery . . . | 411 |
| nerve . . . | 536 |
| Vieussens, valve of . 490. | 499 |
| Villi . . . . | 257 |
| Vision, organs of . . | 612 |
| sense of . . . | 662 |
| Vitreous humour . . | 661 |
| Vomer . . . . | 742 |
| Vulva . . . . | 347 |
| Vulvo-vaginal glands . | 348 |
| Wagner, germinal spot of . | 357 |
| Whartonian duct . . | 35 |
| Willis, circle of 414. 519. | 520 |
| Willisii cordæ . . . | 462 |
| Wilson's muscles . . | 314 |
| Wing of Ingrassius . . | 730 |
| Winslow, foramen of . | 236 |
| ligamentum posticum of . . 382. | 846 |
| Wormian bones . . | 717 |
| Wrisberg, nerves of 150. 555. | 560 |
| Wrist-joint . . . | 829 |
| Wrist-joint, dislocations of | 831 |
| Zinn, ligament or tendon of | 627 |
| zonula of . . . | 661 |

THE END.

# WORKS

PUBLISHED BY

# HODGES AND SMITH, DUBLIN.

---

**MEDICAL AND SURGICAL.**

---

LONDON: SOLD BY SIMPKIN, MARSHALL, AND CO.

AND ALL BOOKSELLERS.

MDCCCXLVII.

DUBLIN:
PRINTED AT THE UNIVERSITY PRESS,
BY M. H. GILL.

# MEDICAL AND SURGICAL WORKS,

PUBLISHED BY

## HODGES AND SMITH, DUBLIN.

**A TREATISE ON FRACTURES** in the Vicinity of Joints, and on certain Forms of Accidental and Congenital Dislocations. By ROBERT WILLIAM SMITH, M. D., M. R. I. A., Fellow of the Royal College of Surgeons in Ireland. Illustrated with 200 Engravings on Wood. 1 vol. 8vo., boards, 16*s*.

"Now that the Profession is inundated with Manuals, Vade Mecums, and merely elementary works, it is a pleasure to have a work like Dr. Smith's brought under one's notice. The first chapter, on Fractures of the Neck of the Femur, is amply illustrated by cases which have fallen under the author's notice; and we may mention that similar practical illustrations of his remarks are furnished to every other chapter. Another commendable feature of the work is, the useful summary which is drawn up from what precedes, and placed at the end of each chapter, giving, at one view, the facts which are illustrated, and the results which have been arrived at. The second chapter is occupied with an inquiry into the phenomena of Chronic Rheumatic Arthritis, a disease producing symptoms very nearly resembling those of fracture of the neck of the thigh bone, and which, therefore, have given rise to many mistakes. Fractures of the Fore-arm in the Vicinity of the Wrist-joint form the subject of the succeeding chapter. Then follow Fractures in the Vicinity of the Shoulder-joint; then those of the Clavicle; and after these have been well handled, we are brought to the consideration of dislocations affecting various joints, and lastly, Dislocations of the Lower Jaw. In perusing the chapters just named, the reader will gain much additional and valuable information, and a clearer insight into many particulars which are omitted, or but lightly passed over, in other works. We should like to have directed our reader's attention to many more points in the pathology of fractures and dislocations than we have done, points which would be of the greatest practical interest, and which are elaborately worked out in the treatise under consideration; but as we are unable to do so, we must recommend each person to consult the work for himself, believing that he will find it a most valuable addition to his stock of surgical books. We cannot conclude without speaking in praise of the perspicuous and flowing style in which the work is written, and in which it differs from very many of the works which now issue from the press. It is, moreover, amply illustrated by numerous engravings, and its typography does credit to Irish art."—*Lancet, May*, 1847.

"Dr. Smith has, in the work before us, proved himself a clever surgeon, for the difficult subjects on which he treats have evidently been well studied, and he has written in a style concise, and devoid of obscurity. Every chapter is replete with information to the surgeon, and there are nearly 200 illustrations, which are, certainly, very beautiful specimens of art. The work is a valuable addition to our professional literature, and a careful perusal of it will amply repay even veterans in the science."—*Medical Times*.

"We have no hesitation in stating that Mr. Smith's is undoubtedly the most important addition to the literature of surgical science with which we have been presented for many years. Replete with novel, accurate, and most valuable information on some of the most obscure and difficult points of every day practice, well arranged, and written in a style as concise and graphic as it is precise and easy to be understood. In short, we have never had to notice any surgical work in which there was so much deserving of the highest praise, so little that we would wish to see changed or curtailed, and we, therefore, recommend, in the strongest terms, both to the student and surgeon in practice, Mr. Smith's Treatise on Fractures and Dislocations."—*Dublin Quarterly Journal of Medical Science*.

LONDON: SIMPKIN, MARSHALL, & CO.

HISTORY AND TREATMENT OF DYSENTERY, AND ITS COMBINATIONS; with an Examination of their Claims to a contagious Character, and an Inquiry into the Source of Contagion in its analogous Diseases. By WILLIAM HARTY, M. D., Physician to the King's Hospital and to the Prisons of Dublin. Second Edition. 1 vol. 8vo., boards, 9*s.*

"This work, in the first edition, has long since taken its place among the standard literature of its subject. It developed views, which, if not entirely new, were before little known or indefinitely announced. The book concludes with an interesting chapter of diseases analogous to dysentery, from which we regret that our space will not allow us to quote; but we with pleasure state our conviction of the great value of the work, and our belief that whoever possesses it has at his command all that is known on the subject."—*Lancet.*

ELEMENTS OF CHEMISTRY; including the most recent Discoveries and Applications of the Science to Medicine and Pharmacy, and to the Arts. By Sir ROBERT KANE, M. D., M. R. I. A., Professor of Natural Philosophy to the Royal Dublin Society. 1 thick vol. 8vo., with 236 woodcuts, 24*s.*

"His high and well-established character as a scientific and practical chemist, his numerous and ingenious discoveries in his favourite science, discoveries which have, at this early period of his life, acquired for him a more than European fame, are a sufficient guarantee for the merits of any chemical work coming from Dr. Kane. The present work is now so universally acknowledged as the best text-book of chemistry in the English language, as to supersede the necessity of any remarks from us. If external reference to the great merits of Kane's Elements of Chemistry were necessary, we might point to the high character given of it by the greatest chemist of this or any other country, we mean the distinguished and worthy successor of Sir Humphrey Davy, Faraday, who has declared Professor Kane's work the best introduction to chemistry that has as yet appeared, and has recommended its adoption in the Royal School of Woolwich. Among the many excellent qualities of this work, we were forcibly struck by the great simplicity of the Author's style, which is such as to render even the more complicated parts of the science intelligible to the veriest tyro in chemistry, while to the more advanced student it cannot fail to recommend itself by the circumstance of its containing all the latest improvements and discoveries in chemical science. We perceive that our American friends are preparing a new edition."—*Johnson's Medico-Chirurgical Review.*

ELEMENTS OF PRACTICAL PHARMACY. By Sir ROBERT KANE, M. D., &c. 1 vol. 12mo., 8*s.* 6*d.*

SURGICAL ANATOMY OF THE ARTERIES, designed for the Use of Students in the Dissecting Room. By ROBERT HARRISON, M. D. Fourth Edition. 1 vol. 12mo., cloth, 9*s.*

PATHOLOGICAL ANATOMY. By G. Andral. Translated from the French by Richard Townsend, A. B., M. D., M. R. I. A., and William West, A. M., M. D. 2 vols. 8vo., cloth, £1 6*s.* 6*d.*

OBSERVATIONS ON THE DUBLIN PHARMACOPŒIA, with a Translation annexed. By F. Barker, M. D., F. R. C. S. I., and W. F. Montgomery, A. M., M. B., M. R. I. A., Professor of Midwifery in the King's and Queen's College of Physicians in Ireland, &c. 1 vol. 8vo., boards, 16*s.*

CAUSES, EXTENT, AND MORTALITY OF CONTAGIOUS FEVER IN IRELAND IN 1741, AND DURING 1817, 1818, 1819; together with a Review of the Causes, Medical and Statistical, productive of Epidemic Fever in Ireland. By William Harty, M. D. 1 vol. 8vo. boards, 10*s.* 6*d.*

OBSTETRIC AUSCULTATION. With an Analysis of the Evidences of Pregnancy, and an Inquiry into the Proofs of the Life and Death of the Fœtus in Utero. By Evory Kennedy, M. D., &c. &c. With an Appendix, containing legal Notes, by John Smith, Esq., Barrister at Law. 1 vol. 12mo., 6*s.* 6*d.*

A TREATISE ON INFLAMMATION. By James Macartney, M. D., F. R. S., &c. &c. 1 vol. large 4to., with plates, 15*s.*

NEW VIEWS OF THE PROCESS OF DEFACATION, and their Application to the Pathology and Treatment of Diseases of the Stomach, Bowels, and other Organs, together with an analytical Correction of Sir Charles Bell's Views respecting the Nerves of the Face. By James O'Beirne, M. D. 1 vol. 8vo., boards, 9*s.*

HÆMORRHOIDAL EXCRESCENCE, additional Observations on the Treatment of certain severe Forms of, illustrated by Cases. By JOHN KIRBY, M. D., F. R. C. S. I. 1 vol. 8vo. Price 3*s.*

DESCRIPTION OF THE LIGAMENTS OF THE HUMAN BODY. By JOSIAS WEITBRECHT, M. D. Translated by ROBERT HARRISON, M. D. 8vo., 2*s.* 6*d.*

SURGICAL PATHOLOGY OF THE LARYNX AND TRACHEA, chiefly with a View to illustrate the Affections of those Organs which may require the Operation of Bronchotomy. By W. H. PORTER. 8vo., 8*s.*

DUBLIN HOSPITAL REPORTS AND COMMUNICATIONS IN MEDICINE AND SURGERY. 5 vols. 8vo., cloth, £3 9*s.*

ANATOMY AND PHYSIOLOGY OF THE NERVOUS SYSTEM. By VALENTINE FLOOD. 5*s.*

ANATOMY OF THE CEREBRAL NERVES AND GREAT SYMPATHETIC. Translated from the French of Cloquet. 12mo., 3*s.*

DUBLIN PHARMACOPŒIA. 1 vol. 8vo., 12*s.*

OPERATIVE SURGERY, containing a Description of the most approved Plans of performing the different Operations in Surgery; principally designed for the Use of Students. By WILLIAM HARGRAVE, A. M., M. D., M. R. C. S. I. 1 vol. 12mo., boards, 9*s.*

# THE DUBLIN QUARTERLY JOURNAL

## Of Medical Science;

INCLUDING THE LATEST DISCOVERIES IN MEDICINE, SURGERY, AND THE COLLATERAL SCIENCES.

*Published on the* 1*st of February, May, August, and November.*

The DUBLIN QUARTERLY JOURNAL consists of three divisions:—ORIGINAL COMMUNICATIONS, in the form of Essays, Monographs, and details of Hospital Practice;—critical and analytical REVIEWS and BIBLIOGRAPHICAL NOTICES of every work of merit that appears, either at home or on the Continent;—and, in order to keep pace with the present condition of periodic Medical Literature, the new Series contains, under the head of SCIENTIFIC INTELLIGENCE, extensive RETROSPECTS and REPORTS on the progress of the various branches of Medical Science, arranged by gentlemen distinguished in each of these separate branches of knowledge, and compiled from the latest and best works and Periodicals in our own as well as the French, German, and Italian languages. Each Number will contain one or more of these Reports, together with the valuable Reports and Proceedings of the Dublin Pathological Society.

THE MEDICAL MISCELLANY attached to this section of the Journal, is chiefly devoted to Original Cases, and likewise contains Biographical Memoirs of distinguished Irish medical men, and occasionally *Portraits* of some of the most eminent practitioners that have flourished in this country, &c. &c. The Publishers have likewise established correspondents in the chief cities on the Continent to supply them with the earliest medical intelligence. They are thus enabled to afford, at a moderate cost, a Journal which, it is hoped, will be not only the mirror of Irish Medical Science, but be able to cope with the best medical Periodicals of the day.

The numbers published during the first eighteen months contain the following Original Communications, &c., on

### Medicine.

On the Law which regulates the Relapse Periods of Ague. By R. J. GRAVES, M. D.

Observations on the Nature and Treatment of various Diseases. By R. J. GRAVES, M. D.

DUBLIN QUARTERLY JOURNAL OF MEDICAL SCIENCE—*continued.*

On Chlorosis and Hæmorrhage. By Sir HENRY MARSH, Bart., reported by Dr. HILL.

Researches on the Symptoms and Diagnosis of Aneurism of the Aorta. By the late G. GREENE, M. D., edited by Dr. S. GORDON.

Observations on some Cases of permanently slow Pulse. By W. STOKES, M. D.

Account of the Case of the late Mr. Colles. By W. STOKES, M. D.

Remarks upon Cerebro-Spinal Arachnitis. By R. MAYNE, M. B.

Observations on Epidemic Dysentery and Diarrhœa, with Cases. By JOSEPH LALOR, M. D., L. R. C. S. I.

Observations on the recent Epidemic Influenza among Children. By FLEETWOOD CHURCHILL, M. D.

Medical Problems. By WILLIAM GRIFFIN, M. D.

Some Particulars respecting Swift and Stella, with Engravings of their Crania; together with some Notice of St. Patrick's Hospital. By W. R. WILDE, with Communications from Dr. MAC KENZIE and Mr. HAMILTON.

## Surgery.

Observations on Lithotomy. By Sir PHILIP CRAMPTON, Bart., F. R. S.

Lithotrity. By Sir PHILIP CRAMPTON, Bart., F. R. S.

On the Treatment of Aneurism by Compression. By W. H. PORTER, M. D.

On the Cure of Popliteal Aneurism by Compression. By J. M. O'FERRALL, M. D. With Illustrations.

On Syphilis contracted from nursed Children. By J. C. EGAN, M. D.

On the Extirpation of the Lachrymal Gland. By C. HALPIN, M. D.

The History of the Cure of Popliteal Aneurism by Compression. By THE EDITOR. With Cases by the late Mr. TODD, Sir PHILIP CRAMPTON, Bart., and Messrs. CUSACK, ADAMS, and HARRISON.

Aneurism by Anastomosis in the Cavity of the anterior Nares, with Remarks. By SAMUEL WILMOT, M. D., President of the Royal College of Surgeons in Ireland.

Remarks upon the Removal of loose Cartilages from the Joints. By ROBERT LISTON, F. R. S.

Some Remarks on the Use of Inoculation in Syphilitic Buboes, as a Guide to their Treatment. By JOHN HAMILTON, M. R. I. A.

DUBLIN QUARTERLY JOURNAL OF MEDICAL SCIENCE—*continued.*

## Midwifery.

Observations on Uterine Polypi and Ulceration. By W. F. MONTGOMERY, M. D.

Observations on the Use of Ergot of Rye. By T. E. BEATTY, M. D.

On Excision of the Cervix Uteri for carcinomatous Diseases. By J. Y. SIMPSON, M. D., Edinburgh. With Illustrations.

Observations on Placenta Prævia, with Cases. By A. TYLER, M. D.

Practical Observations on some congestive, inflammatory, and ulcerative Affections of the Uterus. By EVORY KENNEDY, M. D. With coloured Plates and Illustrations.

## Pathology.

On the Microscopical Characters of Mollities Ossium. By J. DALRYMPLE, F. R. C. S. E. With Illustrations.

## Materia Medica.

On the Detection of spurious Musk Pods. By J. M. NELIGAN, M. D.

## Chemistry.

On the Efficacy of Electricity, Galvanism, Electro-Magnetism, and Magnetic Electricity in the Cure of Disease. By Mr. DONOVAN.

## Medical History.

The Editor's Preface. The History of Periodic Medical Literature in Ireland; together with Biographical Memoirs of Drs. GREENE and HOUSTON.

## Illustrious Physicians and Surgeons in Ireland.

Memoirs of distinguished Irish medical men will appear regularly in this Journal, frequently accompanied with Portraits. There have already appeared memoirs of

I. Sir P. DUN, Founder of the School of Physic in Ireland.

II. BARTHOLOMEW MOSSE, M. D., Founder of the Lying-in Hospital.

III. D. MACBRIDE, M. D., Author of a Methodical Introduction to the Theory and Practice of Physic.

IV. JOHN RUTTY, M. D., author of a Chronological History of the Weather and Seasons, and of the prevailing Diseases of Dublin, &c. &c.

DUBLIN QUARTERLY JOURNAL OF MEDICAL SCIENCE—*continued.*

Memoirs of the following are in preparation for the approaching Numbers:

SYLVESTER O'HALLORAN, M. D.
Sir THOMAS MOLYNEUX.
JAMES MACARTNEY, M. D.
RICHARD STEEVENS, M. D., &c. &c. &c.

## Reviews and Bibliographical Notices.

Budd on the Liver—Foy, Mialhe, Moure et Martin, Ballard and Garrod, on Materia Medica—Parker on Syphilis—Copland's Dictionary—Leroy D'Etiolles' Urologie—Reichenbach on Magnetism—Bennett on the Uterus—Homœopathy and Homœopathic writings—Phillips on the Potato Disease—Walshe on Cancer—Gunsburg and Donne's Microscopic Inquiries—Todd on the Brain and Spinal Cord—Murphy on Parturition—Raciborski and Chereau on Menstruation—Smith on Hydrocephalus—Hastings on Naphtha in Consumption—Calmeil on Epidemic Insanity—Cox on Amputation of the Hip-joint—Corrigan on Fever and Famine—Steenstrup on the Alternation of Generations—Teale on Abdominal Hernia.

Parliamentary Reports on Lunatic Asylums—Taylor's Medical Jurisprudence—Boudon's Mortality in the Army and Navy—Aldridge's Lectures on Urinary Diseases—Marshall on Military Punishments—Lebert's Physiologie Pathologique—Tuson on the Female Breast—Lugot and Philips on Scrofula—Lindley's Vegetable Kingdom.

Brodie's, Liston's, Chelius's, Ferguson's, and Miller's Surgery—Parkes on the Dysentery and Hepatitis of India—Patterson's Zoology—Makellar on Black Phthisis—Leeson's Exposition of Liebig's Physiology—Griffiths on the Blood and Human Secretions—Rees on the Blood and Urine in Health and Disease.

Recent works on Pathology; Vogel, Hoffman, Wagner, Valentin, Hassall, Liebig, Mulder—Noble and Wolkott on Phrenology—Burrowes and Copeman on Cerebral Diseases—Swedenborg's Economy of the Animal Kingdom—Coley and Underwood on Diseases of Children—Catalogue of Bartholomew's Museum—Searle's Philosophy of Life—Milroy, White, &c., on Quarantine and the Plague—Kennedy's Fever Hospital Report—Ellis's Clinical Surgery—Ormerod's Clinical Surgery—Guy's Hospital Reports—Clark on Climate—Turnbull's Tabular View of the

DUBLIN QUARTERLY JOURNAL OF MEDICAL SCIENCE—*continued.*

Diseases of the Lungs—Harty on Dysentery—Williams on the Tongue—On the sanatory Condition of Dublin: Antisell, Robinson, Hayward and Brassington, Willis, Wilde—Smith on Fractures of the Joints—On the Potato Disease: Smee, Parkin, Cooper, Swan—Neligan on Medicines—Woods on Phthisis —Marshall Hall's Observations and Suggestions on Medicine.

## Reports, Retrospects, &c.

Proceedings of the Pathological Society of Dublin—Retrospect of Chemical Science, by Dr. ALDRIDGE—Retrospect of Materia Medica and Therapeutics, by Dr. NELIGAN—Reports on the Diseases of Infants, by Dr. F. BATTERSBY—Retrospect of the Progress of Practical Medicine, by Dr. J. O. CURRAN—Report on the Progress of Ophthalmic Surgery, by W. R. WILDE, M. R. I. A.—Report on the Pathology, Diagnosis, &c., of Abscesses of the Iliac Fossæ.

## Medical Miscellany.

Consisting of Cases by Drs. BANKS, FERGUSON, HUNTER, ROGERS, H. KENNEDY, PUREFOY, HALPIN, ORPEN, AUSTEN, HAMILTON, ELLSWORTH, HUMFREY, MARSHALL, ASTON KEY, PURDON, O'FLAHERTY, CUSACK, WILDE, Sir H. MARSH, PEMBERTON, GELSTON, DARLEY, HUGHES, SMILY, WILMOT, COOPER.

---

The Dublin Quarterly Journal is exchanged with nearly every medical Periodical of note in Europe or America; and the advantage which this affords, as well as its extensive general circulation, renders it an admirable medium for advertising Schools, Lectures, Surgical Instruments, and other subjects connected with Medical Science. Each quarterly Number, two of which will form a Volume, contains about 300 pages, 8vo. Price £1 per annum, or 5*s.* a Number.

The half-yearly volumes may be had, handsomely bound, on every First of May and November, price 10*s.* 6*d.*

DUBLIN QUARTERLY JOURNAL OF MEDICAL SCIENCE—*continued.*

## Opinions of the Press.

"THE Dublin Medical Journal, which has long ranked as one of the most able representatives of Medical Science in Ireland, has recently been transformed into a Quarterly Periodical, under the editorship, we understand, of Mr. Wilde. . . . We have no doubt that the Dublin Quarterly will prosper, and increase the high character which it bears in periodical Medical Literature. The first Number, which we have now before us, promises well for the future. . . . In conclusion, we wish our contemporary every possible success. We have the highest opinion of the Irish Medical School,—a School remarkable for its sound clinical character, and its freedom from speculative fancies, and wish well to its representatives in the Medical Press."—*Lancet.*

"It certainly should succeed, as it has many strong claims on the Medical Profession; it is the first and only Irish Medical Review; it was the first successful Periodical that emanated from the Irish Press; and it will, we doubt not, in its intrinsic value, be henceforth no less distinguished than it has hitherto been."—*Northern Whig.*

"The perusal of the new Quarterly Periodical of Medicine must give great satisfaction to all who wish to see the Medical Science in Ireland provided with a Periodical in which it can be represented, as it is a Journal conducted by gentlemen placed above the suspicion of favouritism, or of having objects of personal interest, and which will vindicate the claims of this celebrated School of Medicine and Surgery to such share in the honours of discovery as it has a just and proper claim to.

"The present Periodical is the continuation, in a quarterly form, of the Dublin Journal of Medical Science, which was originally founded by Sir Robert Kane, and conducted by him, in connexion with Drs. Graves and Stokes . . . . We cannot conclude without thanking Mr. Wilde for the benefit he has conferred on Medical Literature, by procuring a Periodical so highly creditable to this country,—a Periodical which we have no hesitation in pronouncing to be inferior to none, either in Great Britain or the Continent, in the present day."—*Evening Mail.*

"Distinguished as it has heretofore been for ability, and the avoidance of any thing offensive to good taste, the character of those by whom it is hereafter to be conducted, no less than the evidence furnished in the Number before us, afford a sure guarantee that it will maintain its position among the ablest and most valuable Medical Periodicals of the day."—*Philadelphia Medical Examiner, June,* 1846.

"We have been led to exult in the memorials of literary and scientific greatness bequeathed to us by the illustrious Irishmen of former days; a Periodical, such as that before us, tells that the spirit which animated them still exists; and we should be unjust to the eminent men of the present age, did we not acknowledge, that at no period in the annals of this, or any other nation, has the steady and increasing light of Medical Science shone with brighter lustre. It is for the young to appreciate the responsibility, as well as privilege, of sustaining and spreading an illumination so honourable to their country."—*Hospital Gazette.*

"If we may judge from the first Number, we cannot hesitate to prophesy a triumphant career: we have never seen a medical publication of the sort so full of interesting and useful matter. We admire its arrangements exceedingly."—*County Chronicle.*

"This Journal, which has flourished from the year 1832 until the present time, during which period twenty-eight volumes have been published, has now assumed a new and enlarged form. Its pages are devoted to medical and surgical science in all branches, including Chemistry, Materia Medica, and Botany, 'unconnected with medical politics, and uninfluenced by party feeling, jealousy, or personal hostility.' . . . . It is satisfactory to observe the increasing disposition which prevails, both in England and in Ireland, to encourage and support undertakings of this description."—*Pharmaceutical Journal, March 1st,* 1846.

"Of the style and appearance of the new Quarterly it is not too much to say, that it is the most elegant and best got up medical periodical ever published either here or elsewhere; and we have no doubt its matter will not belie its external appearance. . . . . It has every element of success to begin with. As a typographical work, it is most creditable to the present state of the arts amongst us; the most distinguished physicians of the day are contributors to its pages; and the editorial labours are performed with zeal and industry, and more than usual talent."—*Dublin Evening Post, March 19th,* 1846.